

Ciprofloxacin

Dr. Sameer Agarwal
MD, Medicine
Heart & Diabetologist
हृदय एवं डायबिटिक रोग विशेषज्ञ



TULSI HOSPITALS INDIA LTD.®

(A UNIQUE Multi - Speciality Health CENTRE)

14/116-A, Civil Lines, Kanpur - 208 001

Phones : (0512) 2536404, 05, 06, 9598060511-12

E-mail : tulsihospitalsltd@gmail.com

Website : www.tulsihospitalsindialimited.com

16/12/10

Mr Chintan Ram Chaudhry,

4

Tae GRANATONE 17ms 0.00
50

Tae PANTOCARDUO 10 2

~~Tae PAPA GUT 1000 00~~
~~400~~

Glucocorm 1307 00

Tae METFORMIN 1ms 0.00 2046
Ses Huesp

~~Tae PAPA 1~~

2 1/2

FARZOLITE POWDER

3788ms 666

ad 2000

074 00 00 00 00

Tae PROTHERIDEN 10ms 0
50's

2ms 0.00

10ms 2

CBC
SGPT
Urea
Creatinine

A NAME U CAN TRUST

Nov 17 low backache - resolved improved
 3 Jan - R LL & lower back pain - after coughing & straining -

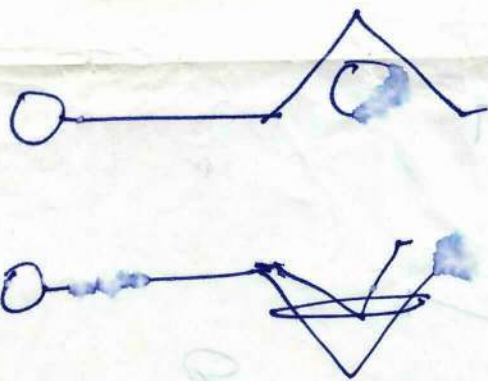
Non Diabetic

- ✓ Neural mg
- ✓ loss of lumbar lordosis

MRI 16.1.18. Central
 PIVD 4.5 8.5 mm ✓

Adv

- ✓ Disperzime 1 TDS before meals
 - ✓ Miolax A 1 BD
 - ✓ Pregabid NT 1 BD
 - ✓ Meconer forte 1 OD
 - ✓ 40 1 OD
- 1.2.18



no partial relief

9e Can walk on heels & toes

Sens. N

Aj bilak + int plantars ↓ ↓

- Adv
- ~~X Disperzime 1 BD < * 10 days~~
 - ~~X Miolax A 1 OD~~
 - ✓ Pregabid NT 1/2 BD <
 - ✓ Meconer forte 1 OD

Forward bending / rot lifting to be avoided

21/2/18

Prof. I. N. Vaiprey
 M.S. (Ortho Surgery)
 Reg. No. 20864 (U.P.)
 Ex. HOD. Surgery
 Prof. of Neurosurgery

9e after sitting long low back pain with occ. feeling of weakness

9e neural mg
 Central

- ✓ Robunaxol 1 TDS < * 15 days
- ✓ Pregabid NT 1/2 BD < } * 1 month
- ✓ Meconer forte 1 OD



VIKAS DIAGNOSTICS

- 1.5 Tesla M.R.I.
- MR Spectroscopy/MRCP
- 4D Colour USG./Doppler
- Fetal Echo
- DEXA (BMD)
- E.E.G./ECG
- 128 Slice Spiral C.T.
- 360° Open M.R.I.
- Digital X-Rays
- Digital O.P.G.
- Pathology
- Whole Body Angiography

111/75 & 82, Ashok Nagar (Near Shanti Niketan Sweet House), Kanpur

Ph. : 0512- 2540938, 2540398 • Mob. : 9935861112, 9935861113, 7753861112, 7753861113

Patient Name	: Shri Chintra Ram	16 December 2018
Ref. By Dr. Name	: Dr. Tusli Hospital	Age / Sex 49 Yrs / M
Investigation	: Ultra Sound Whole Abdomen	

OBSERVATION

- Liver** Normal in size (~13.5 cm), shape and echogenecity.
No evidence of any focal lesion.
Intra Hepatic Biliary Radicals not dilated.
Portal vein is normal in course and caliber ~10.6 mm.
- Gall Bladder:** Normal in distension and wall thickness.
No evidence of any sizeable calculus or mass lesion.
- CBD ~ 4.4mm at porta, normal in course, caliber and clear throughout it's course.
- Pancreas** Normal in size, shape and echogenecity.
No evidence of any sizeable mass lesion.
Main Pancreatic duct not dilated.
- Spleen** Normal in size (9.1cm), shape & Echogenecity. No evidence of any focal lesion. Splenic vein at hilum is normal.
- Retroperitoneum** No evidence of sizeable retroperitoneal lymphadenopathy.
Visualized segment of aorta and IVC normal.
- Right Kidney:** Right kidney is normal in size (~ 9.0x4.8cm), shape, position and echogenecity. CMD is normal. Pelvicalyceal system not dilated. No evidence of any calculus or mass lesion. Right ureter is not dilated.
- Left Kidney:** Left kidney is normal in size (~ 9.8x4.5cm), shape, position and echogenecity. CMD is normal. Pelvicalyceal system not dilated. No evidence of any calculus or mass lesion. Left ureter is not dilated.

Contd..



VIKAS DIAGNOSTICS

- 1.5 Tesla M.R.I.
- MR Spectroscopy/MRCP
- 4D Colour USG./Doppler
- Fetal Echo
- DEXA (BMD)
- E.E.G./ECG
- 128 Slice Spiral C.T.
- 360° Open M.R.I.
- Digital X-Rays
- Digital O.P.G.
- Pathology
- Whole Body Angiography

111/75 & 82, Ashok Nagar (Near Shanti Niketan Sweet House), Kanpur

Ph. : 0512- 2540938, 2540398 • Mob. : 9935861112, 9935861113, 7753861112, 7753861113

Patient Name : Shri Chintra Ram 16 December 2018
Ref. By Dr. Name : Dr. Tusli Hospital Age / Sex 49 Yrs / M
Investigation : Ultra Sound Whole Abdomen

Report contd.

Urinary Bladder Normal in size, shape & distention.
No evidence of any calculus or mass lesion
Post void residue ~ 3ml against pre.void volume ~306ml.

Prostate Normal in size (measures ~3.7x3.0x2.6cm weight ~15.7gms), shape and echogenecity. No median lobe enlargement.

No pleural effusion on either side.
No ascites.

Prominent bowel loops at bilateral flanks.

IMPRESSION: USG findings are suggestive of -


- Prominent bowel loops at bilateral flanks.
- Rest normal USG for whole abdomen.

Please correlate clinically

Kindly Note

- ❖ Ultrasound is not the modality of choice to rule out subtle bowel lesions.
- ❖ Please Intimate us for any typing mistakes and send the report for correction within 7 days.
- ❖ The science of Radiological diagnosis is based on the interpretation of various shadows produced by both the normal and abnormal tissues are not always conclusive. Further biochemical and radiological investigation & clinical correlation are required to enable the clinician to reach the final diagnosis.

The report and films are not valid for medico – legal purpose.


Dr. Shubhang Singhal
M.B.B.S. D.M.R.E.

Dr. Vikas Gupta
M.D.(Radiodiagnosis)
A.I.I.M.S.(New Delhi)
Ex. Sr. Resident (Radiodiagnosis)
A.I.I.M.S.(New Delhi)
(Consultant Radiologist)

Dr. Ashutosh Vajpeyi

M.S.(Surgery)

All
to Cipro

Residence :
2A/201, Azad Nagar,
Kanpur-208 002
Phone : 2562700

Pain
in
no
—

Chenta Ram

04 JAN 2019

Lenel 400 3/11/19

135/85

CBC, ESR
Mp
weirgy

• Rabiyas DSR
5/2/11/19

• Cyplos 500
5/2/11/19

• Fleg 1 200 1/11/19

• Paneta Plus 5/2/11/19

• DUNA 4/2/11/19

Vitasyne 5/2/11/19

5/2/11/19

• Jocyf 500
5/2/11/19

General & Laproscopic Surgery

CLINIC

113/149, Swaroop Nagar,
Opp. Bal Nikunj, Kanpur

CLINIC

0512-2530190
9839603000
9839075204

Regency Hospital

by appointment
Sarvodaya Nagar
Kanpur Ph.:2212001-5
1.00 p.m.to3.00p.m.

Dr. Ashutosh Vajpeyi
M.S.(Surgery)

All Cipro


Residence :
2A/201, Azad Nagar,
Kanpur-208 002
Phone : 2562700

Chintā Ram

14 JAN 2019

Sheet

ISD

- Rifampin 400 SE/2117 100 B.P.
SE/2117 100 WL.
 - Flegin 200 x 12 x 0
 - Cipro SE/2117 100
 - Panethin Plus SE/2117 100
 - Vitazyme 1/2 x 12 x 0
SE/2117
 - DUNA 1/2 गोली बरतना
10
10
- 

General & Laproscopic Surgery

CLINIC

113/149, Swaroop Nagar,
Opp. Bal Nikunj, Kanpur

CLINIC

0512-2530190
9839603000
9839075204

Regency Hospital

by appointment
Sarvodaya Nagar
Kanpur Ph.: 2212001-5
1.00 p.m. to 3.00 p.m.

Dr. Ashutosh Vajpeyi

M.S.(Surgery)

All to
GPO

Residence :
2A/201, Azad Nagar,
Kanpur-208 002
Phone : 2562700

Entamoeba

Chenta Ram

09 FEB 2019

CECT



- Sompnas it S.P.
SE/21/17 WL.
- Rifarus 400 C₀
- SE/21/17 C₀
- Paracetamol Plus C₀
- SE/21/17 C₀
- Metazone C₀
- SE/21/17 C₀
- DUNA 1/2 C₀

✓

General & Laproscopic Surgery

CLINIC

113/149, Swaroop Nagar,
Opp. Bal Nikunj, Kanpur

CLINIC

0512-2530190
9839603000
9839075204

Regency Hospital

by appointment
Sarvodaya Nagar
Kanpur Ph.:2212001-5
1.00 p.m.to3.00p.m.

July



THE GASTRO-LIVER HOSPITAL

7/190, D-Swaroop Nagar, VIP Road, Kanpur (U.P.) INDIA

Dr. No. : 9935556699, 9956653103, 8808556699
OPD : 9793555775, 9793555776
Hospi. : 9044066789, 9935556610

Associates

Dr. Deepak K. Awasthi

M.B.B.S., D.MCH
Asso. Consultant & Endoscopist

Dr. Anand N. Prasad

M.B.B.S., M.D (Med.), K.G.M.C.
Asso. Consultant & Endoscopist

ENDOSCOPY CENTRE

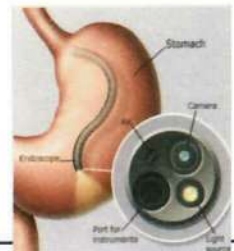e-mail: gastro.hospital@gmail.com

Chief Consultant

Dr. Vinod K. Mishra

M.D., D.M. (Gastro)

Gastroenterologist & Endoscopist



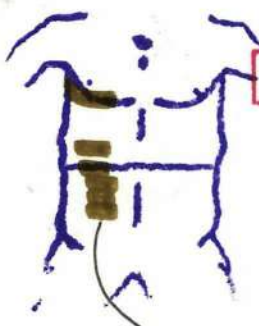
Mr. Chintu Ram
← X →

Date - 26/02/19

Wt - 62 kg

BP - 110/70 mm/Hg.

26 FEB 2019



DOMINANT PROBLEMS

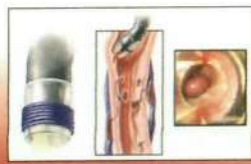Valvular
Recurrent
Severe
Constipation
etc

7

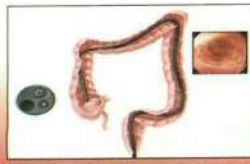DIET ↑
LIFE-STYLE →
NEXT VISIT ↓

Sprawl
whole abdomen] 26/2

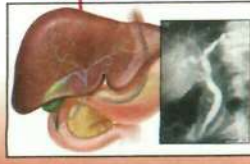✓ Adv
TAB Spasmotrol 0
SUR 4003 (SMA) 2/2



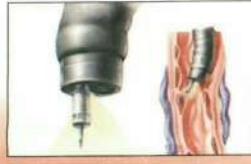Band Ligation



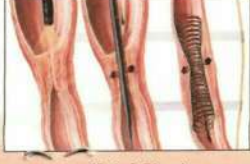Colonoscopy



ERCP



Sclerotherapy



Metal Stent

Challenging Your Imagination

4 MAR 2019

Adv
Top Mearase 0/0/0 → जाने के पके
Cap VSL-30 → 0 कुछ का 20 के वाक
Sub 1003 (≡) (≡) (≡)
20 20 20 ml
जाने के कस (15)

7
DIET ↑
LIFE-STYLE
NEXT VISIT ↓

DR Ankur Gupta

MS

SPIN

फोन: (घर) (512) 2352675
(मो) 9795955959

मिलने का समय
सबह 11.00 बजे से 2.00 बजे
शाम 6.00 बजे से 8.00 बजे

डा. अंकुर गुप्ता
एम.एस.
स्पाइनोलॉजिस्ट

क्लीनिक
8/13- आर्य नगर, ब्रजेन्द्र स्वरुप पार्क के सामने



PATIENT'S NAME : Mr. CHINTA RAM
REF. BY : GASTRO LIVER HOSPITAL

DATE: 04.03.2019
AGE/SEX: 49/M

NC+CECT WHOLE ABDOMEN

☞ Transaxial helical, multislice (16 slice) spiral CT scan of Abdomen has been performed in contrast dynamic mode. Non-ionic intravenous contrast given.

- ✓ Liver is normal in size, shape, contour and attenuation pattern. A focus of parenchymal calcification is seen in left lobe. Intrahepatic biliary channels are normal in caliber. Portal vein is normal in course and caliber.
- Gall Bladder is normal in size, shape and outline. No intraluminal hyperdensity or mass lesion seen.
CBD is normal in caliber.
- Pancreas is normal in size, shape and contour. No mass lesion or calcification evident.
- Spleen is normal in size. No mass lesion evident. Splenoportal venous system is normal.
- Both Kidneys are normal in size, shape, contour and position. No calculus or mass lesion evident. Renal parenchyma on either side shows uniform opacification. Pelvicalyceal system is of normal caliber.
Both ureters are non-dilated.
- Both adrenal glands are normal.
- Urinary bladder is normal in size and shape. No mass lesion evident.
- Prostate is normal in size, shape and attenuation. No focal lesion is seen.
- No sizeable abdominal lymphadenopathy, ascites or basal effusion seen.
- Visualized distended small bowel loops appear grossly unremarkable. Large bowel loops are partially collapsed with faecal contents.
- Appendix is visualized and appears normal.
- A mixed lytic, sclerotic area is seen in D11 vertebral body with subtle adjacent prevertebral soft tissue prominence. No collapse seen at present - ? Infective focus ? Nature. (MRI is advised for further comment).

✓ *Clinical correlation and further work-up is advised.*

Dr. AKHILESH SHARMA, MD
RADIOLOGIST


Dr. GURPREET SINGH, DMRD
RADIOLOGIST

(CT is not the modality of choice for the detection of gall bladder / biliary calculi. USG correlation is advised)

अल्फा इमेजिंग एण्ड रिसर्च इंस्टीट्यूट प्रा. लि.

Alpha Imaging and Research Institute Pvt. Ltd.

7/190, Sales Tax Road, Swaroop Nagar, Near Gastro Liver Hospital, Kanpur - 208002

Ph. : 0512-2530511, 7704803040, 7678907907

E-mail : alphaimagingkanpur@gmail.com



LONG LENGTH IMAGING

ALPHA IMAGING, for the first time in Kanpur introduces the facility of long length imaging, also called as stitch x-ray / scanogram / Hip-knee-ankle xray.

We have a true digital xray system (also the first in Kanpur) which obviates the need of a cassette, hence increasing xray resolution and quality along with decreasing noise and radiation exposure.

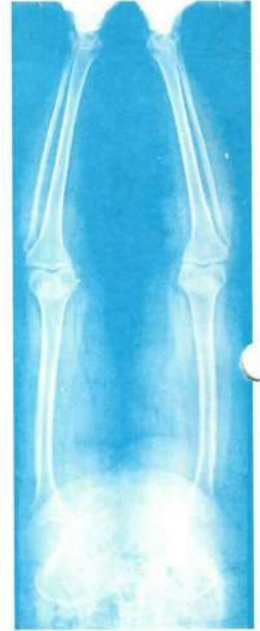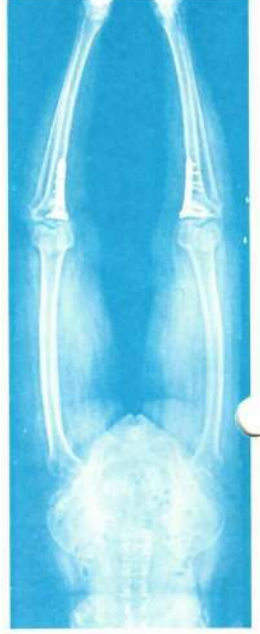Long length imaging comprises a full length xray of a patient extending from hip to ankle joint taken in standing weight bearing position, hence true and accurate depiction of abnormalities.

INDICATIONS

- ❖ Mechanical weight bearing abnormalities
- ❖ Leg length discrepancy (ltd)
- ❖ Leg deformities (genu varus / valgus , coxa vara , etc)
- ❖ Osteoarthritis
- ❖ Post operative follow up

ADVANTAGES

- ❖ Its advantages over previously used techniques like CT scanogram ,
- ❖ Since it is taken in standing position as against lying down position of CT scanogram, there is accurate depiction of axis in natural weight bearing position
- ❖ Precision of angles
- ❖ Low radiation dose
- ❖ Provision of measuring axis and angles in weight bearing position.

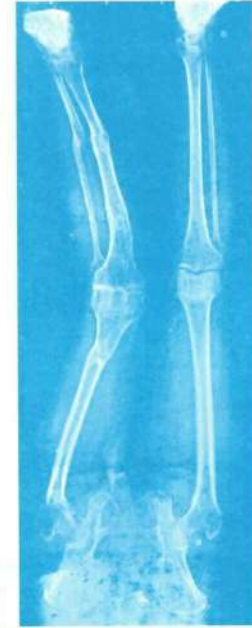
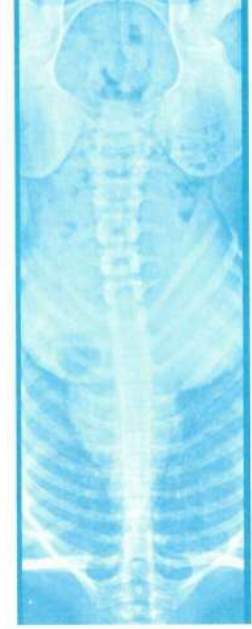
Dr. Akhlesh Sharma

Mob. : 7678901901

Dr. Gurpreet Singh

Mob. : 7678801801



Also Available : 16 Slice (low Radiation) Ct Scan · True Digital X-ray · 4d Ultrasound With Doppler · True Digital Dpg



RATAN MRI & SPIRAL CT CENTRE

7/141-A, SWAROOP NAGAR,
KANPUR - 208 002 INDIA
Phone : 0512-2530204
Mob. : 9935556603, 9935556604
E-mail : office@ratanhousing.com

- First Whole Body Super Conductive 1.5 Tesla MRI -16 Channel System (Philips Achieva) in U.P.
- Whole Body Ultrafast Spiral CT -16 Slice (Low Radiation)

Patient Name	: CHINTA RAM	11 March, 2019
Ref. By Dr. Name	: Dr. ANKUR GUPTA	Age / Sex 49 Yrs / M
Investigation	: MRI D.L Spine	

Observation:-

- Evidence of marrow edema is seen involving D11 vertebral body with evidence of a well defined round lesion within it showing T2 and STIR hyperintense peripheral area appearing hypointense on T1WI images . The central portion of this round lesion appears T2 and STIR hypointense with central hyperintensity. On CT correlation , there is extensive sclerosis of D11 vertebra with central portion of above mentioned lesion appearing sclerotic. Minimal pre vertebral soft tissue is seen at this level Possibility of chronic osteomyelitis appears more likely than Osteoid osteoma.
- Mild loss of lumbar lordosis is seen – likely due to paravertebral muscle spasm .
- Early bony degenerative changes are seen in form of marginal osteophytes .
- Rest of visualized vertebrae appear normal in morphology & signal intensity with maintained vertebral body height and posterior elements. No lytic lesions.
- L4/5 and L5/S1 intervertebral discs are dessicated with postero central annular tear and bilateral mild facet joint arthropathy.
- At L4/5 and L5/S1 levels , mild to moderate diffuse disc bulge with mild ligamentum flavum thickening are seen causing mild to moderate indentation over thecal sac with mild to moderate compromise of bilateral lateral recess and exit foramina.
- Rest of neural foramina appear patent.
- No pre/ paravertebral or epidural collection / granulation tissue.
- ✓ No evidence of any infective / tubercular focus.
- Both Spinal canal AP diameter at mid vertebral bodies and at discal levels is as follows-

L1 –	13.5mm	L1/2 -	13.5mm
L2 –	13.0mm	L2/3 -	12.0mm
L3 –	13.0mm	L3/4 -	10.0mm
L4 –	12.5mm	L4/5 -	8.5mm
L5 –	13.5mm	L5/S1 -	9.0mm
- Rest of the whole spinal cord, cord termination & conus medullaris are grossly normal.
- Posterior paraspinal soft tissue grossly normal.
- Bilateral psoas muscles and SI joints are normal.

Rest of cervical spine screening on T2 sag images show loss of cervical lordosis , mildly dessicated cervical intervertebral disc with mild diffuse disc bulges at C3/4, C4/5 , C5/6 and C6/7 levels .


Dr. RAHUL RANJAN
MD, DNB (Radiodiagnosis)

THE SPINE CLINIC

(In Association with Dr Shekhar Bhojraj's THE SPINE CLINIC, Lilavati & Breach Candy Hospital, MUMBAI)
8/13-A, Arya Nagar, (Ganges Club Road) Opp Brijendra Swaroop Park, Kanpur - 208002

Ph: 9795 408 448, 0512- 2555959

Time : 1pm to 7pm. (Saturday Evening & Sunday Closed)

www.spineclinickanpur.com

डा. अंकुर गुप्ता
Dr. Ankur Gupta

MBBS (KEM HOSPITAL, MUMBAI), MS(ORTHO.)

Spine Surgeon

Reg. No. UPMC : 78353

Spine Observership & Training - • New York University

• Jefferson Medical College, Philadelphia

Dr Bhojraj Spine Fellowship - Lilavati & Breach Candy Hospital, Mumbai.

Spine Fellowship -

• KEM Hospital, Mumbai.

• Spine Hospital Ahmedabad.

विशेषज्ञ

- गर्दन दर्द • पीठ दर्द • कमर दर्द
- स्पाइडिलोसिस • स्लिप डिस्क • शिथाटिका
- रीढ़ की हड्डी का - फ्रैक्चर, टी.बी., कुबड़ापन

In Emergency Contact

केवल आकस्मिक परिस्थितियों में सम्पर्क करें।

789 779 2211

परामर्श समय एवं नम्बर के लिये इस मोबाइल पर सम्पर्क न करें।

NC

Judge

Name CHINTA RAM M/49 Weight 60 Kg Date 6 MAR 2019

Job: (OCCUPATION) - Heavy/ Mild/ Sedentary/ House Wife / Shop / Field work / Travelling on Bad roads / Office

Ref. by.....

ET - D11 lesion ? LgHC

CHIEF COMPLAINS: Pain / Numbness / Pins and Needles / Burning / Bursting / Ants / Tiredness / Heaviness / Pulling Weakness / Bladder -Bowel involvement / Constipation / Acidity / Tension Signs- coughing, sneezing, straining / Imbalance/ Multiple aches and pains / Morning Stiffness / Giddiness / Swelling / Stiffness / Deformity / Night cramps / Fine finger Movement

L/R Low Back / Gluteal / Thigh / Mid Back / Coccyx / Hip / SI Joints / Knee / Calf / Ankle / Sole / Heel Sleep
Neck / Shoulder / Trapezius / Arm / Elbow / Forearm / Wrist / / Hands Allergy
LL - L/R Above / Below Knee Radiation - UL - L / R Above / Below Elbow Diet

Duration: _____ **Aggravated since:** _____ **Constitutional symptoms:** Fever / Weight loss / Loss of Appetite

Claudication: Rest pain, 0-10 min, 11-30 min, >30 min, Nil. **Walks** _____ min / km non stop

Progress: Improving/ same /Worsening/ On & Off/ Squatting Leg Pain Back Pain Climbing Stair

Long Sitting Long Standing Supination Walking Coughing Bending Log Rolling Jerk

FUNCTIONAL DISABILITY TO PATIENT

Difficulty getting up from sitting / lying position Bending
Continuously Bothersome Pain Lifting Weight
Walking difficult
Interfering with daily activities
Posture Changed
Able to perform all activities with bearable pain

Surgery: Spine Yes/No Spinal injections Yes/No
Others - TKR/ Hysterectomy

TREATMENT TAKEN : Bed rest / Physiotherapy / Traction / Yoga

RISK FACTORS: Smoker / Alcohol / Over weight / 2 wheeler

ON EXAMINATION

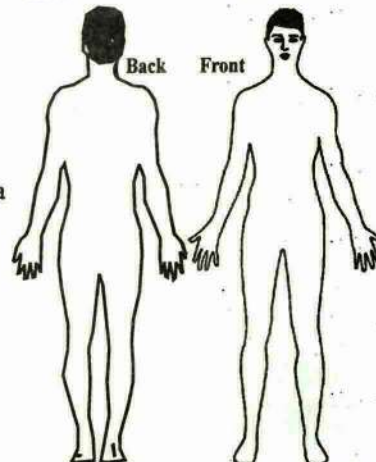
OA Knees Rom : Free / Restricted - Flex / Ext.

Tenderness: Gait: Deformity: (Kyphosis/ Scoliosis)

Swelling: +/- List: Cross legged sitting: Step:

CO MORBID CONDITIONS

DM Thyroid
HT TB
IHD BA



HB	
TLC	
DLC	
PLATELETS	
ESR	
CRP	
RBS	
URICACID	
CREATININE	
BILIRUBIN	
D3	
B12	
BLOOD GP	
ALKALINE PH.	

स्वीकृति पत्र - मुझे डाक्टर द्वारा अपनी/अपने मरीजकी बीमारी तथा उसके इलाज के विषय में सभी उपयुक्त जानकारी दे दी गई है। मैं समझता हूँ कि डॉक्टर द्वारा यथा सम्भव औषधियाँ मरीज के हित में दी जा रही हैं तथा हर यत्न के बाद भी बीमारी अथवा औषधियों से उत्पन्न होने वाली अवांछित घटनाएं यदा-कदा संभव हैं। मैं अपनी जिम्मेदारी पर अपने मरीज के इलाज के लिए डा. अंकुर गुप्ता को स्वीकृत करता हूँ।

.....(हस्ताक्षर / नाम / दिन / मरीज से रिस्त)

	Left Motor	Left Sensory	Right Motor	Right Sensory		RIGHT	LEFT
C5					FINGER ADDUCTION		
C6					BICEPS REFLEX		
C7					TRICEPS REFLEX		
C8					INVERTED RADIAL R.		
T1					KNEE REFLEX		
L1					ANKLE REFLEX		
L2					PLANTARS		
L3					PULSATION		
L4 (HEEL WALKING)					SI STRESS Test		
L5					SI TENDERNESS		
S1 (TOE WALKING)					SLR		
	SPURLING T.	SHOULDER ABDUCTION			HOFFMAN'S		

X-Rays: Lumbar spondylosis DISH FRACTURE Osteoporosis
 Listhesis - Lytic/ Degenerative Scoliosis/Kyphosis. Cervical Spondylosis Ankylosing Spondylitis

M.R.I: LCS PID LISTHESIS DDD CSM KOCHS TUMOR
 (Comp- Nil/Mild /Moderate/Severe) Du lesion ? 2B

PROVISIONAL DIAGNOSIS-

OPINION of DR Saket -

Biopsy
 → HPE
 → AFB

CBC
 ESR
 CRP

- प्रतिदिन टहलें
- व्यायाम करें
- सही मुद्रा अपनायें
- योग करें
- संयमित खानपान
- जल्दी-जल्दी उठना बैठना
- कार्यक्षेत्र की मुद्रा
- जीवन शैली में सुधार
- सूर्य की रोशनी
- स्वस्थ आहार
- वजन घटायें

Digital X-Ray

MRI

9956084847

DL Spine
 (MOR)
 P/Z Compare

..... दिन / सप्ताह / महीना के बाद पुनः परामर्श करें।

निवेदन : औषधि-विज्ञान द्वारा मरीज का इलाज शोधित जानकारीयों पर आधारित होने के साथ-साथ एक कला भी है। एक ही मरीज का दो डॉक्टर अलग प्रकार से विरलेषण कर सकते हैं तथा भिन्न औषधियां उपयोग कर सकते हैं। हर डॉक्टर अपनी शैक्षिक योग्यताओं तथा अनुभव के आधार पर मरीज को यथा संभव श्रेष्ठतम इलाज देने का प्रयास करता है। इलाज का नतीजा मरीज की बीमारी की तीव्रता तथा पूर्व में हो चुके नुकसान आदि पर निर्भर होता है। मरीज का पूर्णतया स्वस्थ होना या ना होना केवल डॉक्टर पर निर्भर नहीं है। अतः डॉक्टर की योग्यता का आंकलन कृपया एक मरीज के नतीजे पर आधारित न करें।

कृपया अपनी सभी पुरानी जाचें / रिपोर्ट / एक्स-रे / एम.आर.आई. हर बार लेकर आयें।

NOT VALID FOR MEDICOLEGAL PURPOSE

यह पर्चा 5 दिनों के लिये ही मान्य है।

SPINE & JOINT Timing: 12pm to 7pm
PHYSIOTHERAPY Contact: 7897792211




Sector - C, Vasant Kunj, New Delhi - 110070 Ph.: 91-11-42255225 (30 Lines), For Appointment - Ext. 201
 Fax : 91-11-26898810 E-mail: appointment@isiconline.org Visit us at : www.isiconline.org

OPD CARD 9717007717

Registration No. 641883
 Name Chinta Ram
 Age 49 M/F M DOB
 Address
 Phone
 Consultant Dr. Anurag
 ✓ Please bring this card on all subsequent visits.

DEPT. OF SPINE SERVICES
 UHID : 641883 Bill Date: 27/03/2019 Age/Sex 49 Yrs. /M
 NAME : Mr. CHINTA RAM
 DOCTOR: DR. ANKUR NANDA
 COMPANY : ISIC - 2018
 ADDRESS : I 10 CIRCUIT HOUSE COLONY KANPUR NAGAR
 UP KANPUR UTTAR PRADESH INDIA
 MOB No : 8874512136



Date	Chief Complaints / Past History
ISIC OPD	Dilator. ?? tubercular.
Date <u>27/3/19</u>	→ NO symptoms.
Signature <u>[Signature]</u>	→ <u>Adv.</u>
Allergies if any (Please Specify)	⇒ Advise. Transpedicle Biopsy.
Investigations Advised / Reports	⇒ Surgical Opn
Treatment Advised	⇒ Biopsy on 29/3.
	⇒ Cardio - Dfl
	⇒ PNE / All notes
	 Doctor's Name and Signature





DL IR Contract (A)

Visit type : Initial Visit
UHID : NHDL.46153
Patient Name : Mrs. SINA SHENA MANSOUR
Doctor : Dr. Vikram Singh
Mobile : 8860518241
Address : 3RD PANJSHER Kabul OTHER



Age / Sex : 36 Year(s) / Female
Department : Neuro-Surgery
Token No :
Bill No/Date time : DLCS44740 / 27-03-2019 12:56
Card expiry Date : 31-03-2019

PRESCRIPTION

Vitals:-
 Height: (cms.) Weight: (Kgs.) BP: (mmHg)
 Pulse: (bpm) Temp: (OF/OC) Pain Score:

HT:

DM:

Hypothyroidism:

CAD:

Allergy:

Past Surgery:

Nutritional Assessment:

Weight Loss:

Appetite:

Ch Cervical pain
Pain in back | *101 day*

MU Spine - A21 @

↓ GUD₃
↓ MTB_n

Ad, *Physio therapy of spine*

Precautions as advised

H2A B27, All joints ANA titre, Serum urea

CT Head plain

Cranioctomy - 1 day

P. Pegemov 25mg B₁₂

T. Hydrocortisone 15mg OD

T. Mefenamic acid 500mg OD

PO code

Dr. VIKRAM SINGH
 MS. M.Ch. Neurosurgery Sr. Consultant (Neurosurgeon)
 VIMHANS NAYATI SUPER SPECIALITY HOSPITAL
 1, Nehru Nagar, New Delhi-65
 DMC No. 29643, For Appointments-9071975970



Mr. Chintē Ram

MR. Chintā ram

27/03/2019

8874572136

D. Leria

As PET of whole Body - 50% discount

[Signature]

Dr. Anil Gupta

9871975970

Sanjay

DR. ANIL GUPTA (Neurosurgeon)
VIMHANS NAYATI HOSPITAL
Nehru Nagar, New Delhi-65
Appointments-9871975970

As
- Ref to J.B. spec
- LTR
Coagulation profs

Dr. Anil Gupta

9956684845



KANPUR NEURO GUIDE CENTRE

130220

Swaroop Nagar, Kanpur • Phone : 2545445, 7524853525

Estd. By : Dr. I.N. Vajpeyi

Consultant Neuro Surgeon

Dr. S. Suri

Mr Chintan Ram

1/2 Pain in both Shoulder & Scapuloacromial region : 1 month

pt is on ATT

PE
• Bilat frozen Sh L > R
• BP: 124 mm Hg
• Neurol neg

• Bilat frozen
L > R

Adv. Cont. of Dr Bharat Mehta MB
• physiotherapy

• Volium gel locally + fomentation

1/1. Roburinol 1 TDS ← after meals

• Balamine forte 1 OD →

• Gabapin NT 1/2 BD ←

• Carvigran 1 OD → bedtime

Prof. I. N. Vajpeyi

M.S., Mch. (Neurosurgery)

Reg. No. 20864 (U.P.)

Ex. HOD. Surgery

Prof. of Neurosurgery

नाम लिखाने का समय - प्रातः 12:00 बजे से सायं 5:00 बजे तक

आर० के० देवी मेमोरियल हास्पिटल के पास।

एमरजेन्सी मरीज नहीं देखे जाते हैं।

शनिवार बन्द रहेगा।



KANPUR NEURO GUIDE CENTRE

150320

Swaroop Nagar, Kanpur • Phone : 2545445, 7524853525

Estd. By : Dr. I.N. Vajpeyi

Consultant Neuro Surgeon

Dr. S. Suri

Mr Chinta Ram

Adm

Cont. of Dr Ashraf Meharota

SP: 130/80

- ✓ physiotherapy
- ✓ ~~violin~~ gel locally + fomentation
- ✓ Balamine forte 1 OD
- ✓ Gabapin NT 1/2 BD <
- ✓ Carnugo M 1 OD —

Prof. I. N. Vajpeyi
M.S. (Neurosurgery)
Reg. No. 22864 (U.P.)
Ex. HOD. Surgery
Prof. of Neurosurgery

नाम लिखाने का समय — प्रातः 12:00 बजे से सायं 5:00 बजे तक

आर० के० देवी मेमोरियल हास्पिटल के पास।
एमरजेन्सी मरीज नहीं देखे जाते हैं।
शनिवार बन्द रहेगा।



KANPUR NEURO GUIDE CENTRE

20 03 19

Swaroop Nagar, Kanpur • Phone : 2545445, 7524853525

Estd. By : Dr. I.N. Vajpeyi

Consultant Neuro Surgeon

Dr. S. Suri

No Chinta Ram
49

Resided pain in abd. @ gen pain in abd : 3 mths - Stab

9e, No spinal deformity / ^{No} tenderness

• Neural aug

• DTR + pl. ↓↓

Adv 40 ESR / Mx test - ve

✓ Biopsy from the lesion / PND

MR 16.1.18

P1V D L4-S L5S1

MR 11.3.19

D11 Vert body
mv E pre vert
Soft tissue

Emp ATT may be considered

Prof. I. N. Vajpeyi
M.S. Mch. (Neurosurgery)
Reg. No. 20864 (U.P.)
Ex. HOD. Surgery
of Neurosurgery

✓ Robaxol 1 TDE ← after meals
✓ Gabapent 1/2 BD ←

नाम लिखाने का समय - प्रातः 12:00 बजे से सायं 5:00 बजे तक

आर० के० देवी मेमोरियल हास्पिटल के पास।
एमरजेन्सी मरीज नहीं देखे जाते हैं।

शनिवार बन्द रहेगा।



THE GASTRO-LIVER HOSPITAL

7/190, D-Swaroop Nagar, VIP Road, Kanpur (U.P.) INDIA

Dr. No. : 9935556699, 9956653103, 8808556699
OPD : 9793555775, 9793555776
Hospi. : 9044066789, 9935556610

ENDOSCOPY CENTRE

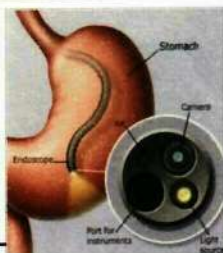e-mail: gastro.hospital@gmail.com

Chief Consultant

Dr. Vinod K. Mishra

M.D., D.M. (Gastro)

Gastroenterologist & Endoscopist



Associates

Dr. Deepak K. Awasthi

M.B.B.S., D.MCH

Asso. Consultant & Endoscopist

Dr. Anand N. Prasad

M.B.B.S., M.D (Med.), K.G.M.C.

Asso. Consultant & Endoscopist

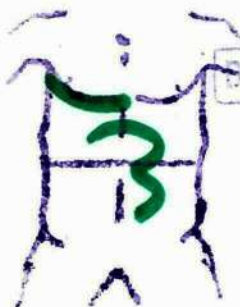
Mr. Chintu Ram

Date - 15/12/2020

B.P. - 130/80

Wt - 66 kg.

15 DEC 2020



DOMINANT PROBLEMS

Frequency stool
CRAMP
EVAR

REGUL
MOR. EVE. NIGHT



NO
POH'S
SPINE } Recent

Features of
IBS

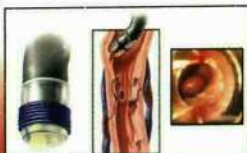Recd Ant-18 Mores

Recent of

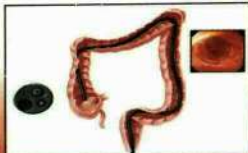
(N)

to water

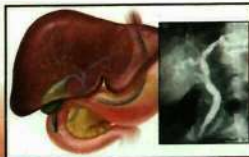for colonic patho



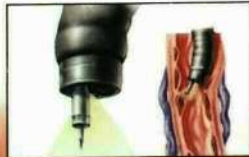
Band Ligation



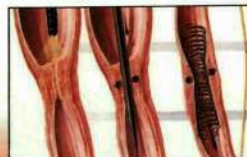Colonoscopy



ERCP



Sclerotherapy



Metal Stent

Challenging Your Imagination

15 DEC 2020

NOUFGOLG
NOGOLA
NO credible found

Acto
✓ Tab Gologmax OXIO
✓ Cap D3 L-30
✓ Tab Fouk100
✓ Cap Digestal OXIO

(21)

Tab Re foxilal 400
OIOIO
(7)

15/12/20

7/NOV/20



CONDUIT

Bot-UC. Gologal

Bot-af gastroalmon

Jafal xelkadow