

Dr.N.C. Krishnamani

Department : CARDIOLOGY

Doctor Reg No. : 10172

OPD Timings :

Patient Name :	Mr. Pawan Kumar Gupta	UHID : 11120413
Father/Husband Name :	Lt M N Gupta	Old UHID :
Address :	A 12 2ND FLOOR PHASE 1 NEAR POST OFFICE ASHOK VIHAR NEW DELHI ASHOK VIHAR	Date : 29-Aug-2023 10:22 AM
Age : 59 YEAR(S)	Sex : Male	

Hb-11.7
Ca-0.85
UA 4.0

Nat-141
Kf-5.4
2.56

BP-100/60
↓
110/90 ✓

Δ P/O CABG. (medicity) Aneurysm of
Aortic Spine.
ECG. ECG. T. Aedbede.
EF 35% → 35%
wafel clot
No postural hypotension

cup & LVC 3T.
ly 5.

Remember +.
4 months

1/2-1/2
1/2 BD
1/2 1/2-1/2
1/2 BD
OD AN
T. Dyts (5)
Kozand-A (10/7) OD
TAD (2/11) 2 OD

IAND Cep Beamble OD AN

Name	: Mr. PAWAN KUMAR GUPTA	UHID	: OPD-11120413
Age/Sex	: 59 Years/male	Lab No.	: 8561
Referring Physician:	Dr. N C KRISHNAMANI	Date	: 28/08/2023

TRANSTHORACIC ECHO-DOPPLER REPORT

2-D/ M-Mode Measurements (mm):

	Observed Values	Normal Values
Aortic root diameter	33	20-36 (mm/M ²)
Left Atrium size	34	19-40

	End Diastole	End Systole	Normal Values
Interventricular Septum	08	10	(ED= 6-12)
Left Ventricle Size	47	42	(ED= 37-56; ES=22-40)
Posterior Wall Thickness	09	12	(ED= 5-10)
LV Ejection Fraction (%)	35 %		55%-80%

Doppler Study-

Valve	Peak valve (cm/sec)	Maximum PG (mmHg)	Mean PG (mmHg)	Regurgitation
Mitral	E=91 A=81	-	-	Nil
Aortic	96	04	-	Mild
Tricuspid	N	N	N	Trace
Pulmonary	N	N	N	Nil



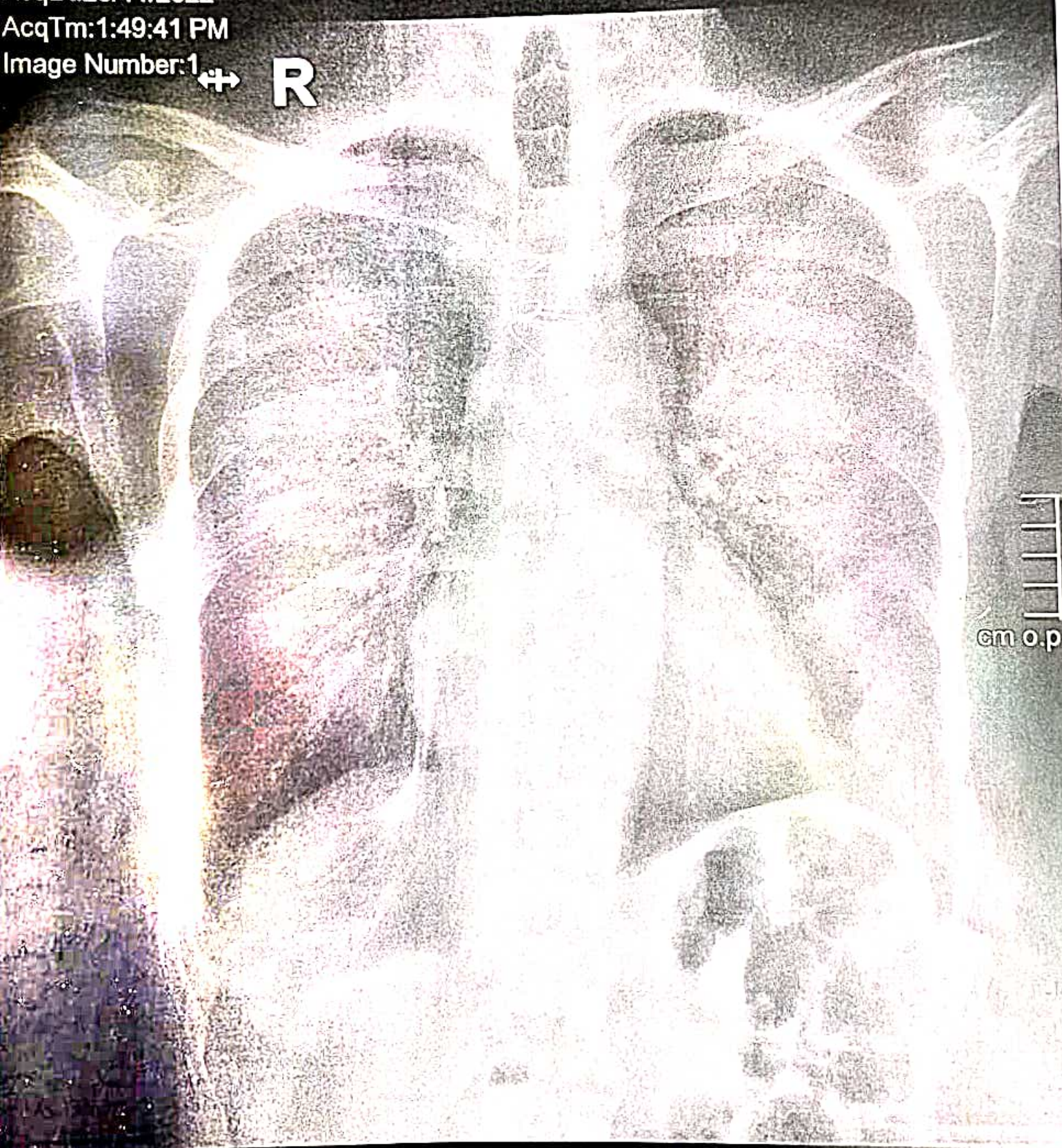
FORTIS HEALTHCARE LIMITED

Regd. Office: Fortis Hospital, Sector-62, Phase VIII, Mohali - 160062, Punjab
Tel: +91 11 2682 5000, Fax: +91 11 4162 8435 CIN: L85110DL1996PLC076704

Name: PAWAN KUMAR GUPTA
ID:MM01711758
DoB:25/11/1964
AcqDt:25/11/2022
AcqTm:1:49:41 PM
Image Number:1

Institution Name: MEDANTA THE MEDICITY
Manufacturer's Model Name: Fluorospot Compact FD

↔ R



cm o.p

MarkOnFilm:

W : 48656
C : 24848

