


Proforma-I

Inter district transfer of Judicial Officer

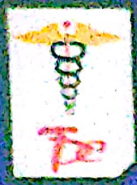Remarks/assessment of Chief Medical Officer/Chief Medical Superintendent
along with verified/countersigned papers

I, Dr. Vishram Singh CMO/GMS
..... have perused the documents presented before me
by Sri **VIVEK KUMAR SINGH-I** (ID No **UP2083** Designation **A.C.J.M.**
(Railway), Bareilly OR on his behalf by Sri
Relation with the officer Phone No. 9450003766

- I have personally examined Sri/Smt./Sushri. Sutali Bhuvan
..... who is suffering from the disease/syndrome/disability
Gastrotomy DMZ [Name of the disease] With 21 wks Pregnancy
and in my opinion he/she may require frequent hospitalization for
treatment/management.
- I also verify that Sri/Smt./Sushri. Sutali Bhuvan is
suffering from the disease/syndrome/disability/disorder NA
[Name of the disease] None and this disease is mentioned at
paragraph no. None of the Annexure-I enclosed herewith.
- In my professional opinion and assessment, I am convinced that the
treatment/management of the above-mentioned disease/syndrome/
disability/disorder in paragraph two above is possible ONLY at the
districts mentioned by the officer in his/her application submitted to
Hon'ble High Court.
- The treatment / management of the above-mentioned disease/
syndrome/ disability/disorder in paragraph two above is also available
at the districts namely..... NA
- I am aware that this document may be presented by the competent
authority/applicant for further use by a competent Medical Board.
- This document shall be valid only for ... 6 (Six) months only.


Signature with seal 20/12/24
Chief Medical Officer (C.M.O./C.M.S.)
Bareilly
Name: DR VISHRAM SINGH
ID No.:
Designation: CMO Bly
Telephone No.
Mobile No. 9958665501

1. Concerned District Judges/Officers in equivalent rank to get these
matter expedited from the office of CMO/CMS
2. The CMO/CMS are requested to retain the copy of this documents and
documents placed before them for issuance of this document for future
reference



20-Nov-23

Name : Stuti
Sex : Female
Ref. By : Dr.

SONOGRAPHY OF LOWER ABDOMEN

Urinary bladder is partially distended. Wall thickness is normal.

Uterus is anteverted and normal in, size, shape & echotexture. Myometrial echoes are homogenous. .

Cervix appears thin and regular

Well defined gestational sac of approx 5mm diameter without foetal pole or yolk sac seen in upper cavity

Both the ovaries are normal in size , shape and pattern. No obvious mass or cyst

There is no free fluid seen in peritoneal cavity

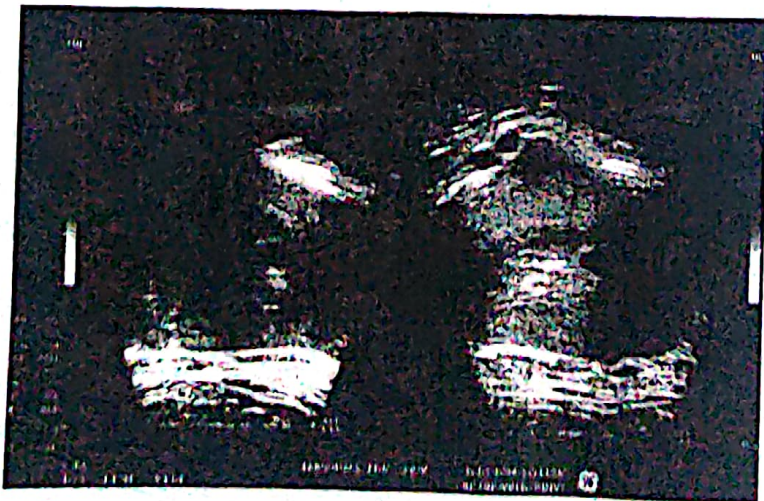
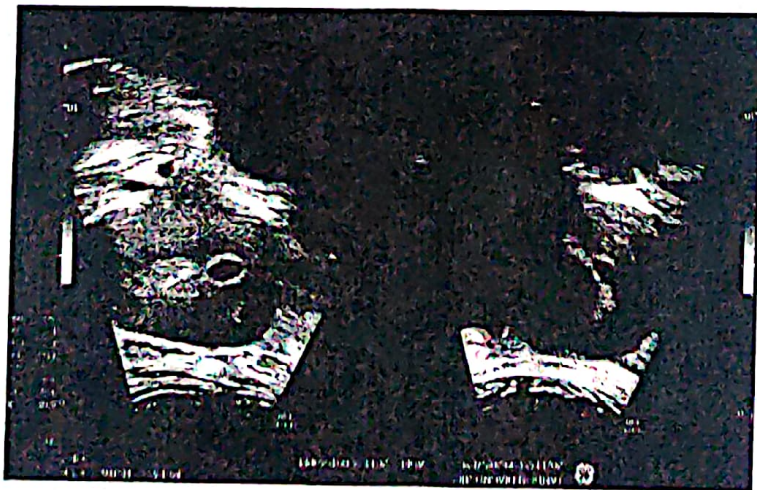
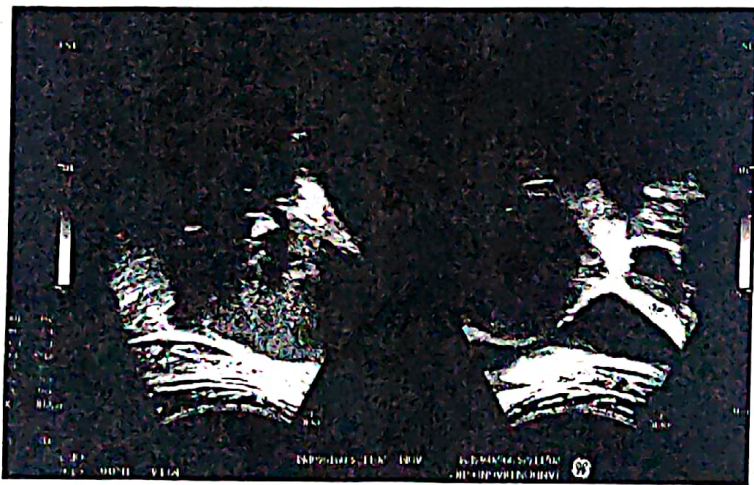
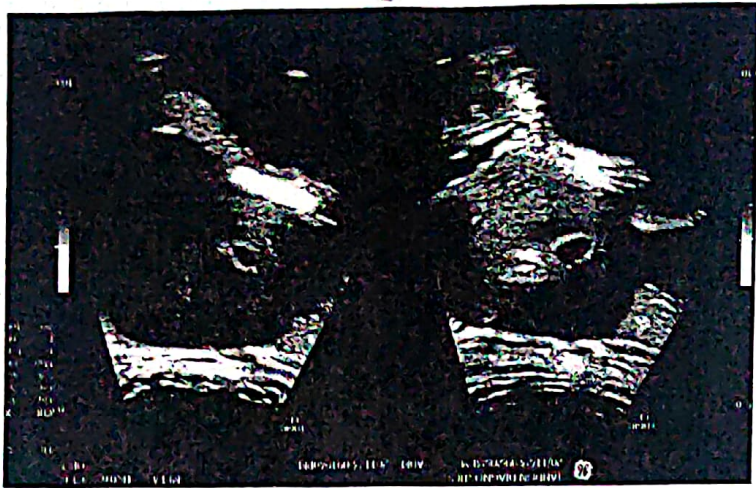
→ **IMPRESSION:-** EARLY INTRAUTERINE GESTATIONAL SAC OF APPROX 5 WEEKS

PLEASE CORRELATE CLINICALLY.

Dr. Rashi Tandon

CG
14/11/24
14/11/24

Dr. Sumit Tandon
M.D. (Radiodiagnosis)
Reg. No.: MP 793/97





SHRI GANGA CHARAN
ARYAWARDHAN HOSPITAL
 A UNIT OF SHRI GANGA CHARAN HOSPITAL PVT. LTD.

A-2, Rampur Garden, Bareilly - 243001
 +91-9675223333, 8171923333
 www.aryawardhanhospital.com
 contact@aryawardhanhospital.com

DR. STUTI

Age - 36 yrs

18/12/23

wt - 74.8 kg

BP - 120/20 mmHg

Gesth @ 10 weeks of preg @ fnANC

M/A - dmp - 02/10/23

O/H Gesth (SI - 3) ~~at~~ hcu
 H₂O GDM in postpreg

daⁿ

- UDE, BG
- HIV
- HBsAg
- HCV
- VDRL
- BSGA(R)
- VKP_M
- SOTSH ✓
- HBsAg

Adv:-

- Tab Macfolate OD - 15 days
- Tab Doxinate 2 tabs 75 15 days
- Tab Dydrover (10) OD 15 days

CS

unh
 अंतर
 18/12/23

Dr. Vidya Rani

D.M.C. No:- 50000

M.S. Gynae

Shri Ganga Charan Aryawardhan Hospital
 Bareilly



SARKAR DIAGNOSTICS

The Lowest Radiation Diagnostic Centre



2001-2008 Certified Organisation
B-307, SECTOR-B, MAHANAGAR, LUCKNOW-226006

Founder

Dr. Sabya Sachi Sarkar, MD
Johns Hopkins & Duke Medical, USA
PADMA SHRI (2016)

Date	10/12/2023	Patient Id	102376347	Age	36 Yrs	Sex	Female
Name	Dr. STUTI BHUVAN	Collected		Authenticated	10/12/2023 13:51:55		
Ref Dr	Dr. CHAVI SHUKLA						

USG PREGNANCY

ULTRASONOGRAPHY REPORT

OBSTETRIC ULTRASOUND

LMP : 02/10/2023
G.Age: 9 wks 6 d

Uterus is enlarged antevetved with an intrauterine live fetus.

Fetal heart rate is 173 /min, regular.

C R Length of the fetus corresponds to 7 weeks 6 days.

Decidual echoes are normal.

Myometrial echoes are normal. No myometrial mass lesion is seen.

Cervical canal is not dilated. Cervical length is 3.8 cms

OPINION:-

SINGLE LIVE FETUS CORRESPONDING TO 7 WEEKS 6 DAYS ± 1 WEEKS OF GESTATION.

I, Dr Sabya Sachi Sarkar declare that while conducting ultrasonography on Dr Stuti Bhuvan, I have neither detected nor disclosed the sex of her fetus to anybody in any manner.
PCPNDT NO PNDT/APP-AUTH/52/2002 Valid upto 16.01.2027.

*** End of Report ***

Dr Sabya Sachi Sarkar MBBS MD D Litt [H]
* Johns Hopkins & Duke Medical, USA
* VISUS, Vienna, Austria

Largest Stand alone Diagnostic Centre

IN CASE OF ANY DISCREPANCY, KINDLY GET YOUR TEST REPEATED

VENTURE OF SARKAR MEDICAL DIAGNOSTIC CENTRE PVT. LTD.

- MRI • PET-CT • GAMMA CAMERA • WHOLE BODY CT SCAN • WHOLE BODY ULTRASOUND • HIGH RESOLUTION ULTRASOUND • EEG • MAMMOGRAPHY
- PFT • BMD • TRANSVAGINAL / TRANSRECTAL & SOFT TISSUE ULTRASOUND • ENDOSCOPY (Upper & Lower G.I.) • BRONCHOSCOPY • TMT & ECG
- FETAL COLOUR DOPPLER • 2D ECHO WITH COLOUR DOPPLER & TISSUE HARMONIC IMAGING • CARDIAC ASSESSMENT WITH SPECKLE TRACKING IMAGING
- PERIPHERAL VASCULAR WITH PW & CW PROBES • 12 CHANNEL DIGITAL HOLTER • 24 Hrs. AMBULATORY BP MONITORING • IMAGE INTENSIFIER (IITV)
- MOTORIZED DOUBLE TUBE 500 & 300 mA X-RAY • FULL DIGITAL X-RAY • COMPUTERISED PATHOLOGY

TIMING : 9 a.m. To 8 p.m.

SUNDAY : 9 a.m. To 4 p.m.

AMBULANCE AVAILABLE

PATIENT NAME : STUTI

REF. DOCTOR : DR. VIDYA RANI

CODE/NAME & ADDRESS : C000021102

A+ DIAGNOSTIC & HEALTHCARE CEN .
112,CIVIL LINES, NEAR PRABHA TALKIES,BAREILLY
BAREILLY 243001
0581-2510777 581-2510778

ACCESSION NO : 0055XB002046

PATIENT ID : STUTF13028855

CLIENT PATIENT ID: RO-273049

ABHA NO :

AGE/SEX :36 Years Female

DRAWN :

RECEIVED :13/02/2024 11:29:51

REPORTED :13/02/2024 12:51:42

Test Report Status	Final	Results	Biological Reference Interval	Units
--------------------	-------	---------	-------------------------------	-------

BIOCHEMISTRY

GLUCOSE FASTING,FLUORIDE PLASMA

FBS (FASTING BLOOD SUGAR)	172 High	Normal : < 100 Pre-diabetes: 100-125 Diabetes: >/=126	mg/dL
---------------------------	----------	---	-------

METHOD : SPECTROPHOTOMETRY

Interpretation(s)

GLUCOSE FASTING,FLUORIDE PLASMA-TEST DESCRIPTION

Normally, the glucose concentration in extracellular fluid is closely regulated so that a source of energy is readily available to tissues and so that no glucose is excreted in the urine.

Increased in: Diabetes mellitus, Cushing's syndrome (10 - 15%), chronic pancreatitis (30%). Drugs: corticosteroids, phenytoin, estrogen, thiazides.

Decreased in : Pancreatic islet cell disease with increased insulin, insulinoma, adrenocortical insufficiency, hypopituitarism, diffuse liver disease, malignancy (adrenocortical, stomach, fibrosarcoma), infant of a diabetic mother, enzyme deficiency diseases (e.g. galactosemia), Drugs- insulin, ethanol, propranolol, sulfonylureas, tolbutamide, and other oral hypoglycemic agents.

NOTE: While random serum glucose levels correlate with home glucose monitoring results (weekly mean capillary glucose values), there is wide fluctuation within individuals. Thus, glycosylated hemoglobin (HbA1c) levels are favored to monitor glycemic control.

High fasting glucose level in comparison to post prandial glucose level may be seen due to effect of Oral Hypoglycaemics & Insulin treatment, Renal Glycosuria, Glycaemic index & response to food consumed, Alimentary Hypoglycemia, Increased Insulin response & sensitivity etc.

****End Of Report****

Please visit www.agludiagnosics.com for related Test Information for this accession

CS
Somya
14/2/24

Dr.Somya Agarwal
Consultant Pathologist




View Details

View Report

PERFORMED AT :

Agilus Diagnostics Ltd.
M/S A+ Diagnostic & Health Services, 112 Civil Lines,
Bareilly, 243001
Uttar Pradesh, India
Tel : 0581 - 2510777, 78, Fax :
CIN - U74899PB1995PLC045956



Patient Ref. No. 77500005409444



SHRI GANGA CHARAN
ARYAWARDHAN HOSPITAL
 A UNIT OF SHRI GANGACHARAN HOSPITAL PVT. LTD.

A-2, Rampur Garden, Bareilly - 243001
 +91-9675223333, 8171923333
 www.aryawardhanhospital.com
 contact@aryawardhanhospital.com

Dr. Stuti

Age 36 yrs

13/02/24

Gab. H. a 19th Wks preg &
 Present for Amn

~~REG.~~

GDM

(Gestational Diabetes Mellitus)

Adm:

sig +e 0-500 um stat -

sig Lab Pan 4000 -

Dr. Sagarin D. 2 x stat
 / Dr. Indranil 2 x stat

physician ofermi for
 High Surgen

For Metformin 500mg
 BD - 15 days

CS
 16/2/24

Dr. Vidya Nani
 D.M.C. No: 58600
 M.S. Gynae
 Shri Ganga Charan Aryawardhan Hospital
 Bareilly.

• Street Diet control / Dietetic Diet -

• Kendal Scan

(Anomaly scan)

• Tab Prosofs 01)

• Tab Calamoxon)

↑
leaf

]- 150

• Maelprol protein powder
& milk

Dr. Vidya Rani

D.M.C. No:- 58600

M.S. Gynae

Shri Ganga Charan Aryawardhan Hospital
Bareilly