

PROFORMA-I

Remarks/assessment of Chief Medical Officer/Chief Medical Superintendent along with verified/countersigned papers.

I, Dr. Kuldeep Narayan Choudhary, Chief Medical Superintendent, District Woman Hospital, Ghazipur have perused the documents presented before me by Smt Shweta Nain, ID No.-UP3557, Designation-Additional Civil Judge (J.D.) and place of posting Ghazipur.

I. Dr. Monica Singh (S.R.), gynaecologist at this hospital have personally examined Smt Shweta Nain who is suffering from the disease/syndrome/disability **Grade IV Endometriosis (operated) and Infertility** and in my opinion She may require frequent hospitalization for treatment/management.


II. I also verify that Smt Shweta Nain is suffering from the disease/syndrome/disability/disorder **Grade IV Endometriosis (operated) and Infertility** and the disease(s) does not find(s) mention in Annexure-1 enclosed herewith.

III. In my professional opinion and assessment, I am convinced that the treatment/management of the above-mentioned disease/syndrome/disability/disorder in paragraph two above is possible at the district mentioned by the officer in his application submitted to Hon'ble High Court.

IV. The treatment/management of the above-mentioned disease/syndrome/disability/disorder in paragraph two above is available at the district namely not applicable.

V. I am aware that this document may be presented by the competent authority/applicant for further use by a competent Medical Board.

VI. This document shall be valid only for 1 Months only.


24/2/2024

Signature with seal

Name-Dr. K. N. Choudhary

Designation-Chief Medical Superintendent
District Woman Hospital, Ghazipur.

Mobile No.-9452685785



महिला एवं शिशु चिकित्सालय, गाजीपुर

सम्बद्ध-महर्षि विश्वामित्र स्वशासी राज्य चिकित्सा महाविद्यालय, गाजीपुर

वाह्य रोगी टिकट

(केवल पन्द्रह दिन के लिए मान्य)



158

पंजीकरण संख्या... 158
 रोगी का नाम... स्वप्ना नैन
 पिता/पति का नाम... रमेश चंद्र कुमार
 पता... गाजीपुर
 रोग निदान... डाक्टर का नाम...

दिनांक... 20-2-24

आयु... 29... लिंग...

आबादी का बढ़ता बोझ, साधन घटते जाते रोज

परिवार नियोजन के तरीके	उपचार
<input type="checkbox"/> मिश्रित गर्भनिरोधक गोलियाँ <input type="checkbox"/> गर्भनिरोधक इंजेक्शन <input type="checkbox"/> कंडोम <input type="checkbox"/> आईयूसीडी (कॉपर टी) <input type="checkbox"/> प्रसव के तुरंत बाद आईयूसीडी <input type="checkbox"/> महिला नसबन्दी <input type="checkbox"/> पुरुष नसबन्दी <input type="checkbox"/> लैम (स्तनपान से गर्भनिरोध) दिनांक.....	Pot+ MC: 2 years LMP: 29 Jan 23 M/H: 5d/28-30d/ A/R. O/E BP: 110/70 mmHg PR: 86/min Paller } -nt Fetuss } Edema } PA: tenderness present in lower abdomen PIV: ut A/V, restricted mobility, tenderness at cervix tenderness at on mobility

K/c/o Grade IV Endometriosis.
 Operated in 28/1/2023.
 want usive treatment.
 H/o infertility

Adv
 As patient is K/c/o Grade IV Endometriosis & infertility as per reports.
 Patient will be requiring further treatment & frequent hospitalisation for further management mainly

गर्भनिरोधक - लड़की का पालन और काबज

संयम से रहें, एड्स से बचें

368/15-02-2024

प्रेषक,

मुख्य चिकित्साधिकारी,
गाजीपुर ।

सेवा में,

श्रीमान जनपद न्यायाधीश
गाजीपुर ।

पत्रांक मु0चि0अ0/एम-1/2023-24/5720

दिनांक 15 फरवरी, 2024

विषय :- श्रीमती श्वेता नैन, अपर सिविल जज, (जू0डि0) के मेडिकल दस्तावेजों के सम्बन्ध में ।

उपरोक्त विषयक आपके अग्रसारण सं0-37/xv दिनांक 14.02.2024 के क्रम में श्रीमती श्वेता नैन, अपर सिविल जज, (जू0डि0) न्यायिक मजिस्ट्रेट, कक्ष सं0-06 गाजीपुर के चिकित्सीय प्रपत्रों को प्रतिहस्ताक्षरित करने के निर्देश के क्रम में डिस्ट्रिक्ट जज समरी प्रतिहस्ताक्षरित कर इस पत्र के साथ पत्रावली मूलरूप में संलग्न कर वापस की जा रही है ।
संलग्नक-उपरोक्तानुसार ।

भवदीय
मुख्य चिकित्साधिकारी,
गाजीपुर



DISCHARGE SUMMARY

Type of Discharge: LAMA/DOR Normal Discharge MLC/Non-MLC
 Patient Name: MRS. SHWETA NAIN UHID No.: 44729 Age/Sex: 28y/f
 IP No.: 2310144 DOA: 16/1/23 DOD: 19/1/23 Time of Discharge: 11A Ward: Gyneco
 Address: MUZAFFARNAGAR

Diagnosis: Endometriotic cyst Consultant: DR-Nutan Jain

History of patient illness: Patient come to the hospital e clo lower abdomen pain

Examination/ findings: G.C patient Conscious and oriented

BP 120/70 puls 74/- SpO2 98/- Temp 97.4°

प्रतिष्ठान अधिकारी
मुख्य निदानाधिकारी
राजीव

Course in Hospital (Including treatment given): PAGILAC powder / STAT Tab T-F 0.5ml stat
INJ AMIKACIN 1gm once in a day TAB PXRIDIUM 400mg thrice
in a day TAB SECNI FORTE 2gm once in a day TAB ACTILOX 150mg thrice
in a day TAB ALPRAX 0.5mg once in a day TAB PERINORM 10mg once in a
day INJ ORNIDA 100ml twice in a day INJ AMIKACIN 1gm once in a
day INJ ZOCIF 1.5gm thrice in a day INJ PANTOP 40mg thrice thrice
a day INJ PERINORM 10mg thrice in a day Tab PXRIDAR 75 thrice in a d
INJ DEXONA 8mg thrice in a day INJ PHENERGEM 50mg thrice in
a day

Investigation Results:

- Laboratory Investigation: NA
- Imaging Investigation: NA
- Others: NA

Procedure (if any): Video laparoscopy hysteroscopy done on 17/1/23

Patient Condition at discharge: stable

Advice on Discharge: INJ PLACENTREX 1 amp once in a day TIm X 10 days
INJ AMIKACIN ^{500mg} 2 VIAL once in a day X 7 days
TAB-ZOCEF 250 twice in a day
TAB- GN 15 twice in a day
TAB PANTOP 40 mg twice in a day
TAB PHENERGAN 10mg HS
TAB DEVRVY 10mg twice in a day X 11 days
start from (27 JAN/23)

Followup Advice: To Come on 28th JAN FOR S/R

When to obtain Urgent care: IF heavy bleeding per vaginal lower abdomen
Pain Nausea Vomiting

Emergency Contact No.: (.....8919162397.....)

Room Clearance [Signature]
Name & Signature of Doctor: DR-Nutan Jain
Date & Time: 19/1/23 11 AM

WARDHIMAN TRAUMA & LAPAROSCOPY CENTRE PVT. LTD.

ANNEXURE A1/2

Dr. NUTAN JAIN

Dr. VANDANA JAIN

13/28/11/2023
9:15

Name: Mrs. Bhawla Nain Age: 28 yrs ML: 1 yr Status: P+0
Weight: 44 kg Height: 5"6 LMP: 11.1.23 Place: (Local)

ICG used: 1688 camera system

Diagnosis: Grade IV endometriosis Treatment: VLH done on 17.1.23

- Both sides Endo cyst noted
- POD obliterated, DIE
- B/L Parametrial tubes
- (N) Uterine cavity.

Op: Placecortone 1 amp 100
00 X (10)

Op: mifacino 2 vial 1ml iv
(500) 00 X 7 days

Operative Findings:

- On inserting the scope at Jain point
- Uterus is densely RU, fixed in POD. POD obliterated.
- B/L tubes and ovaries densely adherent to ovarian fossa
- UTS ligament, back surface of uterus and Rectosigmoid.
- Both sides endometriotic cyst noted. DIE noted
- Rectum adherent. Very careful all adhesiolysis done.
- ICG used in both ureters.
- Complete rectal mobilization done.
- RU space fully cleared. RU node excised & removed.
- B/L Ureter dissection done.
- Both endometriotic cyst drained and excised.
- B/L tubes, ovaries totally freed and space noted.
- Hysteroscopy: shows (N) size uterine cavity.
- B/L ostia loose (N)

T. ZOCOF 1 — |
(250)

T. SN 15 1 — |

T. Paracetamol 1 — |
(40)

T. Phenergan (10) — |HS

T. Dewiry 1 — | X 11
(10) days

(start from 27.1.23)

Inform SOS

To come on 28th Jan.

(FORM S/R)

~~17.1.23~~

28/1/23

BP: 110/70

wt: 45kg

Stroke removed healthy

Adv
Neosporin
Powder

T. Desc 2-2-2-2
(0.5mg)
" 1-1-1-1
" 1-1-1
" 1-1
" 1-daily x 30 days.

To come on
1/2 of

HSA = 29.12.22

HPE

Endometriosis



Rt Endometrial cyst lining

60 million HSO - done
40% motile
Gr. III

exercise / full activity
- UST from next cycle

1/2 give UST

Any special orders

- TSY conception from next cycle.

by upende layu
13 Feb 3.75 pm

AKT: NA

Stent NO

stents

1st OT R2 EC, OIE, RV, Gr. IV Endomy
v12 patient. ity150-25.

1st case Page 02 of 04

Dr. N

Client
Vardhman Hospital
Pathkind Diagnostic Pvt. Ltd.
Vardhaman Hospital, Jansath Road,

Processed By
Pathkind Diagnostics Pvt. Ltd.
Plot No. 55-56, Udhayog Vihar Ph-IV, Gurugram - 122015

Name	: Mrs. SHWETA	Billing Date	: 17/01/2023 15:21:58
Age	: 28 Yrs	Sample Collected on	: 17/01/2023 15:21:58
Sex	: Female	Sample Received on	: 18/01/2023 12:45:11
P. ID No.	: P1110300006711	Report Released on	: 21/01/2023 08:11:43
Accession No	: 111022024992	Barcode No.	: 995366761
Referring Doctor	: DR.NUTAN JAIN	Ref no.	:
Referred By	:		

Report Status - Final

HISTOPATHOLOGY

Histopathology: Medium Tissue Biopsy

Sample: Tissue

Lab No: HA-2366-23

Nature of specimen: Biopsy from Endometriotic cyst

Clinical Details: USG: Right endometriotic cyst.

Gross Description:

Received single cystic cyst measuring 3.5 x 1.5 x 0.3 cm.

Block:1

Entire tissue is submitted in one block.

Microscopic Examination:

Sections show ovarian tissue with foci of endometrial tissue showing irregular and dilated glands lined by simple columnar epithelium. Stroma is compact with a moderate diffuse infiltrate of lymphocytes and some plasma cells. The surrounding tissue show discrete foci of chronic inflammation. No atypia is seen.

Impression: Consistent with Endometriosis.

Note- Slides, report and paraffin blocks will be kept for 10 years. Please contact customer care in case of any queries.
Report entered by: Lalit

** End of Report**



Dr Smita Kumari
Consultant Histopathologist
DMC No. 44237




111022024992 Mrs SHWETA



Dr. Nutan Jain

M.B.B.S., M.S., F.I.C.O.G., F.I.C.M.C.H.
ADVANCE LAPAROSCOPIC SURGEON



vardhman hospital

64729
Dr. Vandana Jain

M.B.B.S., M.S., PGDS
IVF / INFERTILITY SPECIALIST
ADVANCED LAPAROSCOPIC SURGEON

ANNEXURE A/15

3.3.23

Name: Mrs. Sharda New City: hood Husband: G.S.

D.O.B.:

Age: 23 years

ML: 14/23

Parity: P0-P0, 12/23 (molar 4-5 days)

LMP: 2/3/23
↓ secondary bleed (pale w/)

Day:

Chief Complaints:

Bp 103/59
wt 45 kg

Gonorrhea
4 capsules
11/5

Investigation:

9 VS
3rd phase

VILH done on 17/1/23

Grade IV Endometrosis
Both sides Endomet.

Bi patent tube

(N) uterine cavity

1 PC Consist with Endometrosis

1st Lapro (3 7.5 mg D)
13/2/23

TAB. FOLVITE 1-1

TAB. EBEXO 1-1

TAB. DISPIRIN 1/2

E+P

14/3/23

refuse

11/2

USG:

TAB. PROGNOSIS 2mg

↓
G nival dat 1/2

3/3/23

TAB. DEXAMETHASONE 1-1

↓
18 mure dat 1/2

Dr. Nutan Jain

M.B.B.S., M.S., F.I.C.O.G., F.I.C.M.C.H.
ADVANCE LAPAROSCOPIC SURGEON

ANNEXURE A-176

Dr. Vandana Jain

M.B.B.S., M.S., PGDS
IVF / INFERTILITY SPECIALIST
ADVANCED LAPAROSCOPIC SURGEON



Vardhman hospital

Name: Mrs. Shweta Nain

City: local

Husband:

9:1

D.O.B.:

Age: 28 yrs

ML: 1yr

Parity: P₀T₀

LMP: 31/3/23

Day: D/2

Chief Complaints:

Wants
conception

TWS-NP

Investigation:

HSA (29/12/22)

C - 60 m/ml

M - 40%

- Rx VLM done on 17/1/23
- G IV endometriosis
 - DIE noted
 - B/L endocyst noted
 - PGD obliterated
 - B/L tubes spill noted
 - (N) uterine cavity

- 1) T. FOLVITE 1-1
- 2) T. EBEXID 1-1
- 3) T. DISPRIN 1/2 daily

⊕ TAB Letroz (2.5mg) 1-1 x 5 days
start on Today
to come on. 10/4/23
TWS free

1/4/23 ~~10/4/23~~

USG:

P/S: C₀ / mild tenderness

✓ PCT 13^{uu} .)

10/04/23

CT - - -

To come on - - -

~~10/4/23~~
~~10/05/23~~

Name: ...

Dr. Nutan Jain

M.B.B.S., M.S., F.I.C.O.G., F.I.C.M.C.H.
ADVANCE LAPAROSCOPIC SURGEON

ANNEXURE A-1/7

13.2.23

0/28 - Repeat TVS

Dr Vandana Jain

M.B.B.S., M.S., PGDS

ADVANCED LAPAROSCOPIC SURGEON

vardhman hospital

Name: Mrs. S. Bawa Main City D/2 - 1st floor

D.O.B.:

Uterus done on 17/1/23

Age: 28 yrs

R

ML: 1 cps

Grade IV endometriosis
Bilateral tubo-ovarian endometriosis
Bilateral patent tubes

Parity: P0+0

Uterine cavity

LMP: 12/1/23
(NOB 1000)

HPE: Consist with endometriosis

Day: 24: 4-5 days / 28-28 day cycle

TAB FOLVITE
|-----|

Chief Complaints: Dysmen +

Dysp. need

TAB EBEXID
|-----|

Gr. B 15 positive

TAB DUSPirin 75
|-----|

Gravidity: 14

Parity: 0
FH: 14

TVS
NPD
this cycle
Plan out

Investigation: HSD 29/12/22

BP 100/70
wt: 45kg
hgt: 56"

Gonorrhea
407mils
L11

X 2-EP

~~Tab Progynon~~

USG:

Start Lupride (3.75mg)

1 Today

To come on 1/2 of period

or Repeat TVS

6 March

Dr. Nutan Jain

M.B.B.S., M.S., F.I.C.O.G., F.I.C.M.C.H.
ADVANCE LAPAROSCOPIC SURGEON



vardhman hospital

City: Local

ANNEXURE AI/8/15

Dr. Vandana Ja

M.B.B.S., M.S., P
IVF / INFERTILITY SPECIAL
ADVANCED LAPAROSCOPIC SURGE

Name: Shweta Nain

D.O.B.: 27/10/94

Age: 28 yr

ML: 1 yr

Parity: PoAo

LMP: 31/3/23

Day: D/19

Chief Complaints:
Warts
Conception

Lmp
28/4/23

TVS free

Investigation:

HSA (29/12/22)
C - 60 mg/ml
M - 40% (III)

USG:

101

TAB
PROBENOCID (2mg)
1 - 2 x 2 days

VLH done on 17/1/23

- R • G^{IV} endometriosis
- DIE noted
- B/L Endocyst noted
- POD obliterated
- B/L tubes spill noted
- (N) uterine cavity

Husband: Gokulraj
1100 km

T. FOLWITE 1-1

T. EBEXID 1-1

T. DISPRIN 1/2 daily

18/4/23

TAB uterovag (400mg) to be
continue x 11 days.

Inv^o HCG (SK) ilm. stat
5 days over due HCG Card Test

TO come on D12 of period

18/4/23

sphere 1-1 x 5 days

(4) - vs free hcg

29/12/23
Mx - ve
PRL -
T4 - 1.64
TSH - 2.0
21/8/23
T3 - 1.0
T4 - 8.2
TSH - 2.0
Hb - 11.0

Dr. Nutan Jain

M.B.B.S., M.S., F.I.C.O.G., F.I.C.M.C.H.
ADVANCE LAPAROSCOPIC SURGEON

40
10-5
96
9/5/23



Vardhman hospital

ANNEXURE A/956

18
8-5-23
Dr. Vandana Jain

M.B.B.S., M.S., PGDS
IVF / INFERTILITY SPECIALIST
ADVANCED LAPAROSCOPIC SURGEON

Name: Shweta Nain

City: Ghazipur

Husband:

9.3h

D.O.B.: 27/10/94

Age: 29 years

ML: 1 year

Parity: P₀ A₀

LMP: 29/4/23

Day: D11

Chief Complaints:

- wants conception
- on follicular monitoring

LMP
28/5/23

Rx VLH done on 17/1/23

A+ve

- grade IV endometriosis
- BIL tubes spill noted
- (N) uterine cavity

USG
4/5/23-

Rx.

T. FOLVITE 1-1

- AFC =

T. EBEXID 1-1

R. side = 10

L. side = 12

tubal spasm L tub daily

INJ - MCG (10K) IM STAT

TO COME ON 9/5/23

705/1000

8/5/23

Investigation:

10/5/23

USG:

at night

TAB - AZEE (1gm) →

TAB - FORCAN (150mg) →

H/W
single
dose

Actu -
CBC, ABO, RH
HIV, HCV, HBsAg,
VDRL, U-R
-ME
BJ-F
-PP, TSH

P-70

Dr. N. Jain
M.B.B.S., M.S., F.I.C.O.G., F.I.C.M.C.H.
ADVANCE LAPAROSCOPIC SURGEON

vardhman hospital

Dr. Vandana Jain
M.B.B.S., M.S., PGDS
IVF / INFERTILITY SPECIALIST
ADVANCED LAPAROSCOPIC SURGEON

Name: Shweta Nain

City: Ghazipur

Husband:

D.O.B.: 27/10/94

Age: 28yrs

ML: 1 1/2 yr

Parity: PoAo

LMP: 28/5/23

Day: D/10

TNS-NP

Chief Complaints:

- Wants Conception
- Pain in Abd. (Lts side) since 2-3 months

- Rx VLH done on 17/1/23
- GIV endometriosis
 - DIE noted
 - B/L endometriotic cysts
 - POD obliterated
 - B/L tubes spill noted
 - (N) uterine cavity

IUI done on 9/5/23

- Took Letroz 0-1 X5 days from D/2
- Taking T. Progynova 2-2 X7 days from 3/6/23

48
6.6.23
9.54
Took AKTX 6 months @ the age of 16-17yr (pulmonary TB)
29/12/22
Mx-ve
PRL-12.46
T4-1.64
TSH-2.120
21/8/22
Hb-11.8

Investigation:
HSA (29/12/22)
C-60 m/ml
M-40% (III)

✓ Ty. Lupredo (1mg) 1m std. 6h
8/10/23
✓ ✓ ✓
G? daily

USG: USG (Pelvis) 29/5/23

- Minimal hypochoic spiculations extending from Rt. lat. wall of uterus adjacent parametrium ? adhesin
- Minimal thickening of adjacent rectum/sigmoid colon ? due to deep pelvic endometriosis

7AB. Susten (oomy)
14/12/23
come on 12/13/23 R.
10/06/23
10/06/23
10/06/23

M.B.B.S. ADVANCE

ANNEXURE A-1/11

FOLLICULAR SONOGRAPHY

DR. NUTAN JAIN M.S.

DR. VANDANA JAIN M.S.

Name/Age: Skweta Nain | 28 yrs Station: Local

Parity: P0 ML: lycs

Cause of Anovulation: _____ Ovulogen: _____ MH: _____

After lap OSCU.

Lap Date :

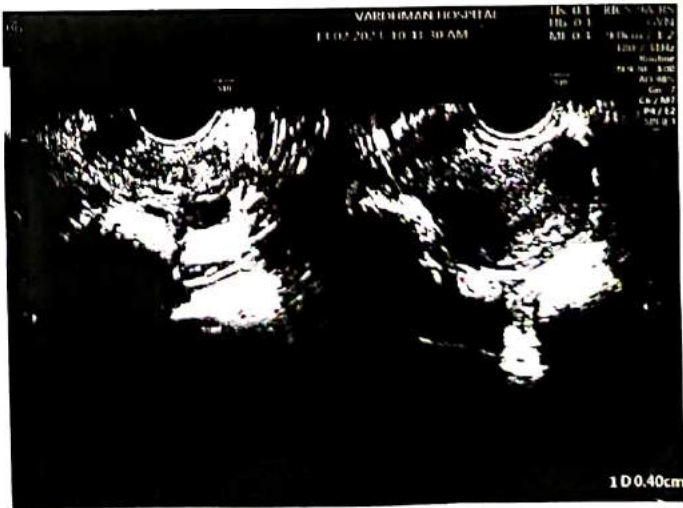
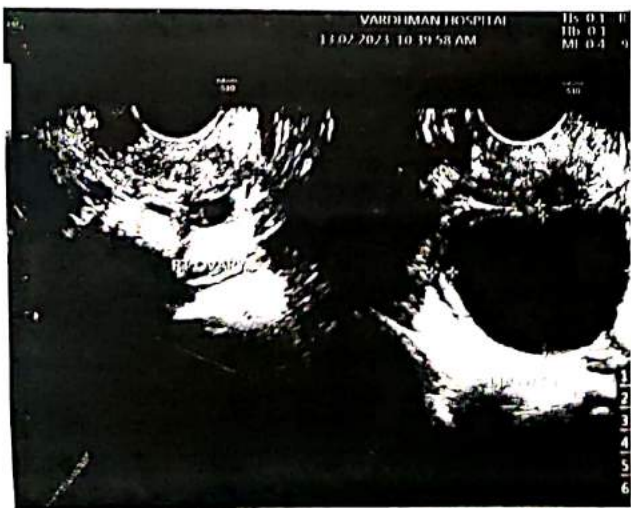
HSA

Count :

Moti. :

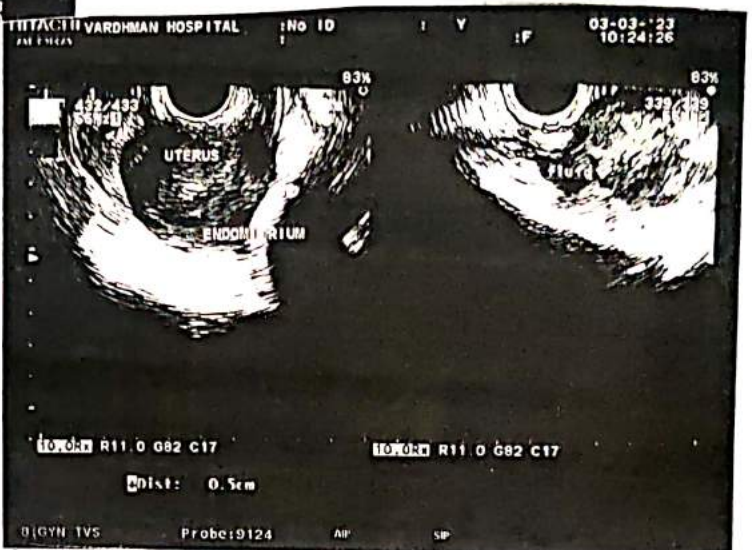
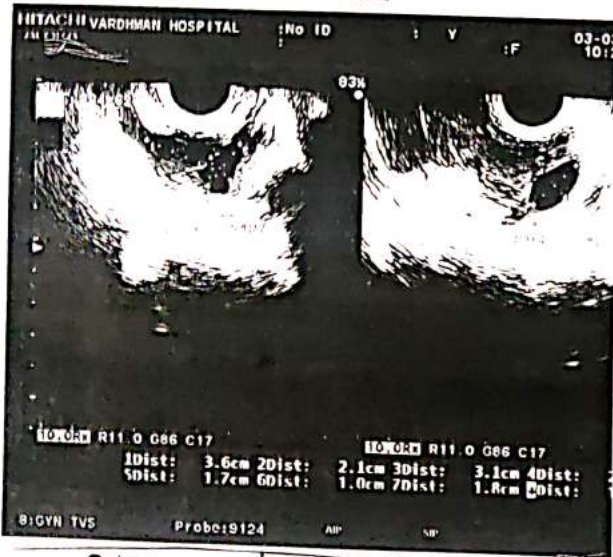
1 Cycle Drug : _____ L.M.P. 12/2/23

Scan	Rt. Ovary	L. Ovary	Endometrium	<input type="checkbox"/> PCT <input type="checkbox"/> Cx Mucus
1. <u>NP</u> <u>13/2/23</u> <u>2/2</u>	<u>(B/L ovaries Seen close)</u> <u>(OS - 46x22)</u>	<u>Seen close)</u> <u>(OS - 58x46)</u>	<u>ut R/v Globular</u> <u>Endo - 4mm</u>	<u>(A Stape)</u>
2.	<u>(5-6 follicle)</u>	<u>cystic follicle</u> <u>(49x41)</u>		
3.	<u>Re-look on Day 20</u> <u>if present go to superide</u> <u>D/2 - see for cystic</u>			
4.				



Cycle Drug :

Scan	Rt. Ovary	L. Ovary	Comments
3/3/23	B/L ovaries	Seen close	Uterus RTV - lobular
0/2	f ₁ - 18x11 (OS - 31x25)	cos - 36x21 (Cystic Collapsed) (7x10) (Mild fluid)	Endo → 5mm (@ Skarpe)



Scan	Rt. Ovary	L. Ovary	Comments
1.			
2.			
3.			
4.			

SONOGRAPHY

DR. NUTAN JAIN M.S.

DR. VANDANA JAIN M.S.

Name/Age: Shweta.

Station: Local.

Parity: P0+0.

ML: 148

Cause of Anovulation:

Ovulogen:

MH:

1+1-1 cycle (D)

Lap Date: grade IV

endometriosis

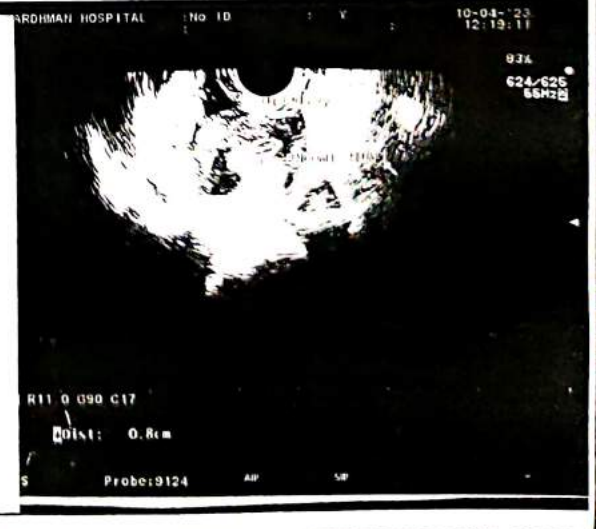
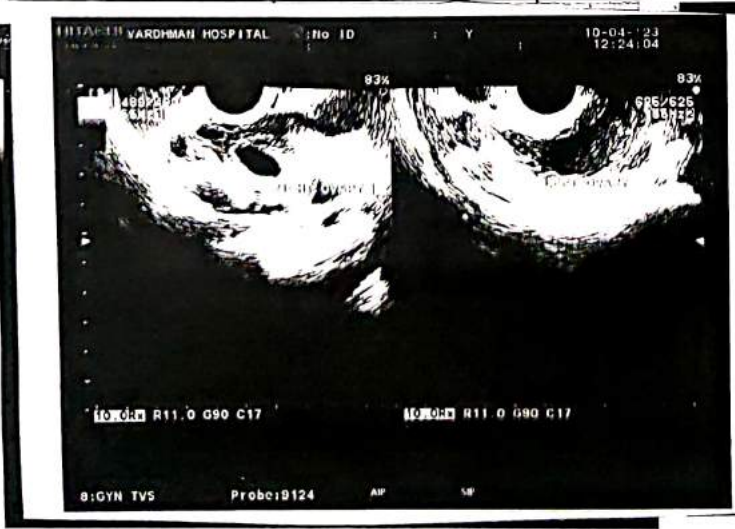
17/1/23 DJE

HSA

Count:

Moti.:

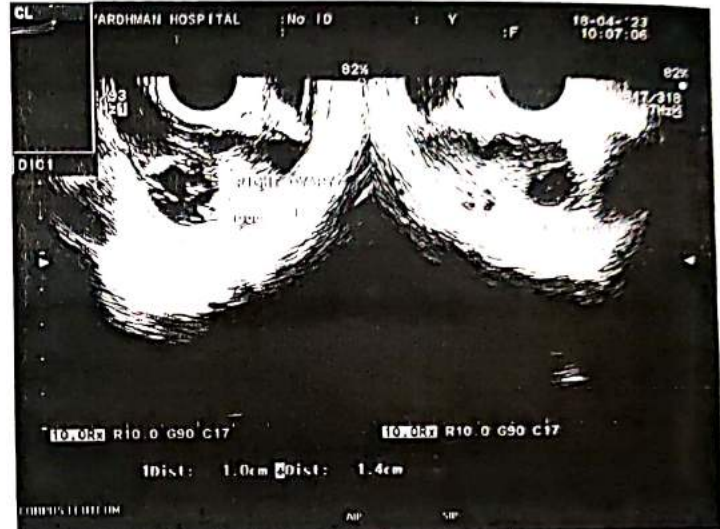
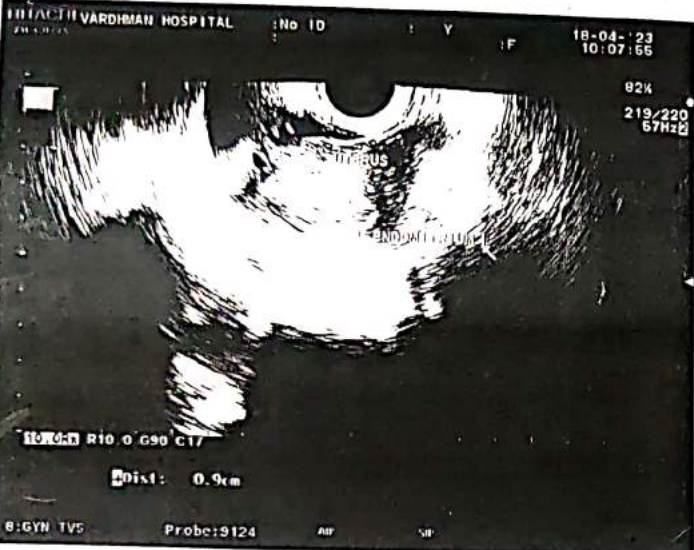1 Cycle	Drug:	L.M.P. 31/8/23		
Scan	Rt. Ovary	L. Ovary	Endometrium	<input type="checkbox"/> PCT Cx Mucus
1. MD 11/4/23 D/2	B/L ovaries seen close (OS-31x15)	Seen close (OS-29x21)	Uterus R/V Endo-5mm.	lobular. O shaped.
2.	4-5 follicle Reg. CL seen.	5-6 follicle.		
3. MD 10/4/23 D/2	B/L ovaries seen F1-17x11	Small F1-11x7	Uterus R/V Endo-8mm	lobular O shaped
4. MD 10/4/23 D/2				



II Cycle Drug :

L.M.P.

Scan	Rt. Ovary	L. Ovary	Endometrium	Comments
1. 13/4/23 D114	B/L ovaries seen		uterus R/v	bilobular (O shaped)
2.	F1- 23x16	F1- 17x8	Endo- 8mm	
3.			Pls- mild tenderness @	
4.			clear mucus. Many motile sperm	



Scan	Rt. Ovary	L. Ovary	Endometrium	Comments
1. 18/4/23 D119	B/L ovaries seen.		uterus R/v	bilobular. O shaped.
2.	good CL seen.	F1- 14x10.	Endo 7.9mm	
3.				
4.				

FOLLICULAR SONOGRAPHY

DR. NUTAN JAIN M.S.

Name/Age: Shweta Nain Station: Local

Parity: P0T0 / 2B4r ML: 1yr

Cause of Anovulation: Ovulogen: MH:

Lap Date : _____

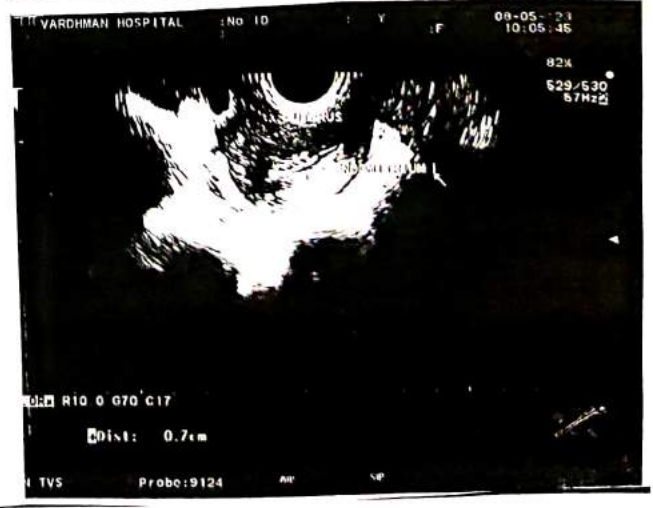
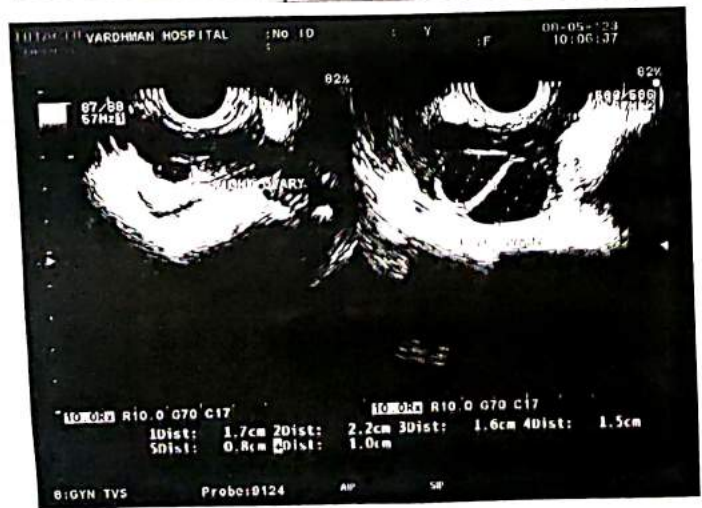
HSA _____

Count : _____

Moti : _____

1 Cycle Drug : CCYOO + HMO L.M.P. 28/4/23

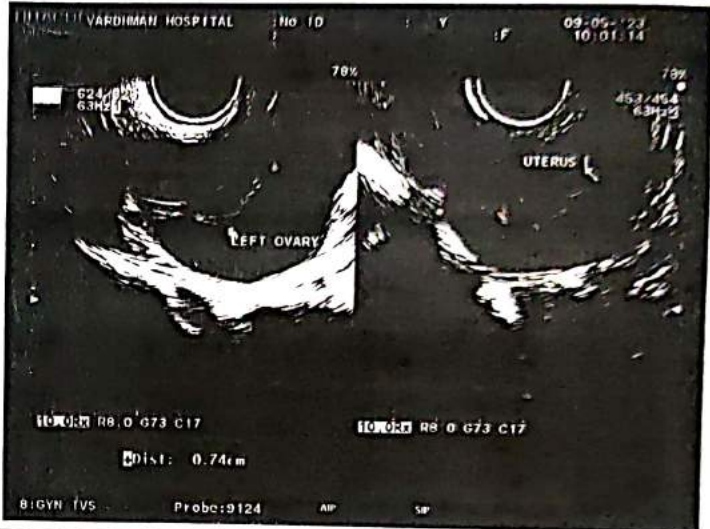
Scan	Rt. Ovary	L. Ovary	Endometrium	[PCT] Cx Mucus
1. MP 29/4/23 D/2	BL ovaries seen. (OS- 37x18)	Seen. (OS- 30x27)	uterus R/v Endo- 5-6mm.	lobulated o shaped.
2.	BL 4-5 follicle.			
3. 8/5/23 D/11	F1- 10x8	F1- 22x17 F2- 16x16 F3- 18x14	uterus R/v Endo- 7mm = 1Pn.	lobulated o shape
4.		F4- 22x11		



Cycle Drug :

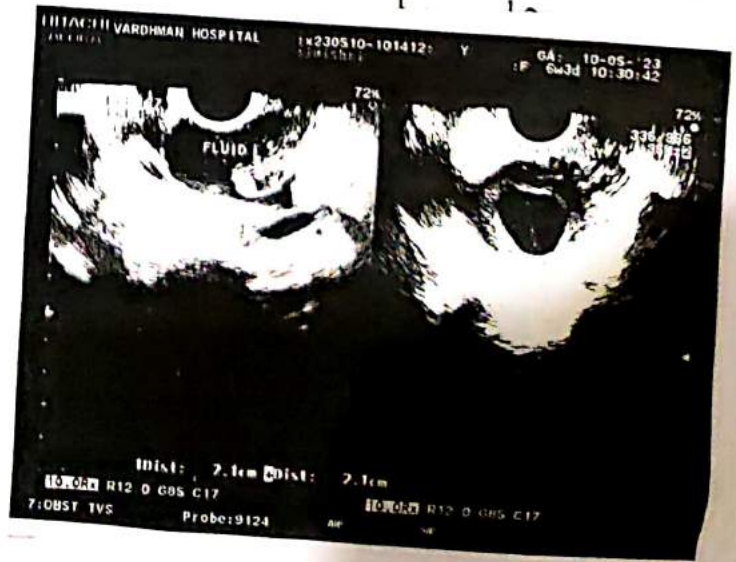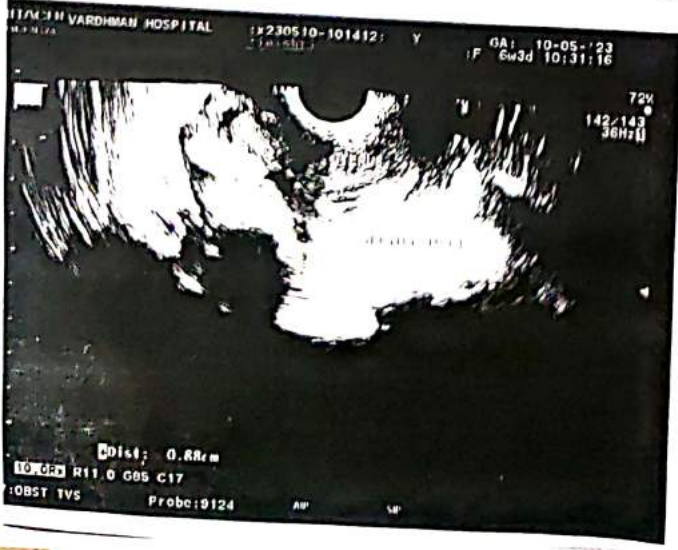L.M.P.

Scan	Rt. Ovary	L. Ovary	Endometrium	Comments
1. 9/5/23	B/L ovaries seen	uterus R/V globular	endo - 7.4mm	@ shape.
2. D/12	F1 - 10x9	F1 - 25x23		
3.		F2 - 22x21		10/1/23
4.		F3 - 20x19		
		F4 - 24x13		



111s Cycle Drug :

Scan	Rt. Ovary	L. Ovary	Endometrium	Comments
1. 10/5/23	B/L Ovaries seen	uterus	Endo - 8.8mm	R/V globular @ shape
2. D/13	F1 12x8	C2 collapsed		
3.		F1 - 21x21		
		F1 even		



VARDHMAN TRAUMA & LAPAROSCOPY CENTRE (P) LTD.
3rd Km., Jansath Road, Muzaffarnagar



FOLLICULAR SONOGRAPHY

DR. NUTAN JAIN.M.S.

DR. VANDANA JAIN M.S.

Lap Date :
HSA
Count :
Moti :

Name/Age : *Sneha Nain*

Station : *Lahazipur.*

Parity : *po-to*

ML : *1/244*

Cause of Anovulation :

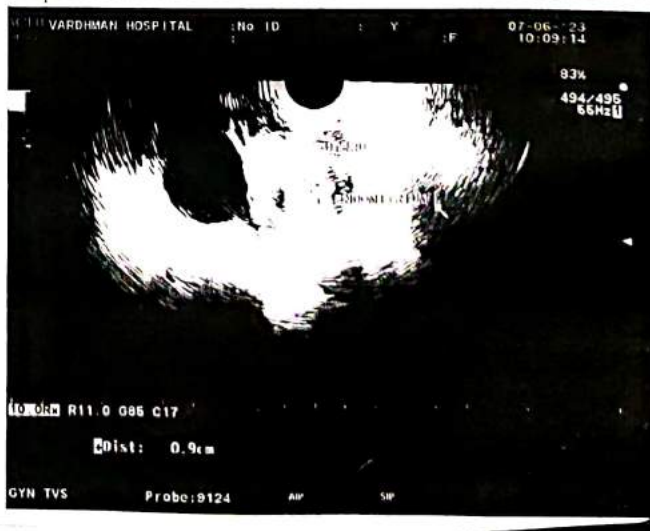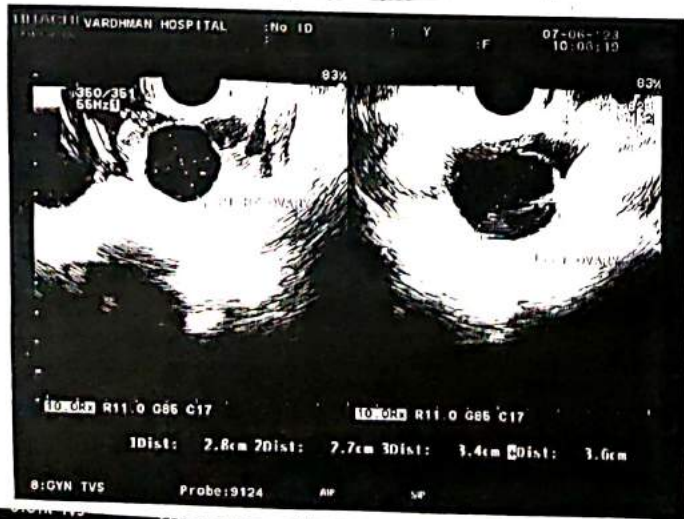
Ovulogen :

MH :

Lt 0-1 cycle (3)

1 Cycle Drug : L.M.P. *28/5/23*

Scan	Rt. Ovary	L. Ovary	Endometrium	PCT	Cx Mucus
<i>MP 6/6/23 D/10</i>	<i>Blk ovaries seen (OS-37x20)</i>	<i>Seen (OS-48x44)</i>	<i>Uterus R/V Endo-8mm</i>		<i>Globular & shaped.</i>
<i>2.</i>	<i>F1-24x24</i>	<i>F1-36x26</i>	<i>≡ lines</i>		<i>NO CT- - -</i>
<i>3. 7/6/23 D/11</i>	<i>Blk ovaries seen F1-27x27</i>	<i>F1-36x34</i>	<i>Uterus R/V Endo-9mm</i>		<i>Globular & shaped <u>10/14R</u></i>
<i>4.</i>					

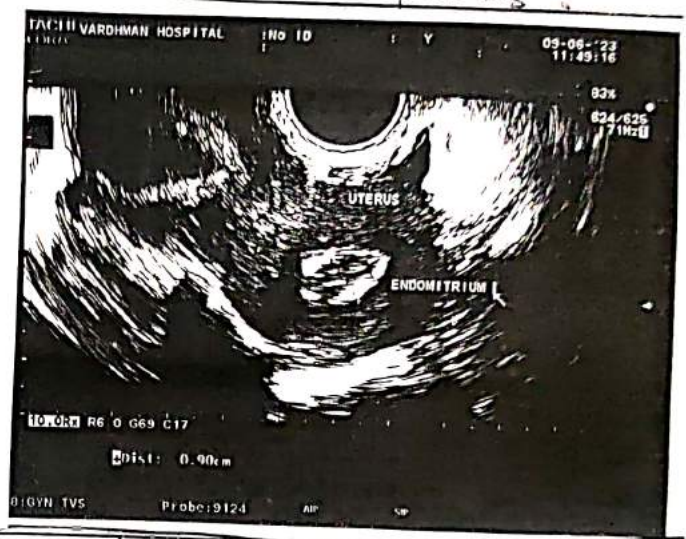
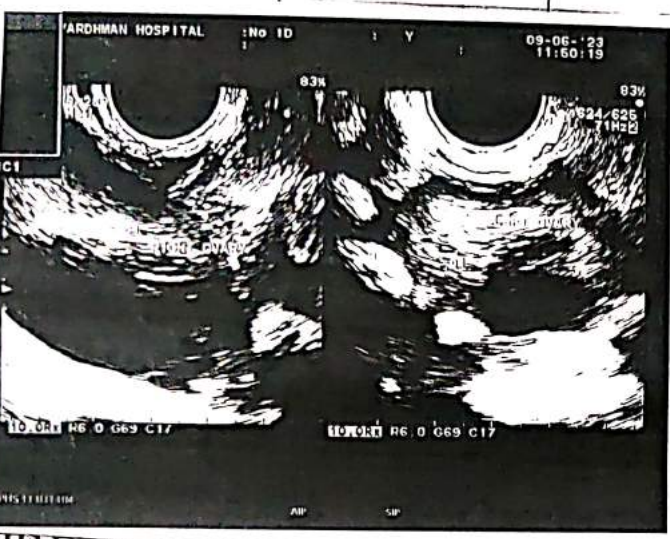
LEAD DATE: _____

I Cycle Drug :

L.M.P.

Scan	Rt. Ovary	L. Ovary	Endometrium	Comments
8/6/23 9/12	Both ovaries seen F1- 33x33	F1- 46x32	Uterus Endo-9mm pls - clear	Rlv globular astaped 1014R ? 1 mucus slowly Abnormal 2.2
3.				
4.				



Scan	Rt. Ovary	L. Ovary	Endometrium	Comments
1. 9/6/23	Both ovaries seen		Uterus	Rlv globular
2. 9/13	(Blood cl seen)	(Blood cl seen)	Endo-9mm	astaped
3.				
4.				

Nutan Jain
M.B.B.S., M.S., F.I.C.O.G., F.I.C.M.C.H.
ADVANCE LAPAROSCOPIC SURGEON

Dr. Vandana Jain
M.B.B.S., M.S.
ADVANCE LAPAROSCOPIC SURGEON

Mr. Shweta Nam Chhapra

36
28/10/2023
18

ANNEXURE B-1/1
55
18-10-23
10.56
Vardhman
Trauma & Laparoscopy Centre (P) Ltd.

Age - 39y

198-340

Potd

Lmp: 20/8/23

13P: 90160

wt: 45.9kg

Pit / nothing
Pit

L usn: 4/10/23

Globe oclax

Casdrae

प्रातिहस्तिकारि
शुभ विचार
पुत्र

pt wat

wait x/wed

adv: evacuation

12/14 done on 17/11/23

Und IV endometriosis

1312 tube spill noted

Normal uterine cavity

inj. 1400 5000 twice weekly Tuesday
Friday

inj. PROLUTIN Depot 250 if weekly

Tab. POLVICY 1 ->

Tab. EBEEID 1 ->

Tab. DUPITASTONE 1 ->

Tab. Lycopem - 1 ->

Tab. DEX 5mg also

Tab. DISPRIN 1/2 DAILY

Day
HAT FSH
13 blood sugar F PP
1+IV 1+3mg 000L
1+CV, 1+3mg
1+6-f Electrolytes

Day sonography box beofal gsoalb
and well bung casdrae

TVS/MP

→ No growth

→ Next Scan for m only

Local Auth. Reg. No. : RMEE2108327

VARDHMAN TRAUMA & LAPAROSCOPY CENTRE PVT. LTD.

3rd Km., Jansath Road,
Muzaffarnagar-251001 (U.P.) India

+91-0131-2623084, 2623085

drvandanaivf3@gmail.com
jainnutan@gmail.com

Reg. Office : C-209, Defence Colony, New Delhi-110024

www.vardhmanhospital.com

Here pre-natal Sex determination (Boy and Girl before birth) is not done, It is a punishable act

Procedure
Evacuation done on 2

✓ Sog. Gestā (30) & comp 1ml/w OD X
4 days

Anembryonic Pregnancy.

→ Sp done

→ Hystuo: → (D)


Proctostyl outline of
Syp. 2002 → Wal

28/12/23
BP: 110/40

wt: 45 kg
Temp: 38

o.k. $\left\{ \begin{array}{l} \text{penn en abelama} \\ \text{...} \end{array} \right.$

Dk of me $\left\{ \begin{array}{l} \text{hbc} \\ \text{APLN} \\ \text{TSH} \\ \text{paleetes} \\ \text{Chromosomal analysis CRBk.} \end{array} \right.$



- T. Celekuid 1 — 1
(250)
- T. Parstop 1 — 1
(40)
- X $\left\{ \begin{array}{l} \text{FT. Falvite} \\ \text{ACTUC} \end{array} \right.$ 1 — 1 day
- X $\left\{ \begin{array}{l} \text{FT. Elexid} \\ \text{...} \end{array} \right.$ 1 — 1
- X $\left\{ \begin{array}{l} \text{FT. Disprein} \\ \text{...} \end{array} \right.$ 1/2 — daily
- T. Methergin 1 — 1 x 3 day
- T. Polybion 1 —

✓ T. Progynon 1 — 1 x 21 day
(2mg)
↓
(start from 27.10.23)

✓ T. Deviry 1 — 1 x 14 days
(10)
↓
(start from 8.11.23)

Inform sas
to come on next day
of pd.

23.10.23

CAP. Rovanemus Post-
1 — 102 day, 15-21

TAB Polure ACTIVE
1 —

TAB Elexin
1 —

TAB Eesperin (2mg)
1 —

VTLC TRAUMA & LAPAROSCOPY CENTRE PVT. LTD.

3rd Km. Jansath Road, Muzaffarnagar (UP)



FOLLICULAR SONOGRAPHY

DR. NUTAN JAIN M.S.

DR. VANDANA JAIN M.S.

Lap Date: 17/11/23.

Name/Age: Mm. Sheela Nain Station: C2B

Cel 14 Endometriosis
B/c tubes small

Parity: 0 29yrs ML: 2yrs

Cause of Anovulation: Ovulogen: MH:

HSA

Count:

Moti.:

1 Cycle Drug: L.M.P. 20/8/2023

Scan	Rt. Ovary	L. Ovary	Endometrium	PCT	Cx Mucus
1. NP 18/10/2023	B/C Cystic cl. (23x23)	Adenexa seen	Utterus R/L Ces - 8 weeks 3 days		
2.		Cel - 36mm	Ces - 26mm yolk sac - 6mm		
3.					
4.		A	Single intra uterine pregnancy of 8 weeks 3 days by scan and 8 weeks 3 days by top		
5.					

पतिहस्ताक्षर
मुख्य चिकित्सा अधिकारी
18/10/24
मजीपुर

18/10/2023

Date: Cx OS

Spinbarkett

Cx Mucus

Sperms

Folliculo-Endo-Cx Synchronization

Motile/Nonmotile

Date:
Time:

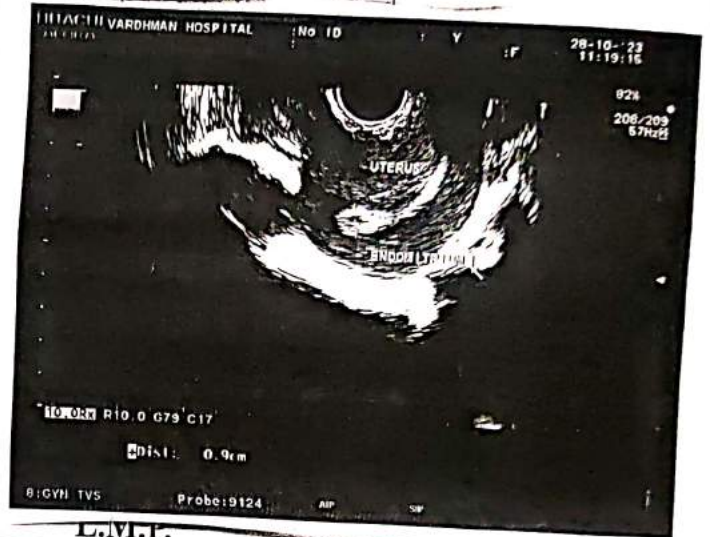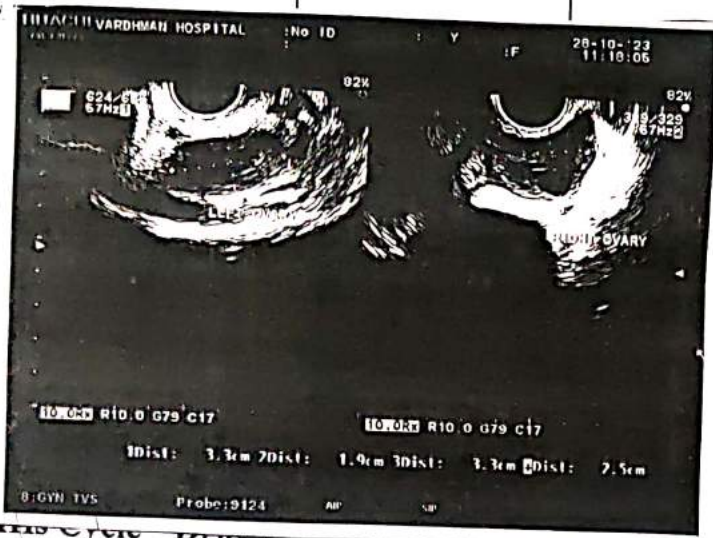Consultant Name & Signatur

P.T.O
VTLC/Gynae/Form/FS/2023/Ver.1

II Cycle Drug :

L.M.P.

Scan	Rt. Ovary	L. Ovary	Endometrium	
1.				
2.	BIL ovaries seen		ut Rly	multifollicular (ashabe)
3.			Endo-9mm	(thickness)
4.				

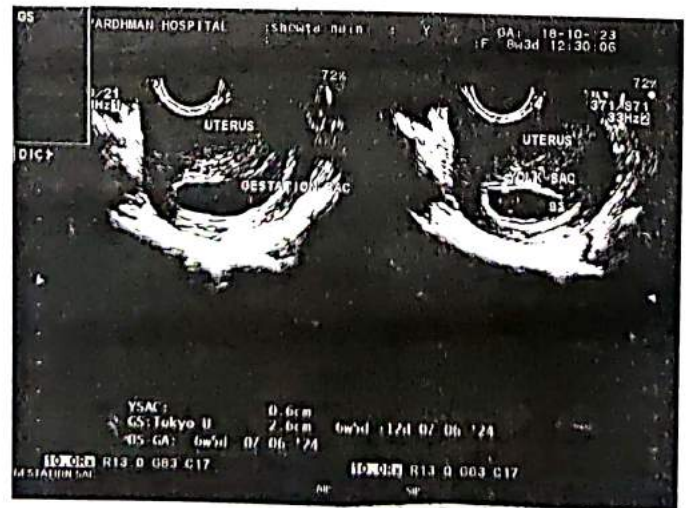
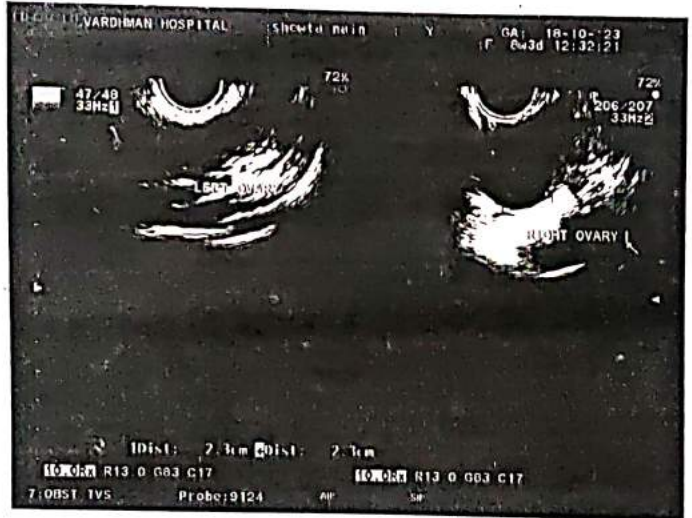
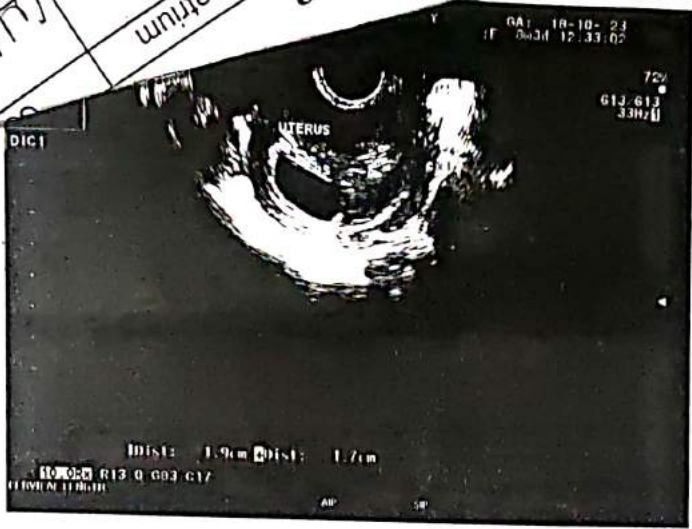
III Cycle Drug :

L.M.P.

Scan	Rt. Ovary	L. Ovary	Endometrium	Comments
1.				
2.				
3.				
4.				

L.M.P.
Endometrium
Rly
Callidulla
(a shape)





Discharge Summary

IPD No: IP-2160/2023

Patient Name: Mrs. SHWETA NAIN

S/D/W/O : Mr. ANANT KUMAR - HUSBAND

Age/Gen/Marital: 28Y /Female/Married

Contact No: 9141407835

Address: MUZAFFARNAGAR -

UHID : VH-18/2023

Department : GYNAECOLOGY & OBSTETRICS

Doctor: VANDANA JAIN

Allocation : 4TH FLOOR -PRIVATE ROOM Unit No : 403

Admission Date 23-Oct-2023 06:40:46AM

Discharge Date 23-Oct-2023 12:49:31PM

Discharge Type:- GENERAL

Final Diagnosis:- Anembryonic pregnancy .

History of Patient Illness:- Patient came to the hospital with complaint of pain in abdomen .

Past Medical & Surgical History:- na .

Procedure/Surgery Details:- 23-Oct-2023 EVACUATION DONE . - TIVA

Post Discharge Prescription:-

S.No.	Medicine	Frequency	Instructions
1.	TAB p/o CEFKIND 250mg	1-0-1	
2.	TAB p/o PANTOP 40mg	1-0-1	
3.	tab p/o FOLVITE 1 tab	1-0-1	
4.	tab p/o EBEXID 1 tab	1-0-1	
5.	TAB p/o DISPRIN 1/2 TAB	DAILY	
6.	tab p/o POLYBION 1 tab	0-1-0	
7.	TAB p/o PROGYNOVA 2mg	1-0-1	for 21 day only start from 27/10/2023
8.	TAB p/o DEVIRY 10MG	1-0-1	for 11 day only start from 18/11/2023

Condition at Discharge:- stable .

Diet Plan:- normal diet .

Advice on Discharge:- to come on next day of period .

Special Notes:- if heavy bleeding per vaginal , lower abdomen pain , nausea vomiting , call on emergency number .

Continue old treatment & medication of physician for any other illness if any like Sugar/BP/Heart/Neuro etc.

When to obtain Urgent Care : Progressive Swelling, Advice discharge from Incision site, Acute pain.

Emergency Contact No. : 8979162397

Next Revisit Date:- To come on next day of period .

Dr. Vandana Jain
MDPS, MS

Regd. No-81598
Dr. VANDANA JAIN (M.S. (GYNAE))
23-Oct-2023

[Signature]

Patient/Attendant Signature

प्रतिहस्ताक्षरित
मुख्य चिकित्साधिकारी
गाजीपुर
15/10/2023



[Signature]
मुख्य चिकित्साधिकारी
गाजीपुर

Treating Doctor/Authorised Signatory

VARDHMAN TRAUMA & LAPAROSCOPY CENTRE PVT. LTD.
3rd Km. Jansath Road, Muzaffarnagar (UP)



FOLLICULAR SONOGRAPHY

DR. NUTAN JAIN M.S.

DR. VANDANA JAIN M.S.

Lap Date : _____

 HSA
 Count : _____
 Moti. : _____

Name/Age : Mrs. Shweta Nair Station : GZB

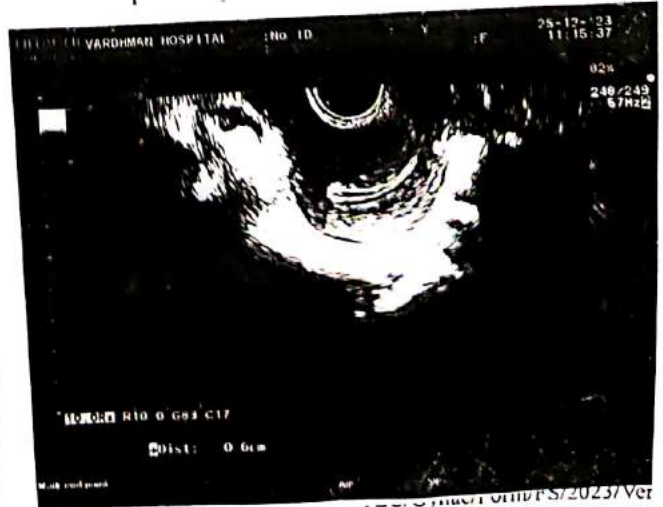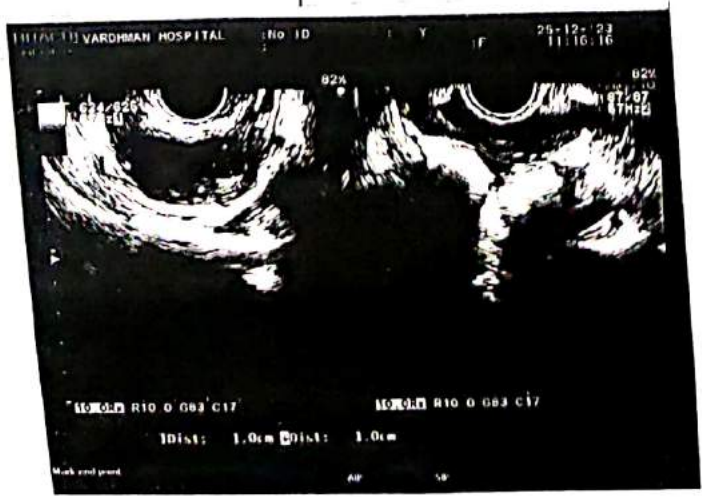
Parity : P0+0 ML :

Cause of Anovulation : Ovulogen : MH :

1 Cycle	Drug :	L.M.P. 10/12/23		
Scan	Rt. Ovary	L. Ovary	Endometrium	[PCT] Cx Mucus
1. NP 25/12/23 D/O	B/L ovaries seen (OS-29x26)	(OS-34x19)	Uterus A/V Globular Endo- 6mm.	
2.	3-4 follicle.	F1-10x10 mild fluid. (Reg CL)		
3.				
4.				

मुख्य चिकित्सा अधिकारी
गाजीपुर

प्रतिदस्तावेज रत
मुख्य चिकित्सा अधिकारी
गाजीपुर



Dr. Nutan Jain

M.B.B.S., M.S., F.I.C.O.G., F.I.C.M.C.H.
ADVANCE LAPAROSCOPIC SURGEON



vardhman hospital

Dr. Vandana Jain

M.B.B.S., M.S., PGDS
IVF / INFERTILITY SPECIALIST
ADVANCED LAPAROSCOPIC SURGEON

Name: Mrs Shweta Nain

City: Ghazipur

Husband:

D.O.B.: 27/10/94

A + ve

Age: 28/y

R Falvit active 1 -

20/11/23

→ Pudact'n - 59.76H

ML: 1yrs

Eberid 1 - 1

TSH - 1.850

Parity: P0 + 1

TVS/NP

Ecosprin (75mg) 1 -

VLLH down 17/11/23

End IV endometriosis

LMP: 18/12/23

P1 + R + R + E + D

131L tubes spill noted
Normal uterine cavity

Day:

Interval Rx

Evacuation done 23/11/23

TRB. CABIMOLIN 500mg wday (4)

Chief Complaints:

absorb

wt - 56kg
BP - 120/80

→ Bon sheet

TRB. Rovamycin PORIC 1-1 x 21d
Crap ab 15 days

Then 1-1 x 21 days

Investigation:
29/12/22

→ foliarase

count - 60M

Mobile - 40%
III

S. PRL
Jatim etc

USG:

D2

Pos.

el

29/12/23

III