

निःशुल्क  
**जिला चिकित्सालय, बाँदा**

अन्तः रोगी टिकट

रोगी का नाम.....चारु बेन.....आयु.....31/7.....  
 पता.....खोदी.....  
 स्त्री/पुरुष/बच्चों की संख्या.....1.....लिंग.....F.....  
 रजिस्ट्रेशन नं०.....S4934.....




दिनांक	लक्षण तथा उपचार
--------	-----------------

Rx

Co - Amoxiclav  
+ Renal Calculus  
Constipation

— Roberto Wisner Centre



San Effect abhiyan aur

एक कदम स्वच्छता की ओर

Verified  
Ref

Chief Medical Superintendent  
 Distt. Hospital, Banda

A

Dr. Ashiqueh

E.M.O.  
 Distt Hospital Banda

कृपया पर्चे को चेक करके लें।

केवल 15 दिनों के लिये मान्य है।

“चिकित्सालय को स्वच्छ रखने में हमारा सहयोग करें”



**CONSULTATION SUMMARY**

Patient Name	: Ms. CHARU KAIN	UHID	: 416430
Age/Gender	: Female/32 Yr 0 Mth 16 Days	OP No	: 534
Doctor	: Dr NRIPEN SAIKIA	Sponsor	:
Department	: GASTROENTEROLOGY	Visit Date	: 02/01/2024 11:09AM

**PRESENTING COMPLAINTS**

RECENTLY DIAGNOSED TO HAVE RENAL CALCULI - ACUTE PAIN ON 20-12-23: USA= LEFT RENAL CALCULI 4-6 MM AND MID POLE  
 WAS ADVISED DOCLO BD , CEFIXIME , RANTAX, ONDEM FOR 5 DAYS . DEVELOPED CONSTIPATION - HARD STOOL P/C:

1. BLEEDING PR FROM 23 TO 31ST DECMBER - FRESH BLOOD , EARLIER NOT MIXED WITH STOOL BUT LATER MIXED WITH STOOL .. PAIN DURING DEFECACTION . NOW NO PAIN , STOOL BETTER AFTER TAKING CRAMAFFIN PLUS FOR LAST 2 DAYS AND BLOOD ALSO NOT COMING SINCE LAST 2 DAYS .
2. DYSPEPSIA,- EPIGASTRIC BURNING SENSATION , FULLNESS, BLOATING , HEAVINESS . MILD EPIGASTRIC PAIN AND DISCOMFORT . IN LEFT LUMBER AREA AND ALSO EPIGASTRIC REGION
3. ANOREXIA , NAUSEA, NO VOMITING  
 NO HEARTBURN , NO REGURGITATION  
 NO PAST H/O JAUNDICE , BT ,

**VITALS**

Date Time	Weight	BP	SPO2
02/01/2024 11:44 AM	69 kg	110/80	98 %

**Diagnosis**

1. BLEEDING PR- ? HAEMORRHOIDAL
2. DYSPEPSIS- APD
3. LEFT RENAL CALCULI

**ORDERS AND PROCEDURES**

1. HAEMOGRAM
2. L.F.T - COMPLETE
3. R.F.T COMPLETE
4. URINE R/E, ROUTINE & MICROSCOPY
5. THYROID PROFILE TEST - FT3, FT4, TSH
6. WHOLE ABDOMEN ULTRASOUND
7. COLONOSCOPY

For All Service Bookings / Appointments : Call / WhatsApp : 9582261515 / 011 61426142 | E-mail : appt@psri.net

Cardiology | CTVS | Critical Care | Dental | ENT | Endocrinology & Diabetes | Gastroenterology | Gynaecology | Internal Medicine | Kidney Transplant | Laparoscopic & GI Surgery  
 Liver Transplant | Nephrology | Neurology | Neurosurgery | Orthopedics | Otolaryngology | Plastic Surgery | Radiation Oncology | Transfusion Medicine | Urology | Vascular Medicine | Transplant | Pediatric | Physiotherapy & Rehabilitation | Psychiatry & Clinical Psychology

Press Enclave Marg, Sheikh Sarai - II, New Delhi - 110017 | E-mail : info@psri.net, web : www.psrihospital.com



Electronic copy of the signature

**CONSULTATION SUMMARY**

Patient Name	: Ms. CHARU KAIN	UHID	: 416430
Age/Gender	: Female/32 Yr 0 Mth 16 Days	OP No	: 534
Doctor	: Dr NRIPEN SAIKIA	Sponsor	:
Department	: GASTROENTEROLOGY	Visit Date	: 02/01/2024 11:09AM

**PRESCRIPTION**

Sr No.	Drug Names	Prescriptions Details	Instruction Remarks
1	PANTOCID D SR 40/30MG CAP 15S,	1 Capsule(s) - once a Day - for 7 Day(s) (Oral), Before Breakfast	
2	DROTIN 40 MG TAB 15S,	1 Tablet(s) - SOS - for 10 Day(s) (Oral), After Meal, FOR ABDOMINAL PAIN	FOR ABDOMINAL PAIN

3- 7- SITCOM FOR SE 100mg daily after meal x 7 days

[In case of Rebleed]

*h saikia*

**EXAMINATION:**

PA- SOFT, NO TENDERNESS AND NO ORGANOMEGALY

Dr NRIPEN SAIKIA

MBBS, M.D.(AIIMS), DNB (GASTRO) MNAMS

SR. CONSULTANT - GASTROENTEROLOGIST & ENDOSCOPIST

DMC NO. 12472

Peglee Plus

1 packet dissolve in 1L water and drink per 6AM - 7:30 AM. Continue to take more water till 8:30 AM

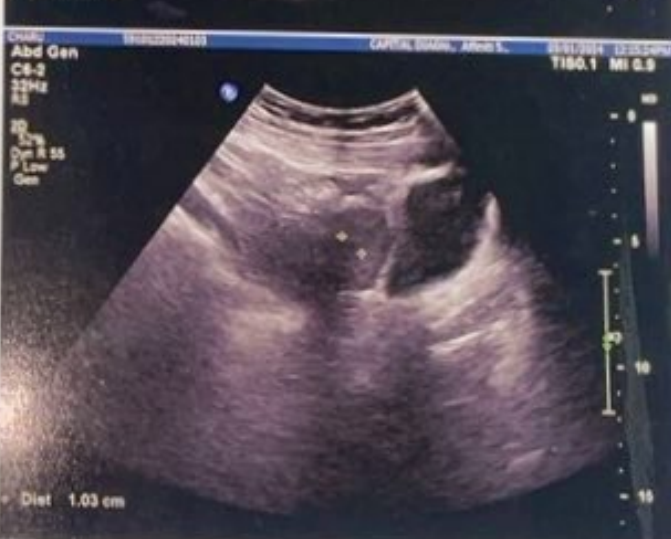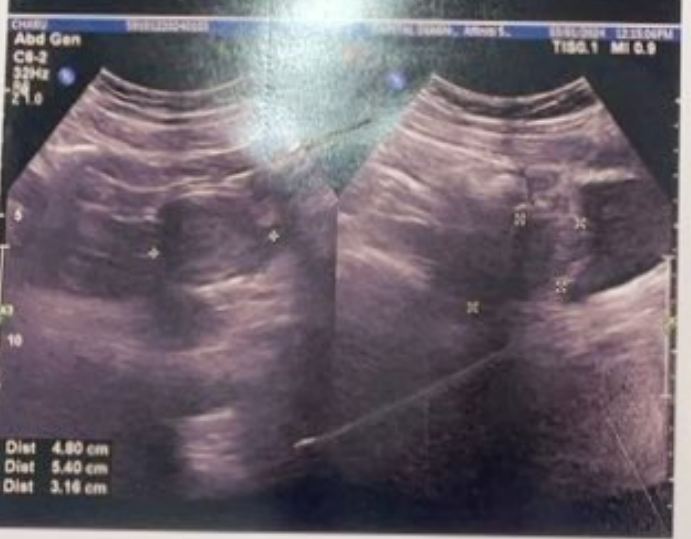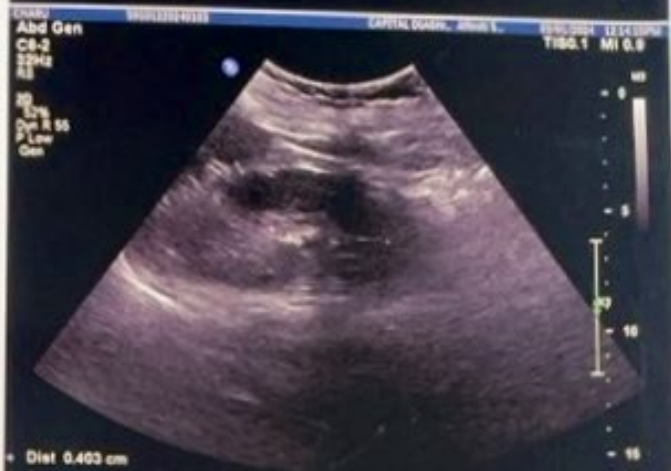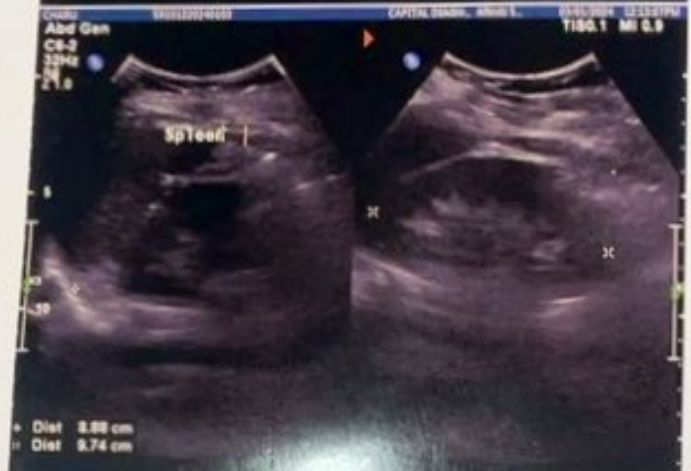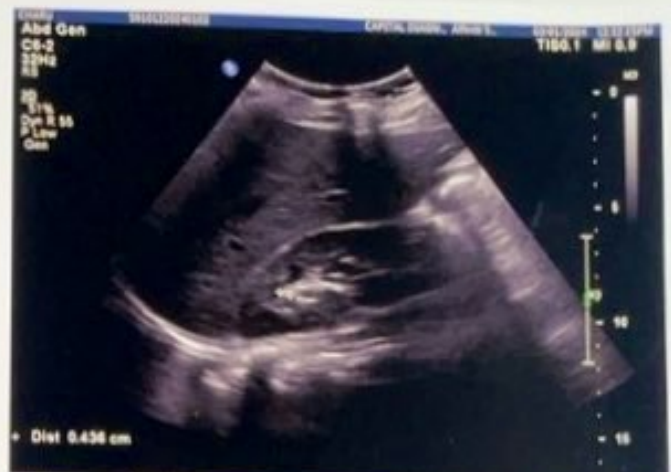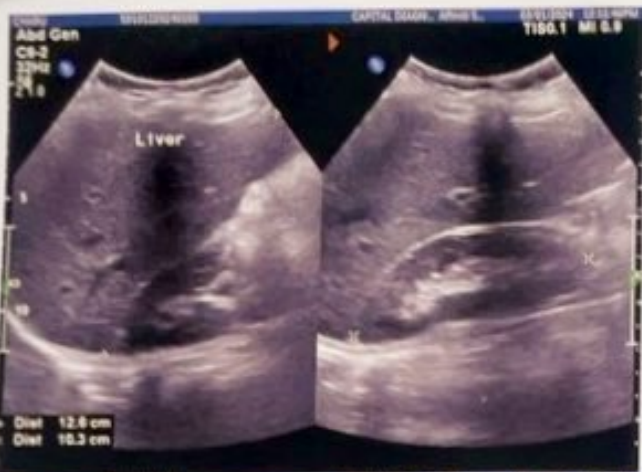USA: B/c nephrolithiasis

- (1) Plenty of oral liquid. 3-4 L/day
- (2) Urology consultation for renal stone.
- (3) Rest for 3-4 days.
- (4) ~~Stress~~

*h saikia*









(An ISO 9001-2015 Certified Centre)

## Capital Diagnostic Centre

Customer Care Number

9910262029, 8750062029, 8750592029,  
9312081529, 011-41676385

NAME:	CHARU KAIN	DATE:	03-Jan-2024
BILL No.		AGE	32 YEARS
REF.BY.DR.	NRIPEN SAIKIA ( PSRI HOSP.)	SEX:	FEMALE

### ULTRASOUND WHOLE ABDOMEN

**Liver**-Is normal in size & measures 12.6 cm. No focal lesion seen. Intra-Hepatic biliary system not dilated. Portal and hepatic venous radicals are normal.

**Gall Bladder**- Well distended. No calculus seen. Wall is normal. Extra hepatic biliary system not dilated.

**Pancreas**- Visualized head is normal in size and echotexture. Pancreatic duct not dilated.

**Spleen**. Is normal in size & measures 8.8 cm with normal echotexture. No focal lesion seen.

**Right Kidney**- measures 10.3 cm in craniocaudal dimension.  
Normal in size shape & position.  
Cortico medullary differentiation maintained with a normal renal parenchymal thickness.  
**Few calculi noted, largest measuring 4.3 mm in upper calyx.**  
No evidence of hydronephrosis seen.

**Left Kidney**- measures 9.7 cm in craniocaudal dimension.  
Normal in size shape & position.  
Cortico medullary differentiation maintained with a normal renal parenchymal thickness.  
**Few calculi noted, largest measuring 4.0 mm in middle calyx.**  
No evidence of hydronephrosis seen.

**Urinary bladder**- Partially distended. No calculus or diverticulum seen. Walls are normal. Both UV Junctions are normal.

**Uterus** - Anteverted and measures 5.4 x 3.1 x 4.8 cm.  
Endometrial thickness 10.3 mm.  
Myometrial echotexture is homogenous with no focal lesion.

**Ovaries** -Both ovaries normally identified and demonstrate normal sonographic appearances.

No fluid in the Pouch of Douglas.  
Air filled bowel loops noted.

### IMPRESSION :

**Bilateral nephrolithiasis**

> *Definitive modality for detecting urinary tract stones is NCCT KUB*

Please correlate clinically.

DR. ADNAN EIRAJ KHAN (MBBS. MD )  
Consultant Radiologist  
Regd. No. DMC 98844

DR. JYOTIRMAYA GOHLI (MBBS. MD )  
Consultant Radiologist  
Regd. No. DMC 78389