

Ms. Yashwant kumar
 Age - 57/m
 Dr. Daraius Shroff
 Reg. No - 108716

W-3, Sector-1, Vaishali, Ghaziabad, NCR, UP - 201012
 Phone: +91-120-4188000, +91-9910036214


Pushpanjali
 Crosslay Hospital
 Journey to Good Health

% Gradual decrease in vision in BR
 since 3 months.

ERD

H/O DM x 17 yrs (L.R)

- Nerve B/D

VA (cell A)
 FCF + PR $\begin{matrix} + \\ \times \\ + \end{matrix}$
 FCF + PR $\begin{matrix} + \\ \times \\ + \end{matrix}$

NCT $\begin{matrix} 33, 30, 29 \\ 23, 22, 22 \end{matrix}$ / mm of Hg

NS 1 + PSC

NS 1 - 2 PSC

I. diamon stat - dil

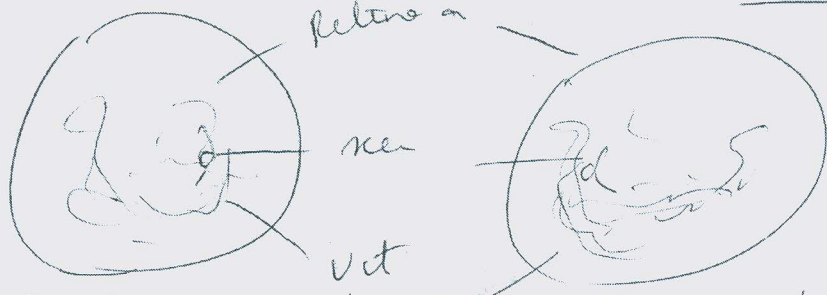
Area 4w - on vit here.

NCT $\begin{matrix} 24, 26, 26 \\ 25, 26, 26 \end{matrix}$

UOE
 UE - weaker > 1 year
 LV - R/E - ~ 2 mths

Controlled Spasms, NS I.

NS 2 + PSC



① Timolol OD

② Refractive 1-1-1

(Cv) Phaco + IOL + vit TMS + LIO

Other Centres:-

- A-9, Kailash Colony New Delhi - 110048. PH.: 41633999, 29231296
- 105, Surya Kiran, 19, K.G. Marg, New Delhi - 110 001. PH.: 23326900, 41510906
- 110-Commercial Plaza, Radisson Suites, Behind Ansal's Time Square Building B-Block Sushant Lok, Phase-I, Sector-27 Gurgaon, Haryana - 122 002. PH.: 0124-4709999, 9971156869

E-mail: shroffey@ndf.vsnl.net.in

Website: www.shroffeycentre.com

[Signature]

Self-attested
 Shalini
 20/9/19



Health Care Imaging Centre

43, Shivaji Road, Near N.A.S. College, Opp. Shanker Ashram, Meerut.
Ph. 0121- 2652434, 2650506

- 3 Tesla Platform MRI (HD)
- Multi Slice Cardiac C.T.
- DEXA Scan (BMD)
- 3D & 4D Ultrasound Colour Doppler
- Digital O.P.G.
- Digital Mammography
- Digital X-Ray

Patient's Name	Mr. Yashwant Kumar	Age/Sex: 63 yrs/M	No. of films
Referred by	Dr. Gaurav Mishra, MS	Jan, 7, 2019	1

OCULAR ULTRASOUND

RIGHT EYE:-

Lens surface is mildly thickened and irregular with minimal intra lenticular opacities, Hyperechoic Area is seen in central part of vitreous chamber, moving on the movement of the eyeballs suggestive of vitreous Hemorrhage / vitreous degeneration. Choroidal detachment is noted on right temporal aspect. Floating membranous opacities are seen in vitreous chamber suggestive of posterior vitreous detachment. Retinal surface is smooth. Evidence of retinal detachment is seen. Optic nerve appears normal. Axial length is 23mm.

LEFT EYE:-

Lens surface is mildly thickened and minimal irregular with intralenticular opacities, floating membranous opacities are seen in vitreous chamber suggestive of posterior vitreous detachment. Retinal surface is regular. evidence of vitreous hemorrhage can be seen. Optic nerve appears normal. Axial length is 24 mm.

Opinion:- B. Scan findings are suggestive of :-

- Vitreous hemorrhage /vitreous degeneration with choroidal detachment on temporal aspect of right eye.
- Posterior vitreous detachment in bilateral eye.

Please correlate clinically.

Dr. Sanjay Gupta
MD

Dr. Alka Agarwal
MBBS (IFUMB)

Dr. Shalabh Bansal
DMRD, FRCR (UK)

Note : Impression is a Professional opinion & not a Diagnosis. All Modern machines /procedures have their limitations. If there is variance clinically this examination may be repeated or reevaluated by other investigations. Patient's identity cannot be verified.
Not for Medico-legal purpose

Self-attested
Shalini
20/9/19

डा० राजेन्द्र प्रसाद नेत्र विज्ञान केन्द्र
DR. RAJENDRA PRASAD CENTRE FOR OPHTHALMIC SCIENCES

UHD: 100724961
CR No.: R-001672-15
Date: 15/01/2015 08:43:33 AM

Name: MR. YASHWANT KUMAR
Age: 59 Y 0 M 16 D/M
S/O: RAM RICH PAL
Address: 71 NANAK PURA MOTI BAGH DELHI

OP-1110029
SURGERY CENTRE
SLIP

ओपीडी सं./OPD No. :

आर. नं./Day Care C.R. No. :
553

निदान/Diagnosis :

15/1/15
B/E
(R) IMSC NSH EPSC E (E)
(L) ER/E Resolving vitreous Haemorrhage

Special Investigations :

24-22 Km < 41-98 / 43-49 (82/172)

Surgery :

(R) phaco + PCIOL + TA
by Prof JS Titiyal

Treatment :

MODEL: SN60WF
POWER: 20.0 D
LENGTH(ØT): 13.0mm
OPTIC(ØB): 6.0mm
SN 21106697 169
EXP DATE 2019-06
UV WITH BL LIGHT FIL
ACRYSOFT IQ
Alcon Laboratories

(R) {
Open pad & bandage after 6 hours
E/d Vigamox TDS
E/d P-lone 6t/day
E/d Tropac TDS
Tab Flexon 1 SOS for pain
Follow up tomorrow in Room 102 at 2PM

सलाह/Advice :

- अपनी आंखों को न मलें। धूप के चश्में का प्रयोग करें।
Do not rub your eyes. Use goggles in sunlight.
- चिकित्सक के निर्देशानुसार नियमित रूप से दवाईयां लेते रहें।
Put medicines regularly as prescribed.
- दो सप्ताह तक अपनी आंखों को नल के पानी से न धोएं।
Do not put tap water in your eyes for 2 weeks.
- दो सप्ताह तक भारी वजन उठाने से बचें।
Refrain from lifting heavy weights for 2 weeks.
- कृपया उपर्युक्त निर्धारित समय पर अपने चिकित्सक से अवश्य मिलें।
Please meet your doctor as and when prescribed above.

Self-attested
Shalini
20/1/15

ब० रो० वि० कार्ड
O.P.D. Card

डा० राजेन्द्र प्रसाद नेत्र विज्ञान केन्द्र,
अ० भा० आयु० सं०, नई दिल्ली - 110029


Dr. Rajendra Prasad



अनुभाग व दिन
Section and Day
मंगलवार व शुक्रवार
Tuesday & Friday

III

कमरा नंबर
Cabin No.



DR RAJENDRA PRASAD CENTRE FOR OPHTHALMIC SCIEN

UHID: 100724961
Dept. No.: 20140050135655
YASHWANT KUMAR 59Y/M
A/O: RAM RICHPAL

Date: 30/12/2014

OPD-Dr. J S Titiyal
Unit-III
Room No.: 3

टेयाल का एकक
s Unit

TUE.	आयु Age	पता Address
------	------------	----------------

Address: 71 NANAK PURA MOTI BAGH, DELHI



DATE DIAGNOSIS

(1) ISC (2) Alcon

उपचार Treatment

C/O of 20V in R/E
since 1yr.

YA \leftarrow HMCF \times 1
No PL.

OM x 18-19 yrs.

Controlled

NCT \leftarrow 25
40.

on medication

A/S

H/O of no vision in L/E
x 14yr

IMSC i NS II
MVI TSC

pseudophakia i
corneal edema

(cat ex 2yrs back)

delhi
B/E 116

जायायें (Dr.) Jeevan S. Titiyal

कृपया इस कार्ड को सुरक्षित रखें -
Kindly keep safe

1. धूम्रपान

MODEL: SN60WF
POWER: 20.0 D
LENGTH(Ø_T): 13.0mm
OPTIC(Ø_B): 6.0mm
SN: 21106697 169

EXP DATE 2019-06
UV WITH BLUE LIGHT FILTER
AcrySof IQ IOL
Alcon Laboratories, Inc.

हर वक्त साथ लायें।
-up visits.

ता डालें 3. थूकिये नहीं

Self-attested
Shalini
20/9/19

Name: **kumar, yashwant**
 ID: 724961
 Date of birth: 01/07/1955
 Examination date: 07/01/2015
 Surgeon: **Dr. JST**

Formula: SRK®/T
 Target ref.: plano
 n: 1.3375



AL measurements should be checked for plausibility as there may be pathological changes!

OD right		OS left	
AL: 24.22 mm (SNR = 8.2) K1: 41.98 D / 8.04 mm @ 82° K2: 43.49 D / 7.76 mm @ 172° R / SE: 7.90 mm / 42.73 D Cyl.: -1.51 D @ 82°			
Refraction: 0 D 0 D @ 0°		Refraction: 0 D 0 D @ 0°	
Status: Phakic		Status: Phakic	
Alcon SN60WF		Alcon ReSTOR SA60D3	
A const: 119.00		A const: 118.50	
IOL (D)	REF (D)	IOL (D)	REF (D)
21.5	-1.08	21.0	-1.15
21.0	-0.73	20.5	-0.79
20.5	-0.39	20.0	-0.44
20.0	-0.05	19.5	-0.09
19.5	0.29	19.0	0.26
19.0	0.62	18.5	0.60
18.5	0.95	18.0	0.94
Emme. IOL: 19.93		Emme. IOL: 19.37	
Alcon SA60AT		Alcon Toric SN6AT(2-9)	
A const: 118.80		A const: 119.20	
IOL (D)	REF (D)	IOL (D)	REF (D)
21.0	-0.90	21.5	-0.91
20.5	-0.55	21.0	-0.57
20.0	-0.20	20.5	-0.23
19.5	0.14	20.0	0.11
19.0	0.48	19.5	0.44
18.5	0.81	19.0	0.77
18.0	1.14	18.5	1.09
Emme. IOL: 19.70		Emme. IOL: 20.16	
Alcon SN60WF		Alcon ReSTOR SA60D3	
A const: 119.00		A const: 118.50	
IOL (D)	REF (D)	IOL (D)	REF (D)
21.5	-1.08	21.0	-1.15
21.0	-0.73	20.5	-0.79
20.5	-0.39	20.0	-0.44
20.0	-0.05	19.5	-0.09
19.5	0.29	19.0	0.26
19.0	0.62	18.5	0.60
18.5	0.95	18.0	0.94
Emme. IOL: 19.93		Emme. IOL: 19.37	
Alcon SA60AT		Alcon Toric SN6AT(2-9)	
A const: 118.80		A const: 119.20	
IOL (D)	REF (D)	IOL (D)	REF (D)
21.0	-0.90	21.5	-0.91
20.5	-0.55	21.0	-0.57
20.0	-0.20	20.5	-0.23
19.5	0.14	20.0	0.11
19.0	0.48	19.5	0.44
18.5	0.81	19.0	0.77
18.0	1.14	18.5	1.09
Emme. IOL: 19.70		Emme. IOL: 20.16	

(* = value has been edited, ! = borderline value)

Self-attested
Shalini
20/9/17

ब. रो. वि. कार्ड
O.P.D. Card

डा. राजेन्द्र प्रसाद नेत्र विज्ञान केन्द्र,
अ. भा. आयु. सं., नई दिल्ली - 110029

Dr. Rajendra Prasad



अनुभाग व दिन
Section and Day
मंगलवार व शुक्रवार
Tuesday & Friday

III

कमरा नंबर
Cabin No.

DR RAJENDRA PRASAD CENTRE FOR OPHTHALMIC SCIEN

UHID: 100724961

Dept. No.: 20140050135655

YASHWANT KUMAR 59Y/M

MO: RAM RICHPAL

Date: 30/12/2014

OPD-Dr: J S Titiyal

Unit-III

Room No.: 3

टेयाल का एकक
s Unit

आयु
Age

पता
Address

Address: 71 NANAK PURA MOTI BAGH, DELHI



DATE DIAGNOSIS

(R) BCL (L) NCV

उपचार Treatment

C/O of 00V in R/E
since 1yr

YAC HMCF $\frac{p}{t}$
No PL.

DM x 18-19 yrs.

controlled

NCT 25
40

on medication

A/S

H/O of no vision in L/E
x 1yr

IMSC i

NS II

pseudophakia i
corneal edema

(cat s x 2yrs back)

no

NVI

जायदे (Dr.) Jeevan S. Titiyal

delhi
B/E 116

कृपया इस कार्ड को सुरक्षित रखें -
Kindly keep safe

1. धूम्रपान

MODEL: SN60WF
POWER: 20.0D
LENGTH (ØT): 13.0mm
OPTIC (ØB): 6.0mm
SN 21106697 169

EXP DATE 2019-06
UV WITH BLUE LIGHT FILTER
AcrySolv IQOL
Alcon Laboratories, Inc.

हर वक्त साथ लायें।
-up visits.

ला डालें 3. थूकिये नहीं

Self-attested

Shalini
20/9/19