

प्रेषक,
मुख्य चिकित्साधिकारी,
राखनऊ

सेवा में,

नीतू पाठक, अपर जिला एवं सत्र दयापौडीश, अ. वि. /
विशेष दयापौडीश, सी. वी. आई. /
कोट संख्या - 1, दरबनऊ

संख्या : ई-7/13960

दिनांक 27.09.2019

महोदय,

आपके पत्र संख्या 3620/XV PF दिनांक 27-9-2019

के सन्दर्भ में सूचित करना है कि श्री/सुश्री/श्रीमती नीतू पाठक, उच्च-त्राघिण अपने स्वास्थ्य परीक्षण हेतु अधोहस्ताक्षरी के समक्ष उपस्थित हुई/हुए।

परीक्षणोपरान्त चिकित्सा अभिलेखों के आधार पर इन्हें दिनांक 06-09-2019 से 26-09-2019 तक के चिकित्सा अवकाश की संस्तुति प्रदान की जाती है। यह अपने कार्य हेतु स्वस्थ हैं, इनके चिकित्सा प्रमाण पत्र वापस किये जा रहे हैं।

संलग्नक : उपरोक्तानुसार

Neetu Pathak
हस्ताक्षर प्रमाणित

for मुख्य चिकित्सा अधिकारी,
अपर जिला चिकित्साधिकारी,
राखनऊ
27.9.2019

भवदीय
for मुख्य चिकित्सा अधिकारी,
अपर जिला चिकित्साधिकारी,
राखनऊ
27.9.2019

Self attested
27.9.19.

Ophthalmology



2019262936

Priority

Neetu Pathak / 36 Years, FEMALE

Printed on 28-3-2019 10:57:17 Ms. Mamta Gauram
172.16.4.153

R

23
27/9/19

SANJAY GANDHI POST GRADUATE INSTITUTE OF MEDICAL SCIENCES LKO.



आत्मना सर्गो जितः

O.P.D. CASE FILE

20.....

NEETU PATHAK

Patient's Name.....

P. N. S. COLONEY

Self assisted
27.9.19

SANJAY GANDHI POSTGRADUATE INSTITUTE OF MEDICAL SCIENCES, LUCKNOW

28-3-2019.
V.K.

Department	Unit/Consultant

Referring Doctor/Hospital:

Name:

Address:

Date	History
------	---------

90 decrease vision LE
X tears 4-5 mths.

operated for RDLEON 13th Sep 20
Post surgery she regained
vision but for now 4-5 mth
vision is hazy & it is gradual
increasing.

Past History

Treatment History

No other/significant systemic
history of medication/ailments

Using glasses
since her grad
(2000)

Personal/Social/Family History

O/E
AC (N) depth
Cornea (N)
G-1 Insulin (N)

Pupil N&NR.
PSC developing LE
Diffuse

Self attested
27.9.19.

②

Physical Examination

Nutrition Status: Good/Adequate/Reduced

Anaemia No Yes

Dyspnea No Yes

Cyanosis No Yes

Jaundice No Yes

Edema No Yes

Exanthem No Yes

W		Kg
H		Cm
BP		mmHg
Pulse		/min

Thyroid

Lymph Nodes

Fundus

Head & Neck

Myopic fundus

Chest

BE

CVS

LE Laser marks

Abdomen

Adv:

Cataract surgery LE E. IOL
when daily routine activity becomes hampered.

Provisional Diagnosis

Dr. Vinay Karanappa
 Department of Ophthalmology
 S.R.N.G. Hospital - 2019.

Self attested
27.9.19.

13. 7.2019 Plan

Fields → 20-2
76 point screening
Follow up Notes
LONC.

Fundus
Status quo as mentioned in March 2019.
Pupil NSNR BE
PSC diffuse
LE.

Retraction
in

Old sh

Dr. N. S. ...
Professor
Department of ...
Srinivas University

4/19/19

P.P. - 21.50 / - 2.75 x 180°

Repeat (New sh) - 19.75 / - 1.75 x 180°


(R) - 21.50 OS / - 2.75 OC x 180° 6/72

(L) - 20.50 OS / - 2.0 OC x 180° 6/112
T.M.

Self attested
27.9.19

④

4/9/19 Patient is having difficulty in reading & daily routine work with her left eye x 2-3 months



Posterior Subcapsular Cataract LE

Diffuse

History of retinal detachment surgery LE in Sep 2017 and oil removal in March 2018.

Adv:

Considering the previous retinal detachment surgery and now difficulty in daily routine chores, immediate ~~cataract~~ surgery is required and a regular follow up is advisable for detailed retinal examination post surgery.

4/9/19

Self attested
27.9.19

4/9/19

Adv

(E)

(R)

(L)

10L powe
Left
eye

Specular
microscop

$PAL = 32.63$

$PAL = 31.71$

$K_1 = 43.99 \times 177^\circ$

$K_1 = 44.28 \times 11^\circ$

$K_2 = 46.85 \times 87^\circ$

$K_2 = 46.58 \times 91^\circ$

$AWD = 3.15$

$AWD = 3.17$

$LT = 3.93$

$LT = 3.82$

$WTW = 12.1$

$WTW = 12.2$

$IOL = -7.50$

$IOL = -5.50$

CC $\begin{cases} 535 \\ 528 \end{cases}$

[Signature]

4/9/19
Dr. Vias Kurnia
MSc (Optometry)
MSc (Ophthalmology)

27/9/19

$V_n \begin{matrix} \text{cos } 6118 \\ \text{cos } 6118 \end{matrix} \begin{matrix} \text{tan } 619 \\ \text{tan } 619 \end{matrix} \begin{matrix} \text{tan } 619 \\ \text{tan } 619 \end{matrix} \begin{matrix} \text{cos } 619 \\ \text{cos } 619 \end{matrix}$

$T_n < \begin{matrix} 13.4 \\ 14.4 \end{matrix} \text{ mmHg}$

P-T-O

Self assisted

29.9.19

6

27/9/19

~~Patient underwent~~ Conj
Cornea
Pupil] NAD
NSNR

O/E Anterior Segment - Pseudophakic
LE

Fundus status quo as
mentioned on 28.3.2019.

R

- Continue medication
as advised elsewhere

- Considering previous
retinal detachment and
the surgeries, periodical
regular short follow up
required early post-op

NA

27-9-19

Dr. S. J. ... (nauja
ology)
or
Ophthalmology
S. J. ...

Self attested

27/9/19

Eye: Right

Name: NEETU PATHAK ID: 2019262936 DOB: 08-08-1990

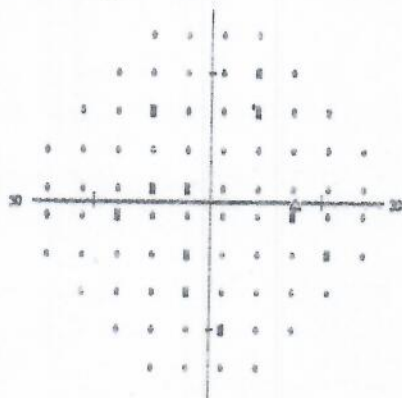
Central 76 Point Screening Test

Fixation Monitor: Blind Spot
Fixation Target: Central
Fixation Losses: 7/11 x
False POS Errors: 6/9 x
False NEG Errors: 7/8
Test Duration: 05:21

Stimulus: II, White
Background: 31.5 A88
Strategy: Two Zone
Test Mode: Age Corrected

Pupil Diameter: 2.8 mm
Visual Acuity:
RX: -20.00 DS -2.00 DC X 180 Age: 36
Date: 19-07-2019
Time: 11:55 AM

Central Reference: 34 dB
Peripheral Reference:



- Seen 65/76
- Not Seen 11/76
- △ Blind Spot

Eye: Left

Name: NEETU PATHAK ID: 2019262936 DOB: 08-08-1990

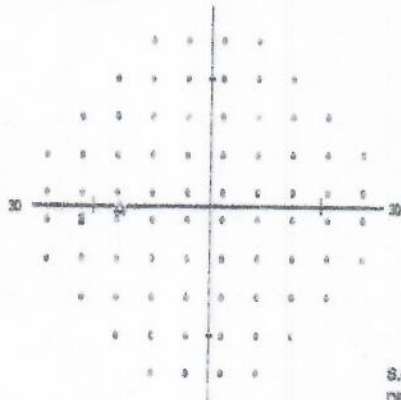
Central 76 Point Screening Test

Fixation Monitor: Blind Spot
Fixation Target: Central
Fixation Losses: 9/10 x
False POS Errors: 6/8 x
False NEG Errors: 0/8
Test Duration: 05:49

Stimulus: II, White
Background: 31.5 A88
Strategy: Two Zone
Test Mode: Age Corrected

Pupil Diameter:
Visual Acuity:
RX: -20.00 DS -2.00 DC X 180 Age: 36
Date: 19-07-2019
Time: 12:02 PM

Central Reference: 34 dB
Peripheral Reference:



- Seen 75/76
- Not Seen 1/76
- △ Blind Spot

S.G.P.S.I.
DEPARTMENT OF OPHTHALMOLOGY
LUCKNOW

© 2010 Carl Zeiss Meditec
HFA II 780-42538-5.1.2

*Self assessed
29.9.19*

**PRAKASH NETRA KENDR
MEDICAL CERTIFICATE**

PNK/F/07/11/00

MRD No. 87774
Gandhinagar Hospital
 NH-2, Vajra E. Road - 4, Gomti
 Nagar, Lucknow
 Tel: 0522-4033000, 4242164
Aliganj Hospital
 HIG-3B, Sector - E, Aliganj,
 Lucknow
 Tel: 0522-4024306
www.pnkycare.com
 pnk_ipa@pnknetra.com



M. K. Khemchandani
Dr. M. KHEMCHANDANI
 M.B.B.S., M.S.
 REGD. No. 42028

TO WHOMSOEVER IT MAY CONCERN

Date of Issue 28/9/19 (Fitness certificate)
 This is to certify that Miss/Mr/ Mrs Neelvi Pathak Age 38 Yrs Gender female
 Address C-18 Bulha colony, Lucknow
 diagnosed as Cataract (high refractive error) (Post Retinal detachment Surgery) (LE)
 He / She has undergone RE / LE Conics with monofocal IOL under TA/LE
 on 6/9/19 He / She was discharge on 6/9/19 and Doctor has advice for rest
 for 21 days days from 6/9/19 to 26/9/19 and She/Hic will be fit to join normal
 duty 27/9/19

Keeping in view her previous medical history of Retinal detachment and consequential major surgeries Short periodical examination of both eyes is extremely necessary.

(Patient Signature)
Neelvi Pathak

Medical Directors

Associate Medical Directors

Consultants

Dr. Rajat Dhesi, M.S.
 Chief - Glaucoma Services

Dr. Mohit Khemchandani, M.S.
 Dr. Bela Kamboj, M.S.

Dr. Prabhat Ranjan, M.S.
 Dr. Anshu Mishra, M.S.
 Dr. Virendra Singh, M.S.
 Dr. Saurabh Singh, M.S.
 Dr. Amit Yadav, M.S.
 Dr. Ajay Prakash, M.S., DOMS

Dr. Shobhit Chawla, M.S., FMRP
 Chief - Vitreo Retina Services

PKM
27/09/2019

Self attested
27.09.19