

हृदय वक्ष एवं तंत्रिका विज्ञान केन्द्र
 ब० रो० वि०
 अ० भा० आ० सं०, नई दिल्ली-110029
 Cardiothoracic & Neurosciences Centre, O.P.D.
 A.I.I.M.S., New Delhi-110029

दिनांक/Date

उम्र

विभाग

Deptt.

NS 2019/017/0013880

UHID: 104783037

Neuro Surgery-I

General

Date 24/10/2019 Mon, Thu

Neuro Surgery

Gen

ब०रो०वि०सं०

O.P.D. No.

Name VEENA NARAIN

②

54Y 14D/Female

W/O: Rakesh Narain

Phone No. 9935854411

Consultant Room 17

SR Room:

Dr.G D SATYARTHEE

Registration Time: 8.30 AM - 10.30 AM

Thursday Only: 12.30 PM - 2.30 PM

Go lumbarache + radiation to ②
 L5 distribution

MPL ② spine

② extrapranimal
 mass (likely
 Nerve sheath tumor)
 in L1-L2 intervertebral
 foramen

② sided disc bulge
 L4/5

Adv:

2 months

- T. Pregabalin M 1 tab HS.
- T. Vibrania D 1 CD.
to continue
- X Ray flex/extension lateral view
- Physiotherapy - ②
- Avoid sitting/Avoid heavy weights
- Avoid bending forwards
- Rest on hard bed

Please share your feedback to improve our hospital on the Website link: meraaspataal.nhp.gov.in

हृदय वक्ष एवं तंत्रिका विज्ञान केन्द्र
ब० रो० वि०
अ० भा० आ० सं०, नई दिल्ली-110029
Cardiothoracic & Neurosciences Centre, O.P.D.
A.I.I.M.S., New Delhi-110029

दिनांक/Date

NC 2019/016/0025723

Neurology-II

Charges Rs. 0.0/-

विभाग

UHID: 104783037

Neurology

Scr

Deptt.

Date 24/10/2019 MON, THU

Name VEENA NARAIN

54Y 14D /Female

ब०रो०वि०सं०

W/O: Rakesh Narain



O.P.D. No.

Phone No. 9935854411

Consultant Room

SR Room: 7

Registration Time: 8.30 AM - 10.30 AM

Diagnosis

LBA

24/10/19

54yr female

Hypothyroidism (on Euthyrox 100ug OD)
x 20 yrs

Mild Low back ache x 2007

mild - moderate

recurred over 1-2 yrs.

Mild LS spine - L4-L5 & L5-S1, PIVD

2015-2016 - Back pain mild - moderate

moderate - severe; gradually increasing

cl/ stretchy pain in left lower limb
x 2-3 months

Please share your feedback to improve our hospital on the Website link: meraaspataal.nhp.gov.in

SARVODAYA HOSPITAL & RESEARCH CENTRE

(UNIT OF GHAZIABAD NURSING HOME PVT. LTD.)

KJ-7, Kavi Nagar, Ghaziabad (U.P.) Tel : 0120-2701694, 4228429, 9811085835 Fax 0120-2800450

www.sarvodayahospitalgzb.in • E-mail : info@sarvodayahospitalgzb.in

CIN-U74899DL1967PTC026952

Mr. Veena Narayan 52y 11²

Date: 16/9/25

♀, Chronic Back ache - 10-15y

↑↑ Last 2yrs.

• Cor Numbness Both lower limbs.

MRI Spine & ? Neurophorum of
C6/7

A. Ref to higher centre

Dept of Neuro / Ortho A.I.I.M.S
N. Delhi

for further mgmt

Dr. Naveen Jain
Dr. NAVEEN JAIN
M.B.B.S. M.S
Laparoscopic And G. Surgeon
OPD-12 Noon 2 PM
8 PM 9 PM
Mob-9811242374

The Hospital is Under Panel of:

- ★ Alankit Health Care TPA Ltd.*
- ★ Appolo Munich Health Insurance Co. Ltd.
- ★ Bajaj Allianz General Insurance Co. Ltd.
- ★ Cholamandalam MS General Insurance Co. Ltd.
- ★ Dedicated Healthcare Service TPA (India) Pvt. Ltd.*
- ★ E-Mediteck TPA Services Limited*
- ★ Ericson TPA Healthcare Pvt. Ltd.*
- ★ Family Health Plan (TPA) Limited*
- ★ Future Generali India Insurance Co. Ltd.
- ★ Genins India TPA Limited*
- ★ Good Health Plan Ltd.*
- ★ HDFC ERGO General Insurance Co. Ltd.
- ★ Health India TPA Service Pvt. Ltd.*
- ★ ICICI Lombard General Insurance Co. Ltd.
- ★ Iffco Tokio General Insurance
- ★ L & T General Insurance Co. Ltd.
- ★ Max Bupa Health Insurance Co. Ltd.
- ★ MD India Healthcare Service (TPA) Pvt. Ltd.*
- ★ Med Save Healthcare (TPA) Limited*
- ★ Medi Assist India Pvt. Ltd.*
- ★ Medi Care TPA Service (I) Pvt. Ltd.*
- ★ Raksha TPA Pvt. Ltd.*
- ★ Religare Health Insurance Co. Ltd.
- ★ Safeway TPA Services Pvt. Ltd.*
- ★ Spurthy Meditech (TPA) Solutions Pvt. Ltd.*
- ★ Star Health & Allied Insurance Co. Ltd.
- ★ TTK/Vidal Health TPA Pvt. Ltd.
- ★ United Healthcare TPA*
- ★ United Healthcare Parekh TPA*
- ★ Universal Sampo General Insurance Pvt. Ltd.

Surya Prits & Stat.



D-170A, Sector 50, Noida 201301
 Tel.: 0120-4880000, Fax: 0120-4880099
 Mobile: 9971055822, 9971055922
 email: info@neohospital.com w-site: www.neohospital.com

P-1 F-2 P-3

Name	MRS. VEENA NARAYAN	Age/Sex	52 YRS/FEMALE
Patient_ID	140274	Pt Mobile NO	09935858441
Issue Date	03-Sep-2019 17:52	Doctor's Name	Dr. RAJIV MOTIANI
Doctor's Dept	NEUROLOGY	Doctor's Timing	5:00 pm to 8:00 pm (Mon to Sat)

Height: _____ (cm) Weight: _____ (kg) Temp: _____ Pulse: _____
 Pain Score(0-10): _____ Allergies If Any: _____ Bmi: _____ BP: _____ (mmHg)

Dr. D. S. Sharma
Neurosurgeon to see

Δ chr lumbar radiculob.
 x > 10 yrs. - PIVD L4-5
 L5-S1
 } Neurofibroma
 22 x 14 mm at L1
 now 17 x 3 x 24 mm in
 last MRI (16/5/19)

MRE: - L4-5 & L5-S1, PIVD & L4-5
 disc coming off int compromise

R
 3/Sept/19

1. T. LYRICA 75mg HS
2. T. NEUROBION FORTE 1-1
3. Cap VIBLANIA-D 1xOD
4. T. PANTOP 40mg OD
5. T. FLEXON-MR 1-1 x 3d.

In Case of Emergency, Please Call On - 01204880077

Back strengthening exercises
 physiotherapy

The new health care destination

A unit of Muskan Medical Centre Pvt. Ltd.

R
 ① Mr Margalep AT (1/2) Day (9pm)
 ② Cap Vibrance D (1) Day (9pm)

3 = 11/13

Review 300 Hz / 150

2
 3/9/15

Mr Mike - P (1) — (1)
 Mr Rave 20 (1) — (1)

500 Hz

2/10/15
 Neurologically
 stable

R
 ① Mr Margalep AT (1) Day (9pm)
 ② Cap Vibrance D (1) Day (9pm)

MRI Lumbar vert spine
 - Contrast after biopsy

Review, 6 weeks
 2/10/15

5A



Sector - C, Vasant Kunj, New Delhi - 110070 Ph: 01 11-42255225 (30 Lines), For Appointment - Ext. 201
Fax: 91-11-26898810 E-mail: appointment@isiconline.org Visit us at: www.isiconline.org

OPD CARD

Registration No. 648905
Name Veena N. Narain
Age 53 M/F f DOB _____
Address _____
Phone _____
Consultant Dr. Arun Sharma

DEPTT. OF NEUROSURGERY
UHID: 648905 Bill Date: 20/07/2019 Age/Sex 53 Yrs. F
NAME: Mrs. VEENA NARAIN
DOCTOR: DR. ARUN SHARMA
COMPANY: ISIC - 2019
ADDRESS: 47 GYAN LOK HAPUR UTTAR PRADESH INDIA
MOB No: 9935854411



✓ Please bring this card on all subsequent visits.

Date Chief Complaints / Past History

ISIC OPD

20/11/19

[Signature]

F10/c6 Right L1 Extraforaminal
nerve sheath tumour extending
into foramen

Allergies if any (Please Specify)

- c6 Low backache

Investigations Advised / Reports

Adv - ① Isometric low back exercise

② Tab Tolperidas 15mg 100
x 5 days

③ Cap Felicitin 100
x 10 days

④ BMD OEXA Scan - Spine +
Left Hip

⑤ Review monthly - check up

Doctor's Name and Signature



Dr. Arun Sharma
M.S., D.S., M.S., M.Ch
NABH & NABL Accredited
FNB (Ortho) 1993, 1995
FNB (Spine) 1995
DMC No. 34574

Indian Spinal Injuries Centre
Sector-C, Vasant Kunj, New Delhi-110070

4.A
9:25 AM



Sector - C, Vasant Kunj, New Delhi - 110071, Ph: 011-42265225 (39 Lines), For Appointment - Ext. 201
Fax: 011-26098814 E-mail: appointment@isiconline.org Visit us at: www.isiconline.org

OPD CARD

Registration No. 648905

Name Veena Narain

Age..... M/F..... DOB.....

Address.....

Phone.....

Consultant Dr. Ankur Nanda

✓ Please bring this card on all subsequent visits.

DEPTT. OF SPINE SERVICES

UHID: 648905 Bill Date: 16/05/2019 Age/Sex 53 Yrs. /F

NAME: Mrs. VEENA NARAIN

DOCTOR: DR. ANKUR NANDA

COMPANY: ISIC - 2019

ADDRESS: 47 GYAN LOK HAPUR UTTAR PRADESH INDIA

MOB No: 9935854411



Date Chief Complaints / Past History

ISIC OPD

Date 16/5/19

Signature A

2007

PND

Allergies if any (Please Specify)

BACK PAIN

2017

Investigations Advised / Reports

MRP Pelvic/Spine
Bony area
tumour @ Sac.

Treatment Advised

Post Neuro Rx

2013

90 → Back pain.
⇒ Change in posture.

C/E: Numbly @

Adv.

(PT) BACK STRENGTHENING EX.
→ CORE STABILISATION EX.
→ SHOULDER COMPLEX EX.
→ ISOMETRIC, NORA PA

⇒ (L) → US & BIPSY / (R) @
⇒ MRI & BACK



NABH & NABL Accredited
FOD/QF/03/01/10-01-15

(L) Tab SURGICAL

(R) Nanda

Doctor's Name and Signature

→ RMD DOXA Scan.
Spine 2 @ 1/1/18.

→ Ref: to Dr. Arun Sharma
Room - NO - 25.

del

relaxer

MRI - Right L2 Extraforaminal
(2017) - 1 cm x 1 cm tumour extending
into foramen

Ref: (1) MRI - Lumbosacral spine with
contrast

S. Creative

→ No significant change in size of
tumour as compared to earlier scan (2017)
→ C4/5 - degenerative changes

Dr. Arun Sharma
M.B.B.S., M.S., M.Ch
Consultant Neurosurgeon
DMC No. 34574
Indian Spinal Injuries Centre
B-Block, Vasant Vihar, New Delhi-110070

- Ref: (1) Tab Tolperidone 15mg BD x 5 days
- (2) Cap Paracetamol 650 mg qd x 10 days
- (3) Isometric back exercises

As

MS. VEENA NARAIN

53/F

16/05/2019

DR. ANKUR NANDA

UHID-648905/CA/957376

M.R.I. OF THE LUMBOSACRAL SPINE WITH CONTRAST

Sagittal T1 & T2 weighted scans of the lumbar spine were studied and these were correlated with axial T1 & FSE T2 weighted images.

L4-5 intervertebral space is especially reduced with degenerated bulging intervening disc encroaching upon lateral neural canals – more towards left side and foraminal compromise is further compounded by facet joint arthropathy.

L5-S1 intervertebral disc is also bulging posterolaterally towards left side, compromising the lateral neural canal.

At other disc levels, thecal sac containing cauda equina and lumbar intervertebral foramina seem adequately capacious.

Lower end of the spinal cord displays uniform parenchymal signal intensities.

Paravertebral psoas muscles are unremarkable.

Pear shaped soft tissue intensity mass-like lesion is seen extending posterolaterally from L1-2 intervertebral foramen into posterior paraspinal muscles – this likely nerve sheath tumor measures up to 17.2 x 38.5 x 24.3 mm in maximum AP, cephalocaudal and lateral dimensions respectively.

IMPRESSION: MR scan has revealed pear shaped likely nerve sheath tumor extending posterolaterally from L1-2 intervertebral foramen in posterior paraspinal muscles.

Degenerated L4-5 and L5-S1 intervertebral discs are encroaching upon lateral neural canals toward left side, and foraminal compromise at L4-5 level is further compounded by facet joint arthropathy.

Please correlate clinically

DR. Rajesh Kapur, MD
SR. CONSULTANT RADIOLOGIST

**DEPARTMENT OF RADIO DIAGNOSIS AND IMAGING
REPORT**

Patient Name	: VEENA NARAIN	Procedure Date	: 28/10/2017
UHID	: JHN000172635	Order From	: RADIOLOGY-BILL-GF-AB
Age/Sex	: 51Y/F	Accession No.	: SC115MR17005358
Requested By	: Dr. Saurabh Rawall	Investigation	: MRI SPINE PLAIN LUMBOSACRAL
Ordered Time	: 28/10/2017	Reported Time	: 28/10/2017 3:32:50

FINDINGS:

Degenerative scoliosis with type I end plate degenerative changes at L4-L5 showing end plate marrow edema on STIR.

Rest of the vertebrae are normal in height and alignment and shows normal marrow signal.

Disc desiccation changes noted from L3-L4 to L5-S1 with annular tear at L4-L5 and L5-S1 at reduced disc space at L4-5 level.

Diffuse disc bulge is seen at L3-L4 level indenting the thecal sac.

Diffuse disc bulge is noted at L4-L5 indenting the thecal sac and causing mild to moderate bilateral neural foramina narrowing.

Diffuse disc bulge is noted at L5-S1 causing no significant canal/neural foramina narrowing.

Well defined enhancing T2 hyperintense lesion is seen at L1 vertebral level and appears encroaching towards neural foramina measuring 22 x 14 mm likely nerve sheath tumour

The primary lumbar canal is adequate in diameter with no evidence of stenosis. The lower end of the spinal cord, conus medullaris and nerve roots of the cauda equina are normal.

The thecal sac is normal and CSF demonstrates normal signal intensity.

No intra spinal mass or pre/paravertebral collection seen.

IMPRESSION:

Degenerative scoliosis with type I end plate degenerative changes at L4-L5 showing end plate marrow edema on STIR.

Diffuse disc bulge is noted at L4-L5 indenting the thecal sac and causing mild to moderate bilateral neural foramina narrowing.



Well defined enhancing T2 hyperintense lesion at L1 vertebral level and appears encroaching towards neural foramina measuring 22 x 14 mm likely nerve sheath tumour

Compared to previous MRI dated 12/06/2017 no obvious change in lesion size or character is seen.



Dr. Anshui Jain
MD,DM (Neurointerventional
Radiology)
Associate Consultant



OP CASE SHEET			
MRN	: JHN000172635	Date	: October 28, 2017 15:45
Patient Name	: Mrs Veena Narain	Visit No	: OP-003
Sex / Age	: Female/52 Years 18 Days	Consultation Type	: REVISIT
Address	: Additional District Judge, Hapur, Uttar Pradesh	Mobile No	: 9935854411
Queue No	: 14	Paid name	: CASH



Weight: _____ (kg) Height: _____ (cm) BP: _____ (mmHg)
 Pain Score(0-10): _____ Pulse/HR _____ Allergies (if any) _____

History:-
~~MR~~
 No chng : size of tumor
 Hdy
 Needs. surgery.

Clinical Assessment :
 7. ETOSINE MR 0 _____ 0 x 5 days
 7. PAN 40 0 _____ x 5 days.
 Physiotherapy - 10 day
 Yoga / Exercises.

[Handwritten Signature]



**DEPARTMENT OF RADIODIAGNOSIS AND IMAGING
REPORT**

Patient Name : VEENA NARAIN Procedure Date : 12/06/2017
UHID : JHN000172635 Order From : RADIOLOGY-BILL-GF-AB
Age/Sex : 51Y/F Accession No. : SC115MR17002838
Requested By : Dr. SAURABH RAWALL Investigation : MRI LUMBOSACRAL
SPINE
Ordered Time : 12/06/2017 Reported Time : 12-6-2017 4:50:31

MRI L. S. SPINE

Using the spine coil, images of the lumbosacral spine was acquired in Sagittal T1, STIR & T2 followed by transaxial T1 and T2 at the level of IV disc in 3 Tesla MRI.

FINDINGS:

Degenerative scoliosis with type I end plate degenerative changes at L4-L5 showing end plate marrow edema on STIR.

Rest of the vertebrae are normal in height and alignment and shows normal marrow signal.

Disc desiccation changes noted from L3-L4 to L5-S1 with annular tear at L4-L5 and L5-S1.

Diffuse disc bulge L3-L4 indenting the thecal sac.

Diffuse disc bulge noted at L4-L5 indenting the thecal sac and causing moderate left neural foraminal narrowing.

Diffuse disc bulge noted at L5-S1 indenting the thecal sac.

Note is made of pedunculated T2 hyperintense lesion seen at L1 vertebral level and appears encroaching towards neural foramina measuring 22 x 14 mm ? neurofibroma.

The primary lumbar canal is adequate in diameter with no evidence of stenosis. The lower end of the spinal cord, conus medullaris and nerve roots of the cauda equina are normal. The thecal sac is normal and CSF demonstrates normal signal intensity.

No intra spinal mass or pre/paravertebral collection seen.

IMPRESSION : MRI LUMBOSACRAL SPINE SHOWS:

- **DIFFUSE DISC BULGE AT L3-L4, L4-L5 AND L5-S1. DISC AT L4-L5 CAUSING MODERATE LEFT NEURAL FORAMINAL NARROWING.**

CONTRAST IS SUGGESTED.



Dr. Cps Chauhan

M.D

Senior Consultant Radiologist

JAYPEE
GROUP

NABH

Regd. & Corp. Office: Jaypee Healthcare Ltd., Wish Town, Sector - 128, Noida - 201304, Uttar Pradesh, India
Ph: +91 (120) 4122222, Fax: +91 (120) 4582899 CIN: U85191UP2012PLC053358

Email: askus@jaypeehealthcare.com, Website: www.jaypeehealthcare.com



Emergency 1800 102 9 102



Helpline 1800 102 9 103

Dr. Saurabh Rawall

MBBS(AIIMS), MS Ortho (AIIMS), FNB Spine Surgery, Fellowship in Spine Surgery(Canada)

INSTITUTE OF SPINE

Consultant

Mob: +91 98688 97026 E-mail: saurabh.rawall@jalindia.co.in



OP CASE SHEET

UHID	: JHN000172635	Date	: June 12, 2017 12:25
Patient Name	: Mrs Veena Narain	Visit No	: OP-001
Sex / Age	: Female/51 Years 8 Months	Consultation Type	: FIRST VISIT
Address	: Additional District Judge, Hapur, Uttar Pradesh	Mobile No	: 9935854411
Queue No	: 9	Plan name	: CASH



Weight: _____ (kg) Height: _____ (cm) BP: _____ (mmHg)
 Pain Score(0-10): _____ Pulse/HR _____ Allergies (if any) _____

History:

Hydroxy-d. PVD - 2007
 C/O... LBA - 1 year (Gp E-3 not)
 O/R... SLR +ve FABER +ve N. defn
 To dex (P) (P) paraspinal area.

Clinical Assessment :

Ad
 Xray L-S spine - AP Flex
 Lat Ext
 MRI L-S spine
 T-XE ROSHINE MR 0 _____ 0 x 5 day
 PAN 40 0 _____ x 5 day
 2 Tab

Dr. Saurabh Rawall
 MBBS (AIIMS) MS Ortho (AIIMS)
 FNB Spine Surgery Fellowship
 (Canada, Australia)
 DMC-125003
 OPD - Tue, Wed, Sat
 For Appointment - 9935854411



NABH

Regd. & Corp. Office: Jaypee Healthcare Ltd., Wish Town, Sector - 128, Noida - 201304, Uttar Pradesh, India
Ph: +91 (120) 4122222, Fax: +91 (120) 4582899

CIN: U85191UP2012PLC053358

Email: askus@jaypeehealthcare.com, Website: www.jaypeehealthcare.com



Emergency, 1800 102 9 102



Helpline 1800 102 9 103

DEPARTMENT OF LABORATORY MEDICINE
BIOCHEMISTRY

Name	Mrs VEENA NARAIN	Department	INSTITUTE OF SPINE
Age	51.8 Year(s) / FEMALE	Consultant	Dr. Saurabh Rawall
UHID	JHN000172635	Specimen	Serum
Visit Type	OP / OP-001	Collected On	12/06/2017 16:05
Patient Address	additional district judge, HAPUR, UTTAR PRADESH	Received At	12/06/2017 16:42
Sample No	BC1706120269	Reported On	12/06/2017 17:23

<u>Test Name</u>	<u>Result</u>	<u>Unit</u>	<u>Biological Reference Interval</u>
BLOOD UREA (Colometric (Urease))	26	mg/dL	19.0-43.0
SERUM CREATININE (Enzymatic-two point rate)	0.67	mg/dl	0.52-1.04

Comments :

Note : Abnormal Results are Highlighted.

H = High (Elevated Above Normal Range Value)
 PH = Panic High (High Critical Range Value)

L = Low (Decreased Below Normal Range Value)
 PL = Panic Low (Low Critical Range Value)

THE TESTS ARE PERFORMED AT DEPARTMENT OF LABORATORY MEDICINE, JAYPEE HOSPITAL, NOIDA-201304

--- End of Report ---

Anjali

Dr. Anjali
 Senior Registrar (Biochemistry)
 Department of Laboratory Medicine

Page 1 of 1



Saurabh Rawall

M.BBS(AIIMS), MS Ortho (AIIMS), FNB Spine Surgery, Fellowship in Spine Surgery(Canada)

INSTITUTE OF SPINE

Consultant

Mob.: +91 98688 97026 E-mail: saurabh.rawall@jalindia.co.in



OP CASE SHEET

MRN	: JHN000172635	Date	: June 13, 2017 15:35
Patient Name	: Mrs Veena Narain	Visit No	: OP-002
Sex / Age	: Female/51 Years 8 Months	Consultation Type	: FOLLOW UP
Address	: Additional District Judge, Hapur, Uttar Pradesh	Mobile No	: 9935854411
Queue No	: 2	Plan name	: CASH



MRI - L1 Extraforaminal Neurofibroma

Ad.

To discuss c. Dr. Chavhan

25A

[Handwritten signature]

7. ME-12 09 1500 0 ————— x 1 month

[Handwritten signature]



Regd. & Corp. Office: Jaypee Healthcare Ltd., Wish Town, Sector - 128, Noida - 201304, Uttar Pradesh, India
Ph: +91 (120) 4122222. Fax: +91 (120) 4582899 CIN: U85191UP2012PLC053358

Email: askus@jaypeehealthcare.com. Website: www.jaypeehealthcare.com



Emergency 1800 102 9 102



Helpline 1800 102 9 103

Dr. Ramneek Mahajan
MBBS, MS, M.CH (Ortho)
Fellowship in Joint Replacements
(Singapore, Germany, Australia)
Director- Orthopedic & Joint Replacement
Head of Unit
OPD Timings: Mon - Sat 11am to 3pm
☎: 09811939693, 09868710877
✉: ramneek.mahajan@maxhealthcare.com

For Appointments:
Rosily: 9810552530
Manoj: 9811939643

Dr. O P Gupta
MBBS, MS (Ortho), PDSE, FISS (USA)
Fellowship in Spine Surgery, USA
Consultant - Orthopedics & Spine Surgery
OPD Timings: Mon/Wed/Fri: 8am to 11am
Wed/Thu/Sat: 3pm to 5pm
☎: 9756010382

Dr. Anil V
MBBS, MS Ortho, DNB Ortho, MNAMS
Attending Consultant
Joint Replacement and Trauma
OPD Timings: Mon/Wed/Fri: 5pm to 8pm
Tue/Thu/Sat: 8am to 10am
☎: 9013284032

Dr. Abbas Shaharyar
MBBS, MS Ortho
Attending Consultant
Pediatric Orthopedics and Trauma
OPD Timings: Mon/Wed/Fri: 8am to 10am
Tue/Thu/Sat: 5pm to 8pm
☎: 8447060410

Patient's Name: *Am. V. Chaudhary*

Age/ Gender: *51 / F*

UHID *140127*



↳ LBP

MRI → neurofibroma at L1 level

Plan

*- Prognosis explained
- Treatment option discussed in detail*

Dr. O P Gupta
Consultant
Spine Surgery & Trauma
Max Smart Super Speciality Hospital
A Unit of Gujarmal Modi Hospital
Research Centre for Medical Sciences

Max Smart Super Speciality Hospital, Saket

A unit of Gujarmal Modi Hospital and Research Centre for Medical Sciences

(Gujarmal Modi Hospital and Research Centre for Medical Sciences Registered under the Societies Registration Act XXI of 1860)

Regd. Office: Mandir Marg, Press Enclave Road, Saket, New Delhi - 110017

Phone: +91-11-7121 2121, Fax: +91-11-2696 3801

Reg. No	443200	Issue Date	15/07/2017
Name	Mrs. Veena Narain	Age/Sex	51 Yrs/Female
Doctor/Unit	Dr. SUMIT SINHA	Department	NEURO SURGERY
Category	TARIFF VERSION 7.2	Pay Mode	Cash : 1200.00 9968292347
Room No		Queue No.	
Doctor Mob.	9818770024	Patient Mob.	9935854411
Day & Time	MON: 9:00AM - 6:00PM, TUE: 9:00AM - 6:00PM, WED: 9:00AM - 6:00PM, THU: 9:00AM - 6:00PM, FRI: 9:00AM - 6:00PM, SAT: 9:00AM - 6:00PM		

Note : Kindly take Prior Appointment for Consultation and diagnostic.

BP: 110/70 mm/Hg	Height:	Weight: 71.4 kg	BMI:
------------------	---------	-----------------	------

Allergies:

History and complaints:

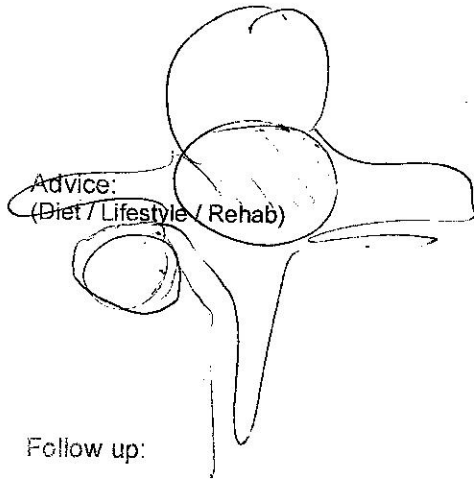
*Low Backache x 6 mths
Similar episode in 2007*

Examination:

*M/Li-Spine L45 Lt) IVD
+ BNST at L12*

Provisional/Final Diagnosis:

Drug orders:



*Adv / PC
- Surgery for the BNST
+ Endoscopic L45 Discectomy*

Follow up:

Investigations:

Date: _____

RTal Pregabalin M 75mg BD To

Time: _____

- Physiotherapy

Contact: _____

- Diathermy

Name & Signature of the Consultant with Stamp:

Reception - 0124-4585555 Ambulance - 0124-4585666

Registered Address - Paras Healthcare Pvt. Ltd. Paras Hospitals, C Block, Sushant Lok, Sec-43, Gurgaon, Haryana, India.



Kriti Scanning Centre (P) Ltd.

55-B, Lowther Road (In front of Medical College), Allahabad.

Name : Veena Narain
Age/Sex : 41 years/ female
Date : 08 March 2007
Referred by : Dr U C Goel MD

Time: 4:01:18 PM

Report:

MRI of Lumbo-Sacral Spine

Imaging Sequences

Axial: T2 TSE, T1TSE

Sagittal: T2 TSE, T1TSE

Mild degenerative disc desiccation and **tear of posterior annular fibres is seen at L4-5 and L5-S1 levels** with maintained disc heights. Vertebral heights are normal with maintained alignment and normal spinal curvature. Bone marrow signal intensity is normal.

Mild posterocentral disc protrusion is seen at L4-5 level indenting thecal sac.

Mild focal posterocentral disc protrusion is seen at L5-S1 level causing effacement of fat ventromedial to both S1 nerve roots.

No abnormal pre or para vertebral soft tissue is seen.

No evidence of ligamentum flavum hypertrophy.

Bony diameters of lumbar canal (on axial sections at mid-body level) are within normal limits.

Conus medullaris is normal in morphology and signal intensity.

Impression: Mild posterocentral disc protrusion at L4-5 level indenting thecal sac

Mild focal posterocentral disc protrusion at L5-S1 level causing effacement of fat ventromedial to both S1 nerve roots

Adv: Clinical Correlation

Dr V K Agarwal MD

Dr S K Gupta MD


Dr Pankaj Kamra MD

Dr S S Anjum DMRD

* Discrepancies due to technical or typing errors should be reported for correction within seven days. No compensation liability stands. RM

12/6/07

Mrs Veena Narain, 41y/F

LBA since 10 Feb 07.

No radiation of pain

O/E. SKI - 90° D/L

Power - 5/5

DTR's - (N)

NO sensory loss

Reflex - (N)

mild L5 spine tenderness

MRI - mild disc bulge at L4-S PIVD (central).

Plan -

Adv - Physiotherapy.

Adv - Tab Xanaxid 275 mg sos.

Max Super Speciality Hospital

1, Press Enclave Road, Saket, New Delhi - 110 017
Phone: +91-11-6611 6666, Fax: +91-11-6611 6677