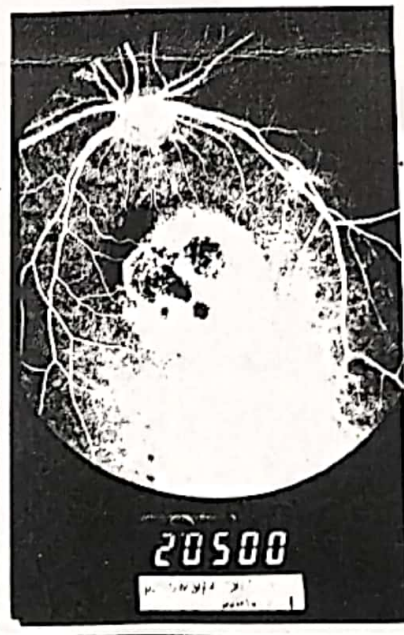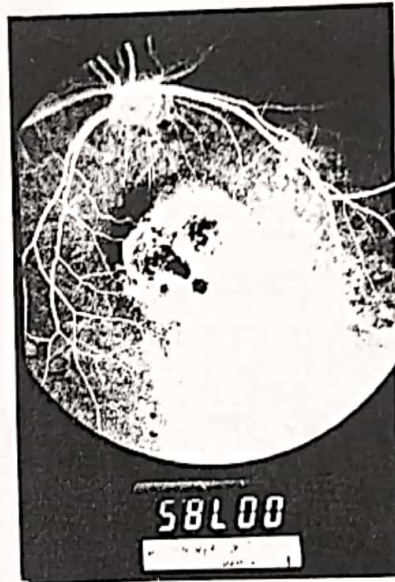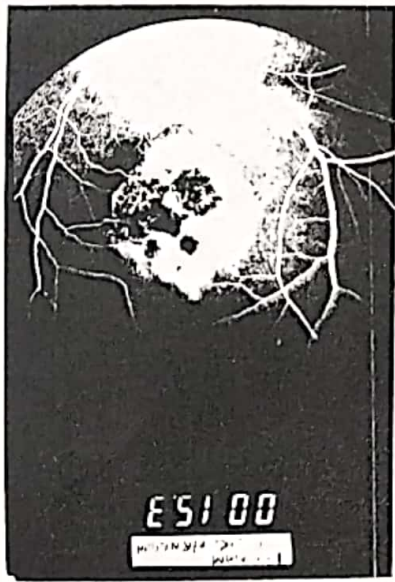
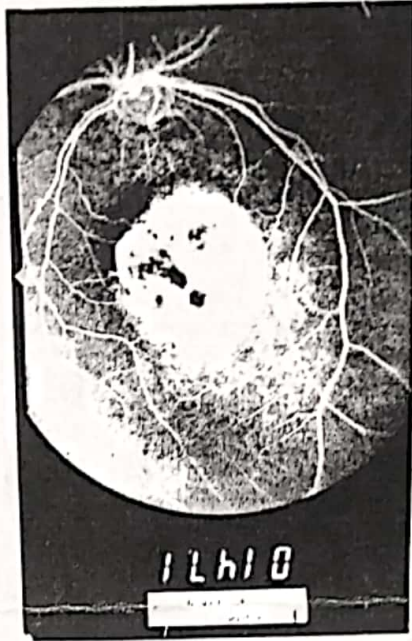
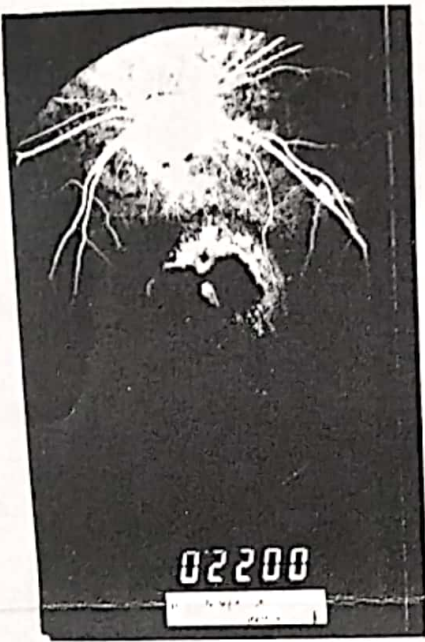
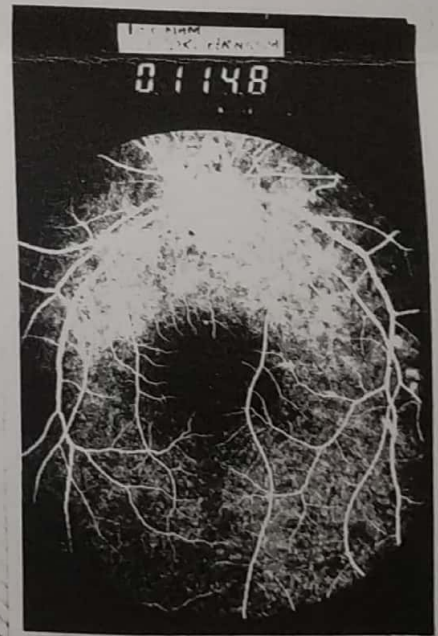
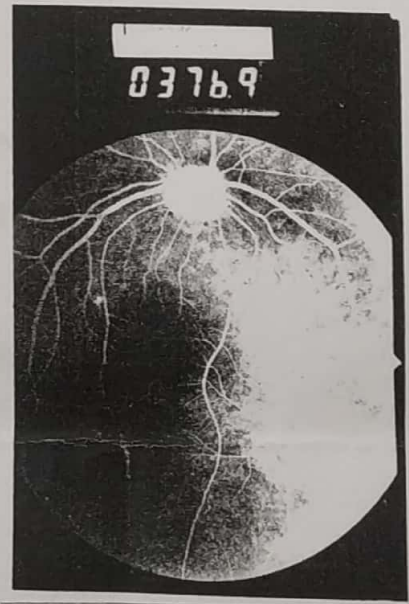

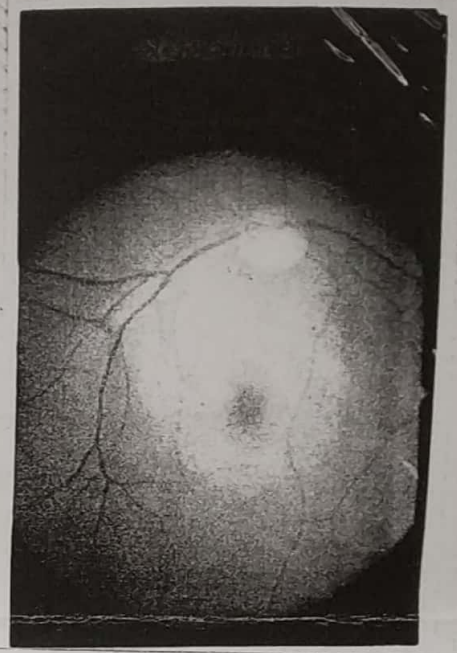
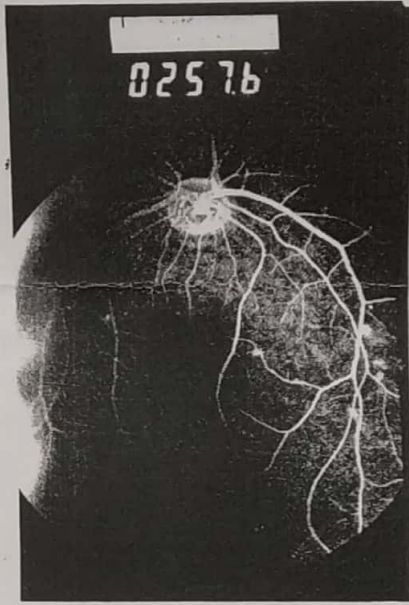



FLUORESCCEIN ANGIOGRAPHY REPORT
RIGHT EYE







Max Hospital™
HB Twin Towers
Near TV Tower, Pitampura
Wazirpur District Centre
New Delhi 110 034
Phone +91 11 2735 1844, 4735 1844
Fax +91 11 2735 7229, 4735 7229

OPHTHALMOLOGY

Patient Name : Ms. POONAM GUPTA
Age/Sex : 43YRS / F
Date : 11/01/2013
Registration : NHWZ.242117
Location : HBT

Complaints : Nil

History : History of right ocular weakness since long

Visual Acuity

Distance

RE: CF

LE: 6/6 (P)

Near

RE: < N 36

LE: N 12

Pupil

Normal size, Normal reaction

Ocular Movements

Complete and Full

Ocular Alignment

Orthophoria

Convergence

Normal for age

Refraction and Acceptance:

Distance

RE: Plano

LE: + 0.50 Ds 6/6

Near

LE: Add + 1.0 Ds N 6



HEALTHCARE
aring for you... for life

Max Hospital™
HB Twin Towers
Near TV Tower, Pitampura
Wazirpur District Centre
New Delhi 110 034
Phone +91 11 2735 1844, 4735 1844
Fax +91 11 2735 7229, 4735 7229

Slit Lamp Examination:

Adnexa	WNL
Cornea	WNL
ANT.CH.	WNL
Lens	WNL
Vitreous	WNL

Tonometry: NCT

RE:	20 mmHg
LE:	19 mmHg

Fundus (Retina / Exam.)

Direct:-

RE -	Healed central chorio retinitis
LE -	Normal

Color Vision - Normal

Impression - Left refractive error, Right maculopathy

Dr. Sudhir Garg
(SR. Consultant Ophthalmologist)

MAHARAJA AGARSAIN HOSPITAL

(A CHARITABLE HOSPITAL & RESEARCH CENTRE)

Managed by : AGARWAL WELFARE SOCIETY (REGD.)



Peenam Gupta
481F

Dr. Narettama
Sun Wed/Sat

Dr. NAROTTAMA SINDHU
M.B.B.S (AIIMS), MD (AIIMS)
DNB, MNAMS
DMC Reg No 8656

ⓐ Healed
wound lesion
? Marginal disc

? Healed
? lesion
? Corneal

etc etc ⓑ

dh -

hs -

by 7/11/18
for exam.

0.75 x 2.5 x 90
0.25 x 160

Add leads 4-strings

Aug Aug 9:30am

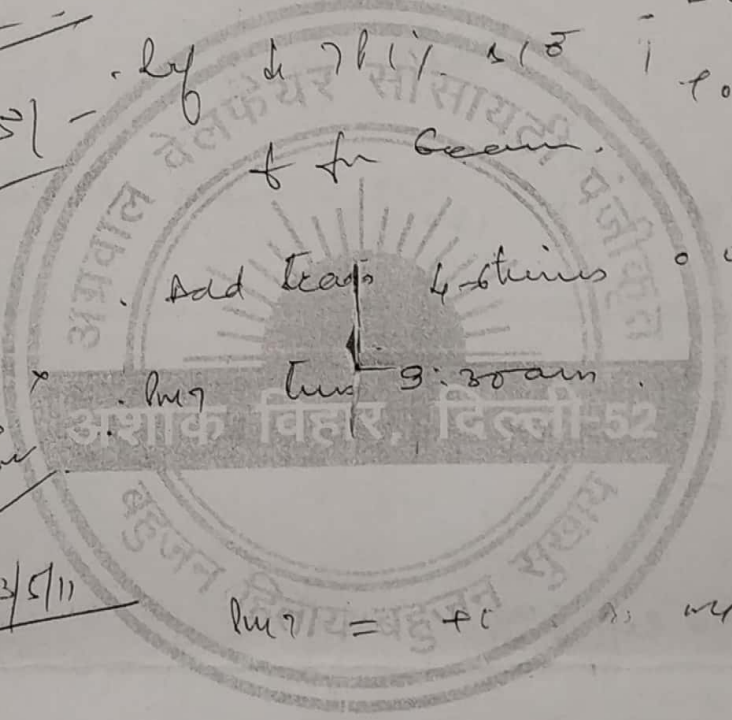
अशाक विहार, दिल्ली-52

3/5/11

Aug = +

4.5 ⓐ

Operational
refers to ligament
clumping
in wound etc!



2/5/12

3 MAY 2011

h - G16

~~h~~ seen + 1.25 m 44.5

On @
re @ depth
h - boat lab /
par

26 FEB 2013

oo
~~oo~~

Ad
A. 12
BP 120

125 A 1 c 6.1/1

h

09 MAR 2013

• Ref. f. 7/14. 30

T 20.25/20.50 x 167

h sol - DW 7 x 20.50

Managed by
A CHA
AV

Gupta

MAR 2013

detected on 1 with back
AS(f) - 140 m/j

AJA AGARSAIN HOSPITAL

(A CHARITABLE HOSPITAL & RESEARCH CENTRE)
Managed by : AGARWAL WELFARE SOCIETY (REGD.)



Dr. Gupta


Dr. [Signature]

his Ined / Sat
Dr. NAROTTAMA SINDHU 9:30-12:00am
M.B.B.S (AIIMS), MD (AIIMS)
DNB, MNAMS
DMC Reg No 8656
SM v smth

12 MAR 2013

Mr. J. in sec. Incan Add +1.50 m kg.5

42



6 weeks at 10/15
- dubin fresh old 2 times B/E
U.

wants new planer
BS

30 AUG 2014

6/6
①

Ref + 70/15
at near connection
hs(2) - [Signature]

②
h-0.5 capping
not healthy

① + 0.75 / + 0.62 x 167°

h-7 sat 5:30a

Equipped with Digital X-Ray (500 mA), Fully Equipped Lab., E.C.G., Ultra Sound, Physiotherapy, Fitness Centre, OPD in all specialities, Dental, Homeopathy, Ayurvedic, Indoor, Modular OT with C-Arm, General & Lap Surgery, Ortho, ENT, PHACO Eye Surgery, Birthing Suites etc.

D-BLOCK, ASHOK VIHAR-I, DELHI-110052 TEL.: 27129193-96 FAX : 011-27417494

8 of 8
6/9/19

PM 7 T m an

neu +1.5 m mb
Ⓢ

Name of the patient: ...
No. 81718
ASHOK VIHAR
AGARWAL
Hospital

Dr

2 DEC 2018

V T Ⓢ

sch.

Headache
Friday

sc @ depth

Steam tubular

of neck to, on operation

Post op
neu

7 AUG 2019

US/F

wants neighbor
Bx ↓ Control
to Genes

V - 6/6/8
of an

sch.

def + see insertion ↓ 7/1/19

neu mb. bilat -

+1.5/1.0 + 0.50 x 1.42

+1.25/1.00 + 0.75 x 1.67

Central
chem. uterine
patches
Ful
Sunkester
on a cupping
neu

PM 7 Friday 3:00 am

14/8/19

PM 7

+1.0/1.0 + 0.50 x 1.70 616

neu add +1.75 m mb.

Ⓢ
Exerting
viewing

Dr