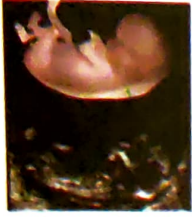
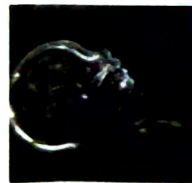



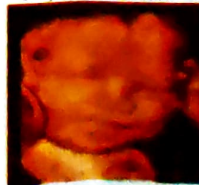Patient Name	Mrs. Jyotsna	Date of Examination	07.11.2020
ID No.	0711202004	LMP	11.08.2020
Age	30Yrs	POG by LMP	12wks 04d
Referred By	Dr. Yuthika Bajpai	EDD by LMP	11.08.2020
USG Performed by	Dr. Ruchika Sood(Puri)	GA by 1 st USG	12wks 04d
Technical conditions/Visibility	Average	GA by Current scan	(12wks 04d by CRL)
Method	Trans abdominal	No. of Fetus	Single
Serum Screening	Not done	Indication	NT/NB Scan
Blood Group	O+ve	High risk factors	NAD
DIAGNOSIS	Primi	Blood Pressure	133/77mmHg



2D Ultrasound



3D, 4D / HD Live



- Single live intrauterine fetus seen .
- CRL measures 60.1mm (12 weeks 04 days).
- Fetal Cardiac activity (145 bpm) is well visualized
- Placenta is forming Posteriorly.
- Liquor seems to be adequate for gestational age.
- Nasal bone is visualized.
- Nuchal translucency measures 1.7mm (55th centile).
- Ductus venosus -normal wave form seen. No reversal of a wave seen .
- Bilateral uterine arteries normal wave form seen. Right PI-1.62, Left PI-1.93, Mean PI-1.7 (50th -95th centile) normal.
- Internal Os is long closed.

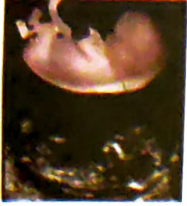

Note : This report is to help for better patient management. No compensation liability stands.

NOT FOR MEDICO LEGAL PURPOSE



SAVE THE GIRL CHILD



FETAL BIOMETRY

Measurements	cm	weeks	Percentile
Biparietal diameter(BPD)	1.88	12wks 06d	40.4%
Head Circumference(HC)	7.27	13wks	36.1%
Abdominal circumference(AC)	5.86	12wks 05d	64.5%
Femur Diaphysis length (FDL)	0.92	12wks 05d	49.9%
Estimated Fetal weight	63+/-9 gms (34.1%)		

Declaration:

I, Dr. Ruchika Sood(Puri) declare that while conducting ultrasonography on the patient (Mrs. Jyotsna),I have neither detected nor disclosed the gender of the fetus to anybody in any manner. Please also note that all congenital anomalies cannot be detected by ultrasound.

Dr. Ruchika Sood (Puri)

IMPRESSION: Single live intrauterine pregnancy of 12 wks 04 days.

Dr. Ruchika Sood(Puri)

DGO, DNB (OBG), MNAMS

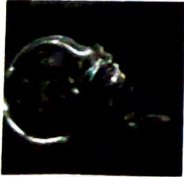PDCC (Maternal &Fetal Medicine SGPGI Lucknow

UK-Fetal Medicine Foundation Accreditation(NT Scan)

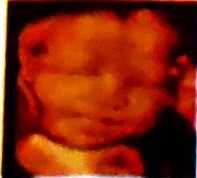
Advice: Correlation with Combined First Trimester Screening(CFTS)

:Level II scan 18-20wks

2D Ultrasound



3D, 4D / HD Live



Note : This report is to help for better patient management. No compensation liability stands.

NOT FOR MEDICO LEGAL PURPOSE



SAVE THE GIRL CHILD