



PANDIT DEEN DAYAL UPADHYAY DISTRICT HOSPITAL  
MORADABAD  
CIVIL LINES MORADABAD



UHDID:20190371410

CONSULTING ROOM NO : 3  
CLINIC: Medicine OPD TOKEN NO: 713  
DAYS: MON,TUE,WED,THU,FRI,SAT



OUT PATIENT RECORD

EHR ID :19000829005541160

Name: MR. ANIL KUMAR VASHISHTHA

Department: Medicine

Dept No.: 2019/051/0204394

Date of Registration : 06-11-2019 01:01:32 PM

Unit: UNIT-1

Billing Type: GENERAL

Mobile No.:

Address: MBD MORADABAD, UTTAR PRADESH, INDIA

Fees: ₹ 1

Sex: Male

S/O XXX

Age: 50Y

Email:

Occupation: OTHER

Patient Type: NON MLC Prepared

By: Mr. Hemant Verma

BP - 110

84

ORS (1)

Riblac (10)

ADU

ECG

R

Self Attested

23/11/2020

- ① ~~Tab. Sildenafil 2 mg~~  
~~Tab. Thiocinchilide 8 mg~~  
myonix 17.
- ② Tab. Neurotonforte
- ③ COK peridol 17.
- ④ Tab. Sumo 17.

self Attested

FORMERLY AT: Sir Ganga Ram Hospital, New Delhi | Neurology Department, K.G. Medical College, Lucknow  
Guru Teg Bahadur Hospital, Delhi | Kasturba Hospital, Delhi | K.P.S. Institute of Medicine, Rangpur

Shri Anil Kumar Vashishth

6.11.19  
6:30 PM

83g/m

q. Sudden onset sweating & weakness w LUL + LLL at 11:0 am

consulted Dist hospital  
↳ ECG + X-ray C spine | MSA DM ⊕

Δ CVA - Ischemic stroke  
(Anterior Rt side of Pons)

Doc

Isospinalgia

in

Multispecificity Isospinalgia

self attached

BP 140/80  
Power weak in LUL + LLL  
Asterix with eyes  
in mild form

Doc  
MRE Brain  
Ant 2/ant Rt side of Pons

Doc  
MRA-Neck  
MSA

TIMINGS: 10:00 a.m. to 6:00 p.m.  
Sunday Closed, Valid for 7 days only  
No home Visit

B-60, Gandhi Nagar,  
Moradabad-244001  
Ph.: +91 591-2494948/9837590764

APPOINTMENT: One day before only on the phone  
Timings: 4:00 p.m. to 6:00 p.m.  
Ph.: 9917994948, 9917991948

FACILITIES: 32 channels digital Electroencephalogram (EEG)/ Video EEG with Brain Mapping | Electromyography (EMG)  
Nerve Conduction Studies (NCV/NCS) | Somatosensory Evoked Potential (SSEP) | Visual Evoked Potential (VEP)  
Auditory Evoked Potential (BAEP/BERA) | Cognitive Evoked Potential (P300)

A UNIT OF MOHAN X RAYS & CAT SCAN CENTRE (P) LTD.

# MOHAN ADVANCE DIAGNOSTIC CENTRE

## MOHAN X-RAYS

## MOHAN PATHOLOGY LAB

## 1.5 TESLA M.R.I.

## 16 SLICE CT SCAN



DIGITAL & PLAIN X-RAY, ULTRASOUND, COLOUR DOPPLER & PATHOLOGY

4-14, Gandhi Nagar, Opp. City Station, Near Roadways Bus Stand, Rampur Road, Moradabad-241001

Phone: 9219558663, 9219558664

Timing: Monday to Saturday 9:00 AM to 8:00 PM, Sunday 9:00 AM to 2:30 PM

Dr. Ram Mohan Agarwal

Dr. (Mrs.) Rekha Agarwal

Dr. Rajat Agarwal

M.B.B.S., F.C.G.P., F.I.C.N., D.M.R.E. (Gold Medalist)

M.B.B.S., D.G.O., P.G.D.C.P., M.F.U.S.M.B.

M.B.B.S., M.D. Pathology

M.R.I.A., M.I.C.R., M.F.U.S.M.B. (Radiologist & Sonologist)

SENIOR C.T., M.R.I. & U.S. SPECIALIST

Professionally Trained AT: S.G.P.G.I (Lucknow)

P.G.I (Chandigarh), A.I.I.M.S., M.A.M.C. (Delhi)

J.K. Institute of Radiology & Cancer Research (Kanpur)

Dr. (Mrs.) Priya S. Agarwal

M.D. Pathology

NAME :- MR. ANIL KUMAR VASHISTH AGE/SEX. 53YRS/M.

REF.BY:-DR. TARUN AGARWAL MD, DM

DATE:- 6.11.2019

### MRI BRAIN

Multiplanar MR imaging of the cranium was done on a 1.5 TESLA MACHINE using a dedicated head coil. T1, T2 weighted, T2 FLAIR, diffusion & Gradient images were obtained in axial, coronal and saggital plane.

- ILL-defined areas of restricted diffusion is seen in right side of pons, measuring about 9x7mm in size. The lesion is iso on T2/FLAIR images.
- Both cerebral hemispheres appear normal in intensity else where.
- Bilateral thalami, basal ganglia, internal capsular & external capsular region appear normal in intensity and gray white matter differentiation.
- Cerebellum, mid brain and medulla appear normal in intensity with normal gray matter differentiation.
- Illrd, IVth and both lateral ventricles appear normal in configuration and intensity with midline septum.
- Cerebellar folia, basal cisterns, fissures, other sulci and supra-arachnoid spaces appear normal in configuration and intensity.
- Sella and parasellar regions are normal.

**IMPRESSION:-** These findings are suggestive of early developing infarct in right side of pons.

**Advised:-** Further investigations, if needed.  
Thanks for referral.

*Rajat*  
DR. RAJAT AGARWAL  
M.D. Radiodiagnosis  
Consultant Radiologist

DR. RAM MOHAN AGARWAL  
M.B.B.S., F.C.G.P., F.I.C.N., D.M.R.E.  
Radiologist( Gold Medalist).

*self Attested*

**NOTE** • These Findings should always be considered in correlation with the Clinical and other investigation findings.  
• Discourage Sex Determination to Stop Female Feticide. • NOT FOR MEDICOLEGAL PURPOSE  
• Please don't leave the films exposed to Sunlight

A UNIT OF MOHAN X RAYS & CAT SCAN CENTRE (P) LTD.

# MOHAN ADVANCE DIAGNOSTIC CENTRE

## MOHAN X-RAYS

## MOHAN PATHOLOGY LAB

## 16 SLICE CT SCAN



DIGITAL & PLAIN X-RAY, ULTRASOUND, COLOUR DOPPLER & PATHOLOGY

A-14, Gandhi Nagar, Opp. City Station, Near Roadways Bus Stand, Rampur Road, Moradabad-244001

Mob.: 9219558663, 9219558664

Timing : Monday to Saturday 9:00 AM to 8:00 PM, Sunday 9:00 AM to 2:00 PM

Dr. Ram Mohan Agarwal

Dr. (Mrs.) Rekha Agarwal

Dr. Rajat Agarwal

M.B.B.S., F.C.G.P., F.I.C.N., D.M.R.E. (Gold Medalist)  
M.R.L.A., M.I.C.R., M.I.F.U.S.M.B. (Radiologist & Sonologist)  
SENIOR C.T., M.R.I. & U.S. SPECIALIST  
Professionally Trained AT: S.G.R.G.I (Lucknow)  
R.G.I (Chandigarh), A.L.L.M.S., M.A.M.C. (Delhi)  
J.K. Institute of Radiology & Cancer Research (Kanpur)

M.B.B.S., D.G.O., P.G.D.C.P., M.I.F.U.S.M.B.

M.B.B.S., M.D. (Radiodiagnosis)

Dr. (Mrs.) Priya S. Agarwal

M. D. Pathology

NAME:- MR. ANIL KUMAR VASHISTH AGE/SEX. 53YRS/M

REF.BY:-DR. TARUN AGARWAL MD, DM

DATE:- 6.11.2019

### MR ANGIOGRAPHY NECK VESSELS

MR angiogram was obtained using a 2D TOF sequence using both venous and arterial saturation by 1.5 TESLA.

- Bilateral common carotid arteries & internal carotid arteries appears normal.
- The Brachiocephalic, & Subclavian arteries demonstrate a normal take off from the arch of aorta. No evidence of any narrowing is seen.
- Vertebral & basilar arteries appear normal.

IMPRESSION: No significant lesion seen.

Advised:-Further investigations, if needed.  
Thanks for referral.

*Rajat*  
DR. RAJAT AGARWAL  
M.D. Radiodiagnosis

DR. RAM MOHAN AGARWAL  
Consultant Radiologist

*self Attended*

- NOTE** • These Findings should always be considered in correlation with the Clinical and other Investigation findings.
- Discourage Sex Determination to Stop Female Feticide.
  - NOT FOR MEDICOLEGAL PURPOSE
  - Please don't leave the films exposed to Sunlight

**Sri Sai Hospital, Moradabad**

Department of Neurological Medicine

**DISCHARGE SUMMARY**

SSH/GEN/FR/28  
 Issue No. I Rev. 0 02.09.2017

Blood Group : B Positive

MLC NO:

Allergies :

Date of Admission: 6-Nov-19 Discharge 8-Nov-19 UHID No.: 139460/ 2019 IPD No.10676 /2019  
 Date of Procedure 1) 2) WARD : PW

**PATIENT INFORMATION**

Patient Name : MR. ANIL KUMAR VASHISHTH Age : 53 yrs Sex: M  
 S/o D/o W/o : MR. CHANDRABHAN VASHISHTH  
 Address : PURANA RTI OFFICE J2 JJJ COMPOUND  
 City : MORADABAD State : U.P. PIN : Contact Numbers :  
 Phone No. or Mobile No. : 9837385336

Consultant Incharge : Dr Anand Singh MBBS, MD, DM  
 Department : Neurological Medicine

Other Consultant involved : Dr Upmanyu Singh D.A.  
 Department : Critical Care

Other Consultant involved : Dr None  
 Department : None

DIAGNOSIS: AIS (RIGHT PONTIVE) (ICDX CODE-I63.9) WITH ? RES (ICDX CODE-I63.9)

Treatment/ Operation done: Conservative Treatment Given. *R/S*

Presenting History: Patient presented in casualty with C/O-Dizziness , Left side weakness since tday approx 11:00pm.

Examination : BP-110/70mmhg ,Pulse-72/ min,Temp- Normal,SPO2- 99%, CNS- Conscious, CVS-S1S2 -N.,Chest-B/L-Clear,P/A-Soft

*self AH-19*

TLC (Per cu mm)	6830				
DLC (N,L,E,B,M)	63.0/29.6/ 3.1/3.7				
GBP(mcv/mch/mchc)					
PCV					
Platelets (Lacs/ cu mm)	1.39				
ESR					
B. Sugar ;Random :Fasting/ PP (mg/ dL)	124.0				
S.Sodium ( meq/ L)	141.1				
S. Potassium (meq/ L)	3.92				
B. Urea (mg/ dL)	20.4				
S. Creatinine (mg/ dL)	1.08				
S.Calcium					
S. Uric Acid					
PO4					
ALP					
S. Bilirubin (mg/ dL)					
SGOT					
SGPT	46.9				
Prot.					
Alb.					
PT/INR	14.0 13.0 1.07 1.07				
BT					
CT					
HBsAg	Non-reactive				
HCV	Non-reactive				
HIV	Non-reactive				

X-Rays: NONE

USG: NONE

CT: NONE

MRI: 6-Nov-19 BRAIN:-Early developing infract in right side pons.

Other Investigations: HbA1C-6.40, eAG-137.0, HOMOCYTINE-12.03 (07/11)  
APPT-36.0/30.0 (06/11)

*self Attended*

Course in Hospital: Patient presented in casualty with C/O-Dizziness , Left side weakness since tday approx 11:00pm. Patient shifted to CCU for observation.All conservative treatment & management given with antibiotics, other supportive medicines & IV fluids .Patient gradually responded to treatment.Now patient being discharged with follow up advise.

EDIC  
GGY (D.  
TANT NEURO

**Advice at Discharge:**

**DIET AS ADVISED**

- TAB.ECOSPRIN 150mg 24Hrly
- TAB.ATORVA 80mg 24Hrly ✓
- TAB.FOLIC ACID 5mg 24Hrly ✓
- TAB.STROCIT PLUS 12Hrly
- CAP.RABENAC-DSR 24Hrly.(BBF) ✓
- TAB.GABAPIN-NT 100mg 1/2 tab 24Hrly.(2 Days)
- TAB.ROPARX 0.25mg 24Hrly ✓
- TAB.PETRIL 0.25mg SOS.(For sleep)
- CALCIROL SACHET TWICE WEEK
- CAP.NUROBION FORT 24Hrly

**PHYSIOTHERAPY AS ADVISED**

**BALANCING EXERCISE**


**ADVISED TEE MR ANGIO BRAIN VESSELS.**

**REVIEW AFTER 5 DAYS IN OPD DR. ANAND SINGH.(9997764545)**

**Neurovision clinic, Near Old Roadways Gandhi nagar (Basement in BOB)MBD.**

**In case emergency please contact hospital emergency service(24hours)@ 0591-2479800.**

**Consultant - in - Charge**



**(Dr Anand Singh MBBS,MD,DM**

**Department of Neurological Medicine**

**NOTE: THIS IS AN IMPORTANT DOCUMENT,PLEASE KEEP THIS FOR FURTHER REFERENCE AND BRING ON YOUR NEXT VISIT**

**SRI SAI HOSPITAL**

**Mansarovar Colony, Delhi Road, Moradabad-244001(U.P.)**

**Tel. Phone : (+91) - 591- 2479800. Fax : (+91) - 591- 2481720**

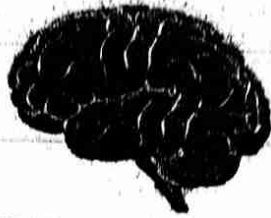**E - Mail : [srisaihospital@rediffmail.com](mailto:srisaihospital@rediffmail.com). Visit us at : [www.srisaihospital.com](http://www.srisaihospital.com)**

**Hari Nair**

*Self Attested*  




and Singh



डॉ. आनन्द सिंह

Neurophysician  
MEDICINE (KGMG, LUCKNOW)  
NEUROLOGY (DR. RMLH, DELHI)

कन्सल्टंट न्यूरोफिजियन  
एम.बी.बी.एस., एम.डी. मेडिसिन (के.जी.एम.पी., इलाहाबाद)

डी.एम. न्यूरोलॉजी (डीओ आर.एम.एम.एम., दिल्ली)

भारतीय चिकित्सा संघ :

CONSULTANT NEURO-PHYSICIAN, PUSHPANJALI CROSSLEY  
SRINAGAR CHARIAPAD  
NEURO-PSYCHOLOGICAL CLINIC, DELHI  
NEURO-PSYCHIATRY CLINIC, DELHI

कन्सल्टंट न्यूरोफिजियन, गुवाहाटी कनिष्ठ चिकित्सक, गुवाहाटी  
कनिष्ठ चिकित्सक, गुवाहाटी  
कनिष्ठ चिकित्सक, गुवाहाटी  
कनिष्ठ चिकित्सक, गुवाहाटी

name MR. ANIL K. VASHISHTH Referred by ..... Age/Sex 53/M Date 13/11/19

This is to certify that Mr. Anil K. Vashisht  
53/M, s/o R/O  
is suffering from CVA (Rt Posture Defant)  
+ RLS (Restless leg synd) + Dyslipidemia.  
He is on treatment since 6/11/19, he requires  
treatment for longer period for his illness.  
+ physiotherapy.

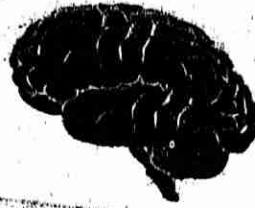*[Handwritten Signature]*

ANAND SINGH  
NEUROLOGIST  
KGMG-40829

self Attested  
*[Handwritten Signature]*

And Singh

Neurophysician  
D. MEDICINE (K GMC, LUCKNOW)  
ROLOGY (DR. RMLH, DELHI)



डॉ. आनन्द सिंह

कन्सलटेंट न्यूरोफिजिशियन  
एम.बी.बी.एस., एम.डी. मेडिसिन (के.जी.एम.सी., लखनऊ)  
डी.एम. न्यूरोलॉजी (डा० आर.एम.एल.एच., दिल्ली)  
भूतपूर्व चिकित्सक।

Consultant Neuro Physician, Pushpanjali Crossley  
Hospital, Ghaziabad

Name: MR. ANIL KUMAR VASHISHTH  
Referred by

Age/Sex: 53/4 / M Date: 13/11/19

Acute Ischemic Stroke  
C RAS (Rt PONTINE)  
C Dyslipidemia

MR. Prasad  
Rt Pontine  
Referred

- 1) Cop. Bleegine A (75) 100 ✓
- 2) Y - Atova (80) 100 ✓
- 3) T. P-A (50) 100 ✓
- 4) Cop. Rabett DRK low ✓
- 5) T. gabapin NT 100 ✓
- 6) T. Repath (0.5) 100 ✓

- Hb - 12.6
- Tc - 6730
- P63
- PC - 139
- RAS - 124
- Na - 14/3-92
- Urea - 20/1-08
- SGPT - 46-9
- DMR - 107
- visual acuity
- HbA1c - 6.4
- Homocysteine - 12.03

self Attended

MR. Anjo Benu  
Venu

(C)

- ELKO
- NO RNA
- EF - 60.3%
- J. chol - 181
- TGS - 197
- HDL - 28.5
- LDL - 112
- TMM - 3.15

- (C) ref. D-gu / dwo
- (C) γ - cere top 1M
- (C) ref. peroxidase

pleurotic /  
Racine /  
Esceer /  
Code

- Ado
- Trans aetophagal
- ELKO
- MR. Anjo Benu

26/4/19

- consulted Cardiology
- Apallo Hospital
- (C) Ado - P. Apraban
- (C) - I. Hona

- (C) P. P. A. (110)
  - (C) γ - gotake RT 1M
  - (C) γ - Pcpal (0.5 M)
  - (C) ref. peroxidase 100
- self Attached

215 de

DR. ANAND SINGH  
DM NEUROLOGY  
NEUROLOGICIAN  
MORARJI, DMC-40829

A UNIT OF MOHAN X RAYS & CAT SCAN CENTRE (P) LTD.

# MOHAN ADVANCE DIAGNOSTIC CENTRE

## MOHAN X-RAYS

## MOHAN PATHOLOGY LAB

### 16 SLICE CT SCAN

### 1.5 TESLA M.R.I.



DIGITAL & PLAIN X-RAY, ULTRASOUND, COLOUR DOPPLER & PATHOLOGY

A-14, Gandhi Nagar, Opp. City Station, Near Roadways Bus Stand, Rampur Road, Moradabad-244001  
Mob.: 9219558663, 9219558664 Timing : Monday to Saturday 9:00 AM to 8:00 PM, Sunday 9:00 AM to 2:00 PM

**Dr. Ram Mohan Agarwal**  
M.B.B.S., F.C.G.P., F.I.C.N., D.M.R.E. (Gold Medalist)  
M.R.I.A., M.I.C.R., M.I.F.U.S.M.B. (Radiologist & Sonologist)  
SENIOR C.T., M.R.I. & U.S. SPECIALIST  
Professionally Trained AT: S.G.P.G.I (Lucknow)  
P.G.I (Chandigarh), A.I.I.M.S., M.A.M.C. (Delhi)  
J.K. Institute of Radiology & Cancer Research (Kanpur)

**Dr. (Mrs.) Rekha Agarwal**  
M.B.B.S., D.G.O., P.G.D.C.P., M.I.F.U.S.M.B.

**Dr. Rajat Agarwal**  
M.B.B.S., M.D. (Radiodiagnosis)

**Dr. (Mrs.) Priya S. Agarwal**  
M. D. Pathology

NAME MR. ANIL KUMAR VASHISHTA AGE/SEX 53YRS/M  
REF.BY:- DR. ANAND SINGH MD, DM  
DATE 15.11.2019

### MRA OF BRAIN.

MRA of the brain was done on 1.5 TESLA MRI MACHINE.

- All intracranial vessels show normal course and calibre.
- There is no evidence of aneurysm or AV malformation.
- No stenosis or occlusion of any vessel is seen.
- There is no displacement of any vessel.

IMPRESSION: - No significant lesion seen.

Advised:- Further investigations, if needed.  
Thanks for referral

*Rajat*  
DR. RAJAT AGARWAL  
M.D. Radiodiagnosis

DR. RAM MOHAN AGARWAL  
Consultant Radiologist

*self Attested*  
M

**NOTE** • These Findings should always be considered in correlation with the Clinical and other Investigation findings.  
• Disourage Sex Determination to Stop Female Feticide. • NOT FOR MEDICOLEGAL PURPOSE  
• Please dont leave the films exposed to Sunlight



Teerthanker Mahaveer University

**TEERTHANKER MAHAVEER MEDICAL COLLEGE & RESEARCH CENTRE**

Delhi Road, Moradabad, UP, India, 244001

Ph: 0591-2360000,2360555,2360777

**TRANS-ESOPHAGEAL ECHO REPORT**

Date: 16.11.2019

CR NO: I911160647

DEPARTMENT: CARDIOLOGY

NAME OF THE PATIENT:

MR. ANIL KUMAR

AGE/SEX: 53 Y / M

CONSULTANT INCHARGE:

Dr. Geetesh Manik M.D., D.M, DNB, (Cardiology- CMC Vellore)

Impression

16x9 mm LAA clot present.

- 16x9 mm LAA clot present. LAA velocity < 25 cm/sec.
- Intact IAS /IVS, No PFO seen.
- Normal Biventricular Function.
- Trace AR.

ADVICE: OAC (NOAC).

SIGNATURE OF CONSULTANT

**Dr. Geetesh Manik**

MD., DM, DNB, (Cardiology- CMC Vellore)

Interventional Cardiologist

Mob. No: 09917400086

Self Affixed



# BATRA HOSPITAL & MEDICAL RESEARCH CENTRE OF CH. AISHI RAM BATRA PUBLIC CHARITABLE TRUST

1, Tughlakabad Institutional Area, Mehrauli Badarpur Road New Delhi - 110062  
Phone : 29958747, 29902001, 29903001, 29051280 Extn. 2039  
Emergency No. : 26053333, 29956885

## DEPARTMENT OF CARDIOLOGY

### TRANSESOPHAGEAL ECHO REPORT

Name	: Mr. Anil Kumar Vashishthi	D. No.	: 152829
Age/Sex	: 53 years / M	Date	: 22.11.19
Referring Diagnosis:		IPD/OPD	: OPD
Ref. by	: Dr. R.D. Yadave	Done by	: Dr. Swati

#### M Mode / 2 D Description

**Left Ventricle** : It is normal in size. No RWMA. Normal LV systolic function. EF 60%

**Left Atrium** : It is normal in size

**Right Atrium** : It is normal in size

**Right Ventricle** : It is normal in size. RV systolic function is normal.

**Inter-atrial septum** : It is intact. No shunt.

**Aortic valve** : Normal

**Mitral valve** : Normal

**Tricuspid valve** : Normal

**Ascending Aorta Root** : It is normal. No dissection, No atheroma.

**Pericardium** : There is no pericardial effusion.

#### COLOR FLOW :

Pulmonic Regurgitation : **NIL**

Mitral Regurgitation : **Nil**

Aortic Regurgitation : **NIL**

Tricuspid Regurgitation : **Nil**

#### COMMENTS:

- 9x5mm mobile left Atrial Appendage clot present.
- No clot in LA.
- All chambers normal sized.
- All valve are normal.
- Normal LV systolic dysfunction.

DR. R.D. Yadave  
SR. CONSULTANT CARDIOLOGY.

  
DR. Swati  
S / R CARDIOLOGY

*self Attested*

**ANIL MODI**

MD (Medicine), D.M. (Cardiology), FACC, FCSI, FICC, FISE  
Senior Consultant and Interventional Cardiologist  
Mobile : 9811043487 E-mail : skmnewdelhi@gmail.com

**DR. RANJAN MODI**

MD (Medicine), DM (Cardiology)  
Associate Consultant Cardiology  
Mobile : 9844917110 E-mail : modi.ranjan@gmail.com  
Indraprastha Apollo Hospital, Sarita Vihar, New Delhi-110076  
Tel. : 29871037, 29871080, 29871081  
Mon., Wed., Fri. : 10 a.m. to 1 p.m. Tue., Thur. : 2 p.m. to 5 p.m.



**HEART INSTITUTE**



Accredited by Joint Commission International

Office/Clinic :  
D/87, East of Kailash,  
New Delhi-110065  
Tel. : 26445668, 26476739  
Mob. : 8130958787, 8826546787

APD1.0011076710  
MR. ANIL KUMAR VASHISHTHA  
Age: 53 Year(s) Year(s)/Male  
22 Nov, 2019 9:57:52 AM



22.11.19

Δ CVA (cardioembolic)  
Lt Hemiparesis (6/11/19)

6th Nov, ↓  
Lt Hemiparesis  
NO H/O HT  
Allergic Rhinitis

O/E  
P - 84/MT  
BP - 132/82 mm  
CVS - WAD  
Lungs - clear  
Abd - Normal

Rx  
Continue

Diabetic diet  
Low fat

M O } (1) Tab Eliquis (5) BD  
N O }

(2) Tab Atorva - 80 OD

HbA1c - 6.4%

Echo - LAA clot, Normal LV function  
NO AF on Holter

(3) Rest as adv by Neurologist

→ NO diagnostic abn

✓ one week Holter - now (AF)  
→ ECG ✓ now, chest Xray PA view  
→ Dobutamine Echo after 2 weeks also to keep LA clot

Self Arterial  
40 2 wks



## OPD CONSULTATION

Patient Name MR. Anil Kumar Vashistha Age/Sex 53/M Regn. No. \_\_\_\_\_  
 Doctor's Name D. D. SINGHANA Date 8/11/19 Time \_\_\_\_\_

### 1. Nutritional Screening

Height.....Weight.....BMI.....

### 2. History : (Present / Past / Family)

RT pontine infarct.  
CAA clot.

No shunt.

Any Drug Allergy :

No allergy.

### 3. General Examination :

BP : Temp. : Pulse : R/R :

Pallor / Oedema / Koilonychia

### 4. Systemic Examination :

CVS :

CNS :

RS :

P/A :

Others :

Trans telephonic  
ECG monitoring.

5. Pain Score :



NO PAIN



MILD PAIN



MODERATE PAIN



SEVERE PAIN

### 6. Investigations Advised :

KFT. F-lipid profile CAT.

TMT.

24hr Holter  
Monitoring.

### 7. Provisional / Differential Diagnosis :

### 8. Treatment Advised :

- Tab Eliquis 1BD <sup>9am</sup> <sub>9pm</sub>
- Tab Dephate 757 1<sup>00</sup> after dinner
- Tab Rosedon 407 1<sup>00</sup> after dinner
- Tab Razo 207 1<sup>00</sup> PM

Follow up Due on.....

### Patient Education (Patient is briefed on the following)

Proposed Care Plan : Yes / No

Expected Outcome : Yes / No

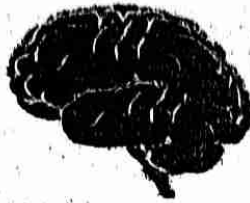Possible Complication : Yes / No

Name and Sign. of Doctor.....Name and Sign. of Patient/Attendant.....

Attested



**Anand Singh**



**डॉ. आनन्द सिंह**

Neurophysician  
M.D. MEDICINE (K GMC, LUCKNOW)  
NEUROLOGY (DR. RMLH, DELHI)

कमलदंड च्युरोफिजिशियन  
एम.बी.बी.एस., एम.डी. मेडिसिन (के.जी.एम.सी., लखनऊ)  
डी.एम. च्युरोलाजी (डा० आर.एम.एल.एच., दिल्ली)

Seniorly :  
CONSULTANT NEUROPHYSICIAN, PUSHPANJALI CROSSLEY  
HOSPITAL, GHAZIABAD  
SENIOR PHYSICIAN, GURMUKH HOSPITAL, DELHI  
SENIOR PHYSICIAN, PARAS HOSPITAL, GUJRANWALA

भारतीय चिकित्सक :

Name Shri AK Varshitha Referred by ..... Age/Sex 44 Date 22/11/19

This is to certify that Shri A.K. Varshitha had Acute Ischemic Stroke and was hospitalized for stroke management. In his TEE (Transoesophageal Echo), there is a clot in LAA. PT requires frequent visits and long treatment under my consultation and Cardiologist's Pt. should avoid long travelling and exertional activities. PT was advised for Bed rest from 6/11/19 to 22/11/19. PT can join his job now but has to follow the treatment properly as advised.

Dr. ANAND SINGH  
D.M. NEUROLOGY  
PHYSICIAN

Dr. ANAND SINGH  
D.M. NEUROLOGY  
NEURO PHYSICIAN  
DMC-40829

*[Handwritten signature and date 22/11/19]*



Teerthanker Mahaveer University

**TEERTHANKER MAHAVEER MEDICAL COLLEGE & RESEARCH CENTRE**  
Delhi Road, Moradabad, UP, India, 244001  
Ph: 0591-2360000,2360555,2360777

## TRANS-ESOPHAGEAL ECHO REPORT

Date: 06.03.2020

CR NO: 1911160647

DEPARTMENT: CARDIOLOGY

NAME OF THE PATIENT:

MR. ANIL KUMAR

AGE/SEX: 53 Y / M

CONSULTANT INCHARGE:

Dr. Geetesh Manik M.D., D.M, DNB, (Cardiology- CMC Vellore)

Impression

9x5 mm LAA clot present.

- > 9x5 mm LAA clot present. LAA velocity - 28 cm/sec.
- > Intact IAS /IVS, No PFO seen.
- > Normal Size Cardiac Chamber, Normal Biventricular Function.

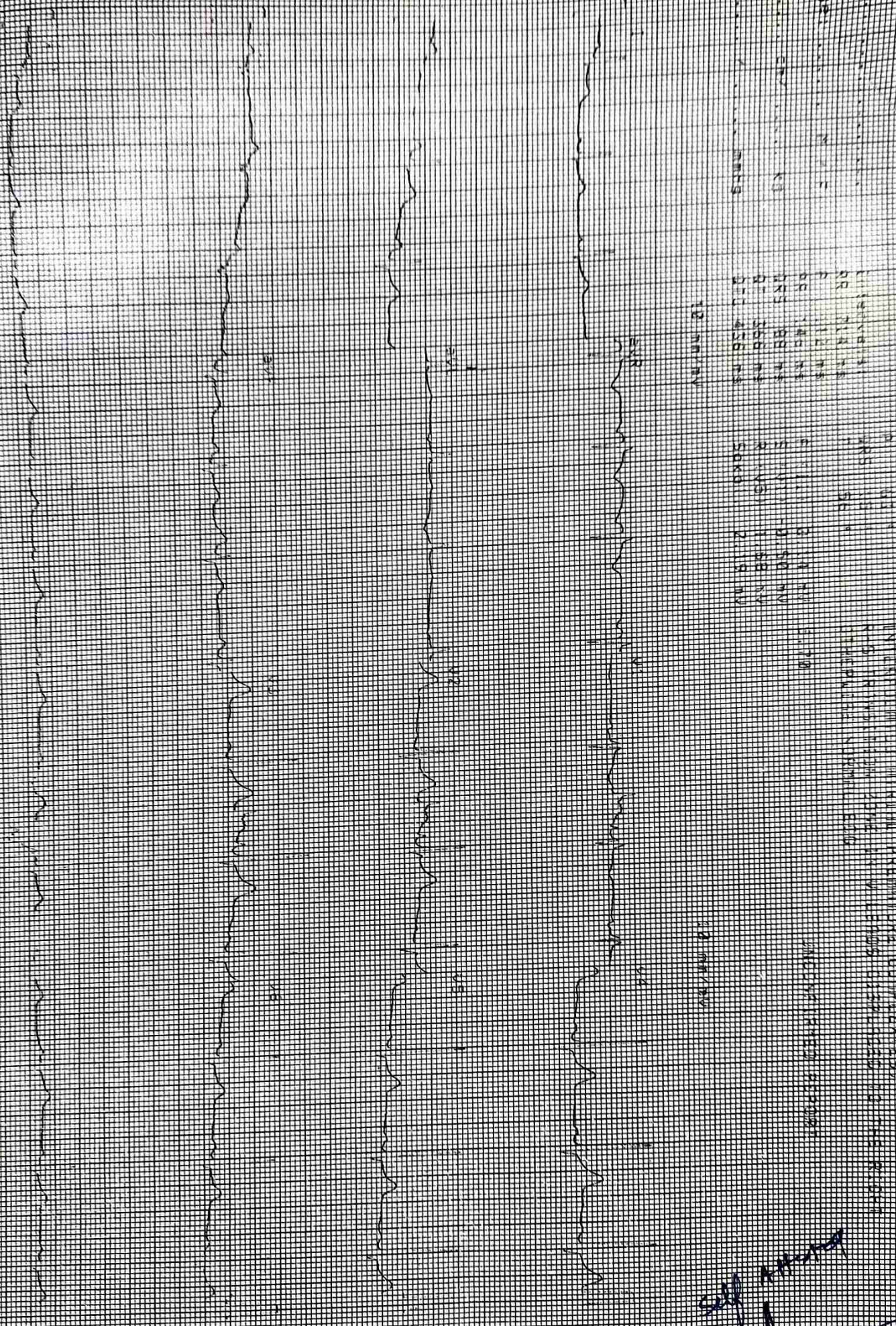
ADVICE: OAC (NOAC).

SIGNATURE OF CONSULTANT

**Dr. Geetesh Manik**

MD., DM, DNB, (Cardiology- CMC Vellore)  
Interventional Cardiologist  
Mob. No: 09917400086

*Self Attested*



LEAD	P	Q	R	S	T	QT	QTc
I	0.08	0.02	0.12	0.08	0.10	0.32	0.38
II	0.10	0.05	0.15	0.10	0.12	0.34	0.40
III	0.12	0.08	0.18	0.12	0.14	0.36	0.42
aVR	0.02	0.10	0.05	0.08	0.05	0.30	0.36
aVL	0.05	0.05	0.10	0.05	0.08	0.32	0.38
aVF	0.10	0.02	0.12	0.08	0.10	0.34	0.40
V1	0.05	0.10	0.05	0.08	0.05	0.30	0.36
V2	0.05	0.10	0.05	0.08	0.05	0.30	0.36
V3	0.05	0.10	0.05	0.08	0.05	0.30	0.36
V4	0.05	0.10	0.05	0.08	0.05	0.30	0.36
V5	0.05	0.10	0.05	0.08	0.05	0.30	0.36
V6	0.05	0.10	0.05	0.08	0.05	0.30	0.36

11/11/83

*[Handwritten signature]*  
11/11/83

# Anand Singh



Consultant Neurophysician  
MBBS, M.D MEDICINE (KGMC, LUCKNOW)  
DM NEUROLOGY (DR. RMLH, DELHI)

# डॉ. आनन्द सिंह

कन्सलटेंट न्यूरोफिजिशियन  
एम.बी.बी.एस., एम.डी. मेडिसिन (के.जी.एम.सी., लखनऊ)  
डी.एम., न्यूरोलॉजी (डॉ. आर.एम.एल.एच., दिल्ली)

Formerly :

- CONSULTANT NEURO PHYSICIAN, PUSHPANJALI COSSLEY HOSPITAL GHAZIABAD
- SENIOR RESIDENT GB PANT HOSPITAL, DELHI
- SENIOR RESIDENT PARAS HOSPITAL, GURGAON

भूतपूर्व चिकित्सक :  
कन्सलटेंट न्यूरोफिजिशियन, पुष्पांजलि कोसले हॉस्पिटल, गाजियाबाद  
सीनियर रेजीडेंट, जी.बी. पन्त हॉस्पिटल, दिल्ली  
सीनियर रेजीडेंट पारस हॉस्पिटल, गुरुगांव  
पूर्व चिकित्सक : टी.एम.यू., पाकबहा

पता: न्यूरोविज्ञान क्लिनिक, मेडिक कॉलेज रोड, बेल ऑफ गढ़ौदा के नीचे, निकट सिटी इमेजिंग सेंटर रोडवेज बस स्टैंड, रामपुर रोड, मुरादाबाद।

Name MR. A.K. VASISHTHA Referred by ..... Age/Sex 54/M Date 20/3/20

of cardioembolic  
stroke  
of atrial clot  
(on Anticoagulant)

1 + eliquas (Apixaban)  
(5) IM

2 + Atova (400 mg)

3 + rectolar (500 mg)

placed

Self Attested

# Anand Singh



Consultant Neurophysician  
 M.D MEDICINE (K GMC, LUCKNOW)  
 NEUROLOGY (DR. RMLH, DELHI)

# डॉ. आनन्द सिंह

कन्सल्टंट न्यूरोफिजियन  
 एम.बी.बी.एस., एम.डी. मेडिसिन (के.जी.एम.सी., लखनऊ)  
 डी.एम., न्यूरोलॉजी (डॉ. आर.एम.एल.एच., दिल्ली)

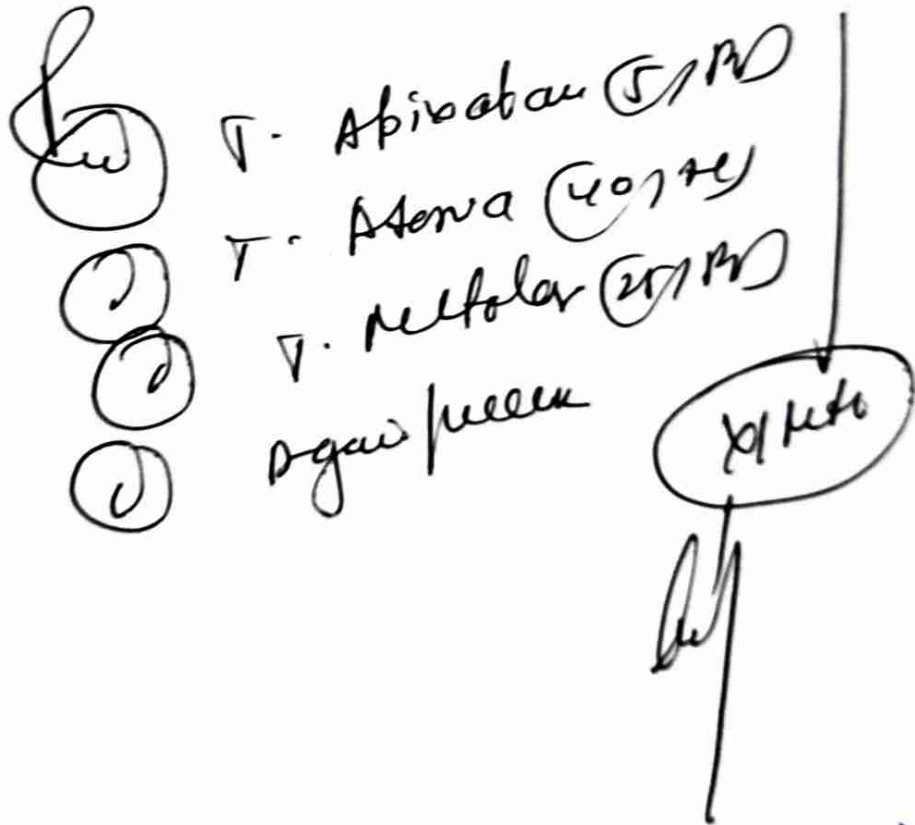
- Formerly :
- CONSULTANT NEURO PHYSICIAN, PUSHPANJALI COSSLEY HOSPITAL GHAZIABAD
  - SENIOR RESIDENT GB PANT HOSPITAL, DELHI
  - SENIOR RESIDENT PARAS HOSPITAL, GURGAON

भूतपूर्व चिकित्सक :  
 कन्सल्टंट न्यूरोफिजियन, पुष्पान्जलि कोसले हॉस्पिटल, गाजियाबाद  
 सीनियर रेजिडेंट, जी.बी. पन्त हॉस्पिटल, दिल्ली  
 सीनियर रेजिडेंट पारस हॉस्पिटल, गुरुग्रांव  
 पूर्व चिकित्सक : टी.एम.ए., पाकबरा

पता: न्यूरोलोजी क्लीनिक, रवि कॉम्प्लेक्स, बिक ऑफ बडीदा के नीचे, निकट सिटी हंगेजिंग सेंटर राउन्डेड बस स्टैंड, रामपुर रोड, मुगादाबाद।

Name MR. A.K. VASHISHTA Referred by \_\_\_\_\_ Age/Sex 41/M Date 30/5/20

- do ces (poutre)  
 c - U Atrial Clot  
 c - Dyslipidemia  
 c - PS.



Self Attached

# Anand Singh



# डॉ. आनन्द सिंह

Consultant Neurophysician  
 M.D MEDICINE (KGMC, LUCKNOW)  
 NEUROLOGY (DR. RMLH, DELHI)

कन्सल्टेंट न्यूरोफिजिशियन  
 एम.बी.बी.एस., एम.डी. मेडिसिन (के.जी.एम.सी., लखनऊ)  
 डी.एम., न्यूरोलॉजी (डॉ. आर.एम.एल.एच., दिल्ली)

- Formerly :
- CONSULTANT NEURO PHYSICIAN, PUSHPANJALI COSSLEY HOSPITAL GHAZIABAD
  - SENIOR RESIDENT GB PANT HOSPITAL, DELHI
  - SENIOR RESIDENT PARAS HOSPITAL, GURGAON

भूतपूर्व चिकित्सक :  
 कन्सल्टेंट न्यूरोफिजिशियन, पुष्पांजलि कोसले हॉस्पिटल, गाजियाबाद  
 सीनियर रेजिडेंट, जी.बी. पन्त हॉस्पिटल, दिल्ली  
 सीनियर रेजिडेंट पारस हॉस्पिटल, गुरुगांव  
 पूर्व चिकित्सक : टी.एम.यू., पाकबहा

पता: न्यूरोविजन क्लीनिक, रावे कॉम्प्लेक्स, बैंक ऑफ बडोवा के नीचे, निकट सिटी हार्मोजिंग सेंटर रोडवेज बस स्टैंड, रामपुर रोड, मुगदाबाद।

Name MR. ANIL KUMAR VASHISTHA Referred by ..... Age/Sex 54/M Date 30/9/20

Uo  
 Cardioembolic  
 Stroke (Partial)  
 - U Actual clot  
 - Dyslipidaemia  
 - PMS

Ch  
 Elevated  
 Palpitations  
 - phentolamine  
 - Metoprolol  
 - Aspirin  
 - Healed



Eligius (Abirabau)  
 Atova (Ug H)  
 Nebular (M) MD  
 cap. neurokind U  
 100

Selu  
 Holter  
 Monitoring  
 Transoesophageal  
 Echo  
 Cardiology  
 Specialist

XLH  
 Self Attended

# HOLTER REPORT

### Patient Details

Patient Name: **MR A.K. VASHISHTH**

ID: **000233**

Age: **54Years**

Gender: **Male**

Address:

Indications:

Medications:

DOB:

Recording Start: **10/10/2020 12:40**

Recorder: **122894**

Pacemaker:

Opr. Doc.: **Dr. Akhil Kaushik, M.D, D.M (Cardiolog**


Physician: **Dr. Anand Singh, M.D, D.M (Neuro)**

### Summary

<u>General</u>		<u>Heart Rate</u>		<u>Heart Rate Variability</u>	
Length(hh:mm):	<b>23:59</b>	Average:	<b>92</b>	SDNN:	<b>153</b>
Total beats:	<b>132233</b>	Min. HR:	<b>66/4:14</b>	SDNN Index:	<b>56</b>
Paced beats:	<b>0</b>	Max. HR:	<b>130/1:00</b>	rMSSD:	<b>99</b>
VE beats:	<b>0</b>	Min. HR-Minute:	<b>66/4:14</b>	pNNS50:	<b>3</b>
SVE beats:	<b>(&lt;1%)3</b>	Max. HR-Minute:	<b>125/18:50</b>	Triangle:	<b>99</b>
BBB beats:	<b>0</b>	# beats in Tachy(>120bpm):	<b>2.8% 3686</b>	HF:	<b>153.7</b>
Aberrant beats:	<b>0</b>	# beats in Brady(<50bpm):	<b>0</b>	LF:	<b>223.7</b>
% of total time in AF/AFL:	<b>0</b>	Longest R-R:	<b>-</b>	VLF:	<b>666.8</b>
<u>Ventriculars</u>		<u>Supraventriculars</u>		<u>Pause</u>	
Isolated:	<b>0</b>	Isolated:	<b>3</b>	Pauses in excess of 2.0 s	<b>0</b>
Couplets:	<b>0</b>	Couplets:	<b>0</b>	Longest Pause:	<b>0</b>
Bigeminy:	<b>0</b>	Bigeminy:	<b>0</b>	<b>QT</b>	
Trigeminy:	<b>0</b>	Trigeminy:	<b>0</b>	Max. QT:	<b>593</b>
Runs:	<b>0</b>	Runs:	<b>1</b>	Max. QTc:	<b>492</b>
Longest runs:	<b>3/12:14</b>	Longest runs:	<b>3/22:00</b>	Avg. QT:	<b>324</b>
HR of max. HR runs:	<b>38bpm/12:14</b>	HR of max. HR runs:	<b>160bpm/22:00</b>	Avg. QTc:	<b>399</b>
HR of min. HR runs:	<b>38bpm/12:14</b>	Length in AF/AFL:	<b>0</b>		
		<u>ST1</u>	<u>ST2</u>	<u>ST3</u>	
Total ST minutes:		<b>0</b>	<b>0</b>	<b>0</b>	
Maximum ST depression:		<b>0</b>	<b>0</b>	<b>0</b>	
Maximum ST elevation:		<b>0</b>	<b>0</b>	<b>0</b>	

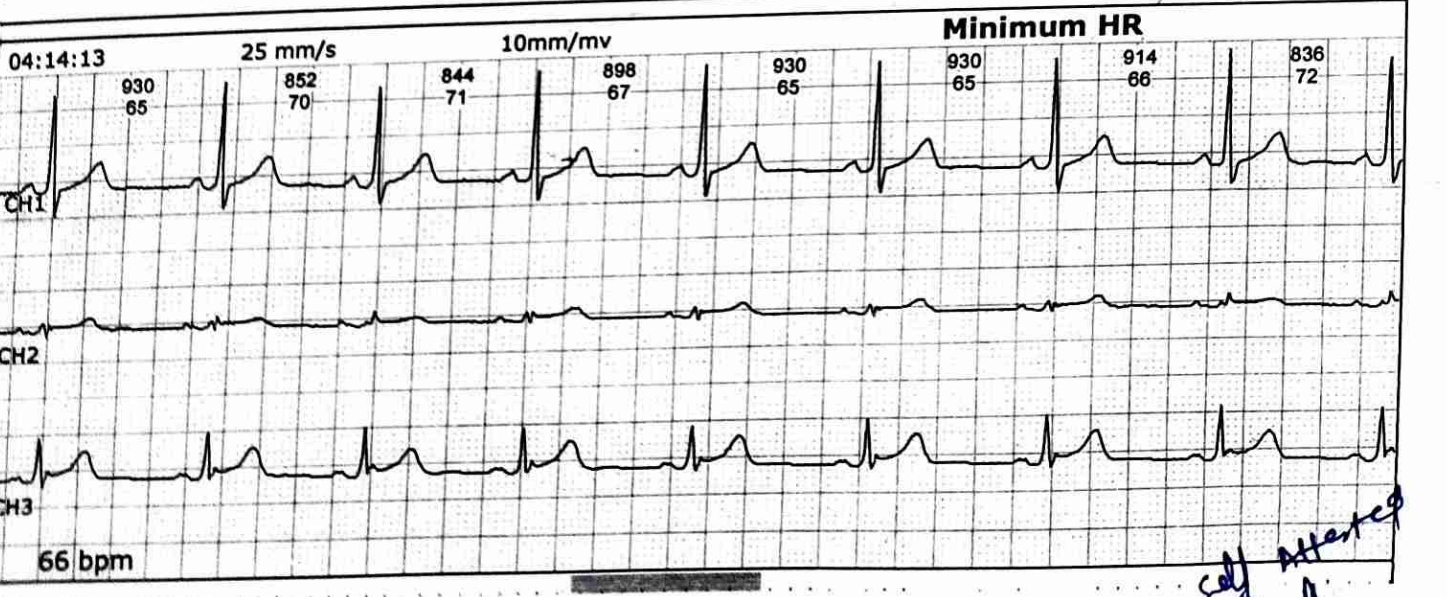
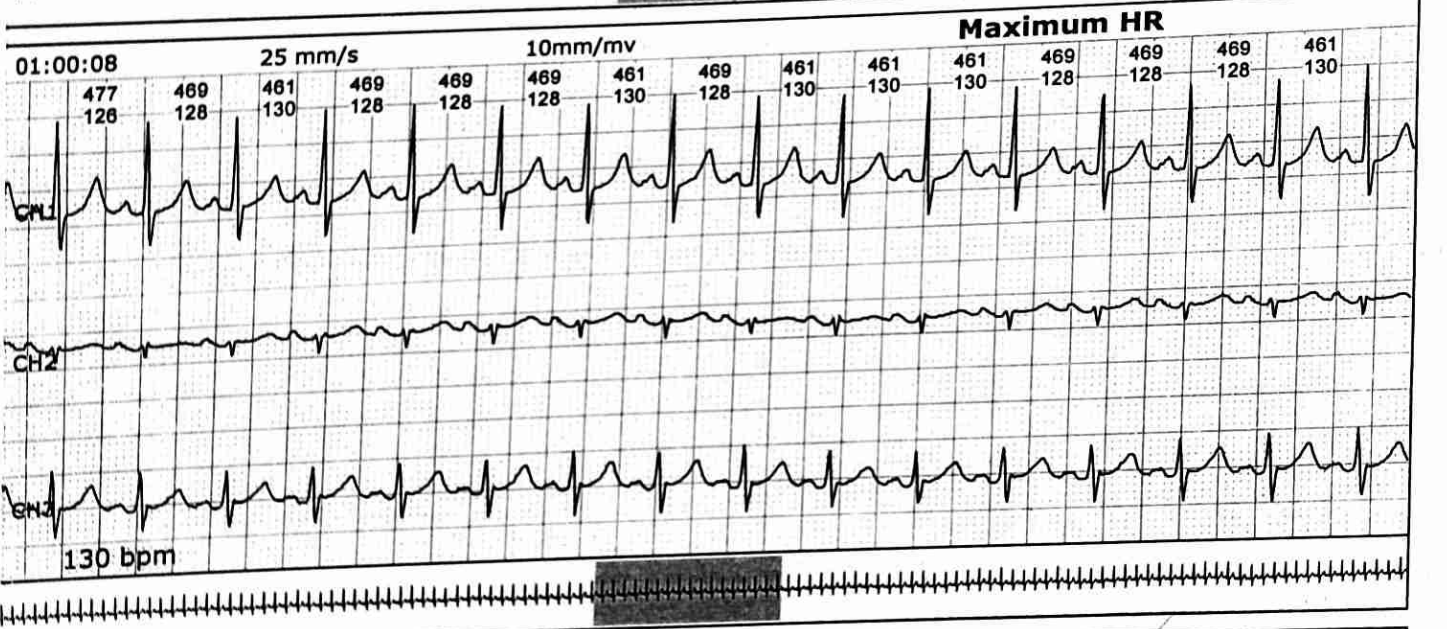
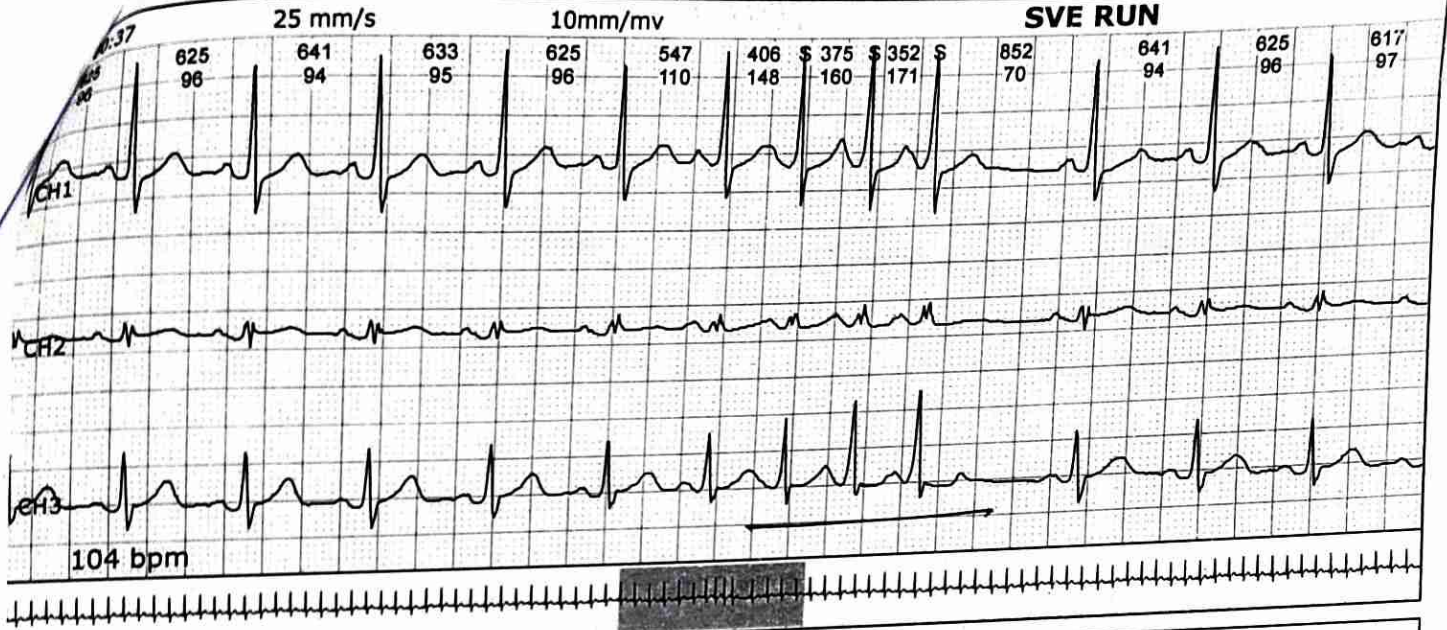
### Conclusion

Total recording time was: 23:59 hours. Average Heart Rate is 92 bpm, Minimum HR is 66 bpm at 04:14 and Maximum HR is 130 bpm at 01:00. There were 0 pause(s) > 2.0 seconds. Total of VE is 0, there were 0 VE runs and 0 pairs, there were 0 bigeminy events and 0 trigeminy events. Total of SVE is 3 and there were 1 SVE runs. ~~Total length of AFib/AFLut is 0 seconds.~~ Total length of ST events is 0 seconds. Very short SVE run noted (?AF), Patient remained asymptomatic during whole study.

  
 self Attest

Signed: \_\_\_\_\_

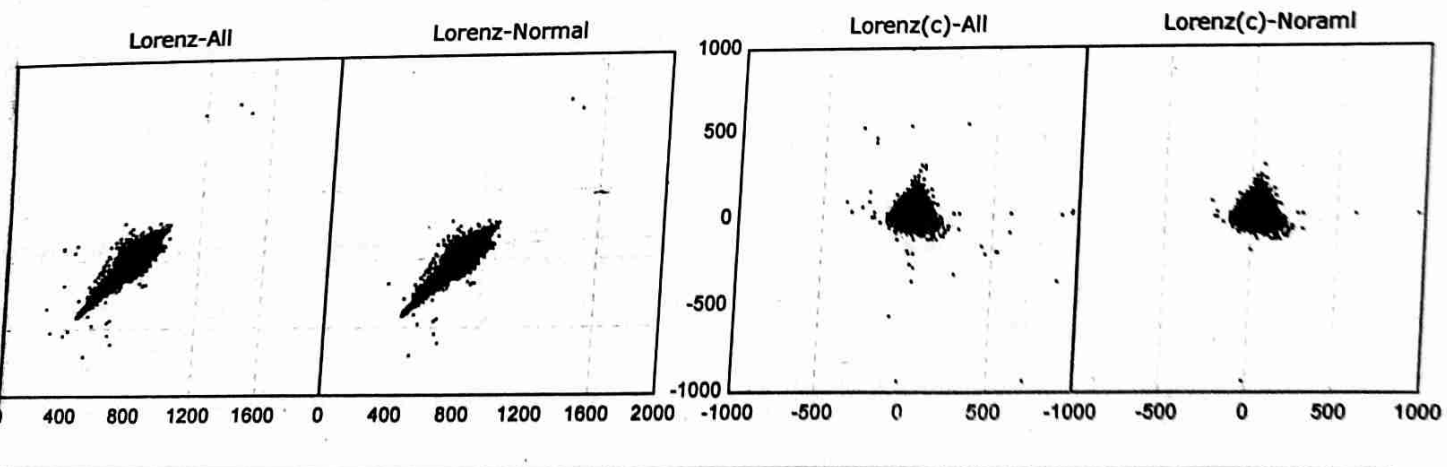
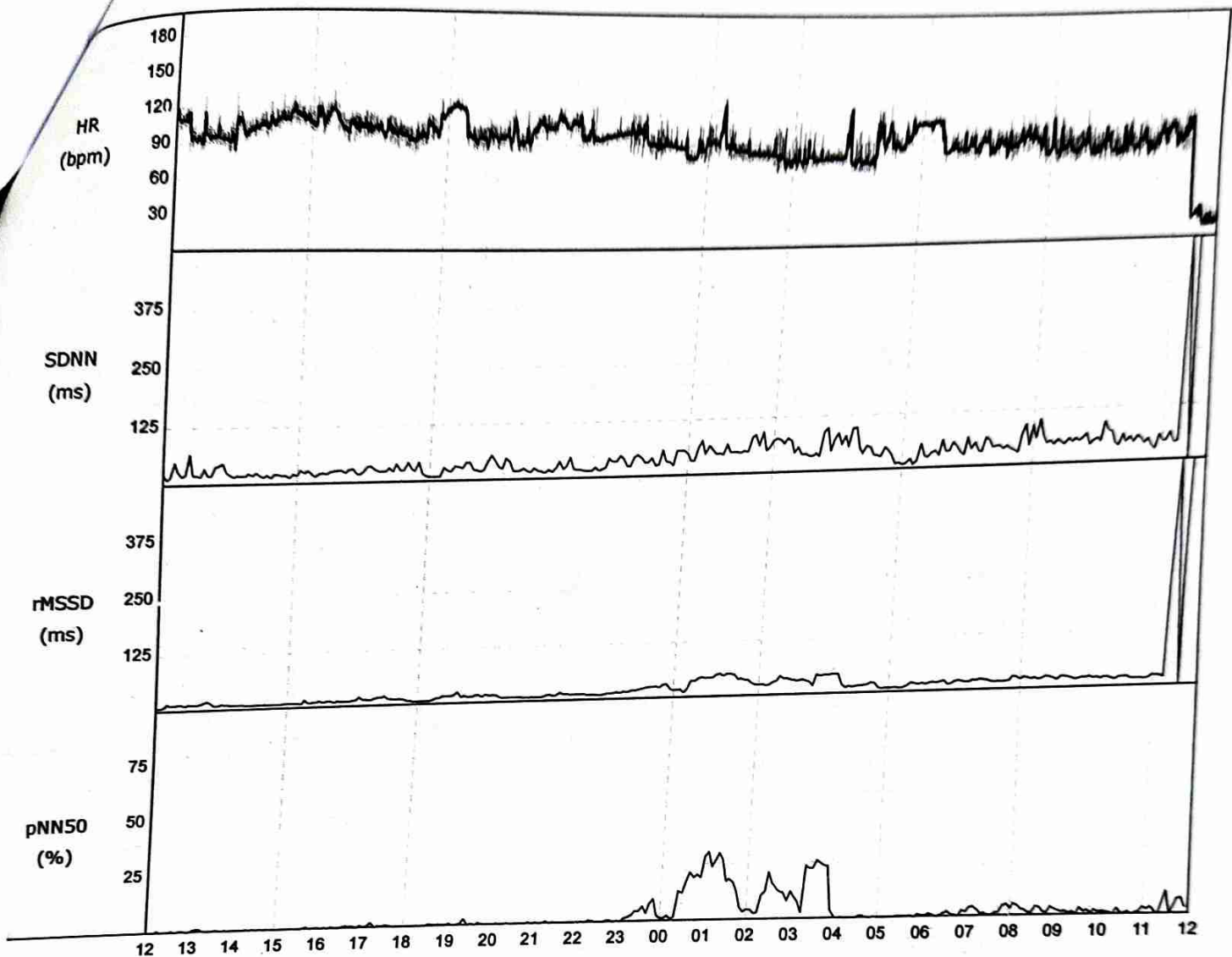
### Full-Sized Strips



*Self Attended*



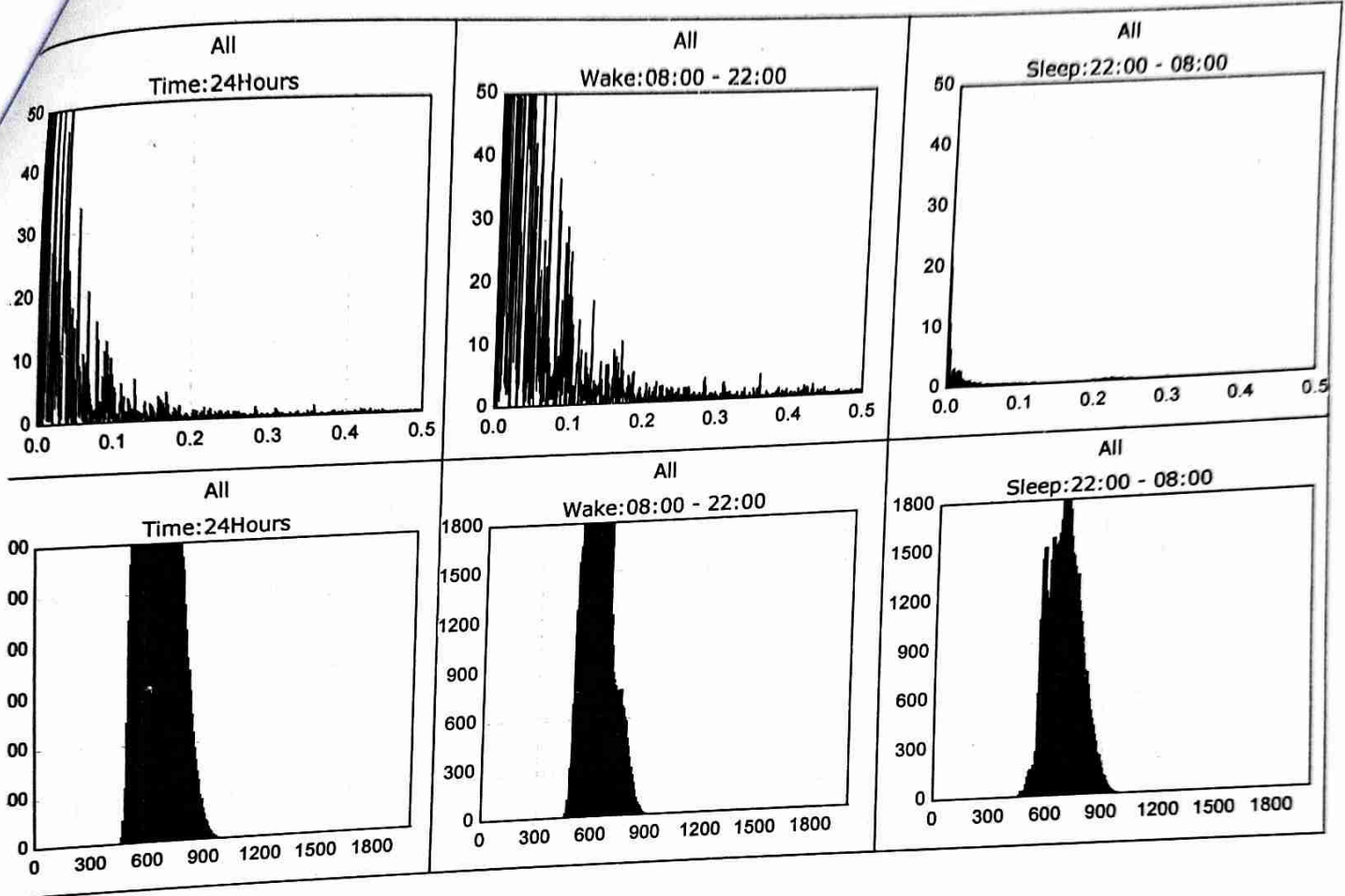
# HRV Time Domain Report



SDNN(ms):153	SDNN Index(ms):56	NN50:3689	Tri. Index:---
SDANN(ms):122	rMSSD(ms):99	pNN50(%):3	

*self Attested*

### HRV Frequency Domain Report



24Hours	Wake:08:00 - 22:00	Sleep:22:00 - 08:00
Power: 1044 VLF: 666 LF: 223 HF: 153  SDNN(ms): 153 SDNN Index(ms): 56 rMSSD(ms): 99 pNN50(%): 3	Power: 831 VLF: 577 LF: 189 HF: 64  SDNN(ms): 178 SDNN Index(ms): 65 rMSSD(ms): 126 pNN50(%): 1	Power: 1329 VLF: 786 LF: 270 HF: 273  SDNN(ms): 86 SDNN Index(ms): 44 rMSSD(ms): 25 pNN50(%): 6

*Self Attested*

### QT Report

Time	QRS	HR	RR(ms)	QT(ms)			QTD	QTc(ms)			QTcD
	Total	Ave.	Ave.	Min.	Ave.	Max.	(ms)	Min.	Ave.	Max.	(ms)
12:40	2165	110	543	281	296	328	46	382	398	437	54
13:00	5691	95	633	281	320	343	62	382	398	421	39
14:00	6322	105	569	273	304	320	46	375	406	429	54
15:00	6737	112	534	281	296	320	39	375	406	437	62
16:00	6464	107	558	273	304	328	54	375	406	437	62
17:00	5981	99	603	273	312	335	62	375	398	429	54
18:00	6612	110	547	273	304	328	54	367	406	437	70
19:00	5855	97	619	289	320	335	46	390	406	445	54
20:00	6003	100	602	281	312	335	54	375	406	437	62
21:00	6300	105	573	281	304	328	46	367	406	437	70
22:00	5901	98	610	273	312	335	62	382	398	421	39
23:00	5572	92	649	273	320	343	70	382	398	437	54
0:00	5287	87	685	281	328	359	78	382	398	429	46
1:00	5137	85	708	289	335	351	62	382	398	429	46
2:00	4657	77	776	296	351	375	78	382	398	445	62
3:00	4807	79	756	273	343	367	93	359	398	445	85
4:00	4958	81	740	273	343	382	109	359	398	437	78
5:00	4958	81	740	273	343	382	109	359	398	437	78
6:00	5926	98	611	273	312	351	78	367	398	429	62
7:00	5229	86	695	296	335	359	62	382	398	429	46
8:00	5219	87	691	296	335	359	62	382	398	429	46
9:00	5219	87	691	296	335	359	62	382	398	429	46
10:00	5311	88	683	289	328	367	78	375	398	437	62
11:00	5311	88	683	289	328	367	78	375	398	437	62
12:00	5000	83	722	281	335	359	78	382	390	429	46
	5000	83	722	281	335	359	78	382	390	429	46
	5085	84	712	289	335	367	78	382	390	429	46
	5085	84	712	289	335	367	78	382	390	429	46
	5496	91	657	281	320	359	78	375	398	437	62
	5496	91	657	281	320	359	78	375	398	437	62
	518	89	673	296	414	593	296	328	390	492	164
	518	89	673	296	414	593	296	328	390	492	164
	132233	93	646	273	324	593	74	328	399	492	61

