

DEPARTMENT OF CARDIOLOGY

K. G's Medical University U.P., Lucknow.

CORONARY ANGIOGRAPHY REPORT

NAME: Yashwan Prasad

Age/Sex :- 58/M

ADDRESS :

Diagnosis : Recent AMI

Physician I/c Dr. R. Saha DM

ID : 13273

Date of catheteri : 28/2/14

Contact No. :

SUMMARY REPORT

Left/Right Dominant System

Vessel	Ostial		Proximal		Mid		Distal		Flow (TIMI)
	%	Type	%	Type	%	Type	%	Type	
LMCA					99%	(B)			1
LAD									
D1									
D2									
INTERMEDIUS									
ICN									
OM1									3
Om2 <u>2mm vessel</u>			50%	(B)					
RCA									
PDB <u>PDA (<2mm vessel)</u>			70%	(B)					3
PLS									

Collaterals :

Grade I collateral from distal RCA to LAD

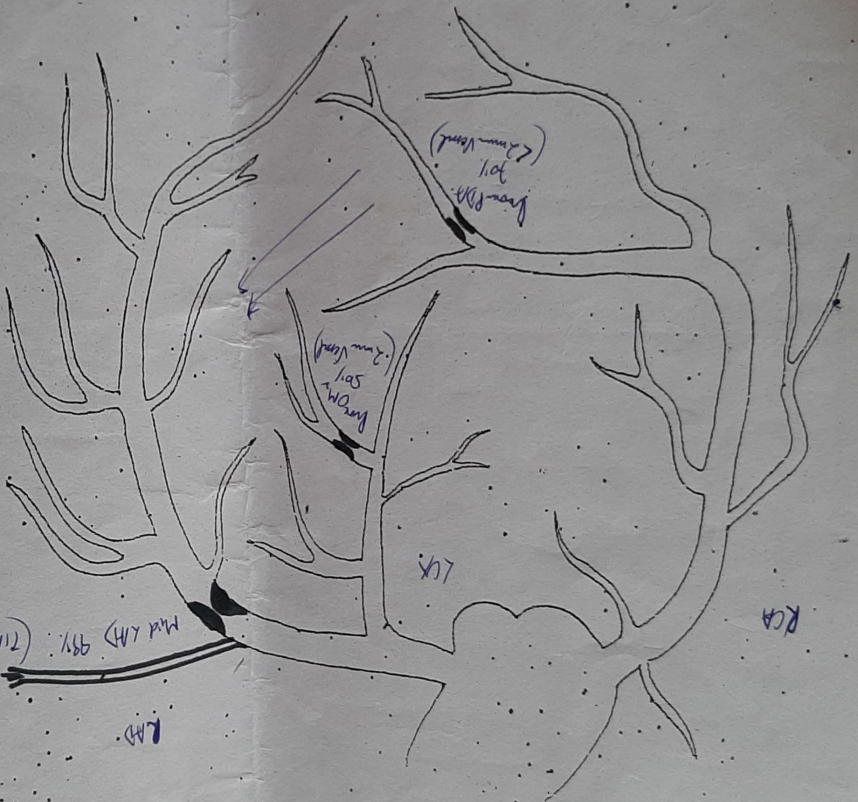
Others :

Mid LAD 99% (B)
from om2 (2mm vessels) - 50%
from PDA (<2mm vessels) 70%

Comments & advice :

Plan PCI → LAD

[Signature]



Good location from 8000 RCA K.A.D.

Right branch condition

Mud Layer

Department of Cardiology
KING GEORGE'S MEDICAL UNIVERSITY, Lucknow

PTCA report

PTCA/ 5787

NAME : MADHAV PRASAD

DATE : 28/02/14

AGE/SEX:58/M

Consultant incharge : DR RISHI SETHI D.M, FACC

Operators: DR. SHARAD CHANDRA D.M, FACC/ DR. RISHI SETHI D.M, FACC
Assistant : DR. VIKAS KUMAR, M.D. Department of Cardiology

Clinical diagnosis: RECENT AMMI/ STK- (12/02/2014)
CART : MID LAD 99%


PROCEDURE DONE: PTCA + STOLAD

1. ACCESS AND SHEATH: RFA/6F
2. GUIDING CATHETER: EBU 3.5/6 F
3. WIRE: FIELDER FC IN LAD
4. THROMBOSUCTION: None
5. CONTRAST: Omnipaque 100 ML
6. PREDILATION: 2.0 X 12 MM ballon @ 10 ATM
7. STENT: XIENCE PRIME 2.75 X 18 MM @ 12 ATM
8. POST DILATION: 3.0 X 9 MM NC ballon @ 14 ATM
9. GPIIb/IIIa INHIBITOR: None
10. RESULT: TIMI 3 FLOW

RESIDENT *[Signature]*


CONSULTANT INCHARGE *[Signature]*

DATE: 28/02/14
AGE/SEX: 58/M
PTCA/ 5787
NAME: MADHAV PRASAD
CONSULTANT INCHARGE: DR. RISHI SETHI D.M, FACC
OPERATORS: DR. SHARAD CHANDRA D.M, FACC / DR. RISHI SETHI D.M, FACC
ASSISTANT: DR. VIKAS KUMAR, M.D. DEPARTMENT OF CARDIOLOGY
CLINICAL DIAGNOSIS: RECENT AMMI/ STK- (12/02/2014)
CART: MID LAD 99%
PROCEDURE DONE: PTCA + STOLAD
1. ACCESS AND SHEATH: RFA/6F
2. GUIDING CATHETER: EBU 3.5/6 F
3. WIRE: FIELDER FC IN LAD
4. THROMBOSUCTION: None
5. CONTRAST: Omnipaque 100 ML
6. PREDILATION: 2.0 X 12 MM ballon @ 10 ATM
7. STENT: XIENCE PRIME 2.75 X 18 MM @ 12 ATM
8. POST DILATION: 3.0 X 9 MM NC ballon @ 14 ATM
9. GPIIb/IIIa INHIBITOR: None
10. RESULT: TIMI 3 FLOW
RESIDENT: *[Signature]*
CONSULTANT INCHARGE: *[Signature]*



KING GEORGE'S MEDICAL UNIVERSITY, U.P., LUCKNOW
Gandhi Memorial & Associated Hospitals

Wednesday OPL
Dr. Rishi Sethi



04/04/2017 / 0/0/00 → 0/0/00 (Reb, 14)

02412-517
0244 - 3571 (20 min rest)

No gross complaints

- 440
- ① 704. Eucosin AV (75/50) 145
- ② 705. Telmed Beta (75/50) 03
- ③ 705. Target to my 03

↑ 6 min rest

Stamwood

04/04 - 72/0 min
020 - 1 12/20

