



Patient Name Rehant Age/Sex 3 1/2 yr Regn. No. \_\_\_\_\_  
 Doctor's Name \_\_\_\_\_ Date & Time 29/7/20

1. Present Complaint

Pain abd x jwday  
vomity see

2. Past History

stools hard

3. Family History

4. Allergy if any :

5. General Examination:

BP: \_\_\_\_\_ Pulse: \_\_\_\_\_  
Temp: \_\_\_\_\_ R/R: \_\_\_\_\_

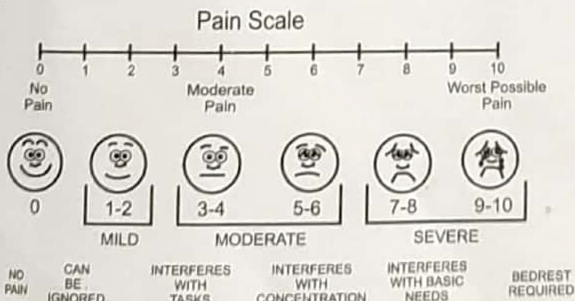
6. NUTRITIONAL SCREENING :

Height \_\_\_\_\_ Weight \_\_\_\_\_  
Pallor/Koilonychia/Edema/Dermatitis

7. Systemic Examination :

Chck  
CS ✓  
Abd ✓

8. Pain:



Patient Education (Patient is briefed on the following)

Proposed Care Plan ( ) Yes ( ) No  
 Expected Outcome ( ) Yes ( ) No  
 Possible Complication ( ) Yes ( ) No

9. Provisional/ Differential Diagnosis :

10. Investigation :

Went R  
1 x m  
YS

11. Treatment Advised :

- ① Milk only 2 times / day
- ② Eye Livoluk 2.5ml  
O.D. x 4 wks
- ③ Eye Cyclopan 3.5ml SOS.
- ④ Enteregamina (comp B1)  
x 5d 4g
- ⑤ Eye Ondem 3.5ml SOS

12. Next Follow up Visit:

Consultant Sign.

Name and Sign. of Patient Attendant

Name: Mst. Rebant

Age: 3.6 y

Sex: male

Date: 29-07-2020

**ULTRASOUND WHOLE ABDOMEN**

**Liver**

Liver appears normal in size [ 102 mm ], shape and echotexture. No focal hepatic lesion seen. Intrahepatic biliary radicals not dilated. Portal vein is normal.

**Gall bladder**

Gall bladder well distended. No gall bladder calculi seen. GB wall thickness normal. No Pericholecystic collection seen.

Common Bile Duct visualized lumen diameter is normal. Visualised CBD lumen is clear.

**Pancreas**

Pancreas is normal in size and echotexture. No focal parenchymal lesion seen . No Peripancreatic free fluid seen.

**Kidneys**

**Right Kidney** 67 mm

**Left Kidney** 71 mm

**Right Kidney:** It appears normal in size, shape and echotexture. No Renal calculus seen. No Hydronephrosis. Corticomedullary differentiation is maintained.

**Left Kidney:** It appears normal in size, shape and echotexture. No Renal calculus seen. No Hydronephrosis. Corticomedullary differentiation is maintained.

**Spleen**

Spleen is normal in size [ 82 mm ]. No focal parenchymal lesion seen.

**Urinary Bladder**

Urinary bladder well distended. Urinary bladder wall thickness normal. No obvious vesical calculus seen. No vesical mass seen.

**No free fluid is seen in abdomen / pelvis.**

**No significant intraperitoneal lymphadenopathy seen.**

**IMPRESSION.**

**Oedema and hypochoic thickening of intestinal wall and distension of fluid-filled lumen seen. The bowel loops are hyperperistaltic. Features suggest Enteritis.**

Please correlate clinically.

  
**DR. VARUN SHARMA**  
MD RADIODIAGNOSIS

**रेमिडी डायग्नोस्टिक्स**

asegment, Plot No.-7, Sanjay Nagar District Centre, (Below Allahabad Bank) Ghaziabad - 201 002 (U.P.)  
Tel.: (0120) - 2783879 Mob.: 0-9650267278 E-mail : remedydiagnostics@gmail.com