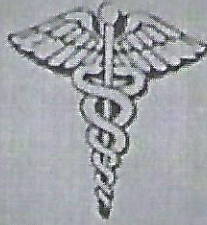



# Dr. (Capt.) RAJESH MEHTA

M.B.B.S., M.D. (PSYCHIATRY)  
CONSULTANT NEURO - PSYCHIATRIST  
FORMERLY - SR. CONSULTANT VIMHANS  
Ph.: 9810098761, 011-45130581



CLINIC : M.K.W. HOSPITAL  
J-BLOCK COMMUNITY CENTRE,  
RAJOURI GARDEN, NEAR SURYA HOTEL,  
NEW DELHI 110027 Ph.: 011-45809999  
Timing : DAILY 6 PM TO 8 PM  
Regd. No. : DMC 13662

NOT VALID FOR MEDICO LEGAL PURPOSE

Mr. Mohd. Amir Khan 47M Δ N-D / R.D

Date 21. 3. 2020

Fear to use public when alone. bhakhat @@  
last seen 02.10.2019. - depressed. now relaxed again

R

- T. Mellaril ① — ① — \*
- T. gabapen 25 \* — \* — ①
- T. Deprom - L ① — ① — ① / ② <sup>if less sleep.</sup>
- (OR)
- T. Moxib ~~placental~~ ② — ② — ② / ①

① ①

Lowozep MD 0.25 ① or ② sos.

(OR)


① sos ① ①

① ①

Moxib 5 mg

① sos ① ①

30days



Advised to be with people / family  
for feeling safe and secure - family

support will do good.

JAIPUR GOLDEN HOSPITAL  
2, INSTITUTIONAL AREA SECTOR - 3  
ROHINI, NEW DELHI 110085  
Ph: 011-51406231/011-27907000  
Timing: 11AM TO 1 PM  
MONDAY WEDNESDAY

U.K. NURSING HOME  
M-1, VIKASPURI, NR. KERALA SCHOOL  
Timing : 10AM TO 11AM  
TUESDAY & FRIDAY

MATA CHANAN DEVI HOSPITAL  
C-1, JANAKPURI, NEW DELHI 110058  
Ph: 011-45582000  
Timing : 11AM TO 1 PM.  
TUESDAY & FRIDAY

# Dr. (Capt.) RAJESH MEHTA

M.B.B.S., M.D. (PSYCHIATRY)  
 CONSULTANT NEURO - PSYCHIATRIST  
 FORMERLY : SR. CONSULTANT VIMHANS  
 Ph.: 9810098761, 011-45130581



CLINIC : M.K.W. HOSPITAL  
 BLOCK COMMUNITY CENTRE,  
 RAJOURI GARDEN, NEAR SURYA HOTEL,  
 NEW DELHI 110027 Ph.: 011-45609999  
 Timing : DAILY 6 PM TO 8 PM.  
 Regd. No. : DMC 13662

NOT VALID FOR MEDICO LEGAL PURPOSE 02.10.2019.

Mr. Mohd. Aamir Khan 47 M Δ N.D P-72 Bp. 120/70

No Tremor. Sudden episodes of Great what / suffocation / going to Pan off. (lasted for an hour or so. 2-2 such episodes in last one week. All Invest. = CNS. CVS. = NAD. H/O sleep disturbance prior to such episodes

No H/O HD fits loc. No Issue  
Distance Family

= ✓ T<sub>0</sub> Stalbid ① — ① — x  
 = T. qutepin 25 x — x — ①  
 = T. Nexito / ~~Stalbid~~ ② — ② — ①  
① ① ②

lowezep NAD ① dos. SARFAR  
 0.25 ② dos. SARFAR ①

ROUTINE - WALK  
BUSY ACTIVITY SCHEDULE

① 07 days ②

T.	Atervan	(loop	x — x — ①	DREAMS
T.	Nexito	(Both	x — x — ①	ONSET

**JAIPIR GOLDEN HOSPITAL**  
 2, INSTITUTIONAL AREA, SECTOR - 3,  
 ROHINI, NEW DELHI 110085.  
 Ph.: 011-61406231/011-27907000  
 Timing: 11AM TO 1 PM  
 MONDAY, WEDNESDAY,

**U.K. NURSING HOME**  
 M-1, VIKASPURI, NR. KERALA SCHOOL  
 Timing : 10AM TO 11AM.  
 TUESDAY & FRIDAY

**MATA CHANAN DEVI HOSPITAL**  
 C-1, JANAKPURI, NEW DELHI 110058.  
 Ph.: 011-45582000  
 Timing : 11AM TO 1 PM.  
 TUESDAY & FRIDAY

## Discharge Summary

### DEPT. OF GASTROENTEROLOGY

#### General Information

UHID	APD1.0011056355	Patient Identifier	DELIP275675
Ward/Bed No	2nd FLOOR TOWER - I , 2nd Floor T1 ward, Bed no:2208		
Physician	Mr. MOHD AAMIR KHAN		
Age	47Yr 6Mth 5Days	Sex	Male
Address	A-43 BETA IST GREATER NOIDA, Noida, Uttar Pradesh		
Primary Consultant	DR. NARINDER MOHAN TIKOO GASTROENTEROLOGY		
Admission Date	26-Sep-2019		
Discharge Date	30-Sep-2019		
Allergies	No Known allergy		
Diagnosis	...		
	Acute Gastritis (H.Pylori induced) with chronic L4-L5 radiculopathy (Left > Right)		

#### Present Illness

##### History of Present Illness

Mr. MOHD AAMIR KHAN 47 years old male was admitted with complaints of pain epigastrium, nausea/ vomiting palpitation / giddiness since 3 days.

#### Clinical Examination

##### On Examination

Conscious, oriented  
 Afebrile  
 Pulse Rate: 80/minute  
 Blood Pressure: 120/80 mmHg

Respiratory Rate: 20/minute  
 No clubbing / cyanosis / pedal edema / icterus / pallor / lymphadenopathy  
 Chest: Bilateral clear  
 CVS: S1, S2 Normal / No murmur / rub / gallop  
 P/A: Soft, No tenderness, No distension  
 CNS: No focal neurological deficit

### Time In The Hospital & Discussion

The patient was admitted and managed medically for his symptoms.

Investigations revealed - Hb- 14.9, TLC- 9.99, PLT- 2.82 lakh, ESR- 4, Amylase- 35, Lipase- 39, Bil -0.4, OT/PT- 35/43, Alk Phosphate- 57, GGTP- 26, Other investigations revealed- UGI scopy - Antral gastritis (RUT + VE), Fibrinogen - 7.2 kpa. NCV bilateral lower limb normal. 2D Echo showed LVEF 60%. Dobutamine stress test positive. Opinion was also taken from Dr.Harsh Bhargava (Sr.Consultant Orthopaedics), Dr.Charu Gauba (Consultant Neurology) and their advice incorporated in the line of management. EMC showed chronic C4-C5 spondylopathy (Left > Right).

### ADVICE ON DISCHARGE

Diet: As advised

Physical Activity: As tolerated

Medication: Cap. Pantocid HP kit 3 tabs per orally twice daily for 14 days. 6-6

Cap. VSI #3 cap per orally twice daily for 5 days 10-10

Tab. Makgalin 50 mg 1 tab per orally twice a day. 10-10

Collect:

MRI Brain with Spine screen and MRI Knee.

Follow Up

Review with Dr. N.M.Tikoo in Physician office with prior appointment. Kindly confirm your appointment on 011-26925858/26925801/29871250/1251.

Bill & Reports

Kindly bring a copy of your bill to collect the pending reports from gate no-4(from respective labs & Gate No:7 for Radiology Reports)on week days,Monday to Saturday(8am-8pm)and Sunday(8am-2pm).

**IF you have any of the following symptoms, please contact your doctor or our CMO on**

**+911126925888 / 26825555 / 29872001/2003**

1. Fever Of 101°F
2. Onset of new pain or worsening of previous pain.
3. Vomiting.
4. Breathing difficulty.
5. Altered level of consciousness.

- Discharge from the operative wound.
- Worsening of any symptoms.
- Other significant concerns.

Please visit our website: [www.apollohospdelhi.com](http://www.apollohospdelhi.com)

DR. NARINDER MOHAN TIKOO  
GASTROENTEROLOGY  
Primary Consultant

  
Registrar/Resident

Mr. MOHD AAMIR KHAN

APD1.0011056355

DELIP275675

**MRI WHOLE SPINE SCREENING**

There is evidence of thinning of the cord, displaying bright T2 signals at the level of D5-D6 with irregular outline of cord and cord appears adherent to the posterior vertebral body of D6. Subtle T2 bright signal seen in the cord at this level.

**LUMBO-SACRAL SPINE:**

Normal alignment of the vertebrae.

Marrow signal from vertebral bodies is normal on T2WI.

Posterior osteophyte at multiple levels.

Intervertebral discs at multiple levels is reduced in signal intensity on T2WI.

Disc bulge is noted at level of L4-L5 and L5-S1 indenting thecal sac.

No significant dural sac / nerve root compression seen.

PLEASE CORRELATE CLINICALLY.

DR. ANJU DHIMAN

--- END OF THE REPORT ---

  
DR.A.S ARORA  
SR.CONSULTANT

Mr. MOHD AAMIR KHAN

APD1.0011056355

DELIP275675

MRI BRAIN PLAIN

Bright signal on T2WI noted in bilateral ethmoidal air cells.


IMPRESSION : MR FINDINGS ARE SUGGESTIVE OF:

- ISCHEMIC / DEMYELINATING CHANGES IN BILATERAL PERIVENTRICULAR AND SUBCORTICAL WHITE MATTER.
- AGE RELATED CEREBRAL ATROPHY

PLEASE CORRELATE CLINICALLY.

DR. ANJU DHIMAN

--- END OF THE REPORT ---

  
DR.A.S ARORA  
SR.CONSULTANT



Dr. Narinder M. Tikoo MD  
Senior Consultant  
Gastroenterology & Hepatology

APD1.0011056355  
MR. MOHD AMIR KHAN  
Age: 47 Year(s) Year(s)/Male  
25 Sep, 2019 5:30:45 PM



~~Allegu to Metronidazole  
(Ornidazole)~~



- Since pain epigastric (episodic),  
since last 3 days
- Today some radiation to the  
back & vomiting times
- no fever or urinary symptoms
- Also of sudden palpitations  
& giddiness for last couple of  
days & chest fluttering feels
- stools - constipation ++

Repts Emergency ch  
can pain - 18 pm

Q/E: GE: tenderness epigastric  
no mass  
Lvs just palpable  
no free fluid

Δ Acute Ascend  
? Gastritis of Ac. Pancreatitis

Advised Ascend

- 1/2 v fluids DWS @
- 2x PPI + 1/2 v oflox
- Caesarian ref.

Dr. Hariharan



India's First Internationally Accredited Hospital

Accredited by  
Joint Commission International

Indraprastha Apollo Hospital, Sarita Vihar, Delhi-Mathura Road, New Delhi-110 076 (India)  
OPD - Gate No.10, 2nd Floor, Room No. 1256, Tel.: 26871256 Reception: 29871250, 29871251 Fax: 91-11-26823629

Mon & Tues : (3.00 P.M. to 8.00 P.M.), Wed & Sat (1.00 P.M. to 6.00 P.M.), Thurs & Fri (10.00 A.M. to 2.00 P.M.)

Mobile: +91-9891874660 Email: nmtikoo@gmail.com Website: www.apollohospdelhi.com

Dr. (Col.) V. HARIHARAN

M.B.B.S., M.D., DM (Cardiology)

F.I.C.A., (U.S.A.) F.I.S.E., F.I.C.C.

Senior Consultant

Interventional Cardiology

Apollo Cardiac Centre



Accredited by  
Joint Commission International



25/11

Mohd AAMIR Khan

- > Abdominal Dysepsia
- > Giddiness, weakness
- > Sweats
- > Unsteady
- > Schrotal

47 M

BP 130/84

Pulse 78b

CVS Mx

CRA, Uter

EKG's Mx  
EKG not

- DM<sup>o</sup>  
- HTN

FH/CAD+

- Tds ALPRA  
25  
55

Ref to see Gastroenterologist

Dr. Sudeep Khanna  
1252

India's First Internationally Accredited Hospital



Regd. No. DMC - 3088

# Prof. Dr. (Col.) P. K. Sethi vsm

MBBS, MD (AIIMS) CBE (NEUROLOGY) CANADA, FIAMS, FCCP, FICA (USA), FAAN (USA)  
PROFESSOR OF NEUROLOGY

Ganga Ram Institute for Postgraduate Medical Education & Research  
Emeritus Consultant & Advisor Neurology

Sir Ganga Ram Hospital

President Brain Care Foundation (India)

Rajinder Nagar, New Delhi-60 • Tel. : 25750000, 42254000 • Fax : 011-25861002 • E-mail : gangaram@sgrh.com, Website : www.sgrh.com

- Padmashri Awarded by the President of India
- Honorary Physician to the President of India
- Chairman, IBE-SEA Region
- Director Prakash Veeranwalli Neurology Clinic

Formerly :  
All India Institute of Medical Sciences  
Fellow State University of New York  
Head of Neurology Army Hosp. Delhi

dad  
24/9/2019

Moh Anur Kher

wednes 18/9/2019

47

- Diabetes

while Nimes

felt weakness

as if faint

hand

arm

are how

apw

gm

R

- smoking

20 years

yes

1) STOP SMOKING

2) NICOTEX Chew  
Bun

Stop Smoking

1-1-1

3) CLONOTRI L

- Two/three times

after 2 PM

2/3mg

smaller episodes

state drop down

less see

4) Symp ~~low~~  
Clonaf  
475

Clinics :

STRESS ECG Coding Sheet - 25/10/2017 3 hours testing

- NICU

5 - ECG Spine I

6 - Amorph Mfalk

7) - Jazulmet 50/500

8) - 12 emyelin D

9) - inj Insulin 2 units 30 min

10) Mikoran sup 1-x-

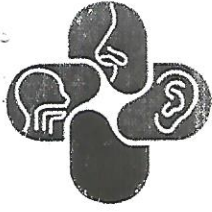11) Embeta 250 0.10

12) CLONOTRIL

F 114  
PP  
HbA1c  
7.6

Dr. (Col.) P.K. Sehgal VSM  
President Brain Care Foundation  
Senior Consultant Neurologist  
Sir Ganga Ram Hospital  
Regd. No.: EP-6540  
DMC-3088

257  
\*-x-9



# DR. SHASHANK GUPTA

ENT Laser Clinic  
116 Civil Lines, Circuit House Crossing, Bareilly  
91-581-2426079, 2511863  
entlaserclinic.com



## Dr. Shashank Gupta

Consultant, Laser & Endoscopic ENT and Head & Neck Surgeon  
MBBS, MS (ENT) Gold Medalist (Safdarjung Hospital, Delhi)  
SC-FRCS (England), DNB, MNAMS  
Fellowship in Laryngology & Laser surgery  
Trained at Harvard & Stanford Medical School (USA)

## डॉ. शशांक गुप्ता

एम.एस. (ईएनटी) गोल्ड मेडल  
(सफदरजंग अस्पताल दिल्ली)  
एससी. एफ.आर.सी.एस. (इंग्लैण्ड)  
Reg. No. 81705

Name Mohd. Anwar

Age/Sex 45/4M

Address Lucknow

17/3/19

R

- T. Pantotab - L 100 → सुबह
- T. Pantotab - D 100 → शाम
- T. Alzero - M 1 HS → रात
- Axeflo. n/s 2 puff BD →
- Subex. Syp 1 tep BD →
- I B - 29 100 →

खाली पक

I<sub>a</sub>  
HBAIC

x 2ml  
Jon  
17/3/19

Gauzeon  
plus

# ENT Laser and Endoscopy Centre

116 Civil Lines, Circuit House Crossing

Bareilly - 243001

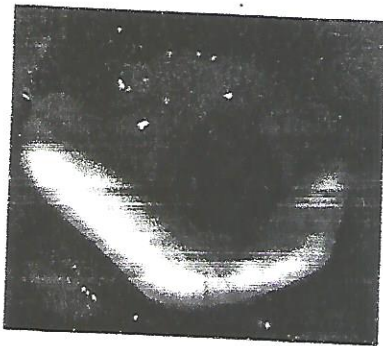Phone No: 2426079, 2511863

WebSite: [www.entlaserclinic.com](http://www.entlaserclinic.com)

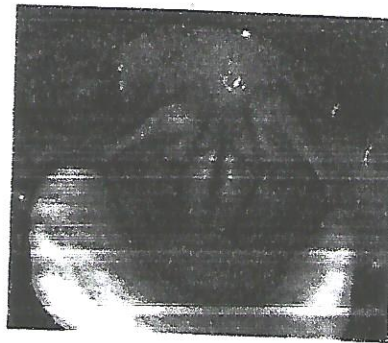Email\_ID: [entlaserclinic@gmail.com](mailto:entlaserclinic@gmail.com)

Patient ID: 2019030013  
Name: Mr. Mohd Aamir Khan  
Age: 45 Y  
Sex: M  
Date: 17-Mar-2019

Ref By: SELF  
Study: HD Video Laryngoscopy



Abduction



Adduction

## 70-Degree Rigid Endoscopy using Hopkins Rod 4mm Endoscope

Base of Tongue : Normal  
Vallecula : Normal  
Vocal Cord Mobility : Bilateral cords mobile  
Symmetry : Bilateral motion of vocal cords Symmetrical  
Abduction : Full excursion of bilateral cords  
Adduction : Complete  
Right Vocal Cord : Smooth  
Left Vocal Cord : Smooth  
Artytenoid Mucosa : Congested, Oedematous, Tiger-stripping +  
Other : LPR+

Examination & Reporting by-

Dr. Shashank Gupta  
MS (ENT) Gold Medal, Safdarjung Hospital  
DNB MNAMS  
SC-FRCS (England)  
Trained at Harvard and Stanford Medical School (USA)

Dr. (Col.) Sabir H Ansari  
 MBBS DLO, MS  
 Senior Consultant  
 Ear, Nose, Throat Surgery

18.10.2018



Mr Amir - 45 yrs IM

Diabetes

pain bilateral Rt & L  
 radiation to head & ear Rt  
 itching ear Rt 1 1/2 yrs

ENT exam: no neck nodes

SA root - tonsils +

nodes, NAD

Otitis media. Ear Rt - Otitis externa +

Impression: Acute Otitis Media

Bedaquine 200mg  
 water 200ml

- 1) Tab Augmentin duo 1g bd 10 days
- 2) Tab Levofloxacin 500mg bid x 7 days
- 3) Caudal block ear drops
- 4) Steam inhalation + saline gargles
- 5) Bedaquine / Leukowaxon

*[Handwritten signature]*

Sarita Vihar, Delhi-Mathura Road, New Delhi - 110076 Tel : 26925858, 26925801, 29871180 / 81, Fax : 91-11-2682369

OPD Room # 1122, 1st Floor, Gate No. 2  
 Timings - Mon, Wed & Sat (8 AM to 12 Noon) Tue (12 Noon to 4 PM), Thur/Fri (4 PM to 6 PM)  
 Resi : 1362, Sector - 29, Noida - 201 303 (U. P.) Ph. : 95-120-2454489 Mobile : 9811214879  
 E-mail : sabiransari@hotmail.com Website : www.apollohospdelh.com

Duplicate



# MEDI DOT DIAGNOSTICS

*Fully Automated*

ISO Approved Lab : ISO 9001-2015

285, A - Block, Shivalik, Near Gate No. 2,  
Malviya Nagar, New Delhi-110017  
Phone : 011-410 7546 0  
Mob.: 078278 16687, 098719 18579  
E-mail : medidotdc@gmail.com  
Timing : 8 AM To 8 PM ( 7 Days Open )

Date	23/08/2018	Srl No. 1		
Name	Mr. MOHD AAMIR KHAN	Age	45 Yrs.	Sex M
Ref. By	SELF			

Test Name	Value	Unit	Normal Value
-----------	-------	------	--------------

### BIOCHEMISTRY

BLOOD SUGAR FASTING	151	mg/dl	70 - 110
---------------------	-----	-------	----------

\*\*\*\* End Of Report \*\*\*\*



*Ashok Malhotra*  
DR. ASHOK MALHOTRA  
MBBS, MD  
CONSULTANT PATHOLOGIST  
REGD. NO - DMC 14095

**FACILITIES: ALL KINDS OF BLOOD TEST URINE, STOOL, ECG, EEG, EMG, NCV, PFT, TMT, X-RAY ETC.**  
On Pannel : LIC (Govt. of India) Health India:-SBI Life Insurance, Max New York Life Insurance, Oriental Life Insurance  
PNB Metlife, Bajaj Allianz Life Insurance, Future Generali India Life Insurance, TATA AIG Life Insurance.





# MEDI DOT

## DIAGNOSTICS

*Fully Automated*

ISO Approved Lab : ISO 9001-2015

285, A - Block, Shivalik, Near Gate No. 2,  
Malviya Nagar, New Delhi-110017  
Phone : 011-410 7546  
Mob.: 078278 16687, 098719 18579  
E-mail : medidotdc@gmail.com  
Timing : 8 AM To 8 PM ( 7 Days Open )

TDOSE VPOSYS EMS PVT. LTD

Lab ID. : 0011808250072	Reg No. : 84028
Patient Name : Mr. MOHD AAMIR KHAN	Reg. Date : 25/Aug 2018 03:22PM
Age Sex : 45 YRS / MALE	Sample Coll. Date : 25/Aug 2018 03:33PM
Referred By : Dr. Self	Sample Rec. Date : 25/Aug/2018 03:34PM
Ref. Source :	Report Date : 25/Aug/2018 05:37PM
Client Code/Name : GH011322-MEDI DOT DIAGNOSTICS	

Test Name	Result	Unit	Bio.Ref.Interval
<b>Liver Panel (LFT)*</b>			
TOTAL BILIRUBIN Serum, Vanadate Oxidase	0.3	mg/dl	0.2-1.0
CONJUGATED BILIRUBIN Serum, Vanadate Oxidase	0.1	mg/dl	0.0-0.2
UNCONJUGATED BILIRUBIN Serum, Vanadate Oxidase	0.2	mg/dl	0.2-0.7
SGOT (AST) Serum, Optimized, (Without P-5-P)	69.5	U/L	15-37
SGPT (ALT) Serum, Optimized, (Without P-5-P)	151.0	U/L	16-63
ALK.PHOSPHATASE Serum, Kinetic, IFCC	77.0	U/L	46-116
T.PROTEIN Serum, Biuret	7.6	gm/dl	6.4-8.2
ALBUMIN Serum, Bromo Cresol Purple	3.9	gm/dL	3.4-5.0
GLOBULIN Serum, Calculated	3.7	gm/dl	2.3-3.6
A/G Ratio Serum, Calculated	1.05		1.0-2.3
GAMMA GLUTAMYTRANSFERASE Serum, Kinetic	75.0	U/L	15-85

**Comment:**

Liver function test is used to detect, evaluate, and monitor liver disease or damage. This includes several tests which are associated with functionality and cellular integrity. These tests can be used to detect the presence of liver disease, differentiate between acute viral hepatitis and various cholestatic disorders and chronic liver disease (CLD), extent of known liver damage, and follow the response to treatment.



Dr. Minakshi Gullia  
MBBS, MD  
Sr. Consultant, Pathology

Dr. Arvind Khanijo  
MD(PATH)

Dr. Surbhi  
MBBS, MD  
Sr. Consultant, Pathology

**FACILITIES: ALL KINDS OF BLOOD TEST URINE, STOOL, ECG, EEG, EMG, NCV, PFT, TMT, X-RAY ETC.**  
On Panel : LIC (Govt. of India) Health India:-SBI Life Insurance, Max New York Life Insurance, Oriental Life Insurance  
PNB Metlife, Bajaj Allainz Life Insurance, Future Generali India Life Insurance, TATA AIG Life Insurance.

Reports are not valid for Medication...



# MEDI DOT DIAGNOSTICS

*Fully Automated*

ISO Approved Lab : ISO 9001-2015

285, A - Block, Shivalik, Near Gate No. 2,  
Malviya Nagar, New Delhi-110017  
Phone : 011-410 754640  
Mob.: 078278 16687, 098719 18579  
E-mail : medidotdc@gmail.com  
Timing : 8 AM To 8 PM ( 7 Days Open .)

Lab ID. : 0011808250072  
Patient Name : Mr. MOHD AAMIR KHAN  
Age/Sex : 45 YRS / MALE  
Referred By : Dr. Self  
Ref. Source :  
Client Code/Name : GH011322-MEDI DOT DIAGNOSTICS

Reg No. : 84028  
Reg. Date : 25/Aug/2018 03:22PM  
Sample Coll. Date : 25/Aug/2018 03:33PM  
Sample Rec. Date : 25/Aug.2018 03:34PM  
Report Date : 25/Aug 2018 03:57PM

Test Name	Result	Unit	Bio.Ref.Interval
<b>HAEMATOLOGY</b>			
<b>Complete Blood Count (CBC)</b>			
HEMOGLOBIN Whole Blood EDTA, Colorimetric	16.0	gm/dl	13.0-17.0
TLC (Total Leucocyte Count)	10.4	thu/cumm	4-10
<b>DIFFERENTIAL LEUCOCYTE COUNT</b>			
POLYMORPHS Whole Blood EDTA, Microscopic	43	%	40-80
LYMPHOCYTES Whole Blood EDTA, Microscopic	46	%	20-40
EOSINOPHILS	05		1-6
MONOCYTES Whole Blood EDTA, Microscopic	06	%	2-10
BASOPHILS Whole Blood EDTA, Microscopic	00	%	0-1
ABSOLUTE NEUTROPHIL COUNT	4.47	thu/cumm	2.0-7.0
ABSOLUTE LYMPHOCYTE COUNT	4.78	thu/cumm	1.0-3.0
ABSOLUTE EOSINOPHIL COUNT	0.52	thu/cumm	0.02-0.5
ABOLUTE MONOCYTE COUNT	0.62	thu/cumm	0.2-1.0
ABSOLUTE BASOPHIL COUNT	00	thu/cumm	0-0.20
RBC Whole Blood EDTA, Electrical Impedence	5.40	millions/cmm	4.5-5.5
HCT Whole Blood EDTA, Calculated	47.5	%	40-50
MCV Whole Blood EDTA, Calculated	87.96	fL	83-101
MCH Whole Blood EDTA, Calculated	29.63	pg	27-32
MCHC Whole Blood EDTA, Calculated	33.68	g/dl	31.5-34.5
RDW Whole Blood EDTA, Calculated	11.3	%	11.6-14.0
MPV	8.2	fl	6.0-9.0

*Signature*



Dr. Minakshi Gulia  
MBBS, MD  
Sr. Consultant

Dr. Arvind Khanijo  
MD(PATH)

Dr. Surbhi  
MBBS, MD  
Sr. Consultant

**FACILITIES: ALL KINDS OF BLOOD TEST URINE, STOOL, ECG, EEG, EMG, NCV, PFT, TMT, X-RAY, ETC**  
On Pannel : LIC (Govt. of India) Health India:-SBI Life Insurance, Max New York Life Insurance, Oriental Life Insurance  
PNB Metlife, Bajaj Allainz Life Insurance, Future Generali India Life Insurance, TATA AIG Life Insurance

Reports are not valid for Medical...



Clinic:  
 KRISHNA ENT CLINIC  
 C-61, Jitar Nagar, Opp. Sukh-Vihar, Delhi-51  
 E-mail : drsanjaygupta4@gmail.com  
 E-mail : sanjaygupta2@maxhealthcare.com

# Dr. Sanjay Gupta

M.B.B.S., MS (ENT)  
 Ear, Nose & Throat Specialist & Surgeon  
 Visiting Consultant :

Max Super Speciality Hospital Patparganj  
 Mobiles : 9555808963, 9868896026

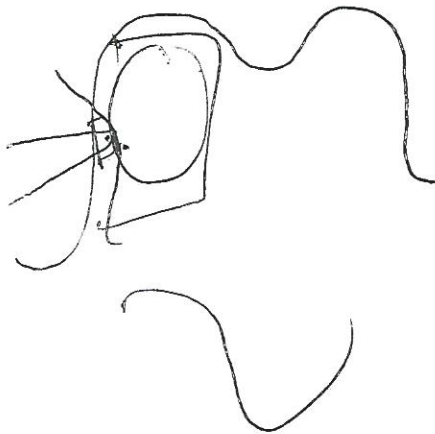
14/8/7

Mr. Amin  
MM

90 (R) ear Pain

Audi

OPG:



R

Urbacet

Tab Niseiw 50

Tab Neurobionil

add

1-m  
 Tab xyzal 50

Steamcivis

Nasogel-NC

MAX HOSPITAL  
 Patparganj

**CONSULTANT**  
 MALIK REDIX HOSPITAL  
 Nirman Vihar

TARAWATI HOSPITAL  
 I.P. Extn

**FACILITIES AVAILABLE :**

- MICROSCOPIC EAR SURGERY
- MICROSCOPIC LARYNGEAL SURGERY
- THYROID SURGERY
- HEARING TEST & HEARING AID

- SURGERY FOR SLEEP & SNORING
- ENDOSCOPIC SINUS SURGERY
- HEAD & NECK CANCER SURGERY
- COSMETIC SURGERY FOR NOSE

NOT VALID FOR MADICO LEGAL PURPOSE

For Appointment : 9868896026, 9555808963, 22503359



**M.K.W. JANKALYAN CHARITABLE TRUST  
HOSPITAL & RESEARCH CENTRE**

J-BLOCK, COMMUNITY CENTRE, RAJOURI GARDEN, NEW DELHI-110027

PHONE : 011-45609999, FAX : 011 25933168,  
E-mail : admin@mkwhospital.com, Website : www.mkwhospital.com  
(Managed by Pt. Kanakya Lal Dayawanti Punj Foundation)

Reg.No. 192429

FREE (OPD)



Patient Name : MR. MOHD AAMIR(DR SHEILA)  
Age/Gender : 40 YRS/MALE  
Address : 3809,DARIYA GUNJ  
Contact No. : 9212878416  
Issue Date : 05-Mar-15 11:14AM  
Receipt No. : FRT/14-15/00123211

Department : PHYSICIAN  
Room No. : 10  
Doctor / Unit : Dr. R.S.SALUJA  
Doctor Days : Mon Wed Thu Sat  
Company Panel : MKW HOSPITAL  
Fee : Rs. 0  
Appoint No : 24

Printed By : Sree Kumar

RBS ..

243 =

BP 120/80 mmHg

T2DM on Amaryl M forte 2mg

Tamumet

50+500

2 Lantus 160 sic 9PM  
2 Neurospalle

on Alrista plus

Adv

LFT, HbA1c

USA upper abdomen

HCV

HbA1c

TSH

6

- ① Amaryl - M forte 2mg
- ② Tamumet 50+500
- ③ 2 Lantus 200 sic 9PM
- ④ Tab Lysica 75 HS

1 then (N) x 32

⑤ Newz-B (1 Bd)

or Mychogen Forte

(M) (M)



# MALHOTRA GASTRO, LIVER & CANCER CLINIC

(A Madhu P.L. Malhotra Enterprise)

C-2, HARI NAGAR, NEW DELHI-64

## Dr. Sharad Malhotra

CONSULTANT GASTROENTEROLOGIST  
LIVER SPECIALIST & ENDOSCOPY SPECIALIST  
(BATRA HOSPITAL)  
MBBS, DNB (MEDICINE), DNB (GASTROENTEROLOGY)  
GOLD MEDALIST  
Mob.: 9810161287

## Dr. Anju Malhotra

CANCER SPECIALIST  
(MATA CHANAN DEVI HOSPITAL)  
MBBS, MD  
Mob.: 9990019648  
E-mail : sharaddoctor@gmail.com

MOND. Aamir

Date : 5/3/15

42/M.

Abd discomfort RUG 2006.

LFT deranged used Hepcivir. C? (Apollo).  
Endoscopy done.

↓  
Abated Udiliv.

USG Fatty liver.

40% continuous pain RUG hypochondrium.

k/c of DM type 2  
↓  
3 yrs.  
(uncontrolled)

of K: Afebrile.

P/A: Liver 4cm ↓ RCM.  
BS ⊕

Rx 1) Control of Diabetes.

2) wt loss 7-10 kg

3) Cap. EVION 400 U OD  
|—

4) XLISAM 400 mg BID  
|—|

x 1 month

Sharad