

बाहरी रोगी कार्ड OUT PATIENT CARD

R No. : 2021 0107 3216 Date : 12-01-2021

Name : AKANSHA BANSAL

Ph. No : 9971512430

Age/Sex : 29 Y/F Category : Tele Consult

Other Name: Aiay Bansal

Address : MIG 74 ADA CLY RAMGHAT ROAD

Aliqarh Uttar Pradesh India

Department : Gynaecology

Unit/Conslt: Unit 2/VJ.GRVP.MRT.SG.SS

Room No : 2053 Serial No : 2

File No : GYNGEN222065 Amount(Rs): NIL

Visit Days : Tue.Fri

सामयिक निदान/तत्कालिक निदान  
PROVISIONAL DIAGNOSIS

परीख व हस्ताक्षर  
DATE & INITIALS

बताई गई जांचें व उपचार  
TREATMENT AND INVESTIGATIONS ORDERED

SUPPLY FOLLOWING DRUGS OR  
EQUIVALENT GENERIC DRUGS

*Akansha*

बाहरी रोगी कार्ड OUT PATIENT CARD

Date: 12-01-2021

Name: AKANSHA BANSAL  
2971512430

Category: Tele Cons

Name: Ajay Bansal  
MIG 74 ADA CLY RAMGHAT ROAD  
Uttar Pradesh India  
Specialty: Gynaecology  
Unit: Unit 2/VJ.GRVP.MRT.3G.8B  
2053  
Serial No: 2  
Amount (Rs): NIL  
Date: Tue, Fri

PROVISIONAL DIAGNOSIS: Unilateral Endometriosis

TREATMENT AND INVESTIGATIONS ORDERED

SUPPLY FOLLOWING DRUGS OR EQUIVALENT GENERIC DRUGS

8/11/20 USG. report -  
normal sized uterus & left ovary.  
Rt ovary chocolate cyst -  
Endometrial thickness 4.5mm.  
Endometrial canal is clear.  
Unmarried girl  
40 pain in lower abdomen  
in June & she had  
severe pain. AKANSHA

তারিখ ও হস্তাক্ষর  
DATE & INITIALS

রোগী গর্ভ জাঁচ ও সপ্তাহ  
TREATMENT AND INVESTIGATION ORDERED

তারিখ ও হস্তাক্ষর  
DATE & INITIALS

SUPPLY FOLLOWING DRUGS OR  
EQUIVALENT GENERIC DRUGS

In June <sup>2020</sup> diagnosed as  
haemorrhagic cyst of size  
4-5 cm. No medication  
taken.

Regular menses. & constipation  
pain during menses.

Repeat USG Nov - Chocolate  
cyst.

Met gyn consultant

Dr. Alka K. She was

advised surgery. ~~to~~ wanted

to delay surgery was given - Dienogest 2mg  
~~and~~ taking regular  
SI SI - NOV.

~~Repeat~~ USG in Dec 2020.

So slight decrease  
in size.

Alka K.

बताई गई जांचें व उपचार  
TREATMENT AND INVESTIGATION ORDERED

SUPPLY FOLLOWING DRUGS OR  
EQUIVALENT GENERIC DRUGS

Adv.

- MRI.

- To continue denogest-  
for 6 months

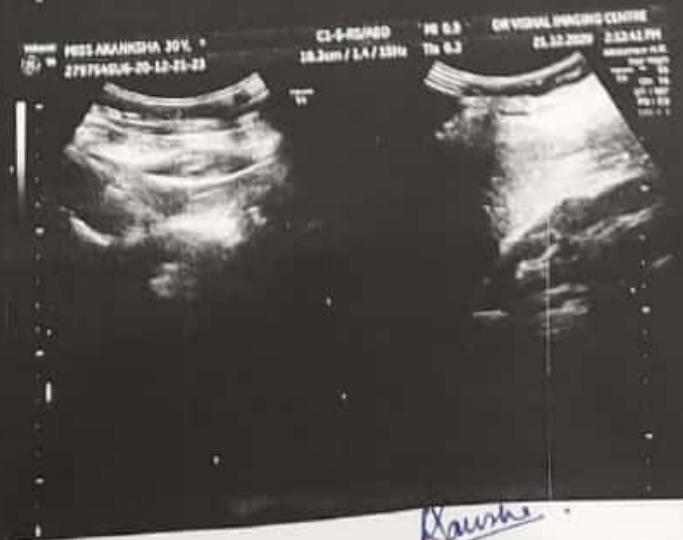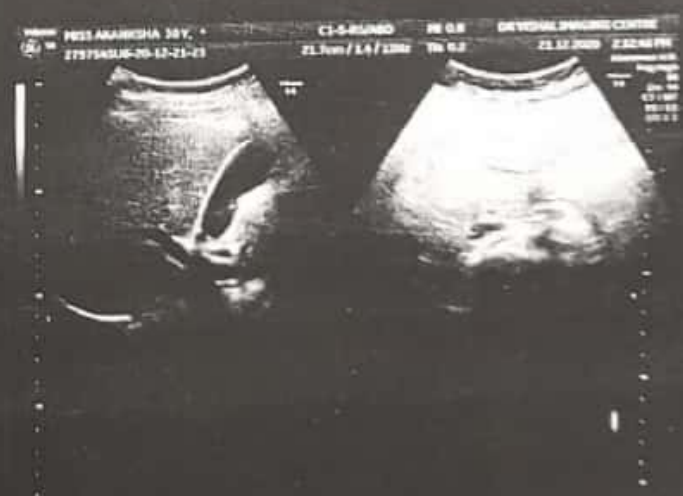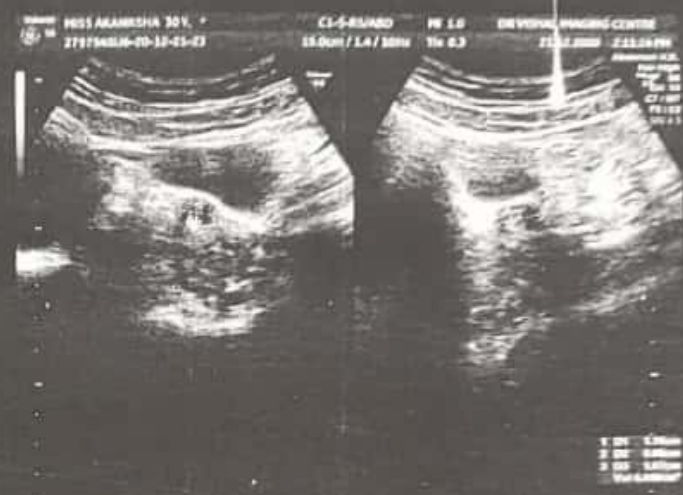
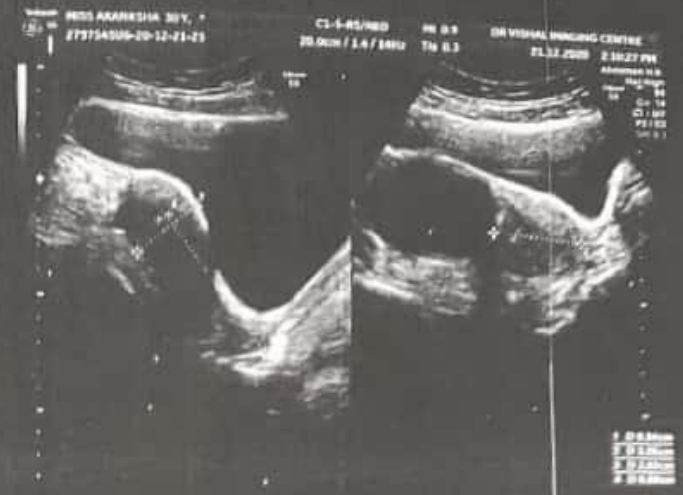
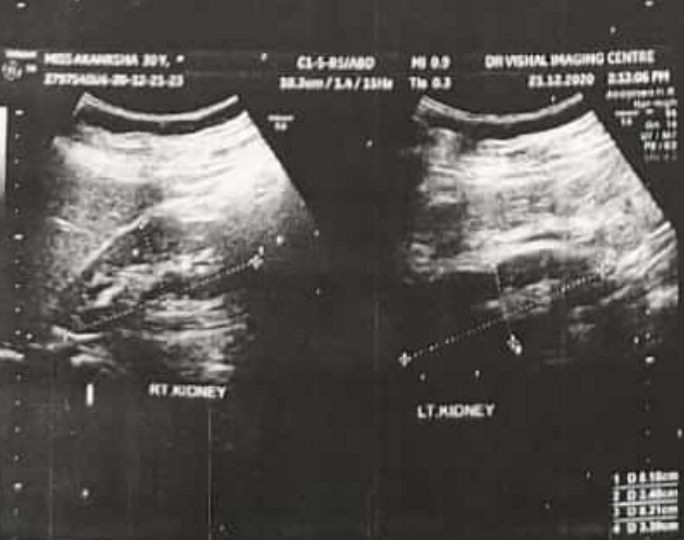
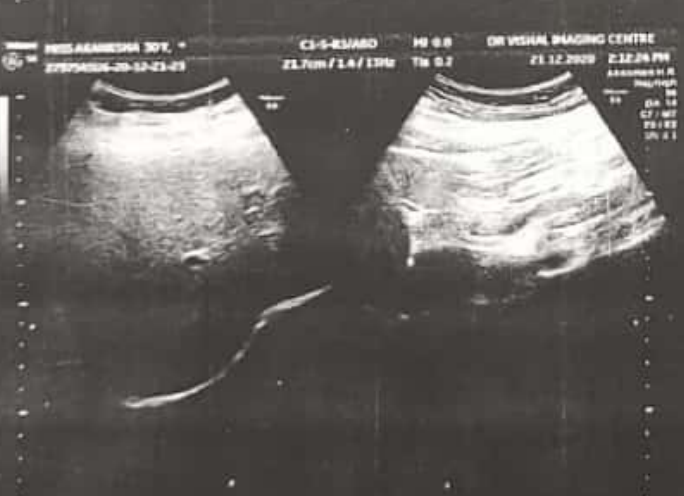
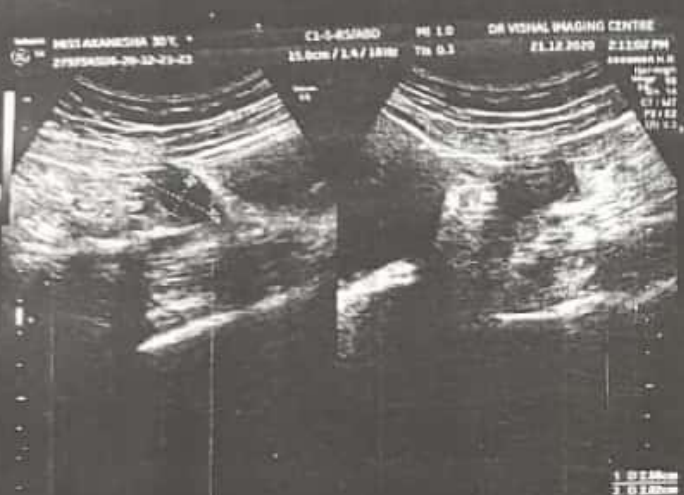
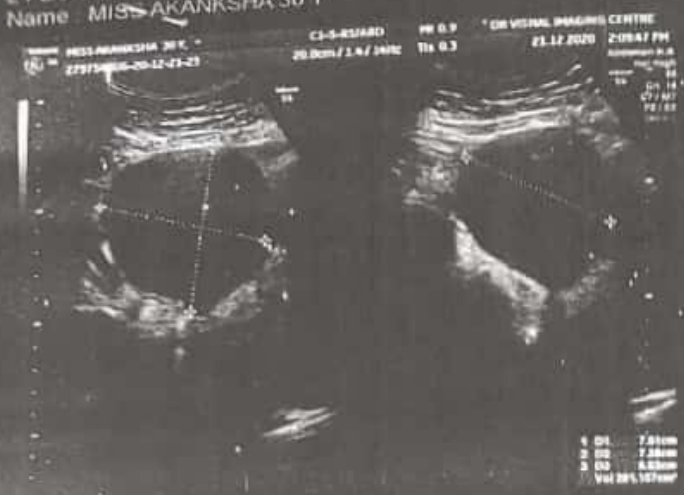
- Renew after 3 mths  
of treatment-

- Sachin

Kaushal



21 Dec 2020  
Name MISS AKANKSHA 30 Y



*Lawke*

# Vishal Imaging Centre

REPORT

Miss. Akanksha  
Dr. Daljeet Kaur

AGE/SEX: 10Y F  
DATE: 8 November 2020

Uterus

Normal in size (6.1x3.4x2.9cm), shape & echogenicity  
No uterine mass lesion

Cervix appears normal

Left ovary is normal in size (2.5x2cm) shape & echotexture

Thick (5.0mm) walled cystic lesion (9x8x7.5cm=280ml) in right adnexal region adherent to the uterine fundus with tiny internal echoes & thin internal septation ? Chocolate cyst right ovary

➤ No evidence of ascitis or pleural effusion/lymphadenopathy

## IMPRESSION:-

- Normal sized uterus & left ovary
- Chocolate cyst right ovary
- Endometrial thickness= 4.5mm.
- Endometrial canal is clear

Please correlate clinically

Dr Vishal Saraswat  
Diplomate National Board (Radiodiagnosis)  
RMC 9183/021913

### Kindly Note

- ❖ Ultrasound is not the modality of choice to rule out subtle bowel lesions.
  - ❖ Please Intimate us for any typing mistakes and send the report for correction within 7 days.
- The accuracy of Radiological diagnosis is based on the interpretation of various shadows produced by both the normal and abnormal tissues and is not always conclusive. Further histological and radiologic investigation & clinical correlation is required to enable the clinician to reach the final diagnosis.

The report and films are not valid for medico-legal purpose.  
CT facility is available

*Kaur*



• Ultrasound • Colour Doppler • Level-II Ultrasound  
• Fetal Echocardiography • 1.5 Tesla MRI • 32 Slice CT Scanner MB  
• Digital X-Ray • OPG IVP, Barium Studies etc.

Madhupuria Bhowan, Gulzar Nagar, Near Devatrayo Hospital  
Ramghat Road, Aligarh • Mob. : 09719657206