

प्रेषक:

वीना नारायन
अपर जिला एवं सत्र न्यायाधीश,
कक्ष संख्या- 3, कौशाम्बी

द्वारा-

जनपद न्यायाधीश
कौशाम्बी

सेवा में,

महानिबन्धक,
माननीय उच्च न्यायालय
प्रयागराज

विषय:

प्रत्यावेदन हेतु प्रार्थनापत्र :

महोदय,

सविनय निवेदन है कि मेरा वार्षिक स्थानान्तरण माननीय उच्चन्यायालय के नोटीफिकेशन संख्या 486/एड.(सेवाये) 2021, दिनांकित 09.04.2021 से जनपद कौशाम्बी हो गया है।

ससम्मान निवेदन है कि मुझे वर्ष 2007 में फिरोजाबाद पोस्टिंग के दौरान (Slip disc) हो गया था जिसकी एम.आर.आई. की प्रति एनेक्चर-1 के रूप में संलग्न है, जिसका इलाज मैंने विभिन्न अस्पतालों में यथा-फिरोजाबाद, इलाहाबाद, आगरा तथा अंत में मैक्स हास्पिटल दिल्ली में कराया था। उपरोक्त के सन्दर्भ में चिकित्सक के पर्चे एनेक्चर-2 के रूप में संलग्न हैं। करीब एक वर्ष तक इलाज चलने के उपरान्त उसमें आराम हो गया था। परन्तु वर्ष 2015 में जब मेरी पोस्टिंग प्रतापगढ़ थी तब पुनः काफी तीव्र दर्द प्रारम्भ हुआ और मैंने प्रतापगढ़ व इलाहाबाद के चिकित्सक को दिखाया क्योंकि बार-बार तीव्र दर्द में दिल्ली जाना सम्भव नहीं था। लगभग दो वर्ष तक कोई आराम नहीं मिला और मैं दर्द निवारक दवाइयों खाती रही।

तत्पश्चात् जब मेरा स्थानान्तरण वर्ष 2017 में जनपद हापुड़ हुआ तब मैंने जे.पी. हास्पिटल नोएडा में पुनः चेकअप कराया, जहाँ उन्होंने एम.आर.आई. कराने की सलाह दी तथा एम.आर.आई. कराने पर पता चला कि मेरे स्पाइन के ठीक बगल में 22X14 एम.एम. का बेनाइन ट्युमर है जिसकी प्रति एनेक्चर-3 के रूप में संलग्न है। इस ट्युमर के कारण नसों में दबाव पड़ने की वजह से तीव्र दर्द प्रारम्भ हुआ था जिसके लिये चिकित्सक ने मुझे आपरेशन कराने की सलाह दी तथा दवाइयों दी परन्तु ट्युमर स्पाइन के बिल्कुल पास में होने के कारण आपरेशन कराने में हिचकिचाहट हुई और दर्द की दवाइयों और कुछ आयुर्वेदिक दवाइयों लेती रही।

उसी दौरान अन्य चिकित्सकों की राय लेने के लिये गुडगाँव के पारस हास्पिटल में भी चेकअप कराया, जिसकी प्रति एनेक्चर-4 के रूप में संलग्न है और वहाँ के चिकित्सक ने भी आपरेशन की सलाह दी।

पुनः अक्टूबर 2017 में जे.पी. हास्पिटल नोएडा के चिकित्सक की सलाह से एम.आर.आई. कराया जिसकी प्रति एनेक्चर-5 के रूप में संलग्न है परन्तु ट्युमर के



साइज में कोई घटोत्तरी न होने के कारण पुनः दिल्ली में इण्डियन स्पाइनल इन्जरी सेंटर में चेकअप कराया तो तथा दिनांक 16.05.2019 को एम.आर.आई हुआ, जिसकी रिपोर्ट एनेक्चर-6 के रूप में संलग्न है, जिसमें ट्युमर का साइज यथावत बना रहा तथा चिकित्सक ने रिपोर्ट देखकर पुनः आपरेशन कराने की सलाह दी। तत्पश्चात मैंने अपनी उपरोक्त समस्या के सन्दर्भ में एम्स के चिकित्सक से भी माह अक्टूबर 2019 में सलाह मशबिरा लिया था। उसकी प्रति एनेक्चर-7 के रूप में संलग्न है। उन्होंने भी आपरेशन कराने की सलाह दी थी। इसी दौरान मैंने अन्य अस्पताल नियों हास्पिटल नोएडा में सलाह हेतु पुनः दिखाया तथा वहाँ पर वर्ष 2019 में एम.आर.आई कराने पर ट्युमर यथावत पाया गया, जिसकी प्रति एनेक्चर -8 के रूप में संलग्न है। नियों हास्पिटल के चिकित्सक ने भी दर्द निवारक दवाइयों दी।

तत्पश्चात पूरे देश में कोविड संक्रमण व्याप्त होने के कारण आपरेशन कराया जाना सम्भव नहीं हो सका। माह जून 2020 में मैं कोविड से संक्रमित हो गयी थी तथा 10 दिन सरस्वती हास्पिटल हापुड़ में भर्ती थी तथा रिकवरी में समय लग गया और आपरेशन कराया जाना सम्भव नहीं हो सका। मैं दर्द निवारक दवाइयों लेती रहीं।

मेरी यह समस्या लगातार बनी है और मुझे समय-समय पर चेकअप के लिये चिकित्सक को धार-बार दिखाना पड़ता है तथा चिकित्सक के द्वारा आपरेशन कराने की भी सलाह दी गयी है तथा मुझे न्युरो के फिजियोथिरोपिस्ट से थिरेपी भी करानी पड़ती है जो कि जनपद कौशाम्बी में उपलब्ध नहीं है।

अतः उपरोक्त परिस्थितियों में माननीय महोदय से करबद्ध प्रार्थना है कि मेरा स्थानान्तरण कौशाम्बी जनपद से दिल्ली के आस-पास के किसी अन्य जिले में कर दिया जाय जिससे मैं अपना इलाज सुचारु रूप से करा सकूँ।

ससम्मान,

भवदीय,
Veeva Narayan
(10.8.21)
(वीना नारायण)

अपर जिला एवं सत्र न्यायाधीश,
कक्ष संख्या-3, कौशाम्बी

संलग्नक-

1- स्वयं का चिकित्सीय प्रमाणपत्र

क्रमांक 771/ए/.../दिनांक 10.08.2021
अज्ञात
जिला न्यायाधीश
कौशाम्बी
10.08.2021

डॉ० आभा गोयल
M.B.B.S., D.C.H.
प्रोफेसर यू० सी० गोयल
M.B.B.S., M.D. (Gold Medalist)
फिजीशियन, न्यूरोलोजिस्ट
(कम्युनिटी कन्सल्टेशन)

Phone : 2260296, 2260297
43, एस० पी० मार्ग, सिविल लाइन्स, इलाहाबाद
◆ Professor MLN Medical College Allahabad
◆ Member Neurology Society of India
◆ Member Indian Academy of Neuroscience
◆ Life Member Association of Physician of India

70%

R Sul Veena Narain

11/11/07

R₂

4)

- Hard bed rest / NO pillow / Back extension
exercises
Anoid squatty
→ Brufen MR 1 time a day after meals
→ enymoral tabs. DS 1 x 3 times a day
→ Pastum Gel locally
Reput in
today

Ann. 10

Phone : Clinic cumi Resi : 0532-2256805, 2256266

Kriti Scanning Centre (P) Ltd.

SUPERCON 1.0T MRI, MULTISLICE (6 Slice) SPIRAL C.T. SCAN, USG. COLOR DOPPLER, 2D ECHO, DIGITAL X-RAY

55-B, Lowther Road (In front of Medical College), Allahabad.

Name	: Veena Narain
Age/Sex	: 41 years/ female
Date	: 08 March 2007
Referred by	: Dr U C Goel MD

Time: 4:01:18 PM

Report:

MRI of Lumbo-Sacral Spine

<u>Imaging Sequences</u>
Axial: T2 TSE, T1TSE
Sagittal: T2 TSE, T1TSE

Mild degenerative disc desiccation and tear of posterior annular fibres is seen at L4-5 and L5-S1 levels with maintained disc heights. Vertebral heights are normal with maintained alignment and normal spinal curvature. Bone marrow signal intensity is normal.

Mild posterocentral disc protrusion is seen at L4-5 level indenting thecal sac.

Mild focal posterocentral disc protrusion is seen at L5-S1 level causing effacement of fat ventromedial to both S1 nerve roots.

No abnormal pre or para vertebral soft tissue is seen.

No evidence of ligamentum flavum hypertrophy.

Bony diameters of lumbar canal (on axial sections at mid-body level) are within normal limits.

Conus medullaris is normal in morphology and signal intensity.

Impression: Mild posterocentral disc protrusion at L4-5 level indenting thecal sac

Mild focal posterocentral disc protrusion at L5-S1 level causing effacement of fat ventromedial to both S1 nerve roots

Adv: Clinical Correlation

Dr V K Agarwal MD

Dr S K Gupta MD

Dr Pankaj Kamra MD

Dr S S Anjum DMRD

* Discrepancies due to technical or typing errors should be reported for correction within seven days. No compensation liability stands. RM

Aug. (2)

Mrs Veena Narain, 41y/F

12/6/07

LBA since 10 Feb 07.

No radiation of pain

O/E. Scoli - 90° B/L

Power - 5/5

DTRs - (2)

NO sensory loss

Reflex - (2)

mild L5 spine tenderness.

MRI - mild disc bulge at L4-5 PivD (central).

Plan -

Phy - Physiotherapy.

Tab Xanaxid 275 mg son

Max Super Speciality Hospital

1, Press Enclave Road, Saket, New Delhi - 110 017
Phone: +91-11-6611 6666, Fax: +91-11-6611 6677

**DEPARTMENT OF RADIODIAGNOSIS AND IMAGING
REPORT**

Patient Name : VEENA NARAIN
UHID : JHN000172635
Age/Sex : 51Y/F
Requested By : Dr.. Saurabh Rawall

Procedure Date : -
Order From : RADIOLOGY-BILL-GF-AB
Accession No. : SC115MR17002845
Investigation : MRI CONTRAST (10 CC
EXTRA)


Ordered Time : 12/06/2017

Reported Time : 13/6/2017 11:52:14

CONTRAST ENHANCED MRI

Contrast study done for the right paravertebral lesion at L1 vertebral level and shows

Moderate enhancement of the lesion - consistent with a nerve sheath tumor.



Dr. Cps Chauhan

M.D
Senior Consultant Radiologist

**DEPARTMENT OF RADIOLOGICAL DIAGNOSIS AND IMAGING
REPORT**

Patient Name : VEENA NARAIN
UHID : JHN000172635
Age/Sex : 51Y/F
Requested By : Dr.. Saurabh Rawal

Procedure Date : 12/06/2017
Order From : RADIOLOGY-BILL-GF-AB
Accession No. : SC115CR17016290
Investigation : XRAY SPINE
LUMBOSACRAL - AP/LAT

Ordered Time : 12/06/2017

Reported Time : 13-6-2017 1:10:28

- Loss of lumbar lordosis is seen.
- Marginal osteophytes seen with end plate erosion.
- L4-5 and L5-S1 discs height are decreased.
- Rest of vertebral bodies are normal in height, alignment and density.
- Rest of intervertebral disc spaces are normal
- Posterior elements are normal
- Bony spinal canal appears normal.
- No evidence of pre/para-vertebral soft tissue abnormality

Dinesh

Dr. Dinesh Pratap Singh
MD RADIOLOGICAL DIAGNOSIS
SENIOR RESIDENT

Note: (1) This report is NOT valid for medico-legal purposes.
(2) In case of any discrepancy due to machine error or typing error, please get it rectified immediately.

Dr. Saurabh Rawall
MBBS (AIIMS), MS Ortho (AIIMS), FNB Spine Surgery, Fellowship in Spine Surgery (Canada)

CONSULTANT
INSTITUTE OF SPINE

Mob.: +91 98688 97026 E-mail: saurabh.rawall@jalindia.co.in

JAYPEE
HOSPITAL
LIFE FIRST

OP CASE SHEET

UHID : JHN000172635 Date : June 12, 2017 12 25
Patient Name : Mrs Veena Narain Visit No : OP-001
Sex / Age : Female/51 Years 8 Months Consultation Type : FIRST VISIT
Address : Additional District Judge, Hapur, Uttar Pradesh Mobile No : 9935854411
Queue No : 9 Plan name : CASH



254

Weight: _____ (kg) Height: _____ (cm) BP: _____ (mmHg)
Pain Score(0-10): _____ Pulse/HR _____ Allergies (if any) _____

History:

History: PVD - 2007
C/O - *Hypothyroid.*
LBA - 1 year. (Op for 2.3 notch)
O/R - SLR -ve FABER -ve N. defect
7e der (P) (P) paraspinal area.

Clinical Assessment :

Adv
X-ray L-S spine - AP Flex
- lat Ext

MRI L-S spine.

TYXETOSHINE

TY PAN 40 0

MR 0 _____ 0 x 5 day
_____ x 5 day
2 Tab

Dr. Saurabh Rawall
MBBS (AIIMS) M.S Ortho (AIIMS)
FNB Spine Surgery Fellowship
(Canada, Australia)
DMC-R/03050
OPD - Tue, Wed, Sat.
For Appointment - 9999103730

JAYPEE
GROUP



Regd. & Corp. Office: Jaypee Healthcare Ltd., Wish Town, Sector - 128, Noida - 201304, Uttar Pradesh, India
Ph: +91 (120) 4122222, Fax: +91 (120) 4582899 CIN: U85191UP2012PLC053358

Email: askus@jaypeehealthcare.com. Website: www.jaypeehealthcare.com



Emergency 1800 102 9 102



Helpline 1800 102 9 103

Provisional Diagnosis :

Investigations Advised:

Treatment Advised:

Follow Up:

Consultant Sign

Date & Time:

Contract Study
CS

DEPARTMENT OF LABORATORY MEDICINE
BIOCHEMISTRY

Name	Mrs VEENA NARAIN	Department	INSTITUTE OF SPINE
Age	51.8 Year(s) / FEMALE	Consultant	Dr. Saurabh Rawall
UHID	JHN000172635	Specimen	Serum
Visit Type	OP / OP-001	Collected On	12/06/2017 16:05
Patient Address	additional district judge, HAPUR, UTTAR PRADESH	Received At	12/06/2017 16:42
Sample No	BC1706120269	Reported On	12/06/2017 17:23

Test Name	Result	Unit	Biological Reference Interval
BLOOD UREA (Colometric (Urease))	26	mg/dL	19.0-43.0
SERUM CREATININE (Enzymatic-two point rate)	0.67	mg/dl	0.52-1.04

Comments :

Note : Abnormal Results are Highlighted.

H = High (Elevated Above Normal Range Value)
PH = Panic High (High Critical Range Value)

L = Low (Decreased Below Normal Range Value)
PL = Panic Low (Low Critical Range Value)

THE TESTS ARE PERFORMED AT DEPARTMENT OF LABORATORY MEDICINE, JAYPEE HOSPITAL, NOIDA-201304
— End of Report —

Anjali

Dr. Anjali
Senior Registrar (Biochemistry)
Department of Laboratory Medicine



Rawall

MS, MS Ortho (AIIMS), FNB Spine Surgery, Fellowship in Spine Surgery (Canada)

CONSULTANT OF SPINE

Consultant

Mob: +91 98688 97026 E-mail: saurabh.rawall@jalindia.co.in



OP CASE SHEET

MRN	: JHN000172635	Date	: June 13, 2017 15:35
Patient Name	: Mrs Veena Naram	Visit No	: OP-002
Sex / Age	: Female/51 Years 8 Months	Consultation Type	: FOLLOW UP
Address	: Additional District Judge, Hapur, Uttar Pradesh	Mobile No	: 9935854411
Queue No	: 2	Plan name	: CASH



MRI - L1 Extracranial Neurofibroma

H

To discuss with Dr Chauhan

25A
[Signature]

7. ME-12 of 1500 0 ————— x 1 month
[Signature]



Regd & Corp. Office: Jaypee Healthcare Ltd., Wish Town, Sector - 128, Noida - 201304, Uttar Pradesh, India
Ph: +91 (120) 4122222 Fax: +91 (120) 4582899 CINC: U85101UP2012PLC053358

Email: askus@jaypeehealthcare.com, Website: www.jaypeehealthcare.com



Emergency 1800 102 9 102



Helpline 1800 102 9 103

Dr. Ramneek Mahajan
 M.Ch (Ortho)
 Director - Joint Replacements
 (Singapore, Germany, Australia)
 Director - Orthopedic & Joint Replacement
 Head of Unit
 OPD Timings: Mon - Sat 11am to 3pm
 Phone: 09811939693, 09868710877
 Email: ramneek.mahajan@maxhealthcare.com

For Appointments:
 Rosily: 9810552530
 Manoj: 9811939643

Dr. O P Gupta
 MBBS, MS (Ortho), PDSF, FISS (USA)
 Fellowship in Spine Surgery, USA
 Consultant - Orthopedics & Spine Surgery
 OPD Timings: Mon/Wed/Fri: 8am to 11am
 Wed/Thu/Sat: 3pm to 5pm
 Phone: 9756010382

Dr. Anil V
 MBBS, MS Ortho, DNB Ortho, MNAMS
 Attending Consultant
 Joint Replacement and Trauma
 OPD Timings: Mon/Wed/Fri: 5pm to 8pm
 Tue/Thu/Sat: 8am to 10am
 Phone: 9013284032

Dr. Abbas Shaharyar
 MBBS, MS Ortho
 Attending Consultant
 Pediatric Orthopedics and Trauma
 OPD Timings: Mon/Wed/Fri: 8am to 10am
 Tue/Thu/Sat: 5pm to 8pm
 Phone: 8447060410


Patient's Name: *Mr. V. Ramu*
 Age/ Gender: *54 / F*
 UHID *140127*



LBP

MRI -> neurofibroma at L1 level

*Prov. - prognosis explains
 - Treatment option discussed in detail*

 **Dr. O P Gupta**
 Consultant
 Spine Surgery & Trauma - Orthopedics
 Max Smart Super Speciality Hospital
 (A Unit of Gujarmal Modi Hospital -
 Research Centre For Medical Sciences)



Aug. 4

OPD Prescription

Reg. No 443200 Issue Date 15/07/2017
 Name Mrs. Veena Narain Age/Sex 51 Yrs/Female
 Doctor/Unit Dr. SUMIT SINHA Department NEURO SURGERY
 Category TARIFF VERSION 7.2 Pay Mode Cash : 1200.00 9968292347
 Room No Queue No.
 Doctor Mob. 9818770024 Patient Mob. 9935854411
 Day & Time MON: 9:00AM - 6:00PM, TUE: 9:00AM - 6:00PM, WED. 9:00AM - 6:00PM, THU: 9:00AM - 5:00PM, FRI: 9:00AM - 6:00PM, SAT: 9:00AM - 6:00PM

Note : Kindly take Prior Appointment for Consultation and diagnostic.

BP: 110/70 mm/Hg Height: Weight: 71.4 kg BMI:

Allergies:

History and complaints:

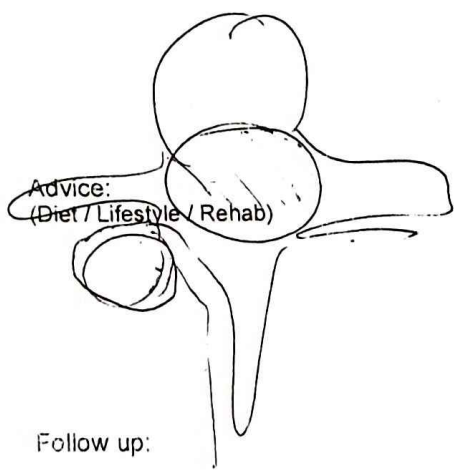
low Backache x 6 months
 Similar episode in 2007

Examination:

M/Li-Spine L45 Lt) RVD
 + BNST at L12

Provisional/Final Diagnosis:

Drug orders:



Adv
 - Surgery for the BNST
 + Endoscopic L45-Discectomy

Follow up:

Date: _____

Time: _____

Contact: _____

Name & Signature of the Consultant with Stamp:

Investigations:

R/Tal Pregabalin M 75mg BD To

- Physiotherapy
 - Diathermy

Reception - 0124-4585555 Ambulance - 0124-4585666

Well defined enhancing T2 hyperintense lesion at L1 vertebral level and appears encroaching towards neural foramina measuring 22 x 14 mm likely nerve sheath tumour

Compared to previous MRI dated 12/06/2017 no obvious change in lesion size or character is seen.

Anshul

Dr. Anshul Jain
MD,DM (Neurointerventional
Radiology)
Associate Consultant

Ann. (S)

**DEPARTMENT OF RADIODIAGNOSIS AND IMAGING
REPORT**

Patient Name : VEENA NARAIN
UHID : JHN000172635
Age/Sex : 51Y/F
Requested By : Dr. Saurabh Rawall

Procedure Date : 28/10/2017
Order From : RADIOLOGY-BILL-GF-AB
Accession No. : SC115MRI7005358
Investigation : MRI SPINE PLAIN
LUMBOSACRAL

Ordered Time : 28/10/2017

Reported Time : 28/10/2017 3:32:50

FINDINGS:

Degenerative scoliosis with type I end plate degenerative changes at L4-L5 showing end plate marrow edema on STIR.

Rest of the vertebrae are normal in height and alignment and shows normal marrow signal.

Disc desiccation changes noted from L3-L4 to L5-S1 with annular tear at L4-L5 and L5-S1 at reduced disc space at L4-5 level.

Diffuse disc bulge is seen at L3-L4 level indenting the thecal sac.

Diffuse disc bulge is noted at L4-L5 indenting the thecal sac and causing mild to moderate bilateral neural foramina narrowing.

Diffuse disc bulge is noted at L5-S1 causing no significant canal/neural foramina narrowing.

Well defined enhancing T2 hyperintense lesion is seen at L1 vertebral level and appears encroaching towards neural foramina measuring 22 x 14 mm likely nerve sheath tumour

The primary lumbar canal is adequate in diameter with no evidence of stenosis. The lower end of the spinal cord, conus medullaris and nerve roots of the cauda equina are normal.

The thecal sac is normal and CSF demonstrates normal signal intensity.

No intra spinal mass or pre/paravertebral collection seen.

IMPRESSION:

Degenerative scoliosis with type I end plate degenerative changes at L4-L5 showing end plate marrow edema on STIR.

Diffuse disc bulge is noted at L4-L5 indenting the thecal sac and causing mild to moderate bilateral neural foramina narrowing.

Saurabh Rawall

MS Ortho (AIIMS), FNB Spine Surgery, Fellowship in Spine Surgery (Canada)

INSTITUTE OF SPINE

Consultant

Mob.: +91 98688 97026 E-mail: saurabh.rawall@jalindia.co.in

OP CASE SHEET

MRN	: JHN000172635	Date	: October 28, 2017 15:45
Patient Name	: Mrs Veena Narain	Visit No	: OP-003
Sex / Age	: Female/52 Years 18 Days	Consultation Type	: REVISIT
Address	: Additional District Judge, Hapur, Uttar Pradesh	Mobile No	: 9935854411
Queue No	: 14	How name	: CASH



Weight: _____ (kg) Height: _____ (cm) BP: _____ (mmHg)
 Pain Score(0-10): _____ Pulse/HR _____ Allergies (if any) _____

History:-

~~MR~~
No chgs : size of tumor

Hy

Needs. surgery.

Clinical Assessment :

Z. ETOSINE MR 0 _____ 0 x 5 days

Z. PAN 40 0 _____ x 5 days.

Physiotherapy - 10 day

Yoga / Exercise.

Ann. 6

Indian Spinal Injuries Centre

NABH & NABL Accredited Organization



DEPARTMENT OF RADIOLOGY & DIAGNOSTIC IMAGING

Sec. C, Vasant Kunj, New Delhi-110 070
Ph. : 91-11-4225 5225 (30 Lines), Extn.: 220, 224 & 365 Fax : +91 11 2689 8810
E-mail : info@isiconline.org Web : www.isiconline.org Emergency : 011-42255295

MS. VEENA NARAIN	53/F
16/05/2019	
DR. ANKUR NANDA	UHID-648905/CA/957376

M.R.I. OF THE LUMBOSACRAL SPINE WITH CONTRAST

Sagittal T1 & T2 weighted scans of the lumbar spine were studied and these were correlated with axial T1 & FSE T2 weighted images.

L4-5 intervertebral space is especially reduced with degenerated bulging intervening disc encroaching upon lateral neural canals – more towards left side and foraminal compromise is further compounded by facet joint arthropathy.

L5-S1 intervertebral disc is also bulging posterolaterally towards left side, compromising the lateral neural canal.

At other disc levels, thecal sac containing cauda equina and lumbar intervertebral foramina seem adequately capacious.

Lower end of the spinal cord displays uniform parenchymal signal intensities.

Paravertebral psoas muscles are unremarkable.

Pear shaped soft tissue intensity mass-like lesion is seen extending posterolaterally from L1-2 intervertebral foramen into posterior paraspinal muscles – this likely nerve sheath tumor measures up to 17.2 x 38.5 x 24.3 mm in maximum AP, cephalocaudal and lateral dimensions respectively.

IMPRESSION: MR scan has revealed pear shaped likely nerve sheath tumor extending posterolaterally from L1-2 intervertebral foramen in posterior paraspinal muscles.

Degenerated L4-5 and L5-S1 intervertebral discs are encroaching upon lateral neural canals toward left side, and foraminal compromise at L4-5 level is further compounded by facet joint arthropathy.

Please correlate clinically

DR. Rajesh Kapur, MD
SR. CONSULTANT RADIOLOGIST



Sector - C, Vasant Kunj, New Delhi - 110070 Ph.: 91-11-42255225 (30 Lines), For Appointment - Ext. 201
 Fax : 91-11-26898810 E-mail: appointment@isiconline.org Visit us at : www.isiconline.org

OPD CARD

Registration No. 208905

Name Veena Narain

Age..... M/F..... DOB

Address

Phone

Consultant Dr. Ankur Nanda

✓ Please bring this card on all subsequent visits.

DEPTT. OF SPINE SERVICES

UHID : 648905 Bill Date: 16/05/2019 Age/Sex 53 Yrs F

NAME : Mrs. VEENA NARAIN

DOCTOR: DR. ANKURNANDA

COMPANY : ISIC - 2019

ADDRESS : 47 GYAN LOK HAPUR UTTAR PRADESH INDIA

MOB No : 9935854411



Date Chief Complaints / Past History

ISIC OPD

Date 16/5/19

Signature [Signature]

2007

PND

Allergies if any (Please Specify)

Excr cyst

2017

Investigations Advised / Reports

(AP) Pelvic/Spinal

Bony tumor @ sac.

Treatment Advised

Post laminectomy

2013

Go → Back pain.
 ⇒ Change in position.

CIE: Numbly @

Ad.

(PT) BACK STRENGTHENING EX.
 → CORE STABILIZATION EX.
 → SHOULDER COMPLEX EX.
 → ISOMETRIC, NORA PA

⇒ (P) → US & BIPASU | (10) @
 ⇒ MRI & BAC

(1) Tab SUPRACAL
 Doctor's Name and Signature [Signature]



NABH & NABL Accredited
 FOD/QF/03/01/10-01-15

Date

→ BMD DGTX Scan.
Spine @ hips.

→ Refer to Dr. Arun Sharma
Room - NO - 25.

del

16/05/19

MRI (2017) - Right L1 Extraforaminal
? nerve sheath tumour extending
into foramen

S. Greadmore

Act - ① MRI - Lumbosacral spine with
contrast

↓
- No significant change in size of
tumour as compared to earlier scan (2017)
- L4/5 - degenerative changes

- Act ① Tab Tolperidas 15mg 180 \times 5 days
- ② Cap Felzeta 100 \times 10 days
- ③ Isometric back exercises

Dr. Arun Sharma
M.B.B.S., M.S., M.Ch
Consultant Neurosurgeon
DMC No. 34574
Indian Spinal Injuries Centre
Sector-C, Vasant Kunj, New Delhi-110070

del



P-1 P-2 P-3

Name	MRS. VEENA NARAYAN	Age/Sex	52 YRS/FEMALE
Patient_ID	140274	Pt Mobile NO	09935858441
Issue Date	03-Sep-2019 17:52	Doctor's Name	Dr. RAJIV MOTIANI
Doctor's Dept	NEUROLOGY	Doctor's Timing	5:00 pm to 8:00 pm (Mon to Sat)
Height	_____ (cm)	Weight	_____ (kg)
Pain Score(0-10)	_____	Allergies If Any	_____
		Temp	_____
		Pulse	_____
		Bmi	_____
		BP	_____ (mmHg)

Dr D. J. Sharma
Neurosurgeon to see

R
3/Sept/19

Δ chr lumbar radiculopathy
 x > 10 yrs. - PIVD L4-5
 L5-S1
 ? Neurofibroma
 22 x 14 mm at L1
 new 17K3 B x 24 mm in
 last MRI (16/5/19)

MRE: - L4-5 & L5-S1, MVD @ L4-5
 disc causing left radicular compression

1 T. LYRICA 750mg HS
 2 T. NEUROBION FORTE 1-1
 3 Cap VIBRANIA-D 1xOD
 4 T. PANTOL 40mg OD
 5 T. FLEXON-MK 1-1 x 3d.

In Case of Emergency, Please Call On - 0120-4880077

- Back strengthening exercises
 physiotherapy

19

- Ⓟ Rx Mergalup AT (1/2) Daily (9mm)
- Ⓟ Rx Vibramo D (1) Daily (9mm)

30/11/15

Review 30/11/15

Rx Mifencol - p (1) — 5
 Rx Razo 20 (1) — 5

500mg 500mg

2/12/15

2/12/15

Neurologically
stable

- Ⓟ Rx Mergalup AT (1) Daily (9mm)
- Ⓟ Rx Vibramo D (1) Daily (9mm)

MRI Lumbosacral spine
 - Contrast after biopsy

Review 6 weeks

2/12/15

SARVODAYA HOSPITAL & RESEARCH CENTRE

(UNIT OF GHAZIABAD NURSING HOME PVT. LTD.)

KJ-7, Kavi Nagar, Ghaziabad (U.P.) Tel. : 0120-2701694, 4228429, 9811085835 Fax 0120-2800450

www.sarvodayahospitalgzb.in • E-mail : info@sarvodayahospitalgzb.in

CIN-U74899DL1987PTC026952

Mr. Veena Narayan. 52y/12

Date: 16/9/25

Chronic Back ache - from 10-15y
 ↑↑ last 2yrs.
 Car Accidents Both lower limbs.

MRI Spine & ? Neuroforams of
 cervical

A. Ref to higher cen
 Dept of Neuro Ortho AIMS
 for further mgmt W. Delhi

Navleen Jain
 Dr. NAVREEN JAIN
 M.B.B.S. M.S
 Laparoscopic And G. Surgeon
 OPD-12 Noon 2 PM
 8 PM 9 PM
 Mob. 9811242371

The Hospital is Under Panel of :

- ★ Alankit Health Care TPA Ltd.*
- ★ Appolo Munich Health Insurance Co. Ltd.
- ★ Bajaj Allianz General Insurance Co. Ltd.
- ★ Cholamandalam MS General Insurance Co. Ltd.
- ★ Dedicated Healthcare Service TPA (India) Pvt. Ltd.*
- ★ E-Mediteck TPA Services Limited*
- ★ Ericson TPA Healthcare Pvt. Ltd.*
- ★ Family Health Plan (TPA) Limited*
- ★ Future Generali India Insurance Co. Ltd.
- ★ Genine India TPA Limited*

- ★ Good Health Plan Ltd.*
- ★ HDfC ERGO General Insurance Co. Ltd.
- ★ Health India TPA Service Pvt. Ltd.*
- ★ ICICI Lombard General Insurance Co. Ltd.
- ★ Iffco Tokio General Insurance
- ★ L & T General Insurance Co. Ltd.
- ★ Max Bupa Health Insurance Co. Ltd.
- ★ MD India Healthcare Service (TPA) Pvt. Ltd.*
- ★ Med Save Healthcare (TPA) Limited*
- ★ Medi Assist India Pvt. Ltd.*

- ★ Medi Care TPA Service (I) Pvt. Ltd.*
- ★ Raksha TPA Pvt. Ltd.*
- ★ Religare Health Insurance Co. Ltd.
- ★ Safeway TPA Services Pvt. Ltd.*
- ★ Spurthy Meditech (TPA) Solutions Pvt. Ltd.*
- ★ Star Health & Allied Insurance Co. Ltd.
- ★ TTK/Vidal Health TPA Pvt. Ltd.
- ★ United Healthcare TPA*
- ★ United Healthcare Parekh TPA*
- ★ Universal Sompo General Insurance Pvt. Ltd.



NC 2019/016/0025723

UHID: 104783037

Date 24/10/2019

Name VEENA NARAIN

Phone No. 9935854411

Consultant Room

SR Room 7



Neurology

MON,THU

Neurology-II

Charges Rs. 0.0/-

54Y 14D /Female

Scr



Ann. (D)

हृदय वक्ष एवं तंत्रिका विज्ञान केन्द्र
 ब० रो० वि०
 अ० भा० आ० सं०, नई दिल्ली-110029
 Cardiothoracic & Neurosciences Centre, O.P.D.
 A.I.I.M.S., New Delhi-110029

दिनांक/Date

विभाग

Deptt.

ब०रो०वि०सं०
O.P.D. No.

NS 2019/017/0013880

UHID: 104783037

Date 24/10/2019 Mon, Thu

Name VEENA NARAIN

W/O: Rakesh Narain

Phone No. 9935854411

Consultant Room 17

SR Room:

Registration Time: 8.30 AM - 10.30 AM

Neuro Surgery-I

General

Neuro Surgery

Gen

54Y 14D/Female

Dr. G D SATYARTHEE

Thursday Only: 12.30 PM - 2.30 PM

Go low backache + radiation to (L)
L5 distribution

MRI L3/4 spine

(R) extraparaspinous
mass (likely
Nerve sheath tumor)
in L1-L2 intervertebral
foramen

(L) s/d disc bulge
L4/5

Adv.

- T. Pregablin M 1 tab H.S.

- T. Vibrania D 1 O.D.
to continue

- X Ray flex/extension lateral
view

- Physiotherapy - (23)

- Avoid stairs/Avoid heavy weights

- Avoid bending forwards

- Rest on hard bed

Please share your feedback to improve our hospital on the Website link: meraasptaal.nhp.gov.in

हृदय वक्ष एवं तंत्रिका विज्ञान केन्द्र
ब० रो० वि०
अ० भा० आ० सं०, नई दिल्ली-110029
Cardiothoracic & Neurosciences Centre, O.P.D.
A.I.I.M.S., New Delhi-110029

दिनांक/Date

विभाग
Deptt.

ब०रो०वि०सं०
O.P.D. No.

NC 2019/016/0025723

UHID: 104783037

Date 24/10/2019 MON, THU

Name VEENA NARAIN

W/O: Rakesh Narain

Phone No. 9935854411

Consultant Room

SR Room: 7

Registration Time: 8.30 AM - 10.30 AM

Neurology-II

Charges Rs. 0.0/-

Neurology

Scr

54Y 14D /Female



Diagnosis

LBA

24/10/19

54yr female

Hypertension (on Ethosin 100mg OD)
x 20 yrs

410 Low back ache x 2007
mild - moderate
recurred over 1-2 yrs.

Mt LS spine - L4-L5 & L5-S, PVD

2015-2016 - Back pain mild - moderate
moderate severe; gradually increasing
cl to stretching pain in left lower limb
x 2-3 months

Please share your feedback to improve our hospital on the Website link: meraaspatal.nhp.gov.in

65

Mrs Veena Nareni 54y female

R ✓
 ① Mr. Margalep Ar ~~9pm~~ → ① 9pm } to continue
 ② by Vibrano D (Duty) (9pm)

③ Tel. Nalanda MR ① — ① } SDA
 ④ N. Rao 20 ① ② }
 ⑤ ① ②

Advind
 MRI kumbhacised
 Spine - Contrast

Person 2 weeks

R
 27/11/15
 (Dr. Rupa Malani)

The new health care destination

MULTISPECIALITY

A unit of Arisika Medical Centre Pvt. Ltd.

Free lab sample collection from home within Noida. Contact : 9773639006 / 9773639007

MRI LUMBOSACRAL SPINE WITH CONTRAST

ID: 6847/148593
VEENA NARAIN
DR. RAJIV MOTIANI

01.12.2019
54 YRS/F

STUDY PROTOCOLS:

FLAIR T1W AND FAST SPIN ECHO T2W HIGH RESOLUTION SAGITTAL IMAGES OF LUMBOSACRAL SPINE WERE OBTAINED ON A DEDICATED PHASED ARRAY SURFACE SPINE COIL USING 1.5 TESLA TWIN GRADIENT SYSTEMS AND CORRELATED WITH T1W AND T2W AXIAL IMAGES. POST CONTRAST IMAGES DONE IN THREE PLANES.

FINDINGS:

Levoscoliosis of lumbar spine is seen.

Spondylotic changes are seen in the form of osteophytes at multiple levels.

Vertebral bodies are normal in height, alignment and marrow signal intensity. Rest of posterior spinal elements are normal.

Diffuse disc bulge is seen at L4-L5 level indenting anterior thecal sac effacing bilateral lateral recesses and impinging on descending nerve roots. AP canal diameter -1.3cm.

Diffuse disc bulge is seen at L5-S1 level indenting anterior thecal sac effacing bilateral lateral recesses and mildly impinging on descending nerve roots. AP canal diameter - 1.2cm.

Left facetar arthropathy is seen at L5-S1 level.

There is evidence of T2 hyperintense extra-foraminal lesion seen at L1-L2 level right paraspinal region measuring 1.6 x 2.4 x 3.7 cm in size (AP X TR X CC) . The lesion shows intense homogenous contrast enhancement
Bony canal is capacious at all levels.

Distal cord and conus medullaris region appear normal in MR morphology.

Pre and paravertebral soft tissues are normal.

DIAGNOSIS:

- Levoscoliosis of lumbar spine is seen.
- Diffuse disc bulge at L4-L5 level indenting anterior thecal sac effacing bilateral lateral recesses and impinging on descending nerve roots.
- Diffuse disc bulge at L5-S1 level indenting anterior thecal sac effacing bilateral lateral recesses and mildly impinging on descending nerve roots.
- Left facetar arthropathy at L5-S1 level.
- T2 hyperintense extra-foraminal lesion seen at L1-L2 level right paraspinal region. The lesion shows intense homogenous contrast enhancement- likely neurofibroma.

As compared to the old MRI dated 16.05.2019, the right paraspinal lesion shows no significant change.

Please correlate clinically.

DR. ANMOL NIGAM
MD RADIODIAGNOSIS
CONSULTANT RADIOLOGIST

DR. RITESH SINGH
DNB RADIODIAGNOSIS
CONSULTANT RADIOLOGIST

DR. VIVEK RATHORE
MD RADIODIAGNOSIS
CONSULTANT RADIOLOGIST

The new health care destination

MULTISPECIALITY

A unit of Muskan Medical Centre Pvt. Ltd.

Free lab sample collection from home within Noida. Contact : 9773639006 / 9773639007