



PACE

HEART CENTRE PVT. LTD.

DR. ATUL KUMAR SHAHI

M.D. (Medicine), D.M. (Cardiology)

P.G.I. Chandigarh

Cardiologist

Reg. No. 33939 (MCI-UP)



D-101, Budh Vihar Commercial, Taramandal,
Paidaleyganj to Rustampur Highway, Gorakhpur. (U.P.)

Timing : 10.00 am to 5.00 pm | Sunday Closed

Mobile : 7668006926, 9695889878

Name : _____

Age : _____ Sex : _____ Date : _____

Address _____

Phone : _____



Please bring this file on every visit.

डा. अतुल कुमार शाही
DR. ATUL KUMAR SHAHI
M.D. (Medicine), D.M. (Cardiology)
P.G.I. Chandigarh

हृदय रोग विशेषज्ञ
Reg. No. 33939 (MCI-UP)



पेस
हार्ट सैन्टर प्रा. लि.

D-101, बुद्ध विहार कामरियल, तारामण्डल, पैडरौज से कलकत्ता हाईवे पर, गोरखपुर, मोबाईल : 7688006926, 9695889878

Pts Name: Mr. Manoj Mishra Residence: Deoria Age/Sex: 57/M Date: 25/5/24

Ref: Dr. C. P. Singh ECG: may 2024 PR: 80ms BP: 120/80mmHg

Ref: Dr. Singh CART: No Pail Keya / clubbing / Ped. Oed. / Jaundice

Ref: Dr. Singh PCI: No CVS: M Respiratory: -

Ref: Dr. Singh ABD: No CNS: -

By Dr. A.K.

अतुल कुमार शाही
R. ATUL KUMAR SHAHI
 D. (Medicine), D.M. (Cardiology)
 Chandigarh
 रोग विशेषज्ञ
 No. 33939 (MCI-UP)



पेस
हार्ट सेन्टर प्रा. लि.

99150 82034

01, बुढ़ विहार कामर्शियल, तारामण्डल, पैडलेगंज से रुस्तमपुर हाईवे पर, गोरखपुर. मोबाईल : 7668006926, 9695889878

Name: Mr - Manoj Mishra Residence: Deoria Age/Sex: 55y/F Date: 23 MAY 2020
 Issue: CAD VA ECG: AF & RVR PR: 10mm BP 120/80 JVP:
 AF & RVR EF: Pall / cya / clubbing / Ped. Oed. / Jaundice
 CART: CVS: H Respiratory:
 PCI: ABD: M CNS: N

Temp: 36.6 °C

↓

- ~~C. Clopidogrel 75 mg qd~~
- ~~1. Statins XL 50mg qd~~
- ~~2. Lipitor 20mg qd~~
- ~~3. Aced 400 2.6mg qd~~
- ~~4. Aspirin 100mg qd~~
- ~~5. Substrate 5y~~

29/5/20


CAD SYD

↓

Ad PCI to CAD

Ⓜ

- 1. Loprin DS 100mg qd
- 2. Axxer 90 mg qd



~~T. Clopidogrel 75 mg qd~~
 Resolved by

DOA 30/5/20

DOA 31/5/20

PCI to m LAD

CSF

RO 3x 34mm

R/L 1ml

Resolute Onyx™
 3.0mm x 34mm

REF RONYX30034X
 LOT 0009551137
 2021-01-22

310 JUN 2020

Tmp: 97.6 F

T. Moxikind 400mg qd
 to TOR 5dy

7 SEP 2020

तत्काल

I PR 10mm
 BP 140/90


CLL

LA 3ml

I PR 10mm

BP 140/90

23/1/20



रविवार बंद (समय : सुबह १० से ५ बजे तक)

PCI REPORT

PATIENT'S NAME:- MR. MANOJ MISHRA AGE/SEX- 50Y/M DATE-31/05/2020
PCI NO : 0103/2020

OPERATOR: DR. ATUL KUMAR SHAHI M.D. D.M.
ASSISTED BY : MS. DIVYA.
CLINICAL DIAGNOSIS : CAD
CONTRAST USED :- OMNIPAQUE 350
ANTICOAGULANT USED : UFH – 10000 UNITS
GUIDING CATHETERS USED :- XB 3.5 6F
CORONARY WIRE USED: SION 0.014
ROUTE :- RRA

PROCEDURE DETAILS: LEFT CORONARY ARTERY ENGAGED WITH XB 3.5 6F GUIDING CATHETER. MID LAD LESION CROSSED WITH SION 0.014" CORONARY GUIDE WIRE. LESION PREDILATED WITH RYUJIN PLUS 2.5*15 BALLOON AT 12.0 ATM PRESSURE. A **RESOLUTE ONYX (DES)** 3.0* 34.0MM STENT DEPLOYED ACROSS THE LESION AT 12.0 ATM PRESSURE. POST BALLOON DILATATION DONE WITH ACCUFORCE 3*8 mm. BALLOON AT 12-20 tm pressure. TIMI – III FLOW ACHIEVED. NO RESIDUAL STENOSIS.

RECOMMENDATION: MEDICAL MX. & LIFE STYLE MODIFICATION.

Resolute Onyx™ 
3.0 mm x 34 mm
REF RONYX30034X
LOT 0009551137
2021-01-22


DR. ATUL KUMAR SHAHI
M.D. (MEDICINE)
D.M.(CARDIOLOGY)
Consultant Interventional Cardiologist

- ◆ Electrocardiography
- ◆ Treadmill Test
- ◆ Echocardiography And Colour Doppler
- ◆ Stress Echocardiography

- ◆ Transoesophageal Echocardiography
- ◆ Temporary Pacemaker
- ◆ Permanent Pacemaker
- ◆ Coronary Care Unit

- ◆ Private Room
- ◆ Angiography
- ◆ Angioplasty

CORONARY ANGIOGRAPHY REPORT

PATIENT'S NAME: MR. MANOJ MISHRA
CART NO : 0698/2020

AGE/SEX: 50 Y/M

Date- 29-May-20

OPERATOR: - DR. ATUL KUMAR SHAHI M.D. D.M. CARD.

ASSISTED BY: MS. DIVYA

TECHNICIAN: MR. C.D. UPADHYAY

CLINICAL DIAGNOSIS: - CAD

CONTRAST USED: - OMNIPAQUE 350

CATHETERS USED: - TIG 5F

ANTICOAGULANT USED: - UFH

ROUTE: - RRA

HIV - 1&2 NEGATIVE
HBsAg - NEGATIVE
ANTI HCV - NEGATIVE

RIGHT CORONARY ARTERY: NORMAL REFLUX. NORMAL & . DOMINANT ARTERY.

LEFT MAIN CORONARY ARTERY: NORMAL REFLUX. NORMAL ARTERY.

LEFT ANTERIOR DESCENDING CORONARY ARTERY: MID LAD SHOWS 90.0% STENOSIS.

LEFT CIRCUMFLEX ARTERY: LCX NORMAL & . NON - DOMINANT ARTERY.

PRESSURE : AORTIC PRESSURE - 119/70 mmHg.

FINAL IMPRESSION:

- SINGLE VESSEL DISEASE.
- RIGHT DOMINANT CIRCULATION.

RECOMMENDATION: MEDICAL MANAGEMENT & PCI TO LAD.

DR. ATUL KUMAR SHAHI
M.D. (Medicine)
D.M. (Cardiology)

CARDIOVASCULAR INTERVENTIONIST

◆ Electrocardiography

◆ Treadmill Test

◆ Echocardiography And Colour Doppler

◆ Stress Echocardiography

◆ Transoesophageal Echocardiography

◆ Temporary Pacemaker

◆ Permanent Pacemaker

◆ Coronary Care Unit

◆ Private Room

◆ Angiography

◆ Angioplasty


Name :: MR. MANOJ MISHRA

Sex/Age :: Male/50 Years

Procedure :: ECHOCARDIOGRAPHY

Patient ID :: 29May2020_022

Date :: May 29, 2020



SPECIAL COMMENT :-

- NO CLOT /VEGETATION /PERICARDIAL EFFUSION /RWMA.

FINAL IMPRESSION :-

- NORMAL ECHO STUDY.



DR. ATUL KR. SHAHI M.D. D.M.



PATIENT ECHO WINDOW :- POOR / **ADEQUATE** / GOOD

M-MODE MEASUREMENTS :-

AORTA:.....37.....mm; LEFT ATRIUM:....37...mm
 RVIDd :.....mm
 IVSd :7...mm ; IVSs :.....12...mm
 LVIDd :44...mm ; LVIDs:....23...mm
 LVPWd : ...7...mm ; LVPWs:..10.....mm
 EPSS :mm
 LV MASS :.....
 IVS/LVPW RATIO :.....
 FS :...47.0...% ; LVEF :....79.0..%
 EDV : ; ESV :
 IVS : **NORMAL** / SIGMOID / PARADOXICAL
 IVS : INTACT
 IAS : INTACT

CARDIAC CHAMBERS :-

LEFT VENTRICLE :- **Normal** / Hypertrophy / Dilated / Thinned out / Aneurysmal
 FUNCTION :- **Normal** / Reduced

RIGHT VENTRICLE :- **Normal** / Hypertrophy / Dilated / Apical Obliteration / Rudimentary
 FUNCTION :- **Normal** / Reduced

LEFT ATRIUM :- **Normal** / Enlarged

RIGHT ATRIUM :- **Normal** / Enlarged

PERICARDIUM : **Normal** / Absent / Thickened / Calcified / Constriction / Mass / Effusion

LV. VOLUME & EF :-

M-MODE :-	MOD. SIMPSON :-
ESV :ml/m2	ESV :ml/m2
EDV :ml/m2	EDV :ml/m2
EF :...79.0...%	EF :%

MITRAL VALVE STUDY :-

ANTERIOR MITRAL LEAFLET :- **Normal** / Thickened / Doming / Calcified / Prolapse / Prosthesis / Flail
 SAM / Cleft / Perforation / Restricted Mobility

POSTERIOR MITRAL LEAFLET :- **Normal** / Thickened / Doming / Calcified / Prolapse / Prosthesis / Flail
 SAM / Flat / Fixed / Cleft / Perforation / Restricted Mobility / Paradoxical

MITRAL VALVE SCORE :- Thickness :-	Mobility :-
Subvalvular Apparatus :-	Calcification :-
Total :-	

MITRAL STENOSIS :- **Absent** / Mild / Moderate / Severe

MVA:.....cm2;cm2

(By 2D) (By PHT)

Max. Gradient :.....mm Hg ; MDG :.....mm Hg ; HR :...../min.

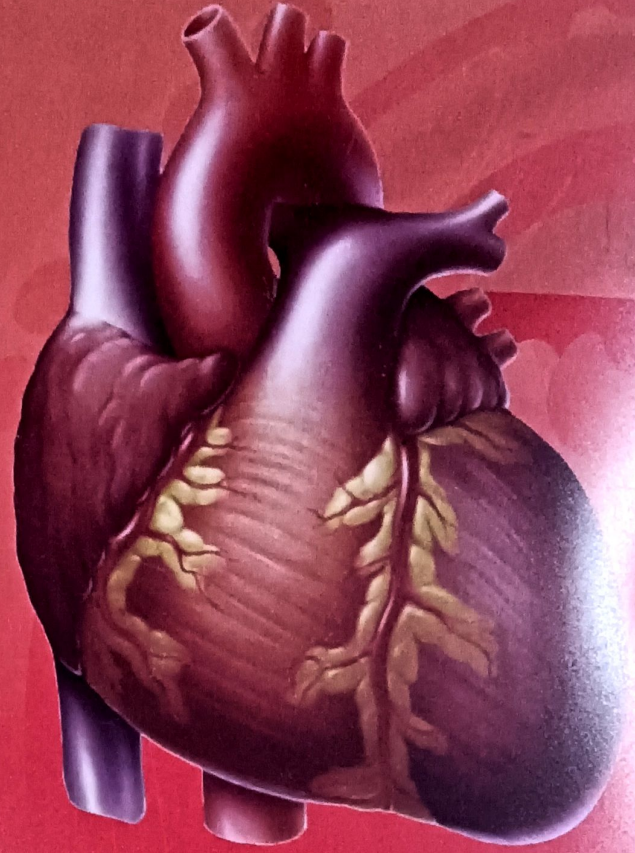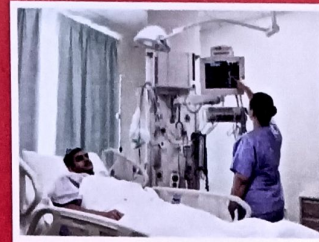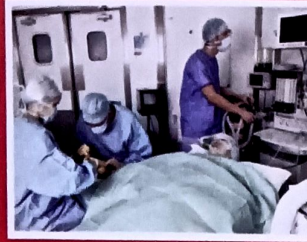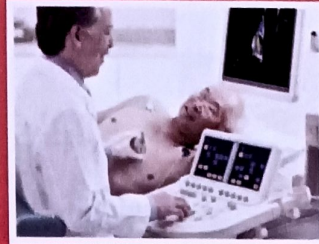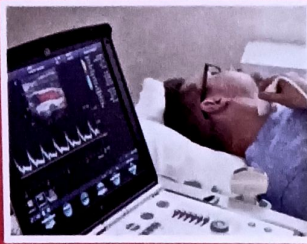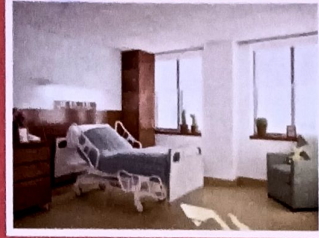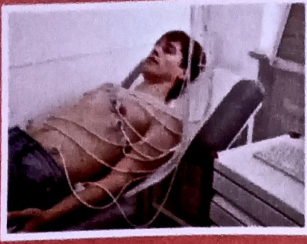
- ◆ Electrocardiography
- ◆ Treadmill Test
- ◆ Echocardiography And Colour Doppler
- ◆ Stress Echocardiography
- ◆ Transoesophageal Echocardiography
- ◆ Temporary Pacemaker
- ◆ Permanent Pacemaker
- ◆ Coronary Care Unit
- ◆ Private Room
- ◆ Angiography
- ◆ Angioplasty

Trivial / Mild / Moderate / Severe
Absolute Jet Area :cm²
Mitral Regurgitation Area :cm² / Left Atrial Area :cm² (PLAX)
Mitral Regurgitation Area :cm² / Left Atrial Area :cm² (4C)
Mitral Regurgitation Area :cm² / Left Atrial Area :cm² (2C)
Severity of Mitral Regurgitation (By Pulse Doppler) : Grade I / II / III / IV
Nature Of Regurgitation Jet : Central / Eccentric / Multi
Mitral Annular Diameter :mm
MITRAL INFLOW VELOCITY :-
E-Wave velocity : ...0.7.....m/sec, A-Wave velocity : ...0.5.....m/sec
IVRT :m/sec, EDT :m/sec
, E<A, E=A, E>>A, MONOPHASIC
TRICUSPID VALVE :- Normal Thickened / Doming / Calcified / Prolapse / Flail /
Restricted Mobility / Apically Displaced / Atretic
TRICUSPID STENOSIS :- Present Absent
Max. Gradient :mm Hg, MDG :mm Hg, HR :/min
TRICUSPID REGURGITATION :- Absent / Trivial / Mild / Moderate / Severe
RVSP =+RAP (mmHg)
Tricuspid Annular Diameter :mm

AORTIC VALVE STUDY :-
AORTIC VALVE :- Normal Thickened / Doming / Calcified / Prolapse / Non-Coapting / Prosthesis
MORPHOLOGY :- Bicuspid / Tricuspid / Not Clear / Quadricuspid
AFV :1.0.....m/sec.
AORTIC STENOSIS :- Absent Mild / Moderate / Severe
Max. Gradient :mmHg, Mean Gradient :mmHg, HR : /min
Jet Velocity :m/sec
Level of Obstruction :- Valvular / Sub Valvular / Supra Valvular
Aortic Annular Diameter :mm
AORTIC REGURGITATION :- Absent Trivial / Mild / Moderate / Severe
Slope :mm, PHT :m/sec ; EDG :mm Hg
ARJH :mm , LVOT :mm

PULMONARY VALVE STUDY :-
PULMONARY VALVE :- Normal Thickened / Doming / Prolapse / Atretic / Absent
PFV :1.5.....m/sec ; PAT :m/sec ; Pul. Annular Diameter : ...mm
PULMONARY STENOSIS :- Absent / Mild / Moderate / Severe
Max. Gradient :mmHg, MDG :mmHg, HR : /min
Level of Obstruction :- Valvular / Sub Valvular / Supra Valvular
PULMONARY REGURGITATION :- Absent Trivial / Mild / Moderate / Severe
Max. Gradient :mm Hg, EDG :mm Hg ; Jet Length :mm
PRJH :mm , RVOT :mm
MPA :mm , RPA :mm , LPA :mm

DR. ATUL KUMAR SHAHI
D.M.(CARDIOLOGY)



FACILITIES AVAILABLE

- Electrocardiography
- Treadmill Test
- Echocardiography And Colour Doppler
- Stress Echocardiography
- Transoesophageal Echocardiography
- Temporary Pacemaker
- Permanent Pacemaker
- Coronary Care Unit
- Private Room
- **Angiography**
- **Angioplasty**



पेस हार्ट सेन्टर प्रा. लि.

D - 101, बुद्ध विहार कार्मशियल, तारामण्डल, पैडलेगंज से रुस्तमपुर हाईवे पर, गोरखपुर. (यु.पी.)

डा. अतुल कुमार शाही
हृदय रोग विशेषज्ञ