


Patient: Saraswati Devi Age: 65 Sex: F
UHID: MM00134091
Dr.: Dr. Anil Bhan

dedicated
to
life

MM00134091

Mrs. Sateswati Devi

1



Medanta Heart Institute

Age - 65 yrs / F

Dr. Anil Bhan

MBBS (Gold Medalist), MS (General Surgery),
MCh (CTVS-AIIMS)

Chairman
Division of Cardiac Surgery
anil.bhan@medanta.org
Mob: +91 99109 29993

Whatsapp: +91 99584 99339
Regd. No. J&K - 2629,
Haryana Medical Council - NH005058

F/U/c of CABG x3 (RSCA - LAD,
Ding, LRA - om) on 12/7/11

Dm
EF - 55%.

H/O Sp → Hysterectomy, cholecystectomy
(12/12/19)

dt: - 05/09/2021

G. 97.2 F

P. 74/min

R. 16/min

- Recurrent VRTI
- SOB on walking.
- cramps in B/L Lower limbs.

BP 140/80 mmHg.

SpO₂ 96%

wt: - 47.3 kgs.

Ht: - 135 cms.

Adv

Continue all medication

Hb - 10 ↓

Review After 1 Months With The Following Tests

CBC
Blood Sugar F/PP -
Lipid Profile -
Thyroid Function -
RFT/LFT -

Chest X-Ray PA View
ECG
Echo

Accredited by



For Medical Queries: Dr. Razia Ahmed +91 99991 43187

For Appointments: Hotial +91 88004 94246, Mahender +91 88004 94266

For Emergency & Ambulance: Dist. ...

BIHAR DIAGNOSTICS

COMPLETE DIAGNOSTIC SOLUTION

BIHAR DIAGNOSTICS & RADIOLOGY CLINIC

222 / 223 B, Patliputra Colony, Patna-800 013

ISO 9001 : 2015

Regd. No: 446/102019

Dr. Chandan Kishore

Senior Consultant - Clinical Radiology
MBBS (SKMC), MD (Pat), FRCR (London)
MCI Reg. No.- 30883, RCR Reg. No.- 316690

Dr. Ratna Priya

Assistant Professor, PMCH, Patna
MBBS (Gold Medalist), MD (Gold Medalist)
MCI Reg. No.- 34301

Patient Name : SARASWATI DEVI
Cont. No : 9122559999
Age/Sex : 65Y/FEMALE
Ref. By Dr. : MEDANTA

Registered : 10/09/2021 13:21
Reported : 10/09/2021 14:36
Regno : BR/21304

Test Report

X-RAY

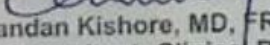
Thanks for referral

CHEST X-RAY- PA VIEW

Status post CABG. Sternal sutures seen in situ.
Mild cardiomegaly seen.
Both Hila are normal.
Bilateral lung fields are clear.
Both CP angles are clear.
Both domes of diaphragms are normal.
Rib cage is normal.

IMPRESSION:

1. Status post CABG. Sternal sutures seen in situ.
2. Mild cardiomegaly seen.
3. No air space opacification or evidence of pleural effusion seen.


Dr. Chandan Kishore, MD, FRCR (London)
Senior Consultant- Clinical Radiology


L96 - ALAM PATH LAB
 S/O Md Aslam, Mainpura Mainpura, Danapur
 PATNA 801503

Name	Mrs. SARSAWATI DEVI	Collected	3/9/2021 2:43:00PM	
Lab No.	297674308	Received	3/9/2021 3:20:49PM	
Age: 66 Years	Gender: Female	Reported	3/9/2021 7:23:24PM	
A/c Status	P	Ref By : Dr. SELF	Report Status	Final

Test Name	Results	Units	Bio. Ref. Interval
COMPLETE BLOOD COUNT; CBC (Electrical Impedance & Flow)			
Hemoglobin	10.10	g/dL	12.00 - 15.00
Packed Cell Volume (PCV)	31.00	%	36.00 - 46.00
RBC Count	3.12	mill/mm ³	3.80 - 4.80
MCV	99.40	fL	83.00 - 101.00
MCH	32.40	pg	27.00 - 32.00
MCHC	32.60	g/dL	31.50 - 34.50
Red Cell Distribution Width (RDW)	14.20	%	11.60 - 14.00
Total Leukocyte Count (TLC)	4.05	thou/mm ³	4.00 - 10.00
Differential Leucocyte Count (DLC)			
Segmented Neutrophils	53.80	%	40.00 - 80.00
Lymphocytes	37.50	%	20.00 - 40.00
Monocytes	5.20	%	2.00 - 10.00
Eosinophils	3.00	%	1.00 - 6.00
Basophils	0.50	%	<2.00
Absolute Leucocyte Count			
Neutrophils	2.18	thou/mm ³	2.00 - 7.00
Lymphocytes	1.52	thou/mm ³	1.00 - 3.00
Monocytes	0.21	thou/mm ³	0.20 - 1.00
Eosinophils	0.12	thou/mm ³	0.02 - 0.50
Basophils	0.02	thou/mm ³	0.02 - 0.10
Platelet Count	199.0	thou/mm ³	150.00 - 410.00

Note

1. As per the recommendation of International Council for Standardization in Hematology, the differential leucocyte counts are additionally being reported as absolute numbers of each cell in per unit volume of blood



Dr Lal PathLabs

Regd. Office/National Reference Lab: Dr Lal PathLabs Pvt. Ltd., Block-C, Tower-3A, Naraina, New Delhi-110028
Web: www.lalpathlabs.com, Call No: +911126199521, 0203268

L96 - ALAM PATH LAB
S/O Md Aslam, Mainpura Mainpura, Danapur
PATNA 801503

Name	Mrs. SARSAWATI DEVI	Collected	3/9/2021 2:43:00PM
Lab No.	297674308	Received	3/9/2021 3:20:49PM
Age: 66 Years	Gender: Female	Reported	3/9/2021 7:23:24PM
A/c Status : P	Ref By : Dr. SELF	Report Status	Final

Test Name	Results	Units	Bio. Ref. Interval
2. Test conducted on EDTA whole blood			

Manju Sharma

Dr Manju Sharma
DCP, Pathology
Chief of Laboratory
Dr Lal PathLabs Ltd

Shilpa

Dr Shilpa Sinha
MBBS, DCP
Chief of Lab

-----End of report-----

IMPORTANT INSTRUCTIONS

- Test results released pertain to the specimen submitted • All test results are dependent on the quality of the sample received by the Laboratory
 - Laboratory investigations are only a tool to facilitate in arriving at a diagnosis and should be clinically correlated by the Referring Physician • Sample repeats are accepted on request of Referring Physician within 7 days post reporting • Report delivery may be delayed due to unforeseen circumstances. Inconvenience is regretted • Certain tests may require further testing at additional cost for derivation of exact results. Kindly submit request within 72 hours post reporting • Test results may show interlaboratory variations • The Courts/Forum at Delhi shall have exclusive jurisdiction in all disputes/claims concerning the test(s) & or results of test(s) • Test results are not valid for medico legal purposes
 - Contact customer care Tel No. +91-11-39885050 for all queries related to test results.
- (#) Sample drawn from outside source.

BIHAR DIAGNOSTICS

COMPLETE DIAGNOSTIC SOLUTION

BIHAR DIAGNOSTICS & RADIOLOGY CLINIC
222 / 223 B, Patliputra Colony , Patna-800 013
ISO 9001 : 2015 Regd. No: 446/102019

Dr. Chandan Kishore
Senior Consultant - Clinical Radiology
MBBS (SKMC), MD (Pat), FRICR (London)
MCI Reg. No:- 30883, FCR Reg. No:- 710886

Dr. Ratna Priya
Assistant Professor, PMCH, Patna
MBBS (Gold Medalist), MD (Gold Medalist)
MCI Reg. No:- 34301

PATIENT NAME: SARASWATI DEVI

AGE/GENDER: 65Y/F

REFD BY: MEDANTA.

DATE: 10/09/2021

ECHOCARDIOGRAPHY

	Patient Value	Normal Value
IVSd/IVSs	12/14	
LVIDd/S	35/25	4.5 - 5.0Cm
LVPWDd/S	12/13	0.8 - 1.1 Cm
Aorta	24	0.8 - 1.1 Cm
Left Atrium	32	3.5 - 4.0 Cm
ACS	16	
R W M A	NO	
MITRAL VALVE E/A	81/110	MR- MILD MVO- N
AV	173/12	AR - TRIVIAL
PV	119/5.7	
TRICUSPID VALVE	93/3.5	PR- TRIVIAL
L V E F	55%	TR-MILD
OTHERS / R V S P	38+RAP	
TAPSE	19	

IMPRESSION :

S/P CABG.

CONCENTRIC LVH. GRADE I DIASTOLIC DYSFUNCTION.

NO RWMA SEEN AT REST. MILD MR, MILD TR, TRIVIAL AR SEEN.

RV/LV FUNCTION NORMAL. EF 55% TAPSE = 19

NO CLOT/VEGETATION/PERICARDIAL EFFUSION



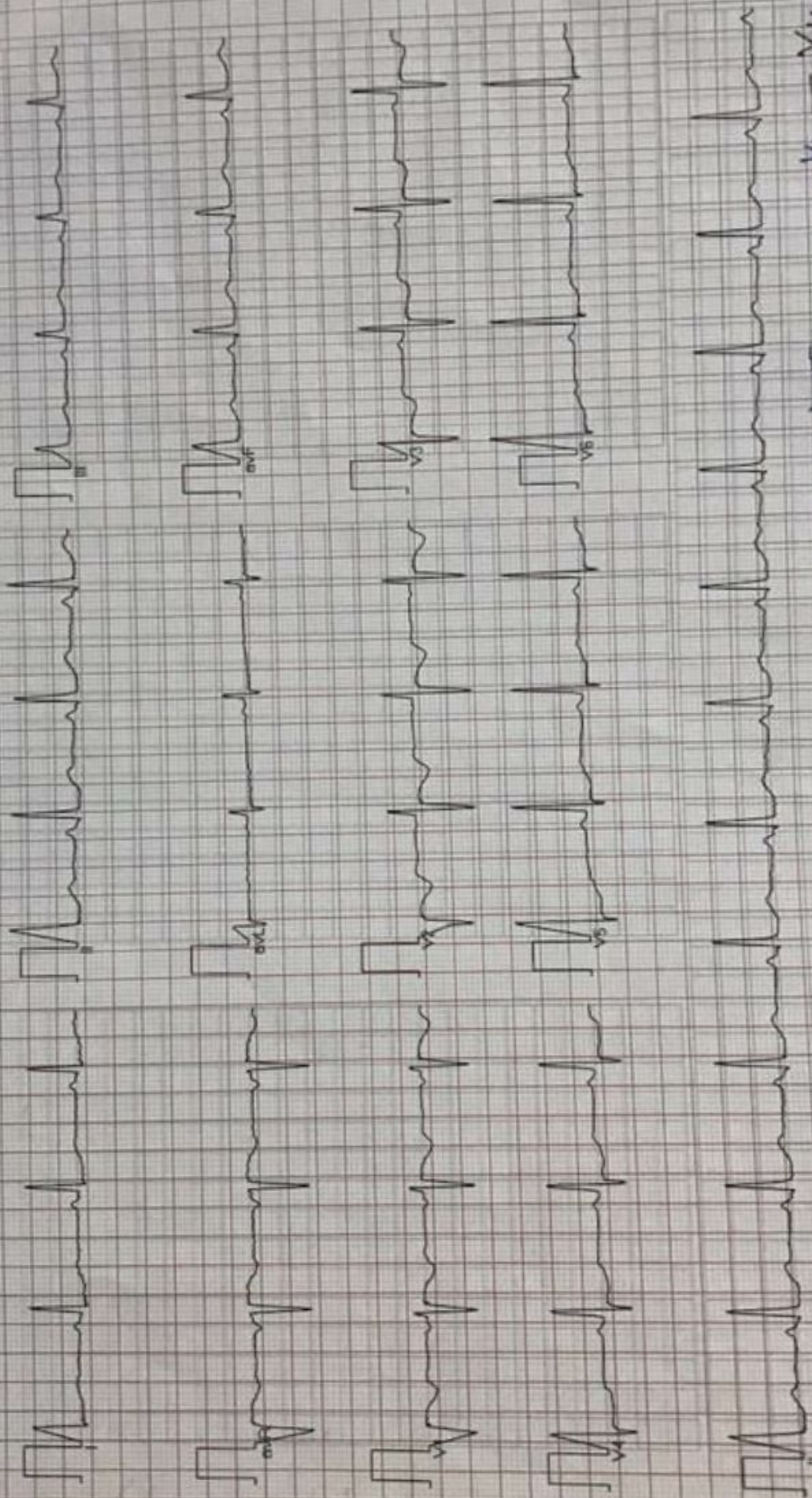
ECG

BIHAR DIAGNOSTIC & RADIOLOGY CLINIC

416 / SARSAWATI DEVI / 65 Yrs / F / 158Cms. / 45Kgs.

Heart Rate : 71 bpm / Tested On : 10-Sep-21 13:52:42 / HF 0.05 Hz - LF 100 Hz / Notch 50 Hz / Sn 1.00 Cm/mV / Sw 25 mm/s

Dr. MEDANTA



depression ST in V1 - V4
 ? ischemia
 Rajan

Heart Rate : 71 bpm
 PR Interval : 130 ms
 QRS Duration : 98 ms
 QT/QTc Int : 412/433 ms
 P-QRS-T axis : 53.00 • 52.00 • 96.00 •
 Sengiers ECG (Pisces) (PI5214180621)