



Tirupati Liver & Gastro Care Center

Dr. Prashant Solanki MD, DM (Gastroenterology)

Gastroenterologist, Hepatologist, Therapeutic Endoscopist

D - 4, Samrat Palace, Opp. Lokpriya Hospital, Garh Road, Meerut

0121-2603166 , 09997756918

LOWER GI ENDOSCOPY

Complementary

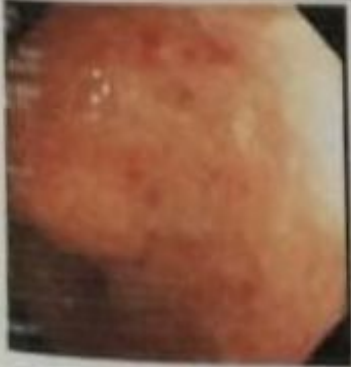
Patient Name : MRS KUSUM LATA

Age/Gender : 48/Female

Date : 25/Jul/20

Referred by : SELF

*W/O Mr. C. Singh
A.B.T. Hep.*



RECTUM - LOSS OF NORMAL VASCULAR PATTERN WITH FRIABILITY & ULCERATION SEEN.

SIGMOID COLON - LOSS OF NORMAL VASCULAR PATTERN WITH FRIABILITY & ULCERATION SEEN.

DESCENDING COLON - LOSS OF NORMAL VASCULAR PATTERN WITH FRIABILITY & ULCERATION SEEN.

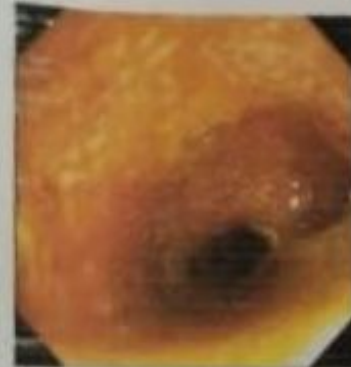
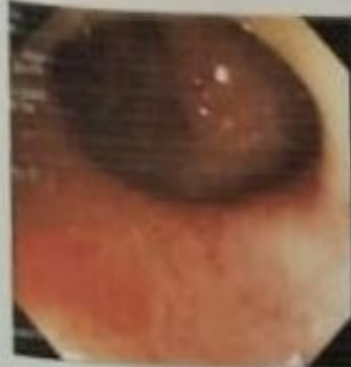TRANSVERSE COLON - NORMAL.

ASCENDING COLON - NORMAL.

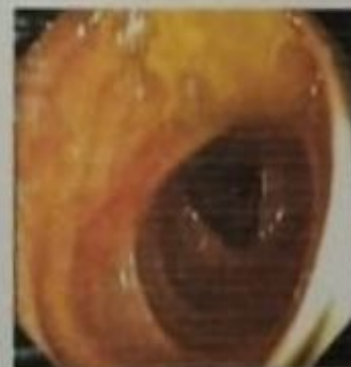
CAECUM & I/C VALVE - NORMAL.

BIOPSY - YES, FROM RECTUM

THERAPEUTIC PROCEDURE - NO.



FINAL IMPRESSION - LEFT SIDED COLITIS - ?CUC.



Dr. Prashant Solanki

MD, DM

Gastroenterology