

Patient Name: Baby of Dolly Pandey	Location: MAX SUPER SPECIALITY HOSPITAL - SAKET
Age/Sex: O/M	IP No.: Admission Type: OutPatient
Max ID: SKMS.0526942	Order Date: 27-AUG-2020
Ref. Doctor: Anurag Krishna	Report Date: 27-AUG-2020 02:06 PM

Micturating Cysto Urethro(MCU) of 27-AUG-2020:

CLINICAL PROFILE: Left hydronephrosis

Results:

MCU was performed after catheterizing the urethra and bladder and injecting 120 cc of dilute contrast.

Urinary bladder is normal in shape, outline and distension.


There is reflux of contrast seen tracking into a dilated tortuous left ureter and reaching upto the pelvicalyceal system which is dilated with ballooned out calyces - Grade V active vesicoureteric reflux.

No evidence of reflux on right side.

The urethra is normal on the micturating films. No hold up of contrast seen.

Post void residue is nil.

IMPRESSION: The study reveals Grade V vesicoureteric reflux on left side.



Dr. Raunak Deo
Sr. Resident
DMC No. 89977

Dr. Vineeta
DNB Junior Resident

Report Approved / Verified Date & Time: 27-AUG-2020 02:06 PM

(For Interpretation by a Registered Medical Practitioner only)

Max Super Speciality Hospital, Saket (West Block)
1, Press Enclave Road, Saket, New Delhi - 110 017
For patient related queries or appointment, call: +91-11-6611 5050

Max Healthcare Institute Limited
(CIN: U72200MH2001PLC322854)

Regd. Office: 167, Floor 1, Plot-167A, Ready Money Mansion, Dr. Annie Besant Road, Worli, Mumbai-400 018
Phone: +91- 22-6660 4447/48/49, E-mail: secretarial@maxhealthcare.com
www.maxhealthcare.in



M-0073



Operational Accredited
by Joint Commission International

DEPARTMENT OF NUCLEAR MEDICINE & PET/CT

Ph: 26515050- 2081-86, Direct: 26595623 Mob: 9650269898

RADIO-ISOTOPE RENOGRAM WITH GFR

Name : B/o Dolly Age/Sex : 2months/M Date : 02/09/2020
 Ref. Dr. : Anurag Krishna UHID No. : SKMS.526943 NM No. : 50452
 Purpose of study : To assess renal function and drainage. RE No. : 4533
 Views taken : Dynamic and Static Posteriorly Dose : 3 mCi
 • 1st Phase (Flow) 02 sec./frame Lasix : 5 mg at 0 min
 • 2nd Phase (Static) 60 sec./frame

FINDINGS

Left kidney appears smaller in size, normal in shape and placement. Perfusion and cortical uptake is decreased. Photopenic area is seen in the pelvicalyceal system, filling up in the serial images and draining slowly with lasix administration. Right ureter is seen in multiple frames of dynamic image as well as in the delayed image taken at 4 hr; however delayed images taken at 22 hrs show good clearance of tracer from the pelvicalyceal system and ureter.

Right kidney appears normal in size, shape and placement. Perfusion and cortical uptake is normal for age. Pelvicalyceal drainage is normal.

Bladder activity is first seen at 3-4 min.

Background tracer activity is mildly increased.

Differential function

GFR

- | | |
|----------------------|-------------|
| • Left Kidney: 40 % | 23.9 ml/min |
| • Right kidney: 60 % | 35.5 ml/min |

GFR estimation by Gates method:


Total GFR	59.4 ml/min.
-----------	--------------

IMPRESSION:


- Smaller left kidney with decreased cortical function, hydroureteronephrosis and slow clearance
- Non-obstructed right kidney with normal cortical function.

Dr. Pulkit Mittal
Senior Resident

Dr. Jaspriya Bal
Associate Consultant


Dr. Anuja Anand
Associate Consultant

Dr. Madhavi Chawla
Principal Consultant


Dr. Pankaj Dougall
Sr. Director & HOD

Max Super Speciality Hospital, Saket (East Block)
A unit of Devki Devi Foundation

(Devki Devi Foundation Registered under the Societies Registration Act XXI of 1860)
Regd. Office: 2, Press Enclave Road, Saket, New Delhi - 110 017
Phone: +91-11-2651 5050, Fax: +91-11-2651 0050
www.maxhealthcare.in



M-0073

Organized & Accredited
by All India Commission on Accreditation

DEPARTMENT OF NUCLEAR MEDICINE & PET-CT

Ph: 26515050-2651-86, Direct: 26595623 Mob: 9650269898

RADIO-ISOTOPE DMSA SCAN

Name	: R/o Dolly	Age/Sex	: 2 months/M
Date	: 24/09/2020	UHID No.	: SKMS 526943
Ref. Dr.	: Anurag Krishna		
Dose	: 1 mCi		
Purpose of study	: To rule out cortical scarring/ pyelonephritis.		
Views taken	: Anterior, Posterior, RAO, LAO, RPO, LPO.		

FINDINGS:

Left kidney appears smaller in size, normal in shape and placement. Parenchymal tracer uptake is decreased. Cortical outline is regular. *Photopenic area is seen in pelvicalyceal region (known hydronephronephrosis).*

Right kidney appears normal in size, shape and placement. Parenchymal tracer uptake is normal. Cortical outline is regular.

Background tracer concentration is normal.

Differential function (geometric mean method): -


Left kidney	-	36 %
Right kidney	-	64 %

IMPRESSION:


- Smaller sized left kidney with decreased cortical function, with no definite scan evidence of acute pyelonephritis / focal cortical scarring.
- Normal functioning right kidney with no definite scan evidence of acute pyelonephritis / cortical scarring.

Dr. Pulkit Mittal -
Senior Resident

Dr. Jaspriya Bai
Associate Consultant


Dr. Anuja Anand
Associate Consultant

Dr. Madhavi Chawla
Principal Consultant


Dr. Pankaj Duggal
Sr. Director & HOD

Max Super Speciality Hospital, Saket (East Block)

A unit of Devki Devi Foundation

(Devki Devi Foundation Registered under the Societies Registration Act XXI of 1860)

Regd. Office: 2, Press Enclave Road, Saket, New Delhi - 110 017

Phone: +91-11-2651 5050, Fax: +91-11-2651 0950

www.maxhealthcare.in



IA-0073



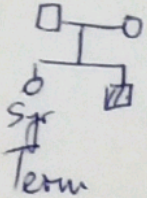
ACCREDITED BY NABL

Anurag Krishna
MCh, FAMS
Director- Pediatrics & Pediatric Surgery



21/07/2020

B/o Dolly Pandey 29d. 11.



Wt: 4.2kg

Antenatal Lt. HV

Had one episode of fever 10 days ago

Treated with IV antibiotics

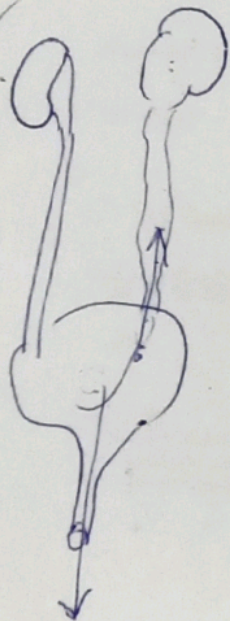
No urine test done

Presented U/S 17.7.2020 Lt. HV

Urine stream @

of kidneys, bladder not palpable

Genitalia - Tests Lt.



In case of fever/lethargy
Urine r/e, U/S

Counsel:

Perineal hygiene as advised.

Rpt U/S KUB after 4 wks

Followed by MCE under
antibiotic cover

Syr. Spiridex Redinix (5ml x 150g)
2ml at bedtime

for

Smart Super Speciality Hospital, Saket

Part of Gujarmal Modi Hospital and Research Centre for Medical Sciences

Guajarmal Modi Hospital and Research Centre for Medical Sciences Registered under the Societies Registration Act XXI of 1860

Office: Mandir Marg, Press Enclave Road, Saket, New Delhi- 110017

Phone: +91-11-7121 2121, Fax: +91-11-2696 3801

maxhealthcare.in



@ Tests conducted at Referral Lab. Laboratory immediately for possible remedial action.

Anurag Krishna
MCh, FAMS
Sector - Pediatrics & Pediatric Surgery



27/8/2020

B/o Dolly Pandey 2m. 4d M.

Antenatal dx. HN

One febrile UTI.

Post natal o/s : dx HN

MCU (today) : dx G⁺ VUR
Urethra, bladder (10)

Counsel

Perineal hygiene

Avoid Constipation

Cont. Sy for gender Redms
125mg
int. x 10 = mg once at bedtime

In case of fever / lethargy
 urine 4/c, 4/s

Rpt U/s KUB after 3m.

Review for

Circumcision offered

4/9/2020.

DMSA Renal Scan
LH 36% Rt 64%
- small H.

DTPA Renal Scan
LH 40% Rt 60%
Non-obstructive

Max Super Speciality Hospital, Saket (West Block)
1, Press Enclave Road, Saket, New Delhi - 110 017
For patient related queries or appointment, call: +91-11-6611 5050
Max Healthcare Institute Limited
(CIN: U72200MH2001PLC322854)
Regd. Office: 167, Floor 1, Plot-167A, Ready Money Mansion, Dr. Annie Besant Road, Worli, Mumbai-400 018
Phone: +91-22-6660 4447/48/49, E-mail: secretarial@maxhealthcare.com
www.maxhealthcare.in



M-0073

26/02/2021

Last 4/9/2020
Video consult

B/O Dolly Pandey Sm 17

74 Lt. Gr V VUR

DMSA : Lt 36% Rt 64%
Small Lt kidney

DTPA : Lt 40% Rt 60% non-obstructive

Baby well No UTI

Last U/S KUB (Dec 2020) : Lt hydronephrosis
(Prev results not available for comparison)

As:

Continue Spondex nodule

Perineal hygiene

In case of fever → urine M/C, U/S

Repeat U/S KUB at 1yr of age

Review

[Signature]

21/7/2021

Sharvil Pandey 1y 1m. 7.
(B/o Dolly Pandey)

Last
26/2/2021.

Full ds. G.V. VUR.

DMSA: Lt 36% Rt 64%.

Small Lt kidney.

Was irregular with spindles/low dose.

? One febrile UTI - June '21.

No constipation. Wk gain.

U/S KUB: Lt HUN. No neovasc.
Ltate gno.

wt 12.1 kg

x 10

Spindles Redimiso (Sml = 250mg)
2.5 ml nocte to continue

In case of fever urine m/c, Cx.

Renew 6m.

- U/S KUB

June