

Ph. : (05462) - 265241  
209091  
Mob. : 6393506040

# AMAR NURSING HOME

BILARIYAGANJ ROAD, HEERAPATTI, AZAMGARH



**Dr. Swasti Singh**  
M.B.B.S. D.G.O., F.I.C.O.G., F.I.A.M.S.  
Obstetrician & Gynaecologist  
Diploma in Obs Gynae  
Ultra Sound.

डा० स्वस्ति सिंह  
एमबीबीबीएस, डीओओ,  
एफआईसीओजी, एफआईएमएस,  
स्त्री एवं प्रसूति रोग विशेषज्ञ  
डिप्लोमा इन आब्स गाइनी आल्ट्रासाउण्ड

Name: निफलागोस योगेश्वरी Age: 28

Dt: 12/11/2021

Ann. 2 months

B+0  
LMP-11-SEP  
TEMP: 98.8  
PULSE: 100  
RES: 16  
B.P.: 100/70  
WT: 60kg  
SPO2: 98

Accu -  
E. Ozone 3- ✓

HB%, ABORh, VDRL  
HIV, HBsAg, Urine R/M  
RES..... TSH.....

Zinc  
Domper. 0.0 1h  
Morphale Actin 1h

for use)

Zeliat - 1  
Semeny 2hs: 70

chr 1u. chr 20

18/09/2022  
17:09:47

Age: 30y  
Ref: Physician

Value	1	2	3	Method	GA	SD	
Hadlock	1.28cm	0.96	1.78	1.11	Avg	7w0d	7w2d 7w6d
value	1	2	3	Method			

Pulsar Measurements  
FHR 119bpm

Value	1	2	3	Method
	130	140		Avg

Comments

Print Print View Export Image Select Analyze Save Comment  
Clear All DR Graph Load Comment

17:19:47

mindray MATRIKA HEALTH CARE ... 20211112 170741 3BE3 12-11-2021 17:17:47

AP 100% MI 0.5 TIS 0.1 AP 100% MI 0.5 TIS 0.1 DC-30

6CV1P  
Follicular Study  
F H8.0M  
D 9.2  
G45  
FR 20  
DR 110  
iClear 4

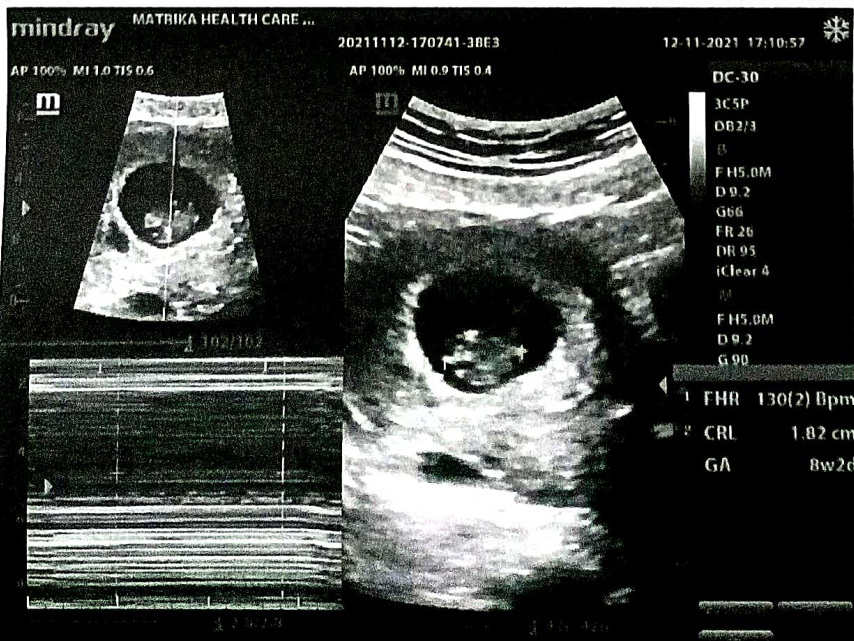
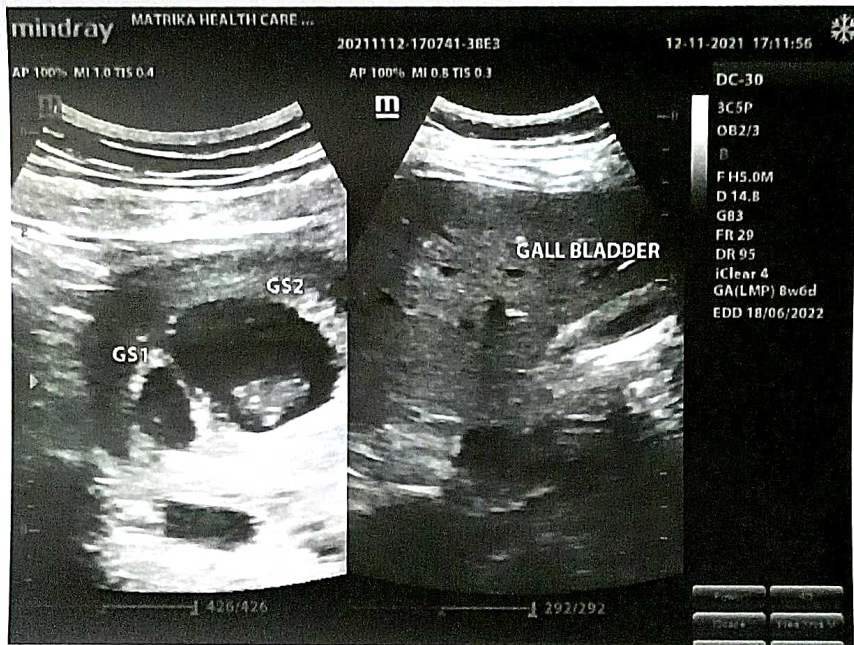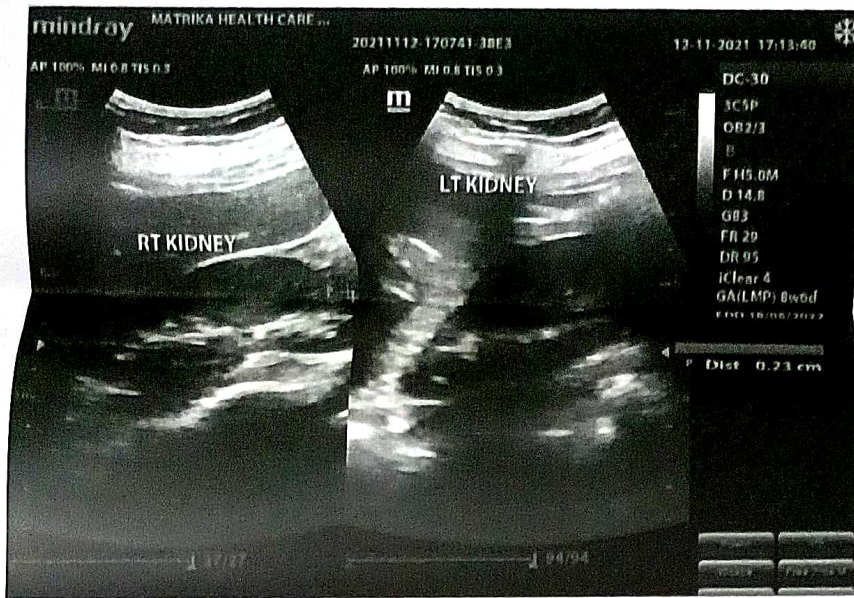1	FHR	148(2) Bpm
2	CRL	0.96 cm
	GA	7w0d
3	CRL	1.78 cm
	GA	8w2d

mindray MATRIKA HEALTH CARE ... 20211112 170741 3BE3 12-11-2021 17:15:10

AP 100% MI 0.6 TIS 0.1 AP 100% MI 0.6 TIS 0.1 DC-30

6CV1P  
Follicular Study  
F H8.0M  
D 9.2  
G33  
FR 14  
DR 110  
iClear 4  
iBeam

1	CRL	1.69 cm
	GA	8w1d
2	CRL	1.11 cm
	GA	7w2d



**Fetal Sonography Report**

PATIENT'S NAME : Nikita Jan.

AGE :

DATE : 12/11/21

Twin embryos. seen with one - yeta heart seen.

# F.H.R. : 130 bpm

b/mt.

# LIE :

# GESTATIONAL AGE : Twin (A) (B)  
8 wks 2u. Twin.

E.D.D. (LMP) : 18.6.22.

C.R.L. 11. 9. mm

E.D.D. (USG) :

F.L. mm

ABDOMINAL CIRCUMFERENCE mm

E.F.W. :

HEAD CIRCUMFERENCE mm

O.F.D. mm

# PLACENTA

# AMNIOTIC FLUID Au

# OPINION Twin gesta sacs seen & embryos.

A) - one corresponds to 8 wks 2u, embryo - B - correct to 7 wks.. (Embryo A - has normal cardiac axis)

I declare that while conducting ultrasonography..... of Nikita Jan.

I have neither detected nor disclosed the sex of fetus to anybody in anyway

Embryo B - has no cardiac action as yet.

Sonologist

Note : For final diagnosis, these findings should be correlated with clinical observations & other supporting investigations.

This report is not valid for medico-legal purpose.