



# ENTRE FOR SIGHT

Every eye deserves the best

A Mahindra Collaboration

*40  
eyebars*

SCFRI

Dr. HARSH KUMAR  
[MD, DMC Reg: 7335]

MRD No: CFS-SAFD/318920

DATE: 03-Jul-2021 14:03:07

PATIENT NAME: Mr.  
KRISHAN KUMAR, 44 Y, MALE

Ophthalmic History NO F/H/O GLAUCOMA, H/O WEARING BIFOCALS ;PG LAST CHANGED 2 YEARS AGO

Complaint/s GLAUCOMA OPINION & CORNEA OPINION

### Ophthalmic Examination

VISION WITH PGP **Right Eye** 6/6P **Left Eye** 6/9+

### Tonometry Record

NCT **Right Eye** 12.0mmHg **Left Eye** 15.0mmHg

Systemic Illness NIL ;NO DRUG ALLERGY KNOWN

### Optometrist findings

	Sph	Cyl	Axis	Add	DVA	NVA
RE	+2.50	-0.50	45	+1.00	6/6	N6
LE	+2.00	-	-	+1.00	6/6 WE	N6

*MRT from (w)  
→ antideformation.*

Mr. M Jaichandran .

*Field test*

*24-2*

*Cornea opinion: It wants*

*105 G  
66 R.*

*- Tramacem HI*

*CCT 550/550*

*98  
74*

*Field after 4mhr*

*R*

*CCT L.*

CENTRE FOR SIGHT - SAFDARJUNG ENCLAVE

CIN No.: U85120MH2002PLC338742

A UNIT OF NEW DELHI CENTRE FOR SIGHT LTD.

5/24, Safdarjung Enclave, New Delhi-110029 Tel.: +91-11-45738888, 41644000 Fax : 91-11-41651744, Website : www.centreforsight.net

Toll-Free No. - 1800 1200 477

Registered Office: First Floor, Flat No. 101, B- Wing, Dhruv, CHSL, Gulmohar Main Road, Ville Parle, Mumbai-400049 MH.

# CLARA SWAIN HOSPITAL J.V.



ESTD. 1870

A Complete Multispeciality Hospital  
for the treatment of All Ailments....

- 243 001 Ph. : 0581 - 2500000, Mob. : 7500612345, 7500712345  
- mail : info@cshbareilly.com, www.cshbareilly.com

Patient's Name Mr. K. K. Yadav Age/Sex 45 Yr / M  
UHID No. 446352 Ward/Bed No. \_\_\_\_\_ Date 27/08/19  
Name of Consultants Dr. R. K. Gupta

Chief Complaints \_\_\_\_\_ Examination \_\_\_\_\_

Pulse Rate \_\_\_\_\_ BP \_\_\_\_\_ RESP \_\_\_\_\_ Temperature \_\_\_\_\_

Weight / Height \_\_\_\_\_

History

NET < 17.00  
15.00

Vu < 619<sup>r</sup> 619  
CS 619 iph 619

Drug Allergy if any

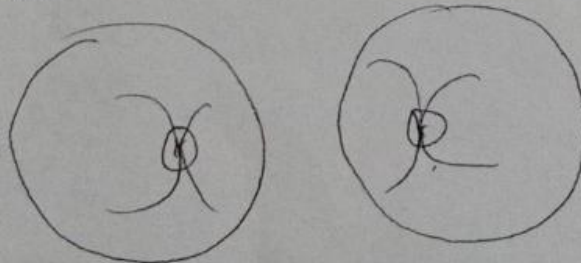
No r glasses change  
Continue same glasses

Systemic Examination

Dilated

Disc Pale +  
LDR

Treatment



Dietary Advice

CD < 0.5  
0.7

Follow up :

Visual +  
periph. Perivasculitis

Dr R K GUPTA 9.01m

MBBS, MS, FMRP, FLVPI, FRCS (I) Glasgow

Doctor Signature & Seal

40 - Headache  
- Pain  
- Watery  
- burning  
Sensation  
for 6-7.  
No 4/0 Am / H  
Lombar Rx.  
ed Hylosol  
ed. Travascom  
ed Alverex

Boonijax 4th  
3 tabs  
Mezot 4th  
3 tabs  
Travascom 4th  
9au

- Latest Ventilator & Advance Burn Care & Dialysis Unit
- Advanced Facilities
- MRI 3-Tesla (Philips) with Multi Transmit
- CT-Scan 64 Slice (Philips)
- Color Doppler (Philips)
- Ech & TMT
- Colposcopy
- Laparoscopy
- Hysteroscopy
- Bronchoscopy
- X-Ray-500 mA
- Centralised Medical Gas System with liquid Oxygen
- Modular Operation Theaters for different specialities
- Advance Physiotherapy Centre

ह पचा केवल 5 दिन के लिए मान्य है।  
ओ.पी.डी. का समय : प्रातः 09.00 बजे से 03.00 बजे तक, सांय 06.00 बजे से 08.00 बजे तक  
यह पचा मेडिको लीगल कार्यवाही के लिये मान्य नहीं है।

Dr. Padmalakshmi K

Assistant Consultant  
Neuro Ophthalmology  
Email: drkpuj@snmail.org  
Phone:  
Fax:

SANKARA NETHRALAYA  
C.U. SHAH OPHTHALMIC POST GRADUATE TRAINING CENTRE  
UNITS OF  
MEDICAL RESEARCH FOUNDATION (Regd.)  
(An ISO 9001:2000 Certified Organisation)



MR No. 4910078  
Name MR. KRISHNA KUMAR  
Age 45 Year(s)  
Sex Male

Address : PANSARI TOLA,  
NEAR BANK OF BARODA,  
, MIRZAPUR,  
UTTAR PRADESH, INDIA - 231001.

Mr. Krishna Kumar (Our MRD no: 4910078), a 45 year old gentleman was seen hereon 04-10-2021. by Dr. TRUPTI SUDHIR PATIL. The detailed case summary is given below.

**Purpose of Visit** Second opinion for glaucoma--

**Main Complaints**

- Both eyes Eye pain 1 Year(s) Onset Gradual Progression Intermittent
- OU: feels no complaints reg vision with glasses, OU: No other specific ocular complaints..

**Past Ocular History**

- Both eyes Nil
- On 4/11/2020 E/w diagnosed as OU: Glaucoma, No baseline IOP available with the patient, vision was OU:6/6, On 28/12/2020 e/w diagnosed as OU: Allergic conjunctivitis and got treated locally, ON 23/4/2021 IOP was checked OD: 18mmhg, OS:19mmhg, vision was OD:6/9p, OS:6/6, On 3/7/2021 IOP was OD: 12mmhg, OS:15mmhg, CCT OU::550microns, On 7/8/2021 IOP was OD: 17mmhg, OS:15mmhg, vision was OD: 6/9p, OS:6/9, OU; CDR: OD:0.5, OS:0.7, hence came here for second opinion and further management.

**Past Medical History**

Nil Nil Says was under Anti depressent for the past 10 yrs and has stopped for the past 1yr. No

**Family History**

Nil No

**Allergy History**

Not aware of

**Visual Acuity Refraction  
GLASS PRESCRIPTION**

Eye	Distance Vision				ADD		
	Sph	Cyl	Axis	BCVA	Sph	BCVA	Distance
RIGHT EYE	+2.25	-0.50	30	6/6 (0.00)	+1.50	N6	30
LEFT EYE	+1.75			6/6 (0.00)	+1.50	N6	30

Cover Test / EOM: Orthophoric Full, Free and Painless

Pupil: Both Eyes Reacting To Light Briskly

Face / Ext Eye Exam: Normal

	Right Eye	Left Eye
Lids	Normal	Normal
Conjunctiva	Congestion,	Congestion,
Cornea	Normal	Normal
Anterior chamber central depth	Normal,	Normal,
Anterior chamber Peripheral depth	Shallow,	Shallow,
Von Hericks Grading	II,	II,
Sclera	Normal	Normal
Iris	Normal	Normal
Lens Status	Early cataract changes,	Early cataract changes,

**CONFRONTATION**

	Right Eye	Left Eye
Ishihara	21/21	21/21

**REMARKS:** OU: GOOD AND RELIABLE RESPONSE

**Intra Ocular Pressure**

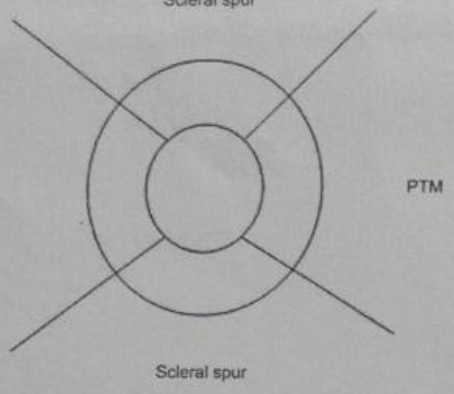
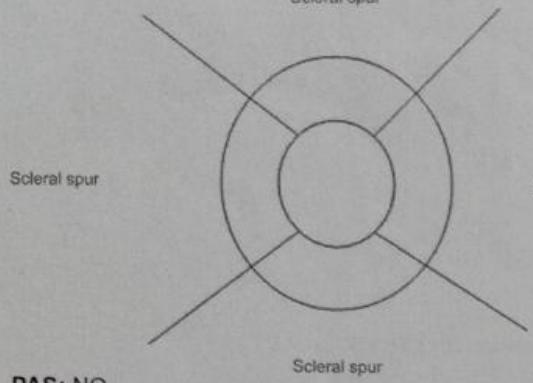
Method	Actual Time	Right Eye Value	Left Eye Value
--------	-------------	-----------------	----------------

Duration	11.48	14 mm of Hg	15 mm of Hg
<b>Intra Ocular Pressure</b>			
Method	Actual Time	Right Eye Value	Left Eye Value
Applanation	11.11	14 mm of Hg	14 mm of Hg

**Gonioscopy**

**Right Eye**  
Dim Illumination-OD  
Scleral spur

**Left Eye**  
Dim Illumination-OS  
Scleral spur



PAS: NO  
TMPig: 2+

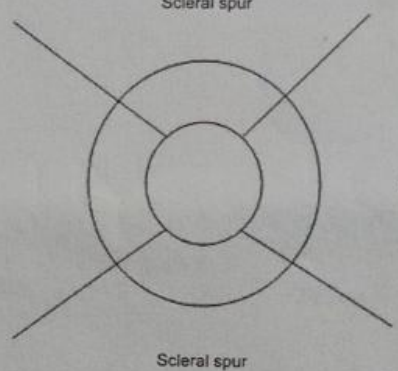
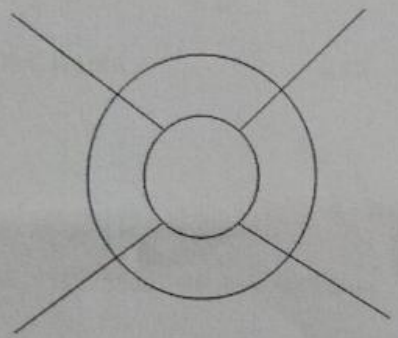
Remarks:

Compression-OD

PAS:  
TMPig:

Remarks:

Compression-OS  
Scleral spur



PAS:

Remarks:

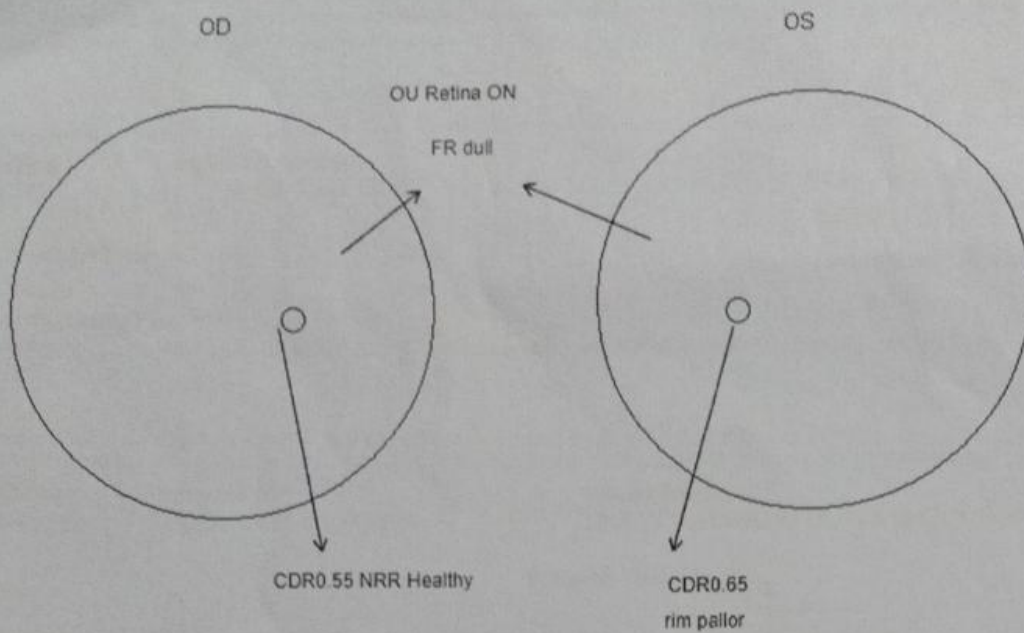
Examined By: JANANI K

PAS: NO

Remarks:

Confirmed By: TRUPTI SUDHIR PATIL

**Fundus Drawing**



**PROCEDURE NAME**

**EYE**

Pachymetry

**Pachy Map**

**Result Details**

Unit Of Measurement is Microns

Right Eye				Left Eye			
Central	540	540	540	Central	542	542	542
OD Average value				OS Average value			
540				542			

**Diagnosis**

EYE	DESCRIPTION
	PresbyopiaH52.4
Right Eye	AstigmatismH52.20
Both Eyes	HypermetropiaH52.00
Both Eyes	Steroid responder - H40.04

**Follow Up/Action Plan**

on AGM 23 April. .was using topical steroid 4 months prior for allergic conjunctivitis Baseline IOP 46 mm hg OU..OU using Travocom..missed 4 days..no f/o of glaucoma. .was investigated for OS vitritis locally. .OS early RPAD..disc as noted adv HVF 24-2 review pls noted..adv Neurophthal opinion pls then review pls

Dr.TRUPTI SUDHIR PATIL

**Purpose of Visit** Others--OU: HVF24-2 SS DONE OD: NORMAL FIELDS OS: INFERIOR ARCUATE DEFECT.. 42410

**Visit Date** 2021-10-04  
**Consultation** CROSS CONSULTATION  
**Consultant** Dr.DURGA PRIYADARSHINI S

**Diagnosis**

EYE	DESCRIPTION
	EXAMINATION OF EYE AND VISION - V72.0

**Follow Up/Action Plan**

c/o left eye pain constant since nov 2020 radiating to left temporal region and ear feels asso with redness ,asympt reg vision systemic h/o unremarkable no s/s/ raised icp /trauma old reports was suspected ?allergic conjunctivitis /?vitritis and was on topical steroids adn post rx - was noted to have 46/45 iop in

2021 adn was started on agm since then was also noted to haev disc pallor then hvf od wnl os per defects more inf MRI Brain and cervical spien reported wnl (no films with pt ) o/e gc good pupil ou dil pharm sle ou quiet os CCC ? Disc od cdr 0.3 os cdr 0.5 pale HVF od wnl os inf arcuate cv intact OS ?prob secondary to raised iop in past ischemic could not explain the left eye pain ?UVEA OPINION to r/o any componenet of Scleritis and DR TSP mam opinion and rev pls.expl if not clinically correlating would prefer rpt imaging /close follow up

Dr.DURGA PRIYADARSHINI S

---

<b>Visit Date</b> 2021-10-04	<b>Consultation</b> SHORT REVIEW	<b>Consultant</b> Dr.TRUPTI SUDHIR PATIL
---------------------------------	-------------------------------------	---

<b>PROCEDURE NAME</b> Disc Photo	<b>EYE</b> Both Eyes
-------------------------------------	-------------------------

**Follow Up/Action Plan**  
Neurophthal opinion noted adv OU Brinzotim BD..(Stop Travocom in view of H/O vitritis)..Uvea opinion pls.. Review with on Wednesday pls

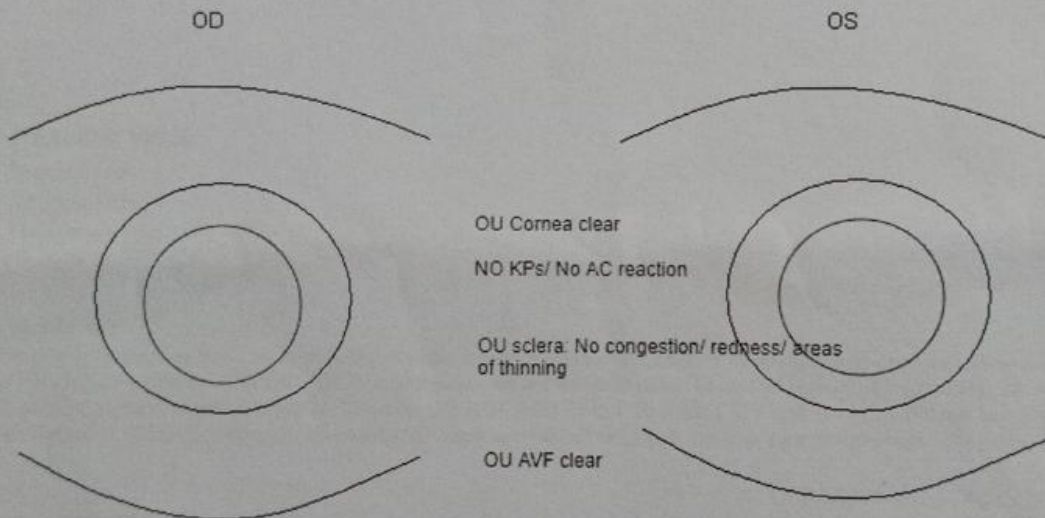
Dr.TRUPTI SUDHIR PATIL

---

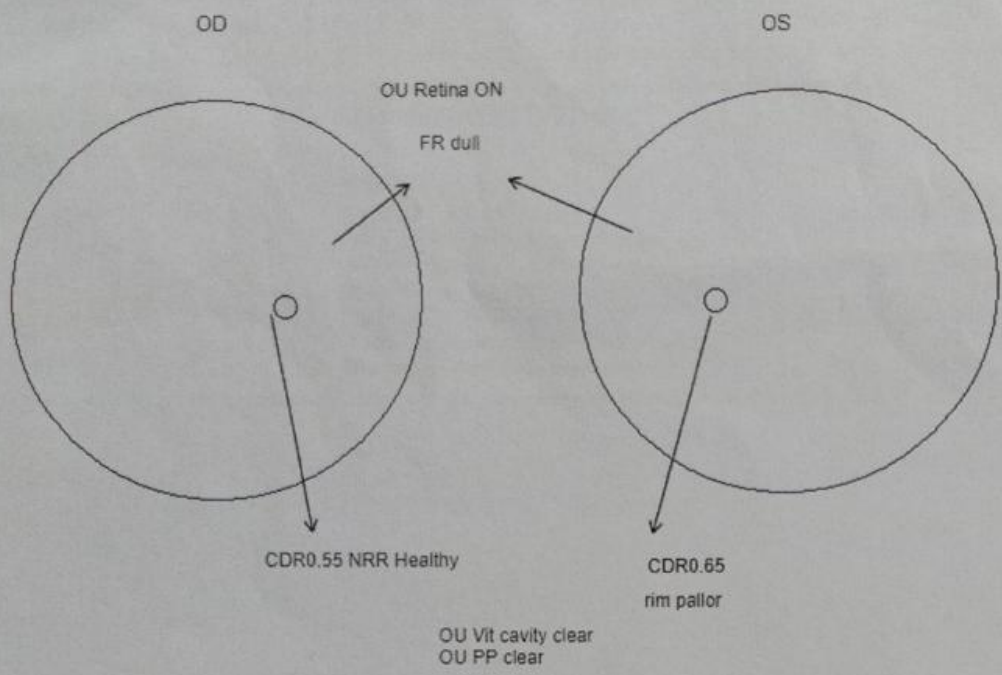
---

<b>Visit Date</b> 2021-10-05	<b>Consultation</b> CROSS CONSULTATION	<b>Consultant</b> Dr.PARTHAPRATIM DUTTA MAJUMDER
---------------------------------	---	---

**Slitlamp Drawing**



**Fundus Drawing**



**Diagnosis**

EYE	DESCRIPTION
	Presbyopia
Right Eye	Astigmatism
Both Eyes	Hypermetropia
Both Eyes	Steroid responder

**Follow Up/Action Plan**

History and findings as noted before; No episodic redness/ associated with photophobia/ no boring headache/ Diagnosed with glaucoma and was put on AGMs/ baseline IOPs high. No history of ATT intake/ breathlessness/ skin lesions/ joint pains/ backache/ History of contact with TB wife and son 15 years ago. Investigated elsewhere: Mantoux negative, IGRA Negative, TORCH ELISA: Rubella/ CMV IgG mildly raised/ rest negative. Imp: OU eye quiet/ no findings suggestive of previous episodes of scleritis. Nil uvea intervention as of now. Review back to Neuro-ophthal/. Glaucoma clinic

Dr.PARTHAPRATIM DUTTA MAJUMDER

Visit Date	Consultation	Consultant
2021-10-06	CROSS CONSULTATION	Dr.PADMALAKSHMI K

Eye	Generic Brand	Form	Strength	Dose	UOM	Freq/	Duration	Dur/Unit	Quantity	Route	Start Date	Direction	Remarks
Both Eyes	HYPROMELLOSE OPTHALMIC SOLUTION USP/ GENTEAL EYE DROP.	Drops.		1 tab.		4 times/day (4th hrly).		Continue till next appt.		Topical.	06-10-2021.		

General Advice:

**Diagnosis**

EYE	DESCRIPTION
	EXAMINATION OF EYE AND VISION - V72.0

**Follow Up/Action Plan**

chart reviewed c/o eye pain and left side headache since nov 2020 radiating to left hemi- scalp/ behind ears occasional giddiness/vertigo....also has itching/dryness of eyes consulted neurosurgeon and later neuropsychiatrist - suspected TGN-in june 2021- used only nexito for 60days -says not much relief mri brain and cervical spine on 22-1-21 o/e pupil ou rrtl no rapd eom ou full color vision noted disc ok, os temporal pallor dr dap mam and uvea opinion noted adv dry eye test and rev-noted ? trigeminal neuralgia adv to do MRI brain and orbit and rev explained will need neurologist consultation after mri for opinion and treatment

Dr. PADMALAKSHMI K

Purpose of Visit Others--DRY EYE WORKUP

For queries, get in touch with your doctor or to fix up an appointment please use following contact details :

Secy. Name / Tel.No MS SUBSHREE S/ EXT. No.1499

drkpi@snmail.org  
SANKARA NETHRALAYA  
41/18, College Road, Nungambakkam  
Chennai - 600 006, TamilNadu, India.  
Fax : +91-44-2825 4180  
Phone : +91-44-2827 1616  
E-Mail : appointment@snmail.org  
Web : Http://www.sankaranethralaya.org

Address



**Trupti Sudhir Patil**

DNB  
 Consultant  
 Glaucoma  
 Email: drtsp@snmail.org  
 Phone: +91-44-28271616  
 Fax: +91-44-28254180

SANKARA NETHRALAYA  
 C.U. SHAH OPHTHALMIC POST GRADUATE TRAINING CENTRE  
 UNITS OF  
**MEDICAL RESEARCH FOUNDATION (Regd.)**  
 (An ISO 9001:2000 Certified Organisation)



MR No. 4910078  
 Name MR. KRISHNA KUMAR  
 Age 45 Year(s)  
 Sex Male

Address: PANSARI TOLA,  
 NEAR BANK OF BARODA,  
 MIRZAPUR,  
 UTTAR PRADESH, INDIA - 231001.

Mr. Krishna Kumar (Our MRD no: 4910078), a 45 year old gentleman was seen hereon 06-10-2021. by Dr.PADMALAKSHMI K The detailed case summary is given below.

Eye	Generic	Brand	Form	Strength	Dose	UOM	Freq/	Duration	Dur/Unit	Quantity	Route	Start Date	Direction	Remarks
Both Eyes	HYPROMELLOSE OPHTHALMIC SOLUTION USP/		Drops.		1 tab.		4 times/day (4th hrly).		Continue till next appt.		Topical.	06- 10- 2021.		

General  
 Advice:

**Diagnosis**

**EYE DESCRIPTION**

EXAMINATION OF EYE AND VISION - V72.0

**Follow Up/Action Plan**

chart reviewed c/o eye pain and left side headache since nov 2020 radiating to left hemi- scalp/ behind ears occasional giddiness/vertigo...also has itching/dryness of eyes consulted neurosurgeon and later neuropsychiatrist - suspected TGN-in june 2021- used only nexito for 60days -says not much relief mri brain and cervical spine on 22-1-21 o/e pupil ou rrtl no rapd eom ou full color vision noted disc ok, os temporal pallor dr dap mam and uvea opinion noted adv dry eye test and rev-noted ? trigeminal neuralgia adv to do MRI brain and orbit and rev explained will need neurologist consultation after mri for opinion and treatment

Dr.PADMALAKSHMI K

**Purpose of Visit** Others--DRY EYE WORKUP

**Visit Date**  
2021-10-06

**Consultation**  
SHORT REVIEW

**Consultant**  
Dr.TRUPTI SUDHIR PATIL

**Follow Up/Action Plan**

Uvea and Neurophthal opinion noted adv OU AGM continue..RTC 6/12 sos

Dr.TRUPTI SUDHIR PATIL

For queries, get in touch with your doctor or to fix up an appointment please use following contact details :

Secy. Name / Tel.No

MS MONICA J/ EXT No.1422

9383571419

drtsp@snmail.org

SANKARA NETHRALAYA

41/18, College Road, Nungambakkam

Chennai - 600 006, TamilNadu, India.

Fax : +91-44-2825 4180

Phone : +91-44-2827 1616

E-Mail : appointment@snmail.org

Web : Http://www.sankaraneethralaya.org

Address

Wrong path



# SANKARA NETHRALAYA

(UNIT OF MEDICAL RESEARCH FOUNDATION)

Smt. Geetha Kothari Out - Patient Department

Old No. 18, New No. 41, College Road, Chennai - 600 006

## Ophthalmologists

- Dr ABHA MUKUND MASHRUWALA (AHM)
- Dr ADITY VERMA (AV)
- Dr AMALA ELIZABETH GEORGE (AEG)
- Dr AMBIKA S (SA)
- Dr AKILA RAMKUMAR V (VAR)
- Dr ARSHEE S AHMED (ARS)
- Dr BADRINATH S S (SSB)
- Dr BHASKAR SRINIVASAN (BSN)
- Dr BIPASHA MUKHERJEE (BPM)
- Dr DIVYA SHETTY (DSY)
- Dr CHARANYA C (CCN)
- Dr CHETAN RAO (CR)
- Dr DHANASHREE RATRA (DAD)
- Dr DURGA PRIYADARSHINI (DAP)
- Dr ELLZABEH SONU JOHN (ESJ)
- Dr GAJENDRA KUMAR VERMA (GKV)
- Dr GEETHA I KRISHNAN (GKI)
- Dr GIRISH SHIVA RAO (GSR)
- Dr JAYALAKSHMI G (JGN)
- Dr JAYAPRAKASH. V (VJP)
- Dr JYOTIRMOY BISWAS (JB)
- Dr KAVITHA KALAIVANI NATARAJAN (KKV)
- Dr K C ANAND (KCA)
- Dr KIRTHI KOKA (KKA)
- Dr MAMTA AGARWAL (MAL)
- Dr MEENAKSHI S (MS)
- Dr MEENALAKSHMIPATHY (MLY)
- Dr MUNA BHENDE (MPB)
- Dr MUTHUMEENA MUTHUMALAI (MMI)
- Dr MONA KHURANA (MAK)
- Dr NISAR SONAM POONAM (NRS)
- Dr NEETHU LATIF (NL)
- Dr NIRMALA SUBRAMANIAN (NS)
- Dr NIVEDITHA NARAYANAN (NVN)
- Dr PADMALAKSHMI K (KPI)
- Dr PARVEEN SEN (PKA)
- Dr PARTHA PRATIM DUTTA MAJUMDER (PMR)
- Dr PARAMESWARI (CKP)
- Dr PRADEEP S (PDS)
- Dr PRAMOD S BHENDE (PB)
- Dr PREMA PADMANABHAN (PP)
- Dr PARIVADHANI A (AP)
- Dr RADHIKA N (NR)
- Dr RAJESH P S (RPS)
- Dr RAMA RAJAGOPAL (RR)
- Dr RATHINI LILIAN DAVID(RLD)
- Dr RAJIV RAMAN(RRN)
- Dr RONNIE JACOB GEORGE (RG)
- Dr SHARANYA SARAH ABRAHAM (SAA)
- Dr SHEMA RAFAEEK (SHF)
- Dr SHANTHA B (BS)
- Dr SHIKHA RAJESH BASSI (SRB)
- Dr SHRUTHI SURESH (STR)
- Dr SHWETA S AGARWAL (SAL)
- Dr SMITA PANDA (SMA)
- Dr SMITA PRAVEEN (SV)
- Dr SRIPRIYA KRISHNAMOORTHY (AVS)
- Dr SRIVALLI KAZA (SVI)
- Dr SUCHITRA PRADEEP (SPD)
- Dr SUDHA K GANESH (SKG)
- Dr SUDHARSHAN S (SSN)
- Dr SUDHIR R R (RRS)
- Dr SUGANESWARI (GSI)
- Dr SUJATHA VK (SJA)
- Dr SUMITA AGARKAR (SAR)
- Dr SURENDRAN T S (TSS)
- Dr TRUPTI SUDHIR PATIL (TSP)
- Dr VARSHA BACKIAVATHY T (VBT)
- Dr VEENA BASKARAN (VBN)
- Dr VIDHYA DHARANI D M (MVD)
- Dr VIJAYA L (LV)
- Dr VIKAS KHETAN (VK)
- Dr VINATA MURALIDHARAN (VTR)
- Dr VINEET RATRA (VR)
- Dr VINITA GIRISH RAO (VGR)

Mr. Krishna Kumar. ~~MRD~~  
MRD: 49/0078

To do

① ~~Hearogram~~

② ESR, CRP

③ ANA

④ RA factor

⑤ ANCA - P - C

⑥ NMO AG

⑦ mog AG

## Physicians

- Dr BHASKARAN S (SB)
- Dr GOVINDARAJULU K E (KEG)
- Dr NATARAJAN M (MN)
- Dr SARAVANABAVAN M (SRM)
- Dr SIVAKUMAR S (SKS)

## Anaesthesiologists

- Dr BRINDHA J SHANKAR
- Dr HEMANAYAKULU TR (HTR)
- Dr JAGADEESH V
- Dr JAICHANDRAN V V
- Dr KANNAN R
- Dr LAKSHMIPRASANNA S
- Dr MANIMARAN S
- Dr MANONMANI B
- Dr PRADNYA SENTHIL KUMAR
- Dr SAAI ARUN SUNDER
- Dr SHANMUGA SUNDARAM
- Dr SHOBA RAVISHANKAR
- Dr SONALI RAMAN
- Dr SRIDHAR RAJ D
- Dr SUJATHA R
- Dr SUJATHA V
- Dr THIRUMAARAN U G
- Dr VISWANATHAN A

## Oncologist

- Dr JULIUS XAVIER SCOTT

## Laboratory Services

drdap@snnmail.org

S. Oh  
mm

Dr.Durga Priyadarshini.S.

M.B.B.S.,D.O.,FICO  
Associate Consultant  
Neuro Ophthalmology  
Email: drdap@snmail.org  
Phone:  
Fax:

SANKARA NETHRALAYA  
C.U. SHAH OPHTHALMIC POST GRADUATE TRAININGCENTRE  
UNITS OF  
MEDICAL RESEARCH FOUNDATION (Regd.)  
(An ISO 9001:2000 Certified Organisation)



MR No. 4910078  
Name MR. KRISHNA KUMAR  
Age 45 Year(s)  
Sex Male

Address : PANSARI TOLA,  
NEAR BANK OF BARODA, ,  
MIRZAPUR,  
UTTAR PRADESH, INDIA - 231001.

Mr. Krishna Kumar (Our MRD no: 4910078), a 45 year old gentleman was seen hereon 04-10-2021. by Dr.TRUPTI SUDHIR PATIL The detailed case summary is given below.

**Purpose of Visit** Second opinion for glaucoma--

**Main Complaints**

- Both eyes Eye pain 1 Year(s) Onset Gradual Progression Intermittent
- OU: feels no complaints reg vision with glasses, OU: No other specific ocular complaints..

**Past Ocular History**

- Both eyes Nil
- On 4/11/2020 E/w diagnosed as OU: Glaucoma, No baseline IOP available with the patient, vision was OU:6/6, On 28/12/2020 e/w diagnosed as OU: Allergic conjunctivitis and got treated locally, ON 23/4/2021 IOP was checked OD: 18mmhg, OS:19mmhg, vision was OD:6/9p, OS:6/6, On 3/7/2021 IOP was OD: 12mmhg, OS:15mmhg, CCT OU::550microns, On 7/8/2021 IOP was OD: 17mmhg, OS:15mmhg, vision was OD: 6/9p, OS:6/9, OU; CDR: OD:0.5, OS:0.7, hence came here for second opinion and further management.

**Past Medical History**

Nil Nil Says was under Anti depressent for the past 10 yrs and has stopped for the past 1yr. No

**Family History**

Nil No

**Allergy History**

Not aware of

**Visual Acuity Refraction  
GLASS PRESCRIPTION**

Eye	Distance Vision				ADD		
	Sph	Cyl	Axis	BCVA	Sph	BCVA	Distance
RIGHT EYE	+2.25	-0.50	30	6/6 (0.00)	+1.50	N6	30
LEFT EYE	+1.75			6/6 (0.00)	+1.50	N6	30

Cover Test / EOM: Orthophoric Full,Free and Painless

Pupil: Both Eyes Reacting To Light Briskly

Face / Ext Eye Exam: Normal

	Right Eye	Left Eye
Lids	Normal	Normal
Conjunctiva	Congestion,	Congestion,
Cornea	Normal	Normal
Anterior chamber central depth	Normal,	Normal,
Anterior chamber Peripheral depth	Shallow,	Shallow,
Von Hericks Grading	II,	II,
Sclera	Normal	Normal
Iris	Normal	Normal
Lens Status	Early cataract changes,	Early cataract changes,

**CONFRONTATION**

	Right Eye	Left Eye
Ishihara	21/21	21/21

**REMARKS:** OU: GOOD AND RELIABLE RESPONSE

**Intra Ocular Pressure**

Method	Actual Time	Right Eye Value	Left Eye Value
Applanation	11.48	14 mm of Hg	15 mm of Hg

Intra Ocular Pressure  
Method  
Applanation

Actual Time  
11.11


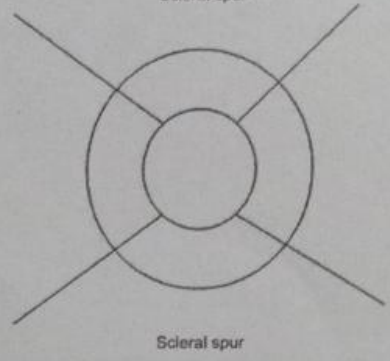

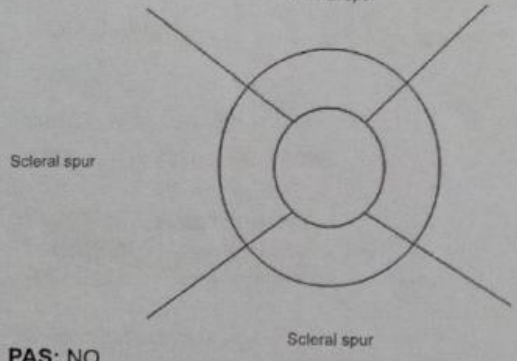
Right Eye Value  
14 mm of Hg

Left Eye Value  
14 mm of Hg

Gonioscopy

Right Eye  
Dim Illumination-OD  
Scleral spur

Left Eye  
Dim Illumination-OS  
Scleral spur



PAS: NO  
TMPig: 2+

Remarks:

Compression-OD

PAS:  
TMPig:

Remarks:

Compression-OS  
Scleral spur

PAS:

Remarks:

Examined By: JANANI K

PAS: NO

Remarks:

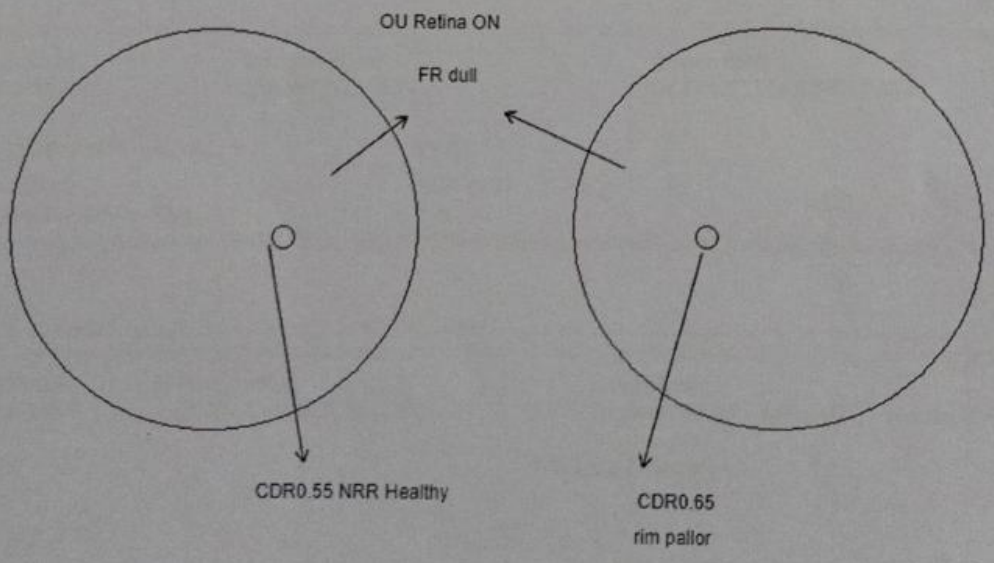
TMPig: 2+

Confirmed By: TRUPTI SUDHIR PATIL

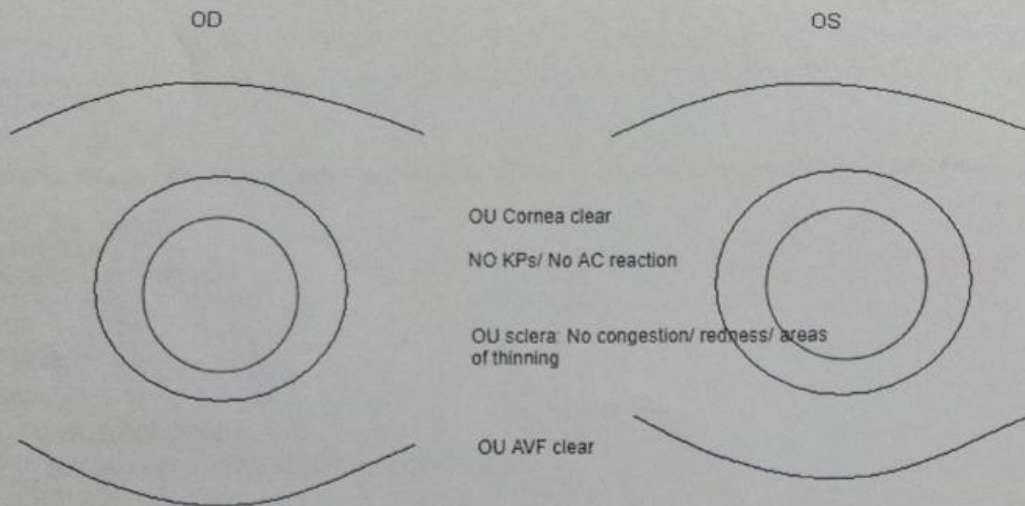
Fundus Drawing

OD

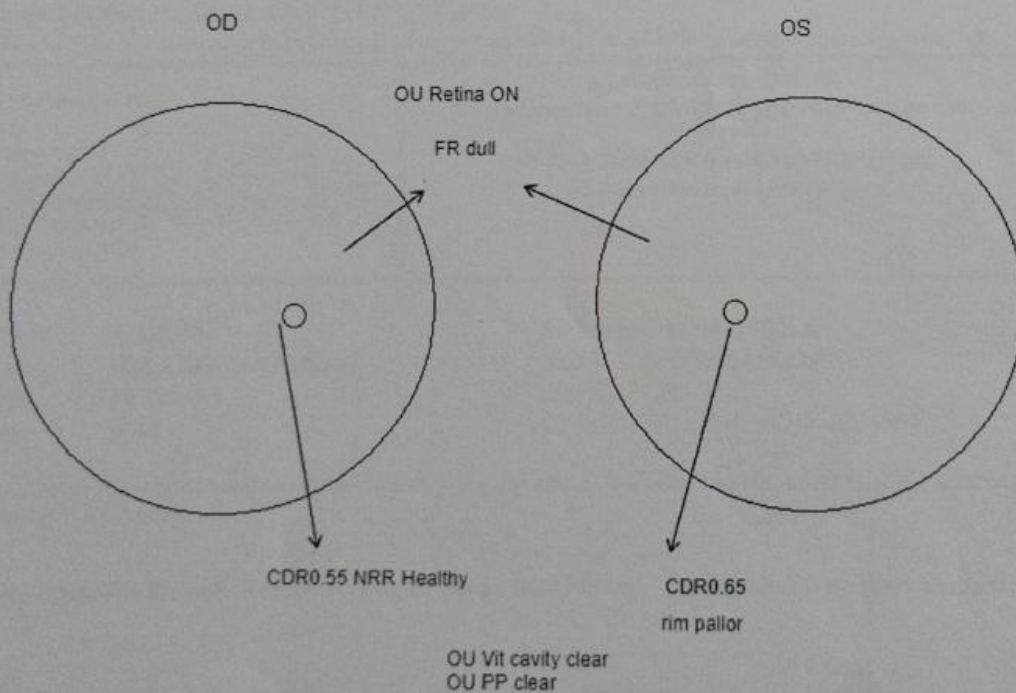
OS







**Fundus Drawing**



**Diagnosis**

EYE	DESCRIPTION
	Presbyopia
Right Eye	Astigmatism
Both Eyes	Hypermetropia
Both Eyes	Steroid responder

**Follow Up/Action Plan**

History and findings as noted before: No episodic redness/ associated with photophobia/ no boring headache/ Diagnosed with glaucoma and was put on AGMs/ baseline IOPs high. No history of ATT intake/ breathlessness/ skin lesions/ joint pains/ backache/ History of contact with TB wife and son 15 years ago. Investigated elsewhere: Mantoux negative, IGRA Negative, TORCH ELISA: Rubella/ CMV IgG mildly raised/

rest negative. Imp: OU eye quiet/ no findings suggestive of previous episodes of scleritis. Nil uvea intervention as of now. Review back to Neuro-ophthal/. Glaucoma clinic

Dr.PARTHAPRATIM DUTTA MAJUMDER

Mr . Krishna Kumar (Our MRD no: 4910078), a 45 year old gentleman was seen hereon 06-10-2021. by Dr.PADMALAKSHMI K The detailed case summary is given below.

Eye	Generic	Brand	Form	Strength	Dose	UOM	Freq/	Duration	Dur/Unit	Quantity	Route	Start Date	Direction	Remarks
Both Eyes	HYPROMELLOSE	OPHTHALMIC	SOLUTION USP/	Drops.	1 tab.		4 times/day (4th hrly).				Continue till next appt.	06-10-2021.	Topical.	

General Advice:

**Diagnosis**


EYE	DESCRIPTION
	EXAMINATION OF EYE AND VISION - V72.0

**Follow Up/Action Plan**

chart reviewed c/o eye pain and left side headache since nov 2020 radiating to left hemi- scalp/ behind ears occasional giddiness/vertigo....also has itching/dryness of eyes consulted neurosurgeon and later neuropsychiatrist - suspected TGN-in june 2021- used only nexito for 60days - says not much relief mri brain and cervical spine on 22-1-21 o/e pupil ou rrtl no rapd eom ou full color vision noted disc ok, os temporal pallor dr dap mam and uvea opinion noted adv dry eye test and rev-noted ? trigeminal neuralgia adv to do MRI brain and orbit and rev explained will need neurologist consultation after mri for opinion and treatment

Dr.PADMALAKSHMI K

**Purpose of Visit** Others--DRY EYE WORKUP

<p><b>Trupti Sudhir Patil</b> DNB Consultant Glaucoma Email: drtsp@snmail.org Phone: +91-44-28271616 Fax: +91-44-28254180</p>	<p><b>SANKARA NETHRALAYA</b> C.U. SHAH OPHTHALMIC POST GRADUATE TRAININGCENTRE UNITS OF <b>MEDICAL RESEARCH FOUNDATION (Regd.)</b> (An ISO 9001:2000 Certified Organisation)</p>	
---	--	---

MR No.	4910078	Address :	PANSARI TOLA,
Name	MR. KRISHNA KUMAR		NEAR BANK OF BARODA, ,
Age	45 Year(s)		, MIRZAPUR,
Sex	Male		UTTAR PRADESH, INDIA - 231001.

Mr . Krishna Kumar (Our MRD no: 4910078), a 45 year old gentleman was seen hereon 06-10-2021. by Dr.PADMALAKSHMI K The detailed case summary is given below.

Eye	Generic	Brand	Form	Strength	Dose	UOM	Freq/	Duration	Dur/Unit	Quantity	Route	Start Date	Direction	Remarks
Both Eyes	HYPROMELLOSE	OPHTHALMIC	SOLUTION USP/	Drops.	1 tab.		4 times/day (4th hrly).				Continue till next appt.	06-10-2021.	Topical.	

General Advice:

**Diagnosis**

EYE	DESCRIPTION
	EXAMINATION OF EYE AND VISION - V72.0

**Follow Up/Action Plan**

chart reviewed c/o eye pain and left side headache since nov 2020 radiating to left hemi- scalp/ behind ears occasional giddiness/vertigo....also has itching/dryness of eyes consulted neurosurgeon and later neuropsychiatrist - suspected TGN-in june 2021- used only nexito for 60days - says not much relief mri brain and cervical spine on 22-1-21 o/e pupil ou rrtl no rapd eom ou full color vision noted disc ok, os temporal pallor dr dap mam and uvea opinion noted adv dry eye test and rev-noted ? trigeminal neuralgia adv to do MRI brain and orbit and rev explained will need neurologist consultation after mri for opinion and treatment

**Purpose of Visit** Others--DRY EYE WORKUP

**Visit Date**  
2021-10-06

**Consultation**  
SHORT REVIEW

**Consultant**  
Dr.TRUPTI SUDHIR PATIL

**Follow Up/Action Plan**

Uvea and Neurophthal opinion noted adv OU AGM continue..RTC 6/12/sos

Dr.TRUPTI SUDHIR PATIL

For queries, get in touch with your doctor or to fix up an appointment please use following contact details :

Secy. Name / Tel.No

MS MONICA J/ EXT. No.1422  
9383571419

drtsps@snmail.org

SANKARA NETHRALAYA  
41/18, College Road, Nungambakkam  
Chennai - 600 006, TamilNadu, India.

Address

Fax : +91-44-2825 4180

Phone : +91-44-2827 1616

E-Mail : appointment@snmail.org

Web : Http://www.sankaranethralaya.org

**Visit Date**  
2021-10-07

**Consultation**  
SHORT REVIEW

**Consultant**  
Dr.DURGA PRIYADARSHINI S

**Follow Up/Action Plan**

Uvea and glaucoma opinion noted MRI Brain and orbit wnl pt primary complaint in pain and vision asymp agree with DR KPI ?trigeminal neuralgia as clinically pain is not correlating in view of disc pallor would prefer to do vasculitis workup +nmo and mog ab ,to have neurologist consult locally and email reports ,cont agm as advised expl would need a regular follow up ,rtc sos

*Dr. Durga Priyadarshini S*  
Dr.DURGA PRIYADARSHINI S

For queries, get in touch with your doctor or to fix up an appointment please use following contact details :

Secy. Name / Tel.No

MS SUBASHREE S/ EXT. No.1499  
9383571426

drdap@snmail.org

SANKARA NETHRALAYA  
41/18, College Road, Nungambakkam  
Chennai - 600 006, TamilNadu, India.

Address

Fax : +91-44-2825 4180

Phone : +91-44-2827 1616

E-Mail : appointment@snmail.org

Web : Http://www.sankaranethralaya.org



**SRI NATHIELLA SAMPATHU CHETTY CLINICAL LABORATORY**  
 (UNIT OF MEDICAL RESEARCH FOUNDATION)


Vision of the Millennium

41/18, College Road, Chennai - 600 006

Phone: +91-44-28271616, 42271500

Fax: +91-44-28254180

E-mail: microbiology@snnmail.org

<http://www.sankaranethralaya.org>

Name : MR KRISHNA KUMAR

MRD No : 4910078

Age : 45 Year(s)

Sex : MALE

Type : Out Patient



NABL Certificate No. MC-2342

**CLINICAL MICROBIOLOGY LAB REPORT**

Report ID: MIB071021008      Request No: REQ/21/10/07/0047      Location : SN MAIN      Lab No. S.NO.2876/21

Referred By : Dr. DURGA PRIYADARSHINI S

Primary Specimen : BLOOD

Secondary Specimen : SERUM

**FINAL REPORT**
**L203 - RHEUMATOID ARTHRITIS (RA) FACTOR**

Parameter Name	Parameter Result	Method Name
RA- Factor	: Negative < 10.0 IU/mL (Reference Value - Positive >= 18 IU/mL)	Nephelometry

**L206 - ANTINUCLEAR ANTIBODY**

Parameter Name	Parameter Result	Method Name
Antinuclear Antibody	: Negative at lower dilution compared to controls	Indirect Immunofluorescent method(FANA) (Using HEp-2 cells as substrate)
Antinuclear Antibody	: Negative	ELISA Qualitative

**L234 - Antibodies to cANCA (PR3)**

Parameter Name	Parameter Result	Method Name
IgG antibodies to Proteinase 3 (PR 3)	: Negative 2.10 RU/mL (Ref Value: Positive >= 20 RU/mL)	ELISA Quantitative

**L235 - Antibodies to pANCA (MPO)**

Parameter Name	Parameter Result	Method Name
IgG antibodies to Myeloperoxidase (MPO)	: Negative 2.08 RU/mL (Ref Value: Positive >= 20 RU/mL)	ELISA Quantitative

**End Of Report**

Verified : PRIYANGA K

 AUTHORIZED BY  
 DR. ANAND A R, Ph.D

*"Electronically generated report and does not warrant signature"*

Collected Date &amp; Time: 07-10-2021 10:12AM      Collected By      SRINIVASAN E      Date Of Reporting: 09-10-2021 4:36PM

Received Date &amp; Time: 07-10-2021 10:23AM      Processing Date &amp; Time 09-10-2021 10:00AM      Print Date: 09-10-2021 4:37PM

SRI NATHIELLA SAMPATHU CHETTY CLINICAL LABORATORY  
(UNIT OF MEDICAL RESEARCH FOUNDATION)



Vision of the Millennium

41/18, College Road, Chennai - 600 006

Phone : +91-44-28271616, 42271500

Fax : +91-44-28254180

E-mail : microbiology@snmail.org

http://www.sankaranethralaya.org

Name : MR KRISHNA KUMAR

MRD No : 4910078

Age : 45 Year(s)

Sex : MALE

Type : Out Patient



NABL Certificate No MC-2342

### CLINICAL MICROBIOLOGY LAB REPORT

Report ID: MIB071021008 Request No: REQ/21/10/07/0047 Location : SN MAIN Lab No. S.NO.2876/21

Referred By : Dr. DURGA PRIYADARSHINI S

Primary Specimen : BLOOD

Secondary Specimen : SERUM

#### FINAL REPORT

L233A - IgG Abs. to Aquaporin 4 (NMO) IF / MOG

Parameter Name	Parameter Result	Method Name
Abs to MOG	: Negative at 1: 10 dilution	Immunofluorescence Method
Abs to Aquaporin 4 (AQP4)	: Negative at 1: 10 dilution	Immunofluorescence Method

End Of Report

Verified : PRIYANGA K

AUTHORIZED BY  
DR A V KAVITHA, M.D

*"Electronically generated report and does not warrant signature"*

Collected Date & Time: 07-10-2021 10:12AM Collected By SRINIVASAN E Date Of Reporting: 07-10-2021 5:05PM

Received Date & Time: 07-10-2021 10:23AM Processing Date & Time 07-10-2021 2:00PM Print Date: 07-10-2021 5:12PM

SRI NATHIELLA SAMPATHU CHETTY CLINICAL LABORATORY

(UNIT OF MEDICAL RESEARCH FOUNDATION)  
No.41(Old No.18), College Road, Nungambakkam  
Chennai-600 006, Tamil Nadu, India



Phone : +91-44-28271616, 42271500  
Fax : +91-44-28254180  
E-mail : appointment@snmail.org

Vision of the Millennium Web Site : <http://www.sankaranethralaya.org>

NAME : MR KRISHNA KUMAR

MRD NO : 4910078

AGE : 45 Year(s)

SEX : MALE

TYPE : Out Patient



NABL Certificate No. MC-234

REPORT ID : HAE071021589 REQUEST NO : REQ/21/10/07/0047

REF. BY : Dr. DURGA PRIYADARSHINI S

PRIMARY SPECIMEN LOCATION : SN MAIN

CLINICAL HAEMATOLOGY AND PATHOLOGY TEST REPORT

SPECIMEN : BLOOD COLLECTED ON : 07-10-2021 10:12 AM RESULT DT. : 07-10-2021 10:57 AM

1 .TEST : L005 - ERYTHROCYTE SEDIMENTATION RATE

NAME	RESULTS	UNIT	BIOLOGICAL REFERENCE		METHOD
			INTERVAL		
E.S.R	6	mm/h	(0 - 10)		Automated - Sedimentation

-- End Of Report --

DATE & TIME : 18-10-2021 16:00:10

TAMILSELVI R

Dr. DOREEN GRACIAS MBBS,DCP,Ph.D

VERIFIED BY

AUTHORIZED BY

"Electronically generated report and does not warrant signature"

SRI NATHELLA SAMPATHU CHETTY CLINICAL LABORATORY  
(UNIT OF MEDICAL RESEARCH FOUNDATION)

Name : MR KRISHNA KUMAR

MRD No : 4910078

Age : 45 Year(s)

Sex : MALE

Type : Out Patient



Vision of the Millennium

41/18, College Road, Chennai - 600 006

Phone: +91-44-28271616, 42271500

Fax: +91-44-28254180

E-mail: microbiology@smrmail.org

http://www.sankaranethralaya.org



NABL Certificate No. MC 2342

### CLINICAL MICROBIOLOGY LAB REPORT

Report ID: MIB071021008

Request No: REQ 21 10/07/0047

Location : SN MAIN

Lab No. S NO.2876/21

Referred By : Dr. DURGA PRIYADARSHINI S

Primary Specimen : BLOOD

Secondary Specimen : SERUM

#### FINAL REPORT

L218 - C- REACTIVE PROTEIN(CRP)

Parameter Name	Parameter Result	Method Name
CRP	: Negative 1.11 mg/L (Reference Value - Positive $\geq$ 6 mg/L)	Nephelometry

End Of Report

Verified : PRIYANGA K

AUTHORIZED BY  
DR A.V.KAVITHA,M.D

*"Electronically generated report and does not warrant signature"*

Collected Date &amp; Time: 07-10-2021 10:12AM Collected By SRINIVASAN E Date Of Reporting: 07-10-2021 5:06PM

Received Date &amp; Time: 07-10-2021 10:23AM Processing Date &amp; Time 07-10-2021 2:00PM Print Date: 07-10-2021 5:13PM



NAME OF PATIENT: MR K K YADAV

AGE: 45 Y/M

REFERRED BY : DR RC MISHRA

DATE - 22.1.2021

### **MRI BRAIN AND CERVICAL SPINE**

#### SCANNING PROTOCOL

MRI of brain and cervical spine. is done in 3 Tesla Scanner using T1 and T2 W images, images, in axial, sagittal and coronal plane. FLAIR, DW and SWI sequence is also done in axial plane for brain

#### REPORT

\*-Cerebral parenchyma reveals normal signal intensity pattern. Basal ganglion and internal capsule are normal. There is no hematoma or infarct seen. Gray and white matter is normal.

\*- Lateral ventricles, 3<sup>rd</sup> ventricle and 4<sup>th</sup> ventricle are normal in size, shape and configuration. There is no evidence of ventriculomegaly or periventricular oozing seen.

\*- Brainstem, pons and medulla are showing normal signal intensity pattern. There is no focal lesion seen. Cerebellar parenchyma reveals normal signal intensity pattern. Cerebellar folia are normal. 7<sup>th</sup> and 8<sup>th</sup> nerve complexes are normal.

\*- Sella and parasellar region is normal. The pituitary gland is showing normal signal intensity pattern. There is no mass seen. Optic chiasma is normally seen.

\*-Cerebral sulci are normal. Sylvian fissures and basal cisterns are normal. CP angle cisterns are normal.

\*-Paranasal sinuses are clear. Both orbits, their extra conal and intraconal compartment are normal.

#### CERVICAL SPINE.

\*- There is evidence of loss of signal intensity seen in the discs of cervical spine s/o disc degeneration and desiccation. Diffuse mild prolapse of C4/C5 disc is seen causing thecal sac compression. Rests of the discs are normal in height, and posterior contour.

\*- The vertebrae are normal in height and signal intensity pattern. The vertebral end plates are normal. Pedicles, laminae and other appendages are normal.

\*- The cervical cord is normal in contour and signal intensity pattern.

NAME OF PATIENT: MR K K YADAV

AGE: 39 Y/M

REFERRED BY : DR RC MISHRA

DATE - 22.1.2021

**MRI BRAIN AND CERVICAL SPINE**

\*-Cervico-medullary junction is normal in signal intensity pattern. Bones of cranio-vertebral junction are showing normal alignment.

\*-No evidence of extra and intradural mass lesion is seen.

\*-No evidence of pre and paravertebral soft tissue is noticed.

\*-Mid sagittal AP spinal canal dimensions are as follow

C2-C3—15 mm

C5-C6---14 mm

C3-C4—13 mm

C6-C7---13 mm

C4-C5---11 mm.

C7—D1---14 mm

**IMPRESSION:-MRI FINDINGS ARE SUGGESTIVE OF—**

\*--MRI OF BRAIN IS WITHIN NORMAL LIMITS

\*- DIFFUSE MILD PROLAPSE OF C4/C5 DISC CAUSING THECAL AC INDENTATION

DR RAHUL NIJHARA  
CONS RADIOLOGIST

DR.SHIVANI GUPTA  
CONS RADIOLOGIST

DR.MEENAKSHI GOYAL  
CONS RADIOLOGIST

DR NUPUR KAUSHIK  
CONS RADIOLOGIST

DR AJAY BULLAGAN  
CONS RADIOLOGIST



Patient Name : KRISHNAKUMAR.MR,  
Age/Sex : 45 Years/ MALE  
Ref.by : DR. KPI(S/N)  
Date : 06-Oct-2021 Id. No. : 22910

MRD no : 4910078. Clinical history : C/o left eye pain associated with left side headache – since Nov 2020/ occasional giddiness vertigo. R/o any neurovascular conflict ? Left trigeminal neuralgia

**MRI Report – Brain and Orbit (Plain) with MRA**

**Technique:**

**Brain: Axial FLAIR and DWI,  
Orbit: Axial T1 SE and T2 FRFSE,  
Coronal T1 SE and T2 FRFSE  
Axial FIESTA and DWI**

**Findings:**

- **Tiny T2 FLAIR hyperintense foci in the bifrontal white matter - Non specific white matter changes**
- **No obvious lesion / neurovascular conflict seen along the course of the 5<sup>th</sup> nerve**

The posterior fossa shows normal cerebellum. The fourth ventricle shows normal size, shape and position. Both the C.P angles are clear.

The medulla, pons and midbrain show normal signals in both the sequences. The basal cisterns are normal. The pituitary gland and optic chiasm are normal.

The third and lateral ventricles are of normal in size, shape and position. No midline shift is noted. The thalami, basal ganglia and internal capsules are normal on both sides.

Rest of the cerebral hemispheres show normal intensities of grey and white matter. The cerebral sulci are normal. The extra cerebral spaces are clear.

Both internal carotid arteries display normal flow void signal and appear normal in caliber. The visualized dural venous sinuses display normal flow void signal.

No significant diffusion abnormality in the brain parenchyma.

The calvarium displays normal marrow signal.

(Contd)

# डा० वी० के० श्रीवास्तव

M.B.B.S., M.D. (PSY), FIPS

मानसिक रोग विशेषज्ञ

पूर्व :- चीफ रेजिडेंट, KGMC, Lucknow

सीनियर रिसर्च आफीसर, ICMR and

संजय गांधी पी० जी० आई०, लखनऊ

नम्बर लगाने के लिये सुबह 9.30 से

12.00 बजे तक इन नं० पर फोन करें

80573-61718

0581-2510040

Mob.:09837078097

ETA

रजिस्ट्रेशन नं० : 28169 (UPMC)

ADJ. दिनांक : 26/10/2024

Δ F32.

— 1/2 TABS LOCERT (100) X — 1  
(SERTRALINE)  
— 1/2 TABS. ETIDEP (15) 1 — 1  
(Eti-zolam.)  
— 1/2 TABS Anapril (20) 1 — 1  
(Propranolol)  
X 20 days  
L

13/11/2024

Repeat X 30 days  
L

कृप्या निर्धारित अवधि के बाद इस पर्चे पर लिखी दवा न दें न ही SUBSTITUTE करें यह रोगी के हित में नहीं है।

समय : सोमवार से शनिवार

सुबह 10.00 बजे से दोपहर 2.30 बजे तक  
शाम 6.00 बजे से 8.30 बजे तक

आनन्द आश्रम (निकट विकास भवन) बरेली।  
आर्यन प्लाजा, महानगर कालोनी, बरेली।

इतवार को सुबह 10.00 बजे से दोपहर 2.30 बजे तक आर्यन प्लाजा, महानगर कालोनी, बरेली। इतवार शाम को क्लीनिक बन्द रहता है

कानूनी कार्यवाही के लिए अमान्य

पर्चा केवल सात दिनों के लिए मान्य