

Shri Ram Murti Smarak Institute of Medical Sciences, Bareilly

(Established & run by Shri Ram Murti Smarak Trust)

Ram Murti Purum, 13 Km. Bareilly-Nainital Road, Bareilly - 243 202 (U.P.) India
Phone : (0581) 2582000; Fax : (0581) 2582010
email : hospital@srmsims.ac.in; website : www.srms.ac.in



SRMS



Cert. No. : MC-3527

Department of Microbiology

Age/Sex 28 Yrs / M

LABORATORY REPORT

Patient Name : MR ATUL CHAUDHRY GOODLI IPD/OPD No : 4157581
Address : LUCKNOW
Referred By : Dr. MALINI KULSHRETHA . Ward :

Molecular Biology (Covid - 19 Real Time PCR)

SARS COV-2 REAL TIME PCR REPORT

Drawn On : 17-04-2021

Received On : 17-04-2021

Lab No : 04214464

Reported On : 18-04-2021

UP COV. PORTAL CASE ID :

TEST RESULT

CT VALUE BIOLOGICAL REFERENCE INTERVAL

SARS-CoV-2 RNA **DETECTED**

24 Not Detected

INTERPRETATION

RdRp	E gene	RNase P	Result Interpretation	Final Report
+	+	+/-	SARS CoV-2 Positive	Report Positive
+	-	+/-	SARS CoV-2 Positive	Report Positive
-	+	+/-	SARS CoV-2 Inconclusive	Repeat after 48-72 hours
-	-	+	SARS CoV-2 Negative	Report Negative
-	-	-	Invalid	Collect new swab and repeat

Interpretation(s):

SARS CoV-2 REAL TIME PCR -

SARS-CoV-2, formerly known as 2019-nCoV, is the causative agent of the coronavirus disease 2019 (COVID - 19). Main symptoms of the disease include fever, cough and shortness of breath. The virus is spread via person-to-person contact through respiratory droplets produced when a person coughs or sneezes. The SARS-CoV-2 RNA is generally detectable in nasopharyngeal/oropharyngeal swabs during the acute phase of infection. Positive results are indicative of active infection. Real Time PCR assay targets specific genes and can be used of diagnosis of SARS-CoV-2 virus infection which contributes to severe upper respiratory distress, complications.

Interpretation:

Detected result is considered a positive test result for COVID - 19. This indicates that RNA from SARS-CoV-2 was detected, and the patient is considered infected with the virus and presumed to be contagious.
Not Detected test result for this test means that SARS-CoV-2 RNA was not present in the specimen above the limit of detection.

Limitations:

- Negative result do not preclude COVID -19 and should not be used as the sole basis for patient management decisions. Negative results must be combined with clinical observations, patient history, and epidemiological information.
- Positive results but do not rule out bacterial infection of co-infection with other viruses.
- Optimum specimen types and timing for peak viral levels during infections caused by 2019-nCoV have not been determined. Collection of multiple specimens (types and time points) from the same patient may be necessary to detect the virus.
- If the virus mutates in the rRT-PCR target region, 2019-nCoV may not be detected or may be detected less predictably. Inhibitors or other types of interference may produce a false negative result.
- The performance of this test has not been established for monitoring treatment of 2019-nCoV infection.

References:

- Laboratory testing for corona virus disease 2019 (COVID-10) in suspected human cases. Interim guidance. World Health Organization.
- Druce et al. JCM. 2011
- N. Engl. J. Med. 2020, 382, 929-936

Page 1 of 1

Rahul Kumar Goyal

Dr. Rahul Kumar Goyal
MBBS, M.D.
Lab Director & HOD (Microbiology)

Jaspreet Kaur

Dr. Jaspreet Kaur
Ph.D.
Senior Clinical Research Scientist

Fauzia Khan

Dr. Fauzia Khan
MBBS, MD
Assistant Professor



*This report is digitally signed and need not to be signed physically.

This report is not for medical legal purpose. All investigations have their limitations which are imposed by the limits of sensitivity and specificity of individual assay procedures as well as the specimen received by the laboratory. Investigations never confirm the final diagnosis of the disease. They only help in arriving at a diagnosis in conjunction with clinical presentation and other related investigations. In case of any discrepancy please repeat sample within 24 hours

24 HOURS HELPLINE : 0581-2582000

Head Office : 4 Laplace, Shahnajaf Road, Lucknow, U.P. (India)



DEEP DIAGNOSTIC CENTRE

An Iso 9001 : 2000 Certified Institution

A unit of Saran Hospital & Institute Of Paramedical Sciences

MALGODAM ROAD, BAREILLY - E-mail : saranhospital@hotmail.com, Web: www.saranhospital.com

COMPUTERISED LAB EQUIPPED WITH I-STAT BLOOD GAS ANALYSER (USA),
BIOCHEMICAL AUTO ANALYSER, SODIUM POTASSIUM ANALYSER


PATHOLOGY REPORT

Name : Mr. ATUL CHOUDHARY


Print Time : 16-Apr-2021 6:28 pm

Referred By : Dr. SUDEEP SARAN, M.D.

Age : 38Yrs. / Male




Automatic Blood Counter




Electrolytes Analyzer



Semi Auto Analyzer



Electrolytes Analyzer



Blood Gas Analyzer

COVID - ANTIGEN SCREENING TEST

Test	Result	Normal Value	Unit
SCREENING TEST FOR COVID ANTIGEN	POSITIVE		

Notes

1. It is important to know that it is only screening test, not at all confirmatory. It never excludes the possibility of Corona infection in initial phase. If positive, it has to be confirmed by rtPCR / TRUNET TEST further. False positive and false negative test are very common.
2. Initially Antigen may be positive, later on IgM Antibody may be positive followed by IgG Antibody presence. Only IgG Antibody positive means that patient is in recovery phase.

Atul KI PCR for confirmation

[Signature]

Authorised Collection Centre
D. MEDICARE DIAGNOSTIC SERVICES
(A Unit of D.P. Medicare Clinical Lab. Pvt. Ltd.)

[Signature]
Dr. Suddeep Saran
M.D. (Med)
Consultant Physician

[Signature]
Pathologist
Dr. D.C. Dubey
M.D. (Path & Bact.)
Consultant Pathologist & Microbiologist



सरन हॉस्पिटल

एण्ड

इन्स्टीट्यूट ऑफ पैरामेडिकल साइन्सेज

O.P.D. No. 7351005354, 7088276666, 7088044333 Ph.: 0581-2570806, 2570807, Fax : 0581-2570806

AN ISO 9001 : 2000 CERTIFIED INSTITUTION

73-ए, मालगोदाम रोड, निकट रेलवे जंक्शन, बरेली Pinplus-243001-06002
E-mail: saranhospital@hotmail.com Website : www.saranhospital.org

डॉ. सुदीप सरन

M.D. (Med.), M.A.G.S. (USA), M.C.C.P. (USA),
A.F.I.S.C., F.G.S.I., F.I.A.C.M., F.I.M.S.A., M.N.C.C.P.
Post Graduate Diploma in Diabetes (PGDD)
Professional Diploma in Clinical Research (P.D.C.R.)
कन्सल्टेन्ट फिजीशियन, क्रिटिकल केयर
एवं हृदय रोग विशेषज्ञ

16.9

Shri Atul Chaudhary
(COM)

- भूतपूर्व विभागाध्यक्ष, मेडिसिन विभाग
क्लेरा स्वेन (मिशन) हॉस्पिटल, बरेली
- भूतपूर्व सीनियर रेजिडेंट (नेफ्रोलोजी)
बत्रा हॉस्पिटल, नई दिल्ली।
- भूतपूर्व रजिस्ट्रार (कार्डियोलॉजी)
सर गंगा राम हॉस्पिटल, नई दिल्ली
- भूतपूर्व फिजीशियन
जी.एम. मोदी हॉस्पिटल, नई दिल्ली।
- विशेष प्रशिक्षण इकोकार्डियोग्राफी
एक्कोर्ट हार्ट सेन्टर, नई दिल्ली।
- भूतपूर्व रेजिडेंट
एस.एन. मेडिकल कालेज, आगरा।
- वाइस पेट्रन
इण्डियन रेड क्रॉस सोसाइटी, बरेली।

हृदय रोग

आयुष्य 60 वर्ष

ATACK awatka

हृदय रोग 2012 वर्ष
↓
12 वर्ष 1995

3 नकारात्मक एंजाइम 1995 2114
x 49

3 Average 12 रोज रोज x 59

3 cefand A2 17

3 cefand A2 17

3 Blunt C2 17

(X) asymmetry
of heart
sat should be > 95) @ 1995 2114

(X) गंभीर बीमार
17 वर्ष 1995 17

(X) 3 वर्ष 1995 17

(X) Malactia - Anorexia

(X) hospital in case
hospital if needed

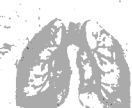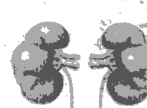रविवार पूर्ण अवकाश

इमरजेन्सी डॉक्टर की सुविधायें 24 घंटे उपलब्ध

मिलने का समय

प्रातः 12:00 बजे से 3:00 तक
सायं 08:00 बजे से 9:00 तक

* सातवें दिन शुल्क देय होगा।
* दोपहर 3:00 बजे एवं सायं 9:00 बजे
के बाद नम्बर नहीं लगेगा।



Dr. Nitin Agarwal

MD., DM (Cardiology)

Consultant Interventional Cardiologist

Cell : +91-94578 33777

Formerly at :

Escorts Heart Institute & Research Centre, Delhi

Dr. Ram Manohar Lohia Hospital, Delhi



APPLE
CARDIAC CARE

DR. NITIN AGARWAL'S HEART CLINIC

57/200

13060

98

9612

ATL CERAMONY

38712

P/curro

@ cur pm

16

i. Prohibit x 99

0

i. Sum, F.

i. Enc LL

->

i. Ruzo 2.9

T4=215

LDL-60

MM-102-103

i. Ugt 0.25 500

img

1244

p. Dure 106 4urc.

@

A-3, EKTA NAGAR, (OPP. CARE HOSPITAL) STADIUM ROAD, NEAR DELAPEER CHAURAHA, BAREILLY - 243 122 (U.P)

For Appointment Call @ 09458888448, 07599031977

OPD Timings : 12.00 Noon to 04.00 pm, Sunday : 12.00 Noon to 3.00 pm

VALID FOR 5 DAYS.

पर्चा पाँच दिन के लिये मान्य



Dr. Nitin Agarwal

MD., DM (Cardiology)
Consultant Interventional Cardiologist
Cell : +91-94578 33777

Formerly at :
Escorts Heart Institute & Research Centre, Delhi
Dr. Ram Manohar Lohia Hospital, Delhi



CC
DR. NITIN AGARWAL'S HEART CLINIC

24/11/2021

126/30

50/20

46/1

x

Actual Cholesterol

325g/m

Plasma

Cholesterol

0.5%

Plasma

i. Protein x (up)

ii. Sugar B

~~iii. Electrolyte~~

iv. Angio 2:0

v. Urine 1/week

2 month

Need Regular follow up.

See

. M1

. H2CT CHEST

डॉ० नितिन अग्रवाल
डी०एम०
हृदय रोग विशेषज्ञ

A-3 EKTA NAGAR (OPP. CARE HOSPITAL) STADIUM ROAD, NEAR DELAPEER CHAURAHA, BAREILLY - 243 122 (U.P)

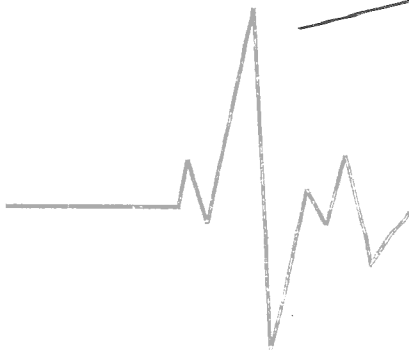
For Appointment Call @ 09458888448, 07599031977

OPD Timings : 06.00 pm to 09.00 pm, Sunday : 12.00 am to 3.00 pm

12.00 Noon to 04.00 pm at Rohilkhand Medical College, Bareilly

VALID FOR 5 DAYS.

पर्चा पाँच दिन के लिये मान्य



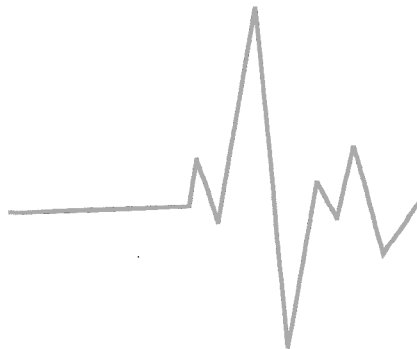

NAME	Mr. ATUL CHAUDHARY	AGE/SEX	38 Y/M
Reff. By	Dr. NITIN AGARWAL (DM)	DATE	05/07/2021

ECHOCARDIOGRAPHY AND COLOUR DOPPLER STUDY

<u>MEASUREMENTS</u>	<u>VALUE</u>	<u>NORMAL DIMENSIONS</u>
LVID (d)	4.5 cm	(3.7 –5.6 cm)
LVID (s)	2.5 cm	(2.2 –3.9 cm)
RVID (d)	2.5 cm	(0.7 –2.5 cm)
IVS (ed)	1.0 cm	(0.6 –1.1 cm)
LVPW (ed)	1.0 cm	(0.6 –1.1 cm)
AO	2.5 cm	(2.2 –3.7 cm)
LA	2.8 cm	(1.9 –4.0 cm)
<u>LV FUNCTION</u>		
EF	60 %	(54 –76 %)
FS	30 %	(25 –44 %)

- LEFT VENTRICLE** : No regional wall motion abnormality
 No concentric left Ventricle Hypertrophy
- MITRAL VALVE** : Thin, PML moves posteriorly during Diastole
 No SAM, No Subvalvular pathology seen.
 No mitral valve prolapse calcification .
- TRICUSPID VALVE** : Thin, opening wells. No calcification, No doming .
 No Prolapse.
 Tricuspid inflow velocity= 0.7 m/sec
- AORTIC VALVE** : Thin, tricuspid, opening well, central closer,
 no flutter.
 No calcification
 Aortic velocity = 1.3 m/sec
- PULMONARY VALVE** : Thin, opening well, Pulmonary artery is normal
 EF slope is normal.
 Pulmonary Velocity = 0.9 m /sec



FACILITIES : ECG | COLOUR DOPPLER | ECHO CARDIOGRAPHY
 TMT | HOLTER MONITORING | PATHOLOGY

ON DOPPLER INTERROGATION THERE WAS :

- No mitral regurgitation
- No tricuspid regurgitation
- No aortic regurgitation
- No pulmonary regurgitation

MITRAL FLOW E= 0.6 m/sec A= 0.8 m/sec

ON COLOUR FLOW:

- No mitral regurgitation
- No tricuspid regurgitation
- No aortic regurgitation
- No pulmonary regurgitation

COMMENTS:

- No LA /LV clot
- No pericardial effusion
- No intracardiac mass
- IAS/IVS Intact
- Inferior vena cava – normal in size with normal respiratory variation

FINAL IMPRESSION

- NO REGIONAL WALL MOTION ABNORMALITY
- GRADE I LV DIASTOLIC DYSFUNCTION
- NORMAL LV SYSTOLIC FUNCTION (LVEF~60%)
- NORMAL CARDIAC CHAMBER DIMENSIONS
- NORMAL VALVULAR COLOUR FLOW PATTERN

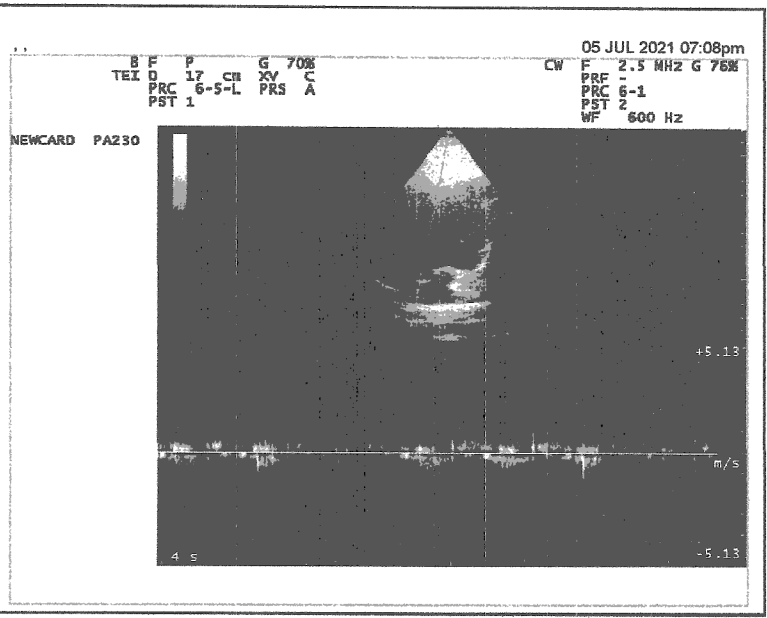
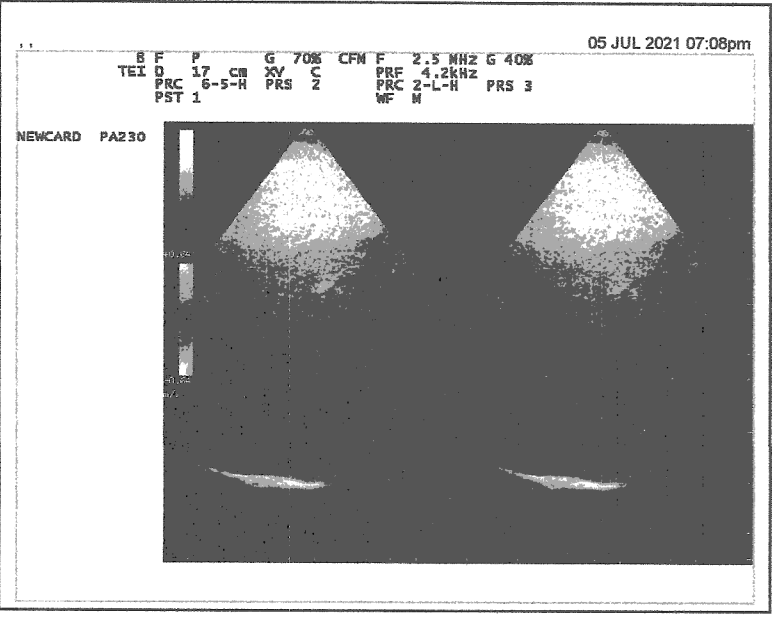
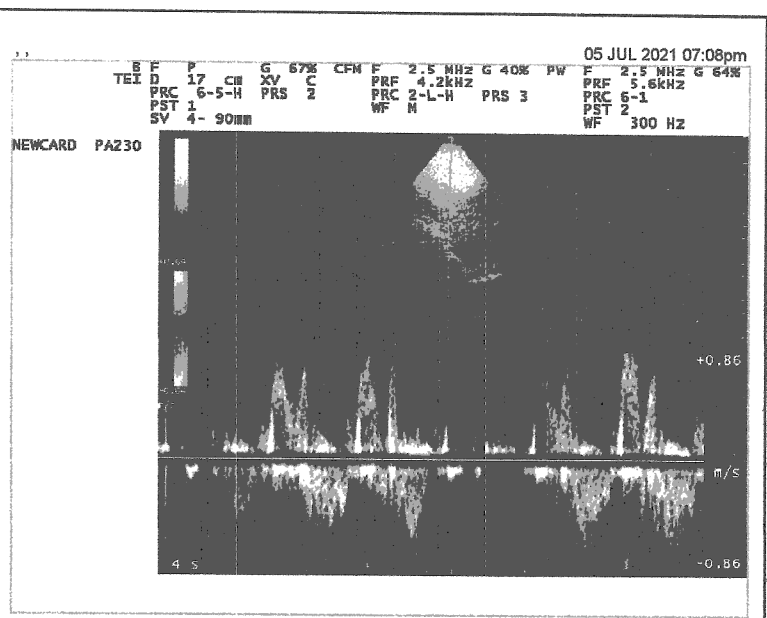
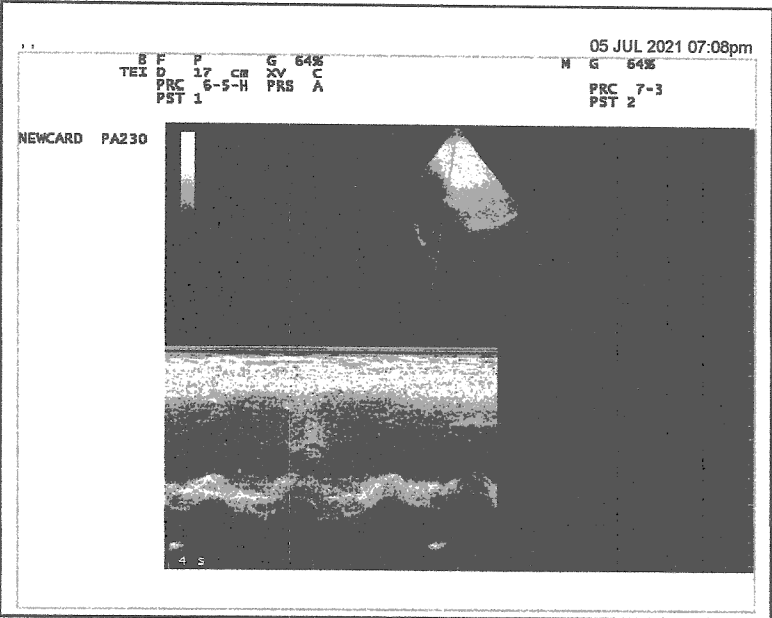
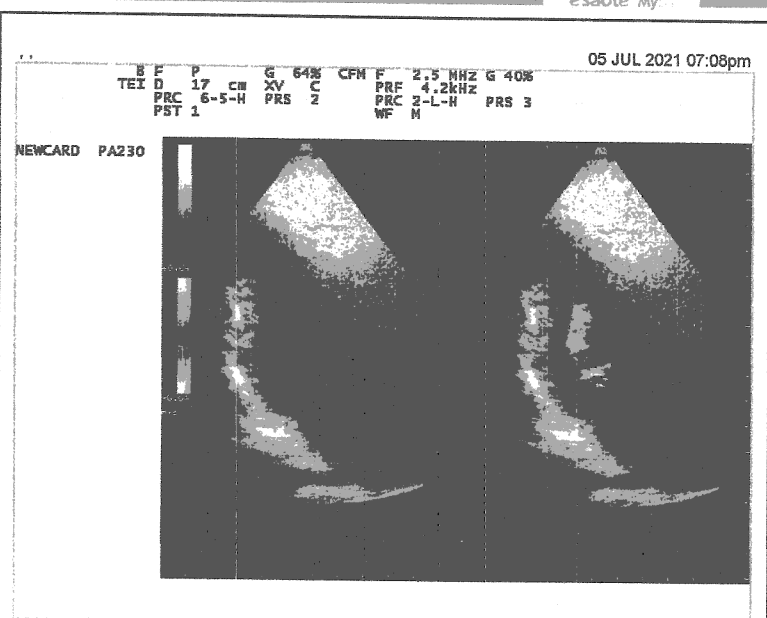
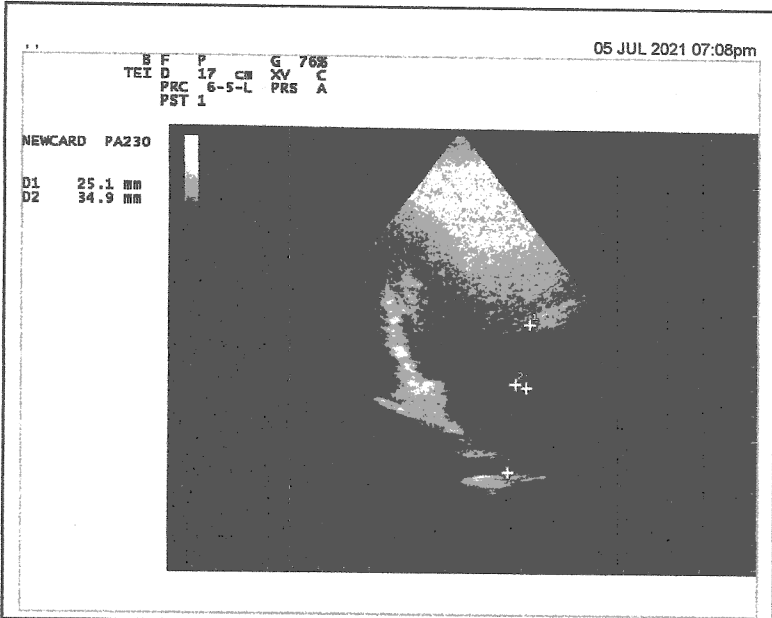


DR.NITIN AGARWAL
DM (Cardiology)
Consultant Cardiologist

This opinion is to be correlated with the clinically findings and if required, please re-evaluate / reconfirm with further investigation.

APPLE CARDIAC CARE, BAREILLY

esaote My...



SATYADEEP DIAGNOSTIC CENTRE

B-55, Deen Dayal Puram, Adjacent to O₂ Gym, Bareilly

Dr. Deepak Saxena
M.S. (Ortho) BHU

Ex Senior Consultant :

- ◆ Distt. Hospital, Bareilly
- ◆ Distt. Hospital, Budaun
- ◆ Pyare Lal Sharma Distt. Hospital, Meerut

Dr. Anil Chaudhary
392

डा० दीपक सक्सेना
एम.एस. (ऑर्थो)

भूतपूर्व वरिष्ठ परामर्शदाता :-


- ◆ जिला अस्पताल, बरेली
- ◆ जिला अस्पताल, बदायूँ
- ◆ प्यारे लाल शर्मा, जिला अस्पताल, मेरठ

डा० रजत सक्सेना

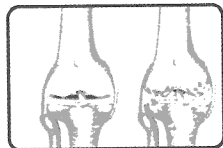
एम.बी.बी.एस. (लखनऊ)
डी.एम.आर.डी.
कन्सल्टेंट रेडियो डायग्नोसिस
एवं. अल्ट्रासोनोलोजिस्ट

डा० स्वाति सक्सेना

एम.बी.बी.एस. (लखनऊ)
एम.डी. (पैथ.)



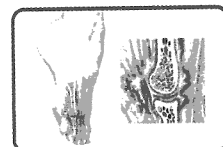
Osteoporosis



Osteoarthritis



Osteomalacia



Osteomyelitis

कमर एवं डिस्क सम्बन्धी दर्द/गर्दन का दर्द - सरवाइकल स्पान्डिलाइटिस, कन्धों के दर्द एवं जाम होना (फ्रोजन शोल्डर), टेनिस एल्बो का विश्वस्तरीय इलाज

यहाँ हड्डी के हर प्रकार के रोगों का पचार आधुनिक विधि से किया जाता है। जोड़ों के दर्द/गठिया इत्यादि का उचित एवं सन्तोषजनक इलाज, टूटी हुई हड्डी को जोड़ने के लिए छोटे चीर से ऑपरेशन एवं प्लास्टर/फिजियोथैरेपी की सुविधा

दिनांक 16/10/2021

Dr. Anil Chaudhary
 - Acft = Turpanum stop of calf
 - Pain left calf esp in night persistent + throbbing pain left knee esp after Exertion
 - Calvit Lc (1 tab) 3
 - Calvit 12 2cc 1m 10/10/21
 - Cap Enon 400 3
 - Cap Celestine 100
 - Cap Nitroglie 400 3
 - Elevation of Ls at bed
 - Crepebandage while walky
 - Do not do the Exertion
 - Avoid therapy Ex in gym
 - Review 2 reports
 - Ref to Dr. Anil Chaudhary Cardiologist or C. Capp Circulation
 - fullness base left foot
 - Calf Tenderness left
 - Covid 19 infection 2 RT-PCR +ve on 16/4 April 2021 instructed by Dr. Subeef Saran & by Dr. Nitin Agrawal Cardiologist
 16/4 SEPT 2021
 20/4 HECT done
 5-7-2021 Echo/Doppler 1st grade LV Dilation & mild functional dysfunction
 16/10/21
 Left Ankle LFT (LFT) color Doppler left leg. 16/10/21
 16/10/21

NOT VALID FOR MEDICO LEGAL PURPOSE

SATYADEEP

SATYADEEP

DIAGNOSTIC CENTRE

B-55, Deen Dayal Puram, Adjacent to O₂ Gym, Bareilly

Dr. Deepak Saxena
M.S. (Ortho) BHU

Ex Senior Consultant :

- ◆ Distt. Hospital, Bareilly
- ◆ Distt. Hospital, Budaun
- ◆ Pyare Lal Sharma Distt. Hospital, Meerut

Dr. Atul Choudhary
384

डा० दीपक सक्सेना
एम.एस. (ऑर्थो)

भूतपूर्व वरिष्ठ परामर्शदाता :-

- ◆ जिला अस्पताल, बरेली
- ◆ जिला अस्पताल, बदायूँ
- ◆ प्यारे लाल शर्मा, जिला अस्पताल, मेरठ

डा० रजत सक्सेना

एम.बी.बी.एस. (लखनऊ)
डी.एम.आर.डी.
कन्सल्टेंट रेडियो डायग्नोसिस
एवं. अल्ट्रासोनोलोजिस्ट

डा० स्वाति सक्सेना

एम.बी.बी.एस. (लखनऊ)
एम.डी. (पैथ.)

दिनांक 16/11/2021

Cl. Pain leg calf persistant

April 2021

HL same 2-34

gk say pain leg knee throbbing leg pain on walking - rest on walking - rest

DR. Anant Lal Sharma
MD
Dr. Rajat Saxena
MD

Xray both knee - AD on one side

1 Vascular Doppler leg L5

AD
Blood + Lipid profile

Dr. Hwt
5 Turpankhi oil
Crepe bandage while walking
Pain after 1 hr walk for local infection

Zentral lvs sep
Dulce day 2 lvs
milk stop


Ch. Ebon Lc 103

Calmit Lc 103

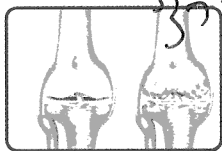
Enzyme Pity

Sandic MR 103

रजत सक्सेना



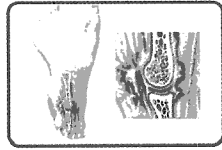
Osteoporosis



Osteoarthritis



Osteomalacia



Osteomyelitis

कमर एवं डिस्क सम्बन्धी दर्द/गर्दन का दर्द - सरवाइकल स्पान्डिलाइटिस, कन्धों के दर्द एवं जाम होना (फ्रोजन शोल्डर), टेनिस एल्बो का विश्वस्तरीय इलाज

यहाँ हड्डी के हर प्रकार के रोगों का पचार आधुनिक विधि से किया जाता है। जोड़ों के दर्द/गठिया इत्यादि का उचित एवं सन्तोषजनक इलाज, टूटी हुई हड्डी को जोड़ने के लिए छोटे चीरे से ऑपरेशन एवं प्लास्टर/फिजियोथेरेपी की सुविधा

NOT VALID FOR MEDICO LEGAL PURPOSE



SATYADEEP

DIAGNOSTIC CENTRE

B-55, Deen Dayal Puram, Adjacent to O₂ Gym, Bareilly

Dr. Deepak Saxena
M.S. (Ortho) BHU

Ex Senior Consultant :

- ◆ Distt. Hospital, Bareilly
- ◆ Distt. Hospital, Budaun
- ◆ Pyare Lal Sharma Distt. Hospital, Meerut

डा० दीपक सक्सेना
एम.एस. (ऑर्थो)

भूतपूर्व वरिष्ठ परामर्शदाता :-

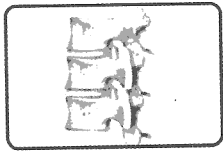
- ◆ जिला अस्पताल, बरेली
- ◆ जिला अस्पताल, बदायूँ
- ◆ प्यारे लाल शर्मा, जिला अस्पताल, मेरठ

डा० रजत सक्सेना

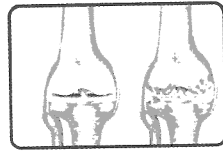
एम.बी.बी.एस. (लखनऊ)
डी.एम.आर.डी.
कन्सलटेंट रेडियो डायग्नोसिस
एवं. अल्ट्रासोनोलोजिस्ट

डा० स्वाति सक्सेना


एम.बी.बी.एस. (लखनऊ)
एम.डी. (पैथ.)



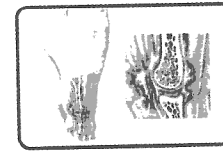
Osteoporosis



Osteoarthritis



Osteomalacia



Osteomyelitis

दिनांक 29/11/2021.....
To Whom This May Concern
(NOT for medico legal purposes)
This is to Certify that Sri Atul Chaudhary aged
about 39yr Sr. Sri M. P Chaudhary whose
signatures are attested below has been under
my treatment as an OPD pt for last one month
for? Myalgia calf left & Synovitis knee joint
(Post Covid 19) & mild Cardiac & Hepatic dysfunction
(as per available test reports) needs rest &
treatment with constant observation for long
duration

(Signature)
29/11/2021
29/11/2021

Dr. Deepak Saxena
M.S. (Ortho)
Associate Professor

Dr. Deepak Saxena
M.S. (Ortho)
Associate Professor
Dept. of Orthopaedics
Reg. No. 25572

कमर एवं डिस्क सम्बन्धी दर्द/गठन का दर्द, कंधों के दर्द, कलाई/कूल्हा/पैरों के दर्द, एंजाइमेटिस, कंधों के दर्द एवं जाम होना (फ्रोज़न शोल्डर), टेनिस एल्बो का विश्वस्तरीय इलाज
यहाँ हड्डी के हर प्रकार के रोगों का पचार आधुनिक उपकरणों/गठिया इत्यादि का उचित एवं सन्तोषजनक इलाज, टूटी हुई हड्डी को जोड़ने के लिए ऑर्थोपेडिक प्लास्टर/फिजियोथेरेपी की सुविधा

NOT VALID FOR MEDICO LEGAL PURPOSE



DR. BRIJESWAR SINGH

M.S. (Ortho)

Senior Consultant & Orthopaedic Surgeon
Specialist in Modern Orthopaedic and Trauma Surgery
Delhi Institute of Trauma & Orthopaedics, Delhi
Sant Parmanand Hospital, New Delhi
SHRI SIDDHI VINAYAK HOSPITAL, BAREILLY
Ph.: 98370-74714, 2510044



डा० गरिमा सिंह

(एम.एस.) गायत्री

स्त्री एवं प्रसूति रोग विशेषज्ञ
समय : प्रातः 10 से 4 बजे तक
शाम 6 बजे से 8 बजे

इमरजेन्सी की सुविधा 24 घण्टे उपलब्ध

112, CIVIL LINES, NEAR PRABHA CINEMA, BAREILLY.

Ref.

Date

Mr. Abul Choudhury

3/2/17

Pain in left knee

Joint Swelling

For

Calcitriol tablet

daily 57
5 days

Supracal

daily

15 days

Dx ungu spray

16 days 3-4 times

For OPD Appointment :
98370-74714, 93591-00009,
For 24 Hrs. Emergency :
0581-2510044, 310510, 9412328135

(नम्बर लगवाने हेतु)
(Time- 8.00 A.M. - 9.00 A.M.)

O.P.D. Timing: 01.00 P.M. to 7.00 P.M.

EMERGENCIES 24 HOURS

VALID FOR 5 DAYS

NOT VALID FOR MEDICO LEGAL PURPOSE



NAME: ATUL CHAUDHRY	SEX: MALE	AGE: 38 YEARS
REFERRED BY :- DR. DEEPAK SAXENA		DATE: 16/11/2021.

INVESTIGATION-LEFT LOWER LIMB VENOUS DOPPLER STUDY

REAL TIME B.MODE STUDY:

The external iliac, common femoral, superficial femoral and popliteal veins are normal in caliber and shows good compressibility

Bilateral sapheno-femoral junction is competent.
Bilateral sapheno-popliteal junction is competent.

PULSED DOPPLER STUDY:

The blood flow in above veins are spontaneous and showed phasic variation with respiration.
The response to valsalva was normal.

The deep veins of the calf shows spontaneous flow.
Mild Dilated tortuous veins seen along the GSV.

IMPRESSION: THIS VENOUS DOPPLER STUDY OF LEFT LOWER LIMB REVEALS:-

- ❖ **BILATERAL SAPHENO-FEMORAL COMPETENCE.**
- ❖ **NO EVIDENCE OF DEEP VEIN THROMBOSIS.**
- ❖ **SCANNED ARTERIES APPEARS NORMAL.**

Please correlate clinically.

DR RAJAT SAXENA
MBBS, DMRD RADIOLOGIST

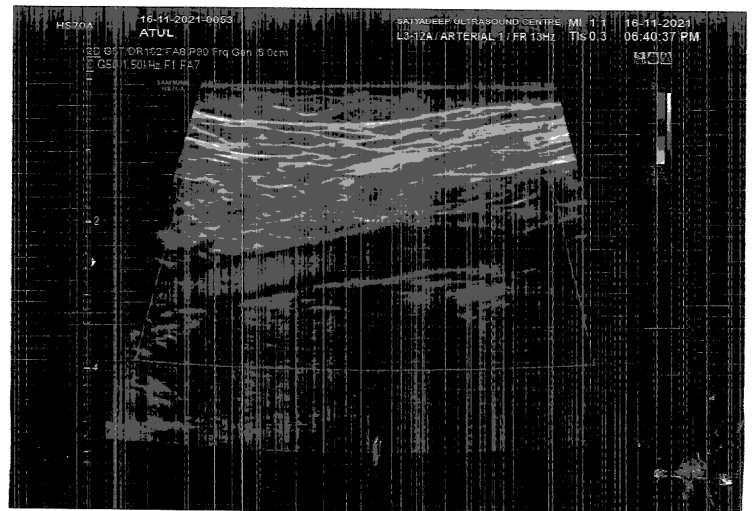
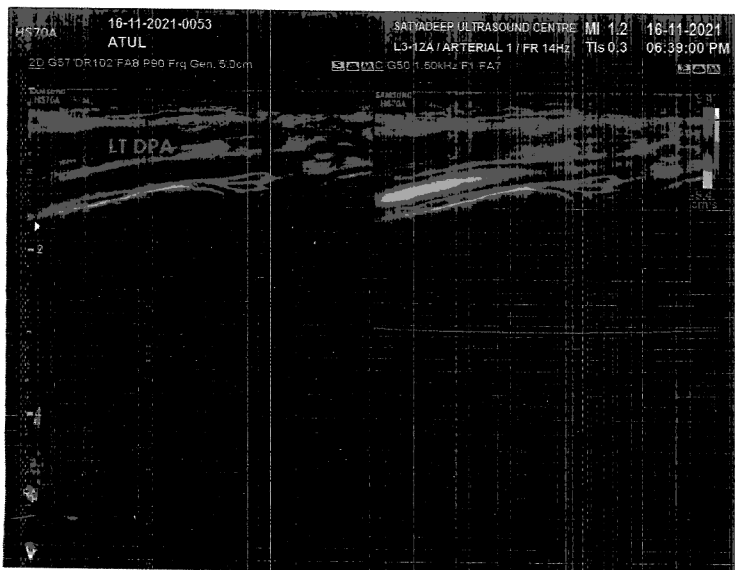
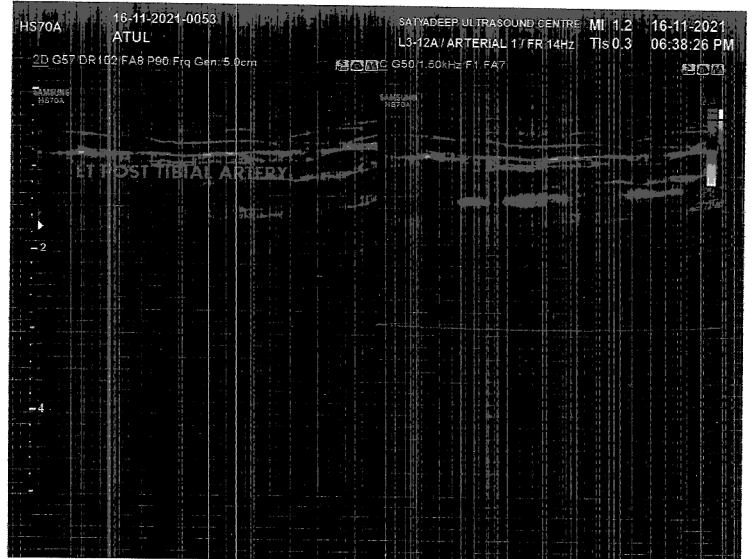
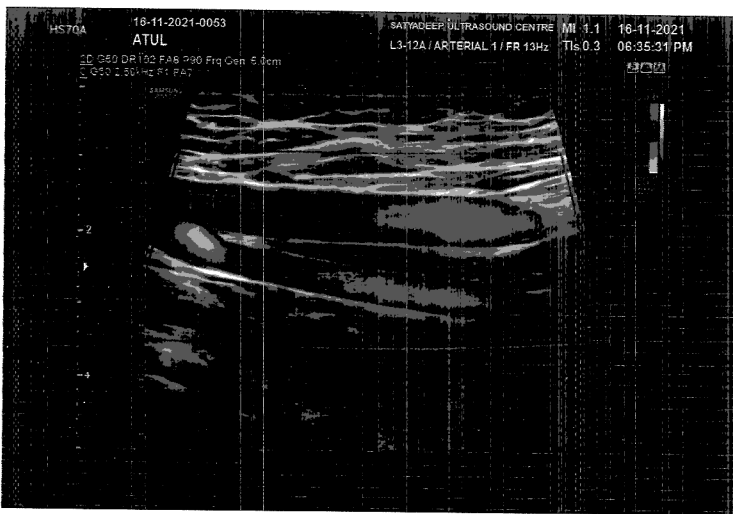
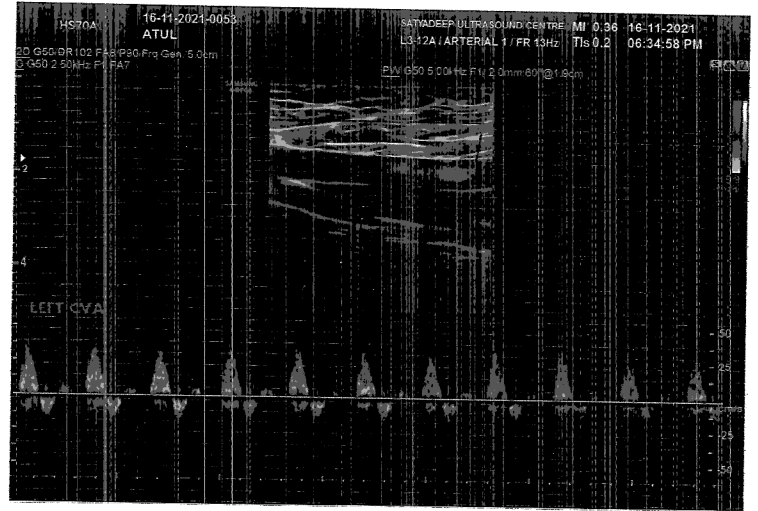
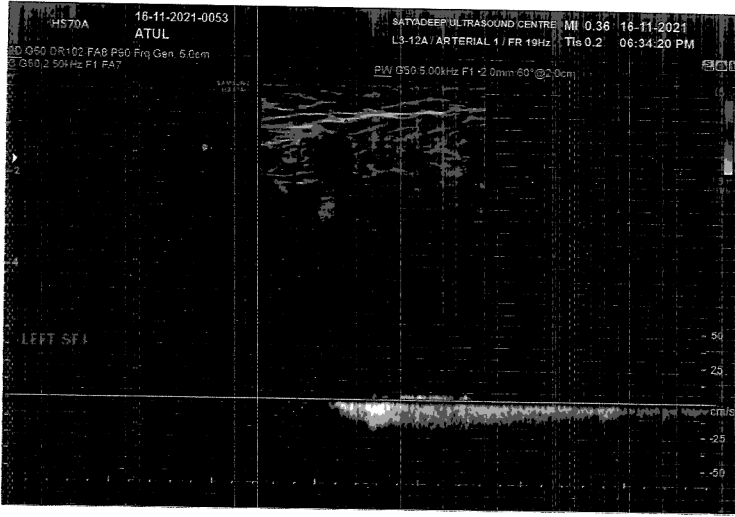


NOT VALID FOR MEDICO LEGAL PURPOSE

Patient

Exam

ID	16-11-2021-0053	Accession #	
Name	ATUL	Exam Date	16112021
Birth Date		Description	
Gender		Sonographer	



The Admission Coordinator
Invertis University
Barcilly

Dated On: 24-11-2021
Student ID: LLM2021045

Subject: Application to request the deposits of fee in installments.

Respected Sir,

This is to state that VANDANA has taken admission in MASTER OF LAWS for in session 2021-22. The total structure for the program including.

Institute Fee		70000.00
Scholarship (if any on tuition fee, for 1st year only)	(Less)	70000.00
Either Hostel (double/single) or Bus		-
Uniform Fee		-
Exam Fee		-
Notebook Fee		4500.00
Insurance Fee		-
Total Amount		265.00
Note: Fee structure subjected to change.		<u>3765</u>

Yours Sincerely,

Institute Fee Installment

- 1st Installment & Date: 0 -
- 2nd Installment & Date: 0 -
- 3rd Installment & Date: 0 -
- 4th Installment & Date: 0 -

Received Amount: 0

Received Date:

Applicant Signature

[Handwritten Signature]
Signature

Hostel Fee Installment:

- 1st Installment & Date: 0 -
- 2nd Installment & Date: 0 -

Other Expenses:

- 1- Uniform -
- 2- Exam 4500.00
- 3- Notebook -
- 4- Insurance 265.00
- 5- Bus -

Other Fee Date: 30-11-2021