

Name: Mr. Yogindra Singh
Age/Gender: 64Yr/M
Referred By: Dr. Malay Sharma
Sample Collection: 23/07/22
Reported: 25/07/22
Mobile No. 7417794367
Receipt No. 83328

HISTOPATHOLOGY REPORT

Lab No: AV/H/1058/22

Specimen: Gastric Biopsy

Gross: Received multiple soft tissue bits. All tissue processed.

Microscopic Examination: Biopsy consists of an ulcerated infiltrating tumour in gastric pyloric type mucosal bits. Tumour is composed of sheets of atypical cells having severe nuclear atypia, hyperchromasia and brisk mitosis. Occasional vague ill-formed acinar formation noted. Tumour cells are seen infiltrating around the benign foveolar epithelium and also into the submucosa through the muscularis mucosae in few bits. Areas of necrosis also seen. No dysplastic epithelium identified in the gastric mucosal epithelium sampled.

Impression: Infiltrating Poorly Differentiated Malignant tumour.

- D/Ds – 1) Adenocarcinoma, 2) High grade NHL.

Kindly correlate clinically with imaging and IHC findings for further opinion.

Adv- IHC for definitive tumour typing.



Dr. Rashmi Khemka

M.D. (PATH)

- Test values may vary with different lab standards, methods, kits and other physiological and biological factors.
- The clinic pathological lab tests involve Man-Machine-Computer interface with slight chances of inadvertent discrepancy and should be immediately discussed & alleviated.
- Report purports for patients care and not for medicolegal documents.
- All cytological & Histopathology reports should be interpreted as an opinion and final diagnosis to be considered in conjunction with clinical & radiological findings only.



ARYAVART HOSPITAL
 A Unit Of The Shreya Medicare Pvt.Ltd
 NH-58, Near Tollplaza, Roorkee Road, Meerut (U.P.)
 7055218361

Pulmonary Function Test Report

Patient Details

ID: 74819
 First Name: Yogendra
 Last Name: Singh
 Smoker: Yes

Birth Date: 10 Aug 1956
 Age: 65
 Gender: Male

Height: 179 cm
 Weight: 80 kg
 BMI: 24.97
 Hb: --- g/dL
 O2%: --- %

Session Details

Session Date: 03 Jun, 2022
 Start Time: 9:53 AM
 Technician: Dinesh Thakur
 Physician: Dr. Diksha Tyagi

Medical Condition: ---

Reimbursement Codes: ---

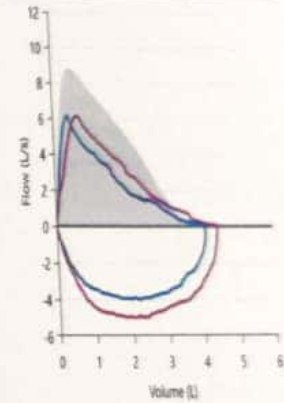
LLN: 70%

Prediction

Adults System Default

FVC

| | | Pre | | | | Post | | | | % Change |
|-----------|-------|-------|-------|-----|---------|-------|-----|---------|---|----------|
| | | Pred. | Best | Gr. | % Pred. | Best | Gr. | % Pred. | | |
| FVC | L | 4.49 | 4.10 | A | 91% | 4.46 | A | 99% | ▲ | 9% |
| FEV1 | L | 3.42 | 2.73 | A | 80% | 3.09 | A | 90% | ▲ | 13% |
| FEV1/FVC | % | 76.51 | 66.49 | | 87% | 69.16 | | 90% | ▲ | 4% |
| FEF 25 | L/sec | 7.39 | 4.14 | | 56% | 4.90 | | 66% | ▲ | 18% |
| FEF 50 | L/sec | 4.39 | 1.78 | | 41% | 2.66 | | 61% | ▲ | 49% |
| FEF 75 | L/sec | 0.77 | 0.78 | | 102% | 0.93 | | 121% | ▲ | 19% |
| FEF 25-75 | L/sec | 2.69 | 1.80 | | 67% | 2.10 | | 78% | ▲ | 17% |
| PEF | L/sec | 8.31 | 6.18 | | 74% | 6.13 | | 74% | ▼ | -1% |
| PIF | L/sec | --- | 4.03 | | --- | 5.02 | | --- | ▲ | 25% |
| FET | sec | --- | 6.47 | | --- | 6.92 | | --- | ▲ | 7% |
| Lung Age | Years | 65.81 | 90.64 | | 138% | 77.89 | | 118% | ▼ | -14% |



| | | Pre | | | | | Post | | | | |
|----------|-----|-------|-------|-------|--------|-------|-------|--------|-------|------|-------|
| | | Best | LLN | ULN | Zscore | %Pred | Best | Zscore | %Pred | Chng | %Chng |
| FVC | L | 4.10 | 3.37 | 5.62 | -0.56 | 91% | 4.46 | -0.04 | 99% | 0.36 | ▲ 9% |
| FEV1 | L | 2.73 | 2.52 | 4.27 | -1.27 | 80% | 3.09 | -0.63 | 90% | 0.36 | ▲ 13% |
| FEV1/FVC | % | 66.49 | 63.73 | 87.74 | -1.31 | --- | 69.16 | -0.98 | --- | --- | --- |
| FET | sec | 6.47 | --- | --- | --- | --- | 6.92 | --- | --- | --- | --- |

Pulmone

PFT Outside The Box

Patient: Yogendra Singh, ID: 74819

1 / 3

Page 2 of 3


(DCP)
 Consultant



ARYAVART HOSPITAL
A Unit Of The Shreya Medicare Pvt.Ltd

NH-58, Near Tollplaza, Roorkee Road, Meerut [U.P.]
7055218361

FVC



Pulmone PFT Outside The Box Patient: Yogendra Singh, ID: 74819



ARYAVART HOSPITAL
A Unit Of The Shreya Medicare Pvt.Ltd

NH-58, Near Tollplaza, Roorkee Road, Meerut [U.P.]

7055218361

Medical Report

Diagnosis: *mild obstructive ventilatin defect c
reversibility test he*

According to ATS/ERS guidelines - Interpretation: Normal
Severity: Mild

Can't generate an interpretation chart due to missing DLCO Test

Conclusion:

Signature: 

PFT Outside The Box Patient: Yogendra Singh, ID: 74819



ARYAVART HOSPITAL

N.H. 58, Near Tollplaza, Roorkee Road, Meerut (U.P.)

Patient Name: Mr. Yogendra
Registration No: 000
Diagnosis:

Age/Sex: 65 Yrs/M

Ref By:
Date: 23-07-2022 10:25:00 AM
Procedure: Endoscopy

OESOPHAGUS

UPPER 1/3 : Normal

MIDDLE 1/3 : Normal

LOWER 1/3 : Normal

GE-JUNCTION : 40 cm

STOMACH : Ulceroproliferative growth seen in pylorus extending into D1, scope passed with mild difficulty into D2.

D2 : Normal

IMPRESSION : ?GOO-CA Pylorus
Biopsy Done
RUT Done

Assisted by : Shubham

Dr. Malay Sharma
MD DM (Gastro)

