



VM-281219070

104981181



VANDANAKUMARI

# श्री ० अस्पताल / A.I.I.M.S. HOSPITAL विभाग / Out Patient Department

पान मना है / SMOKING IS PROHIBITED IN HOSPITAL PREMISES



₹ 10 कर्म स्वच्छता को ओ

Mon, Wed, Fri

OPR-6

एक/Unit

विभाग/Dept.

ब०रो०वि० पंजीकृत सं०/O.P.D. Regn. No.

नाम/Name 2019/002/0011319 (Physical Medicine & Rehabilitation)	दिना/पुरु/स्त्री/पुत्री F/T/S/W/D or	PMR	Dr. S. L. Yadav	104981181
नाम: वनदाना कुमारी VANDANA KUMARI	W/O: पति:श विजय कुमार हिमनशु SH VIJAY KR. HIMANSHU	महिला F	52 वर्ष/Y	H NO. 1A-207, GURJIDER VILLAR TOWNSHIP AWHO, GREATER NOIDA, UTTAR PRADESH, INDIA

निदान/Diagnosis

OA L knee

दिनांक/Date	उपचार/Treatment
<p>Registration Time : Mon-Fri: 8:30 - 11:00 AM Sat: 8:30 - 10:30 AM</p> <p>Done By: PMR Counter/7423</p> <p>Room No. 9, Ground Floor(तल मंजिल)</p> <p>27/12/2019 10:19:18 AM</p> <p>*TO TAKE APPOINTMENT NUMBER THROUGH PHONE, DIAL: 011-26589142</p> <p>**फोन के माध्यम से अप्पॉइंटमेंट नंबर लेने के लिए, डायल : 011-26589142</p> <p>***Doctor may not be available. However you may be seen by some of the Doctors in the department</p> <p>***आपके डॉक्टर के उपलब्ध न होने पर, आपको विभाग में अन्य किसी डॉक्टर द्वारा देखा जा सकता है।</p>	<p>1. Isometric Quad ex (VMO) +</p> <p>Progressive Resistive Quad ex</p> <p>2. Avoid Squatting / Cross legged siting</p> <p>3. Tab. Orcelexin 50mg 1-1 जए-शाम</p> <p>4. Tab. Torcoxia BCD 90mg दोपहर में खाने के बाद</p> <p>5. Tab. Calciumre 3 100 पर रेखांक वृषके साथ</p> <p>6. Volitra sel CA जए शाम</p> <p>x kumari</p> <p>27/12/2019 Dr. S. L. Yadav, MD, DNB</p>

59

AIIMS FREE GENERIC PHARMACY  
(V) MEDICINE RECEIVED  
NAME: 27/12/19  
DATE: 27/12/19  
SIG: 27/12/19



भौतिक विकिरण एवं पुनर्वास  
DEPARTMENT CLEAN AND GREEN AIIMS / एम्स को यही संकल्प, स्वच्छता से काया कल्प  
अखिल भारतीय अंगदान परिषद  
ALL अंगदान: जीवन का बहुमूल्य उपहार / ORGAN DONATION - A GIFT OF LIFE  
O.R.B.O., AIIMS, 26588360, 26593444, www.orbo.org Helpline - 1060 (24 hrs service)





for 1/2 an hour.

• Tab pregabalin HT 75 night

• Tab FURIC 40 mg <sup>00</sup> and 80 all day

• Inj Arachidol 62 units 1/4 today and repeat after 3 wks - (1)

• Inj methylcobal 1 amp once a (4)

• Tab Rosuvastatin 10 100 0-0

↓  
summary

1 month

• treatment

• ca

• S. strachand

• PMH

MRI L5 spine - (3T), x-ray L5 spine R. lat in flex + ext -



VM-281219070

104981181



VANDANAKUMARI

शरीरमाघं खलु

# अस्पताल / A.I.I.M.S. HOSPITAL विभाग / Out Patient Department



पान मना है / SMOKING IS PROHIBITED IN HOSPITAL PREMISES

Mon, Wed, Fri

OPR-6

<

एकक/Unit \_\_\_\_\_

विभाग/Dept. \_\_\_\_\_

व०रो०वि० पंजीकृत सं०/O.P.D. Regn. No. \_\_\_\_\_

नाम/Name	पिता/पुत्र/पत्नी/पुत्री F/S/W/D of	लिंग Sex	आयु Age	डॉक्टर Dr. S. L. Yadav	पता/Address
नाम: वनदाना कुमारी VANDANA KUMARI	W/O : पति :श विजय कृ० ? हिमनशु SH VIJAY KR. HIMANSHU	महिला F	52 वर्ष/Y		H NO. 1A-207, GURJIDER VIHAR TOWNSHIP AWHO, GREATER NOIDA, UTTAR PRADESH, INDIA

निदान/Diagnosis

दिनांक/Date	उपचार/Treatment
<p>Registration Time : Mon-Fri: 8:30 - 11:00 AM Sat: 8:30 - 10:30 AM</p> <p>Done By: PMR Counter/7423</p> <p>Room No. 9, Ground Floor (तल मंजिल)</p> <p>27/12/2019 10:19:18 AM</p> <p>*TO TAKE APPOINTMENT NUMBER THROUGH PHONE, DIAL: 011-26589142</p> <p>**फोन के माध्यम से अपाईटमेंट नंबर लेने के लिए, डायल : 611-26589142</p> <p>***Doctor may not be available, However you may be seen by some of the doctors in the department</p> <p>***आपके डॉक्टर के उपलब्ध न होने पर, आपको विभाग में अन्य किसी डॉक्टर द्वारा देखा जा सकता है।</p>	<p>OA L knee</p> <p>1. Isometric Quad ex (VMO) +</p> <p>Progressive Resistive Quad ex</p> <p>2. Avoid Squatting / Cross legged siting</p> <p>3. Tab. Orcelem 50mg 1-1 जए-शाम</p> <p>4. Tab. Torcoxia BCD 90mg दोपहर में खाने के बाद</p> <p>5. Tab. Celebrex 3 100 पर खाने के बाद</p> <p>6. Volitra sel CA जए शाम</p> <p>x kurolet</p>

59

AIIMS FREE GENERIC PHARMACY  
(✓) MEDICINE RECEIVED  
NAME: \_\_\_\_\_  
DATE: 27/12/19  
SIGN: \_\_\_\_\_

Dr. S. L. YADAV, MD, DNB  
27/12/19



DEPARTMENT CLEAN AND GREEN AIIMS / एम्स को यही संकल्प, स्वच्छता से काया कल्प  
अखिल भारतीय आयुर्विज्ञान संस्थान  
ALL अंगदान जीवन का बहुमूल्य उपहार / ORGAN DONATION - A GIFT OF LIFE  
O.R.B.O. AIIMS: 26588360, 26593444, www.orbo.org Helpline - 1060 (24 hrs service)



27-12-2019 10:23



**MAHAJAN IMAGING**  
*From X-rays to Molecular Imaging*

K-18, Hauz Khas Enclave, New Delhi- 110016  
☎ 011- 43138000, info@mahajanimaging.com  
www.mahajanimaging.com  
CIN : U85199DL1999PTC101010



**Dr. Harsh Mahajan, MD**

*Honorary Radiologist to the President of India, Padma Shri*

- Dr. (Col.) R.K. Sharma, MD • Dr. Punit Sethi, MD • Dr. Anjana Aggarwal, DMRD
- Dr. Geetanjali Nanda, MD • Dr. Vishal Maskara, MD • Dr. Aditya Patney, MDS

---

Visit No.	: 031905090070	UID No.	: 407283
Patient Name	: <b>Ms. VANDANA KUMARI</b>	Reg. Date	: 09/May/2019 11:23 AM
Age/Sex	: <b>52 YRS / Female</b>	Report Date	: 09/May/2019 02:23PM
Referred By	: Dr. HAVIND TANDON	Print Date	: 09/May/2019 02:23 PM

---

MR imaging of the **left knee joint** was performed using spin-echo and gradient-echo pulse sequences and high resolution T1-and T2-weighted serial sections were obtained in the sagittal, axial and coronal planes using a dedicated phased-array extremity coil on a 1.5 Tesla scanner. Additional 3D volume imaging was also performed using CUBE technology and 0.6mm serial T2-weighted sections obtained in multiple planes.

*Clinical profile:- Complaint of pain.*

Full thickness loss of articular cartilage is seen in medial femorotibial compartment with large osteophyte formation and subarticular marrow edema. The lateral femorotibial compartment shows irregularity of articular cartilage. The patellofemoral joint shows large osteophyte formation with irregularity and thinning of articular cartilage along with variable thickness chondral defects.

Myxoid degeneration is seen in posterior horn of medial meniscus in the form of intrasubstance increased signal intensity with posterior horn root tear. The lateral meniscus is normal with no evidence of tear or area of signal alteration.

Mild knee joint effusion is seen.

The anterior and posterior cruciate as well as the lateral and medial collateral ligaments are unremarkable with no evidence of a tear. The posterolateral corner structures are unremarkable.

The quadriceps tendon, ligamentum patellae and patellofemoral retinaculum are unremarkable. The popliteus muscle belly and tendon appear normal.

**OPINION: MR findings are suggestive of tricompartmental osteoarthritic changes with myxoid degeneration & posterior horn root tear in medial meniscus and mild knee joint effusion as described above. Please correlate clinically.**

  
**DR. GEETANJALI NANDA, MD**  
DMC NO-50982

Hauz Khas Enclave • Pusa Road • Defence Colony • Gurugram • PSRI Hospital • Sir Ganga Ram Hospital  
• Fortis Flt. Lt. Rajan Dhall Hospital • Sports Injury Centre, Safdarjung Hospital • Bali Nagar • Dehradun

• Dual Energy 750-HD GSI Spectral CT • Dual Energy GSI Cardiac CT Angiography • Open Standing MRI • 1.5 Tesla Volume MR • Cone Beam CT  
• 4D Ultrasound & Colour Doppler • Ultrasound with CT/ MRI Fusion • True Digital X-Ray IITV • True Digital OPG & Cephalogram • Digital Mammography  
• DEXA Bone Densitometry • Echocardiography • CT/US Guided Biopsies



**Dr. Harsh Mahajan, MD**

*Honorary Radiologist to the President of India, Padma Shri*

- Dr. (Col.) R.K. Sharma, MD • Dr. Punit Sethi, MD • Dr. Anjana Aggarwal, DMRD
- Dr. Geetanjali Nanda, MD • Dr. Vishal Maskara, MD • Dr. Aditya Patney, MDS

---

Visit No.	: 031905090070	UID No.	: 407283
Patient Name	: <b>Ms. VANDANA KUMARI</b>	Reg. Date	: 09/May/2019 11:23 AM
Age/Sex	: <b>52 YRS / Female</b>	Report Date	: 09/May/2019 02:23PM
Referred By	: Dr. HAVIND TANDON	Print Date	: 09/May/2019 02:23 PM

---

MR imaging of the **right knee joint** was performed using spin-echo and gradient-echo pulse sequences and high resolution T1-and T2-weighted serial sections were obtained in the sagittal, axial and coronal planes using a dedicated phased-array extremity coil on a 1.5 Tesla scanner. Additional 3D volume imaging was also performed using CUBE technology and 0.6mm serial T2-weighted sections obtained in multiple planes.

*Clinical profile:- Complaint of pain.*

The study reveals osteoarthritic changes in medial femorotibial compartment in the form of full thickness loss of articular cartilage with marginal osteophyte formation. Irregularity of articular cartilage is also seen in lateral femorotibial compartment with small osteophyte formation. The patellofemoral joint shows variable thickness loss of articular cartilage with patellofemoral osteophytes. Mild lateralization of patella is seen.

Mild knee joint effusion is seen.

Few osseous loose bodies are seen in posterior joint space behind the lateral femoral condyle measuring about 11 to 12mm in size.

The medial and lateral menisci are normal with no evidence of tear or area of signal alteration.

The anterior and posterior cruciate as well as the lateral and medial collateral ligaments are unremarkable with no evidence of a tear. The posterolateral corner structures are unremarkable.

The quadriceps tendon, ligamentum patellae and patellofemoral retinaculum are unremarkable. The popliteus muscle belly and tendon appear normal.

**OPINION: MR findings are suggestive of tricompartmental osteoarthritic changes with mild knee joint effusion and loose bodies in posterior joint space. Please correlate clinically.**

**DR. GEETANJALI NANDA, MD**  
**DMC NO-50982**

Hauz Khas Enclave • Pusa Road • Defence Colony • Gurugram • PSRI Hospital • Sir Ganga Ram Hospital  
• Fortis Flt. Lt. Rajan Dhall Hospital • Sports Injury Centre, Safdarjung Hospital • Bali Nagar • Dehradun

• Dual Energy 750-HD GSI Spectral CT • Dual Energy GSI Cardiac CT Angiography • Open Standing MRI • 1.5 Tesla Volume MR • Cone Beam CT  
• 4D Ultrasound & Colour Doppler • Ultrasound with CT/ MRI Fusion • True Digital X-Ray IITV • True Digital OPG & Cephalogram • Digital Mammography  
• DEXA Bone Densitometry • Echocardiography • CT/US Guided Biopsies




Joint View Clinic

Dr. Havind Tandon

MS (Ortho)  
Senior Consultant Orthopaedic Surgeon  
Adult Joint Reconstruction  
drhavind@icloud.com  
www.jointviewclinic.com

(S/O Dr. Deepak me)



Dr. VANDANA KUMARI  
52F

(84)

(L) Knee  
synovitis

10166.935

locking knee

Part t/o (R) knee pain

Per M

5'3"

72 kg

Adv: -


X Ray FLFS

MRI b/c knee.

(cartilage regrowth)

T MUCOXIA - SA

60y



5

MO ROAL

COLD PACK.

✓ CBC	12.3
✓ ESR	63
✓ CRP	10.15
✓ RA	<10
✓ FBS	97
✓ HbA1C	5.6
✓ TFT	NMN.
✓ KFT	28/0.7
Uric Acid	5.1
✓ S. Calcium	8.5
✓ VITD <sub>25</sub> OH	42
✓ Vit. B <sub>12</sub>	44
✓ UrineR/M	3-4

*[Signature]*  
06/5/19

R. No. : 1206, Mon/Tue/Thu/Fri 12-4; Wed/Sat 8-12 Indraprastha Apollo Hospitals Sarita Vihar, Mathura Road, New Delhi-76

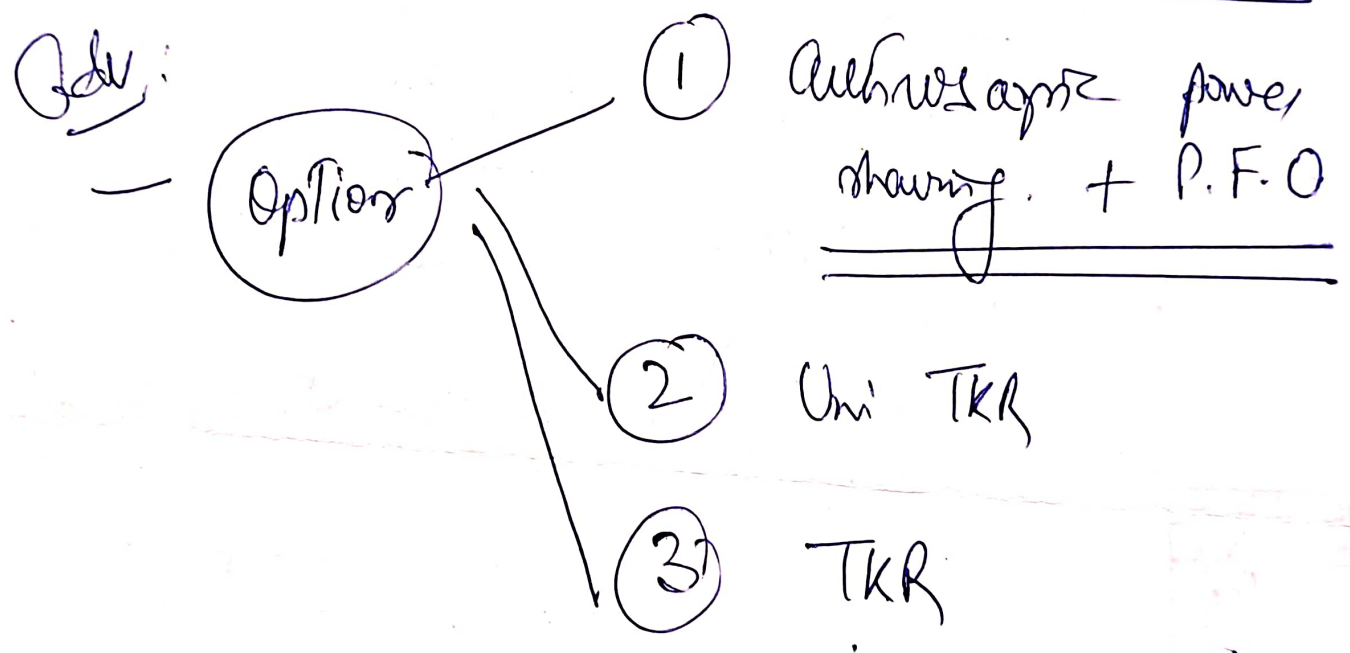
Consultation by Appointment only. Call & Confirm Appt. Between - 9-6 p.m. with Tinky +91-813-007-5257, +91-112-987-1206

Address for Correspondence : C-55, Anand Niketan, New Delhi - 110021

13/5/19

Ons pt's husband

Xray + MRI → Medial compartment  
Adv OA (L) > (R)  
when views  
& tricompartmental OA



① ——— ①  
 X [ ] X  
 T ORCERIN - 9M  
 Colloflex powder  
 60

① ——— ①  
 T MUCONA - 5  
 X 5  
 → Cold pack  
 → Use STICK  
 → STATIC CYCLING

13/5/19



**DEPARTMENT OF RADIOLOGY**

**Patient Details** : Dr. VANDANA KUMARI | Female | 52Yr 1Mth 5Days

**UHID** : APD1.0010166935 **Patient Location:** OP

**Patient Identifier:** DEL1OPP2308408



**DRN** : 119080843

**Completed on :** 06-MAY-2019 16:00

**Ref Doctor** : Dr. H. TANDON

**X-RAY BOTH KNEES LATERAL AND SKYLINE VIEW**

**Report ::**

Both knee joints severe reveals reduced medial tibio femoral joint space with subchondral sclerosis.

Tibial spiking seen bilaterally.

Marginal tibio femoral and patello femoral osteophytes seen.

**IMPRESSION:**

SEVERE OSTEOARTHRITIS BOTH KNEES.

--- END OF THE REPORT ---


  
DR. BALRAJ SINGH GILL

SENIOR CONSULTANT

Keep the records carefully and bring them along during your next visit to our hospital

For enquiry & appointments contact : **011-26925801 / 26925858**

DEPARTMENT OF RADIOLOGY

**Patient Details** : Dr. VANDANA KUMARI | Female | 52Yr 1Mth 5Days  
**UHID** : APD1.0010166935 **Patient Location:** OP  
**Patient Identifier:** DEL1OPP2308408   
**DRN** : 119080842 **Completed on :** 06-MAY-2019 15:59  
**Ref Doctor** : Dr. H. TANDON

**BOTH HIP TO ANKLE ALIGNMENT VIEW**

**Report ::**

Right hip joint to right ICN = 40.37 cm.

Right ICN to right ankle joint = 31.21 cm.

Right angle = 172°/8°

Left hip joint to left ICN = 40.27 cm.

Left ICN to left ankle joint = 31.37 cm.

Left angle = 176°/4°

— END OF THE REPORT —

  
DR. BALRAJ SINGH GILL  
SENIOR CONSULTANT

Keep the records carefully and bring them along during your next visit to our hospital

For enquiry & appointments contact : **011-26925801 / 26925858**



Accredited by

**ORTHOPAEDICS UNIT - 2**

**Dr. Brajesh Koushle**

MBBS, MS  
Additional Director - Orthopaedics  
Spl. Joint Replacement (Hip & Knee)  
Spl. Sports Injuries & Arthroscopies  
Member Medical Committee Common  
Wealth Games 2010,  
Indian Athletic Team  
Honorary Consultant,  
Mob. 9312404648  
(Monday & Thursday)

**Dr. Amit Pachauri**

MBBS, MS, (Ortho)  
Attending Consultant - Orthopaedics  
Spl. Joint Replacement (Hip & Knee)  
Spl. Trauma  
Mob. +919582891319  
(Monday & Thursday)

**Dr. Gourav Thakral**

MBBS, DNB (Ortho), MNAMS (Ortho)  
Attending Consultant - Orthopaedics  
Spl. Joint Replacement (Hip & Knee),  
Arthroscopies  
Specialist Foot & Ankle Surgery  
Mob. +919811184304  
(Monday & Thursday)

Patient Name ..... Vandana Kumari ..... Date ..... 4/1/18  
Age ..... 51 ..... Sex ..... F ..... UHID No. ..... 643106  
Clinical Diagnosis .....

**Advice**

Radiating pain (R) lower limb

Pain (R) knee

Adv

① X-ray (R) knee & AP (stair)

② X-ray 2-5 spine & AP



**Clinical Presentation**

- ① Tab Insulate NP 10b after dining  
- o - x x 2oclay
- ② Tab Myristin 1Bh x 2month  
o - o after near
- ③ Tab C-D-nee care 10b after near  
- o - x 2month
- ④ Tab Etoshure 90mg 10b after RFX 1odg  
- o -

For Appointment :  
Mr. Pankaj : 9650268882  
Between 9.00 am to 5.30

DEPARTMENT OF RADIO DIAGNOSIS AND IMAGING

Name: Mrs. VANDANA KUMARI UHID: FHL5.643106  
Age / Sex: 51 Year(s) / Female Order No / Order Date #####/2018-01-04  
Doctor: Dr. Brajesh Koushle Reporting Date: 04-Jan-2018

KNEE JOINT X-RAY (AP LATERAL VIEW) RIGHT SIDE

- Osteophytes present on medial tibial and femoral condyles and patellar poles .
- Reduced medial tibio-femoral joint space .
- Bone density is normal.

IMPRESSION: OA right knee joint.

Suggest clinical correlation.

*Handwritten signature*

Dr. Shekhar Kalia

DR. DINESH KAPOOR MD  
DIRECTOR & HOD

DR. ARTI CHATURVEDI MD  
SR. CONSULTANT

DR. DEEPTI M. CECIL MD SR  
CONSULTANT

DR. ABHISHEK SHEKHAR  
DMRD CONSULTANT

DR. SHEKHAR KALIA  
MD, DNB, ATTENDING  
CONSULTANT

DR. HARMEET KAUR RISSAM MD  
ATTENDING CONSULTANT

Note : Impression is not a diagnosis and should be correlated with the Clinical findings, Lab & other radiological investigations.

International Hospital Limited

CIN: U74999HR1994PLC048225

Registered Office : Fortis Memorial Research Institute, Sector-44, Gurgaon-122002 (India)  
Tel: +91-124-438 6666, Fax: +91-124-496 2222

DEPARTMENT OF RADIO DIAGNOSIS AND IMAGING

Name: Mrs. VANDANA KUMARI UHID: FHL5.643106  
Age / Sex: 51 Year(s) / Female Order No / Order Date #####/2018-01-04  
Doctor: Dr.Brajesh Koushle Reporting Date: 04-Jan-2018

LUMBAR SPINE X-RAY ( AP LATERAL VIEW )[]

Straightening of lumbar lordosis.

Vertebral bodies are normal in height and density. Posterior neural arches are also normal.

Tiny Marginal osteophytes are seen at L3 and L5 vertebral end plates.

Intervertebral disc spaces are normal.

Pre and paravertebral soft tissues are normal.

SI joints are normal in appearance.

Suggest clinical correlation.

Dr. Shahrukh Ahmed

DR. DINESH KAPOOR MD  
DIRECTOR & HOD

DR. ARTI CHATURVEDI MD  
SR.CONSULTANT

DR. DEEPTI M. CECIL MD SR  
CONSULTANT

DR. ABHISHEK SHEKHAR  
DMRD CONSULTANT

DR. SHEKHAR KALIA  
MD,DNB,ATTENDING  
CONSULTANT

DR.HARMEET KAUR RISSAM MD  
ATTENDING CONSULTANT

Note : Impression is not a diagnosis and should be correlated with the Clinical findings, Lab & other radiological investigations.



DR. SUDHA'S

# ayurveda KENDRA

Website : www.ayurveda-kendra.com E-mail : sudhaasokan@hotmail.com

21/2/15

Director :

**Dr. (Mrs.) K. Sudha Asokan, B.A.M. MD (Ayurveda)**  
Regd. No. 6733 (Delhi) 4006 (Kerala)

Date: 30/12/21

Mrs. Vandana Kamen. 52 yem

Sense o. Akur  
Covidi oct.

① V. Rasnardi Kestraye | 10am + 4pm  
Punamveda Kestraye  
Warm Water et 7AM + 4PM

②. Bahelkaleansha 15ml 30am 2 time after  
Punamvera 15ml mix o o after food.

③. Ayus 4 lines. | 1 each after breakfast  
Jalashma Cap | 1 each after bF & dinner.

4. Aripathy choorna 1 tsp with warm water at bed time.

5. V. Rasnardi Advised Niglicid - 3 dyp.

7 days ehege. Rs. 23000/-  
celebrating

Hospital: B-5/99, Safdarjung Enclave, New Delhi-110029 Tel.: 011-26161606, 26182022, 41652898, Mob.: 8599998811

Treatment Centres :

Kerala Holiday Retreat : Thrithaloor, Tippu Sulthan Road, Near Sarada Ayurvedic Pharmaceuticals,  
Post office- Vatanapilly, Thrissur (District), Kerala-680619 Ph.: 91-487-260 2288, Mob.: 91-9387 100 443

1990-2020

20 years

The medicines given do not fall within the meaning of food, toiletry products, tonics and disinfectors

Breakfast.

6:30 AM -

6:45 - Takro Pellèguè, some Aloo -  
gud + Amles.

8 AM. 1-2 glass of lukewarm  
water.

7 AM. — Medicine.

9 AM - Breakfast. Spiced - with saled.

Tea. cup. ~~to cup. Fruits.~~

ⓑ Dhalia + Oats

Fruits - 11 AM.

~~12:00~~

1 PM - Lunch - Ratti - 2.

Saled, Sabji - Dal.

4 PM - Tea.

8 PM - Dinner -

Ratti + Dal + Sabji

1 cup milk at  
bedtime + Haldi.

---

Consumable

①

a) Valiya Rasnadi Kashayam - 5ml

b) Punaenavadi Kashayam - 5ml

5ml each with 40ml warm water  
morning and evening empty stomach.

②

a) Rohetakarishtam - 15ml

b) Punaenavasavam - 15ml

15ml each two times after food.

③

a) Ayur 4 liver - 1 cap

b) Goleshua - 1 cap

1 each after Breakfast and dinner.

④ Avipathy Choovanam

1 tea spoon with 1 glass <sup>warm</sup> water at bedtime.

⑤ Eladi churnam