



# Health Care Imaging Centre

43, Shivaji Road, Near N.A.S. College, (Opp. Shankar Ashram) Meerut. (U.P.)  
Ph.: 0121-2652434, 2650506

Helpline : 9760011538

- 3 Tesla Platform MRI (HD)
- Multi-Slice Cardiac C.T.
- 3D & 4D Ultrasound
- Digital O.P.G.
- Digital X-Rays
- DEXA Scan (BMD)
- Digital Mammography

HCIC No. :	012002000782	Reg. Date :	05 Feb 2020 ✓
Patient Name :	Mrs. SHEELA RANI	Report Date :	05 Feb 2020
Age/Sex :	71 YRS/FEMALE	Referred By :	Dr. S.P. Sondhi M.D. (Medi)

## RENAL ARTERY DOPPLER & ULTRASOUND WHOLE ABDOMEN

(Known case of hypertension & hypothyroidism)

**Right kidney** measures 10.5x3.9 cms. **Left kidney** measures 9.3x4.6 cms. **Both** kidneys are hyperechoic with altered corticomedullary differentiation. Renal margins are lobulated. No evidence of hydronephrosis or calculus is seen.

### Renal Arteries Doppler

### PSV

Mild diffuse atherosclerotic changes are seen in aorta.	
Aorta	40.67 cm/s.
Right renal artery hilum	39.18 cm/s.
Left renal artery hilum	38.72 cm/s.
Renal artery aorta ratio	Normal
Right renal artery Upper	27.86 cm/s. RI:- 0.67
Mid	16.25 cm/s. RI:- 0.62
Lower	18.02 cm/s. RI:- 0.61
Left renal artery Upper	28.11 cm/s. RI:- 0.66
Mid	31.16 cm/s. RI:- 0.71
Lower	26.91 cm/s. RI:- 0.68

**Bilateral renal artery flow at the origin level is poorly visualized.**

**Urinary bladder** is partially filled by urine.

**Uterus** measures 7.3x2.9 cms. It is post menopausal.

Adenexal sites are clear. Pouch of douglas is clear.

**Liver** shows normal echotexture. No dilatation of intrahepatic biliary radicles is seen. Liver margins are smooth and regular. Hepatic veins are normally opening into IVC. IVC is normally opening into right atrium.

**Gall-bladder** is not visualized (H/o Cholecystectomy).

**C.B.D.** is normal in caliber. It measures 3mm

**Pancreas** has normal ultrasound appearance.

Portal and splenic veins are normal in caliber with normal flow. Portal vein measures 9.1mm

**Spleen** appears normal. It measures 7.2x3.1 cm.

No evidence of ascites, pleural effusion or retroperitoneal lymphadenopathy is seen.

**Opinion:- Sonologically findings are suggestive of:-**

- **Hyperechoic renal parenchyma with altered corticomedullary differentiation bilaterally.**
- **Poorly visualized arterial flow at origin level of bilateral renal arteries, otherwise segmental renal arteries doppler - Normal.**

**Adv:- MR renal angiography**

Dr. Sanjay Gupta  
MD (Radio-diagnosis)

Dr. Alka Agarwal  
MBBS (IFUMB)

Dr. Gaurav Jain  
MBBS

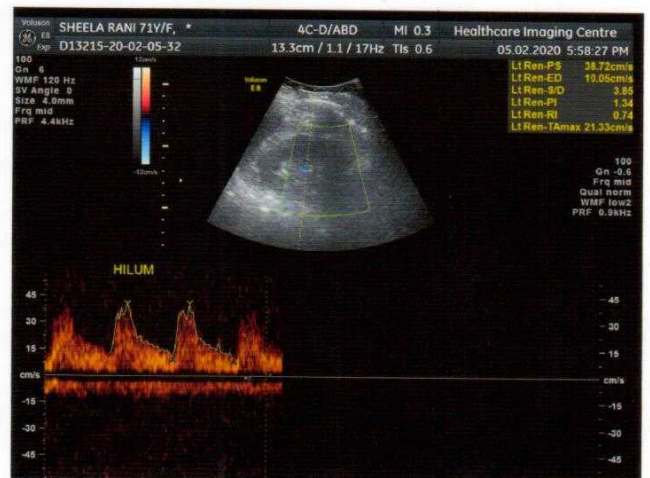
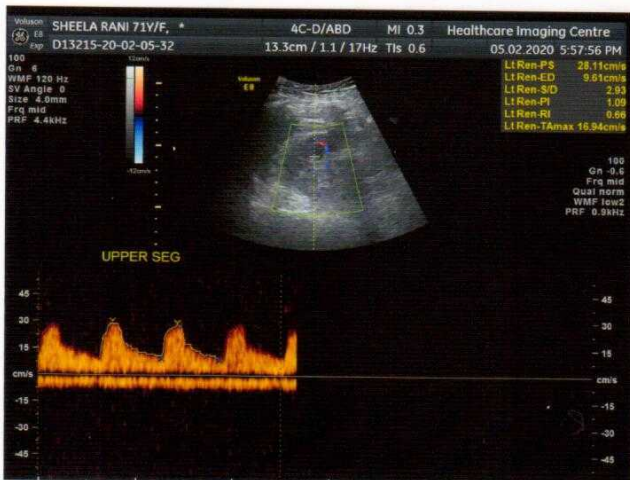
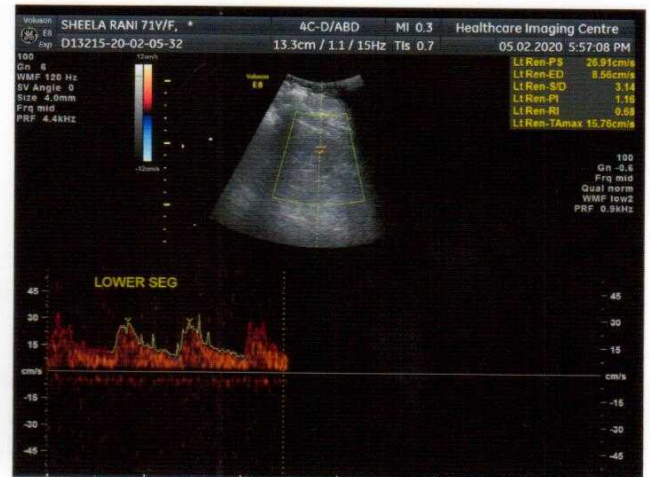
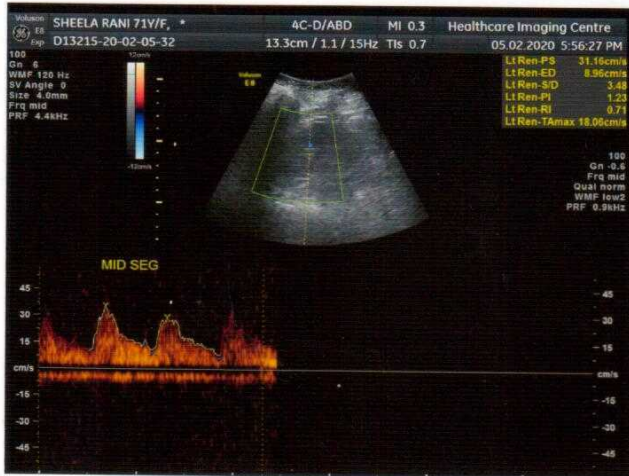
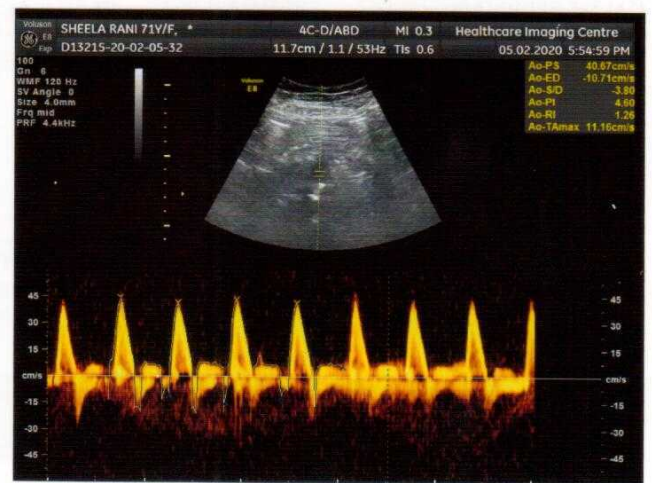
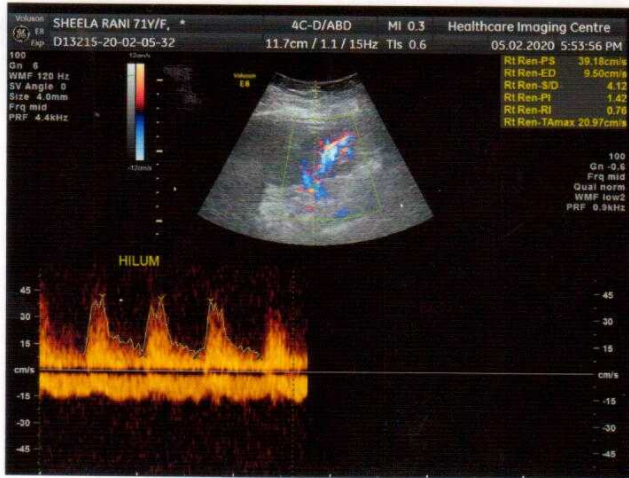
Dr. Ankur Aggarwal  
MD

Dr. Shalabh Bansal  
DMRD, FRCR (UK)

Please correlate clinically

Note: Impression is a Professional opinion & not a Diagnosis. All Modern Machines/Procedures have their limitations. If there is variance clinically this examination may be repeated or reevaluated by other investigations. Typing errors sometimes are inevitable. Not for medico-legal purposes. Patient's identity cannot be verified.







# DR. SATYARTH CHAUDHARY

M.D.(MEDICINE), D.M. (GASTROENTEROLOGY)  
EUS FELLOWSHIP (C.M.U. , SHENYANG)  
ESD POEM FELLOWSHIP (FUDAN UNIVERSITY, SHANGHAI)

## ENDOSCOPY

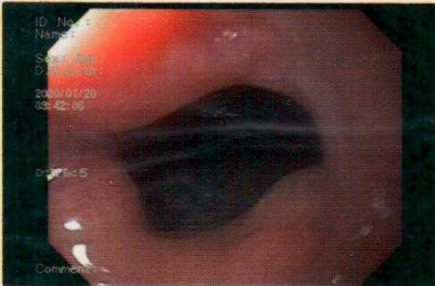Patient Name : SHEELA RANI

Age/Gender : 72/Female

Date : 20/Jan/20

Referred By : SELF

Unit No :



**MEDICATIONS : Topical xylocaine Viscous ( 2%).**

**PROCEDURE : Esophago-Gastro-Duodenoscopy**

**Esophagus : Large hiatus hernia, GE junction at 31 cm from incisors**

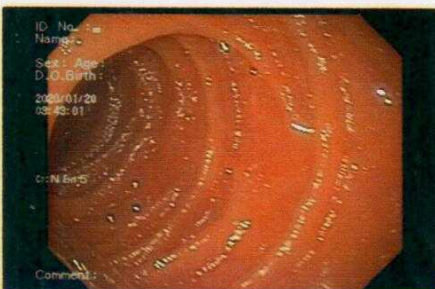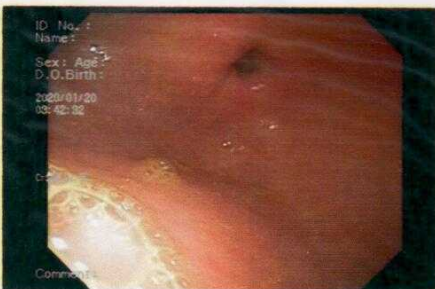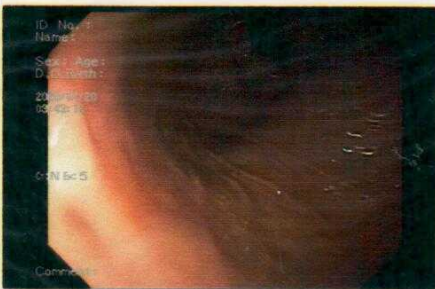**STOMACH : Normal**

**DUODENUM :**

**1st Part : Normal.**

**2nd Part : Normal.**

**IMPRESSION : LARGE HIATUS HERNIA**



**DR SATYARTH CHAUDHARY**  
M.D(Medicine),D.M(Gastroenterology)





A unit of Shri Devshri Medicare Hospital Pvt. Ltd.

# SDS GLOBAL

## Super Speciality Hospital

.... excellence In Medicare !

### HEART & TRAUMA CENTRE

#### PATHOLOGY REPORT

Net Amount :- 250 Rec No. :- 2001IR-001


Patient Name	: Sheela Rani	Lab Accession No	: 200119010579
Mobile No	: 8750331133	Alt Ref No	:
Age	: 72 Yr	Date # SNo	: 19-01-2020 # 19
Referred by	: DR.SATYARTH CHAUDHARY DM ( GASTRO )	Sample Booking Time	: 19/01/2020 10:25:51 PM
REG No	: 26854	Sample Receiving Time	:
Category	: General		

Investigation	Value	Units	Biological Ref. Interval
<b>COMPLETE BLOOD COUNTS</b>			
HAEMOGLOBIN (HB)	: 9.2 L	gm/dl	13.0 - 17.0
TOTAL LEUCOCYTE COUNT (TLC)	: 9500	/cmm	4000 - 10000
<b>DIFFERENTIAL LEUCOCYTE COUNT</b>			
NEUTROPHIL	: 80	%	40 - 80
LYMPHOCYTE	: 14 L	%	20 - 40
EOSINOPHIL	: 03	%	1 - 6
MONOCYTE	: 03	%	2 - 10
BASOPHIL	: 00	%	0 - 2
DLC TOTAL	: **		
R B C (Red Blood Cells)	: 3.61 L	Millions/cmm	4.50 - 5.50
PLATELET COUNT	: 2.00	Lakh/cmm	1.50 - 4.5
P.C.V / HAEMATOCRIT	: 29.5 L	%	40 - 50
M C V	: 81.7	cubic micron	78 - 92
M C H	: 25.5 L	picogram	27 - 32.0
M C H C	: 31.2 L	%	31.5 - 34.5
RDW	: 20.0 H	%	10.0 - 15.0

\*\*End of Report\*\*

DR. ANJALI JAIN  
MBBS,DCP

DR. MEDHA JAIN  
MBBS,MD

Checked by : 

" All Pathological Tests have Limitations,These are professional opinion, to be correlated clinically.Incase of unexcepted result or printing error patient is advised to contact lab for recheck witnin 24 hours.Not for medico legal purpose ,patient identity is not conformed."

# Care

24 Hrs  ब्लड बैंक / पैथोलॉजी TPA - ECHS / BSNL

120/122, NH-58, Near Melange Mall, Modipuram, Opp. Agriculture University,  
Meerut (U.P.) - 250 110 | Tel : 70 5500 4223/24/25/27

E: care@sdsglobalhospital.com | Web : sdsglobalhospital.com





A unit of Shri Devshri Medicare Hospital Pvt. Ltd.

# SDS GLOBAL

## Super Speciality Hospital

.... excellence In Medicare !

### HEART & TRAUMA CENTRE

#### PATHOLOGY REPORT

Net Amount :- **1270** Rec No. :- 2001IR-001

Patient Name : **Ms. Sheela Rani**  
Mobile No : **8750331133**  
Age : **72 Yr**  
Referred by : **DR.SATYARTH CHAUDHARY DM ( GASTRO )**  
REG No : **26854**  
Category : **General**

Lab Accession No : **200119010580**  
Alt Ref No :  
Date # SNo : **19-01-2020 # 20**  
Sample Booking Time : **19/01/2020 10:50:48 PM**  
Sample Receiving Time :

Investigation	Value	Units	Biological Ref. Interval
<b>COAGULATION PROFILE</b>			
PLATELET COUNT	: 2.00	Lakh/cmm	1.50 - 4.5
BLEEDING TIME	: 02 MIN 48 SEC		1 - 6
CLOTTING TIME	: 04 MIN 50 SEC		3-8 MIN
<b>PROTHROMBIN TIME</b>			
PT PATIENT	: 13:40	SEC	
PT CONTROL	: 12:50	SEC	
INDEX	: 1.1	Derived Index	
ISI value of reagent	: 1.0		
INR (International Normalized Ratio)	: 1.1		
<b>INTERPRETATION</b>			
ACTIVATED PARTIAL THROMBOPLASTIN TIME (APTT)	: 33:10	SEC	29 - 40
APTT CONTROL	: 32:50	SEC	
<b>BLOOD UREA</b>			
	: <b>48 H</b>	mg /dl	13 - 45
<b>SERUM CREATININE</b>			
	: 1.0	mg /dl	0.6 - 1.4
<b>SODIUM</b>			
	: 138	mmol/L	135.0 - 145.0
<b>POTASSIUM</b>			
	: <b>3.0 L</b>	mmol/L	3.40 - 5.50
REFERENCE RANGE: PREMATURE INFANTS: 4.5 - 7.2 FULL TERM INFANTS: 3.7 - 5.7 mmol/L CHILDREN: 3.5 - 5.8 ADULTS: 3.4 - 5.5			
CHLORIDE	: 104	mmol/L	94.0 - 110.0

\*\*End of Report\*\*

DR. ANJALI JAIN  
MBBS, DCP

DR. MEDHA JAIN  
MBBS, MD

Checked by

24 Hrs **ब्लड बैंक / पैथोलॉजी** TPA - ECHS / BSNL

120/122, NH-58, Near Melange Mall, Modipuram, Opp. Agriculture University,  
Meerut (U.P.) - 250 110 | Tel : 70 5500 4223/24/25/27

E: care@sdsglobalhospital.com | Web : sdsglobalhospital.com

Continue...1



PATHOLOGY REPORT

Name	Sheela	Date	19/01/20
Age	72/M		
DR NAME	Dr S. Chavla	APTT-T	33:10
		C-	32:50
HB	9.2	BILL (T)	
TLC	9,500	(D)	
RBC	3.61	(I)	
PC	2.0	T.PROTEIN	
PCV	29.5	ALB	
MCV	81.7	ALP	
MCH	25.5	SGPT	
MCHC	31.2	SGOT	
RDW	20.0	LDH	
		PT T	13:40
UREA	48	C	12:50
CREATININE	1.0		
URIC ACID		T.CHOLESTROL	
CALICUM		TRIGLYSRIDE	
NA+	138	HDL	
K+	3.0	LDL	
CL	104	VLDL	
SUGAR F		S. AMYLASE	
PP		S.LIPASE	
R			
		MP Antigen	
CPK-MB		Typhi Dot IgM	
TROPONIN I		IgG	
PCT			
HIV		Bleeding Time	02min 48sec
HCV		Clotting Time	04min 50sec
HBsAg		D-Dimar	—

19/1/2020

DISCHARGE SUMMARY  
(DOPR)

Mrs. Sheela Rani; 72 yrs female was admitted in chest emergency on 17/1/2020 with c/o haematemesis & melena & throat irritation. ∴ Idly. Pt is K1C10, Pott's Spine (on ATT 1. Aug 2019), HTN, & post CABG.

Pt was investigated and managed with IV Antibiotics, O<sub>2</sub> Supplemental & other supportive care (reports attached).

- In view of low Hb (7 gm%) patient received 2 OPRBC transfusions and her Hb at the time of discharge was 9 gm%

- In view of GI bleed, patient attendant wanted to get discharged for further management at a known gastro centre.

Diagnosis: GI Bleed (under evaluation)

Pott's Spine (L5-S1) (on ATT 1. Aug 2019)

CAD - post CABG

HTN

Hypothyroidism

- Rx:
1. Duj. Merocin 1g / 2x / 10s
  2. Duj. Levoclozap 100mg / 1x / 10s
  3. Duj. Tranexa 500mg / 2x / 10s
  4. Duj. PAN infusion 8mg / hr
  5. Tab. Etroxin 125mg (BBF)
  6. 1. Amlodipine 5mg / B.D
  7. 1. Atenolol 50mg / B.D.

Vitals @ of discharge:

B.P: 150/90 mm Hg

PR: 96 / min

SpO<sub>2</sub>: 95% Room air



**Cardiology Wing**

X-1, Sector-12, Noida - 201301

Tel. : +91 120 2533 491, 2444 466, 4366 666

Fax : +91 120 2533 487

**Multispeciality Wing**

L-94, Sector 11, Noida-201301

Tel. : +91 120 2522 959, 2442 666

Fax : +91 120 2442 555

E-mail : metro@metrohospitals.com, Website: www.metrohospitals.com

Regd. Office : 14, Ring Road, Lajpat Nagar IV, New Delhi-110024

MHHI/CL/0115/Rev. No. 01





# SDS GLOBAL SUPER SPECIALITY HOSPITAL

120/122, NH-58, Modipuram, Opp. Agriculture University, Meerut (U.P.)

Ph. No. +91 7055004225, +91 70550042277

Web: sdsglobalhospital.com

## DISCHARGE SUMMARY

Patient Name: <u>Ms SHEELA RANI</u>	Consultant Doctor: <u>D. SATYARTH CHAUDHARY</u>
Age/Gender: <u>72/F</u>	IPD No: <u>23112/20</u>
Address: <u>B-8 Adm Compound</u>	D.O.A & Time: <u>19/01/2020 at 9:21pm.</u>
<u>City - (Meerut)</u>	D.O.D & Time: <u>20/01/2020 at 1pm.</u>
Room No: <u>116</u>	MLC No: .....

### 1. Diagnosis:

LARGE HIATUS HERNIA

### 2. Significant Findings:

### 3. Investigations Result:

### 4. Treatment Given / Procedure Performed:

UGI Endoscopy: Large Hiatus Hernia.



5. Condition at the time of Discharge

6. Advice/Treatment on Discharge:

Rx.

- Tab. Razo-L

1 30 min before breakfast

- Cap. Pantocid - IT for 5 days


- Symp. Sucrotas-0.15ml 30 min before dinner.

Small frequent meals.

7. When to Contact Hospital for Urgent Care:

Consult Dr. Raveer Agarwala for  
Accelerated hypertension

8. How to Take Urgent Care:



\_\_\_\_\_  
Name & Sign of Consultant

\_\_\_\_\_  
Name & Sign of RMO





# Health Care Imaging Centre

43, Shivaji Road, Near N.A.S. College, (Opp. Shankar Ashram) Meerut. (U.P.)  
Ph: 0121-2652434, 2650506

Helpline : 9760011538

- 3 Tesla Platform MRI (HD)
- Multi-Slice Cardiac C.T.
- 3D & 4D Ultrasound
- Digital O.P.G.
- Digital X-Rays
- DEXA Scan (BMD)
- Digital Mammography

HCIC No. :	012007002477	Reg. Date :	22 Jul 2020
Patient Name :	Mrs. SHEELA RANI	Report Date :	23 Jul 2020
Age/Sex :	72 YRS/FEMALE	Referred By :	Dr. Amit Aggarwal M.D.(Chest)

## MRI LUMBO-SACRAL SPINE

### PROCEDURE

Using the High Definition coil, High Resolution images of the L.S. spine acquired using twin gradient 16 channel 3.0 Tesla platform system with zoom gradient coil in T2, T1W Sagittal & STIR Coronal, followed by transaxial T1 and T2 at the I/V disk levels.

### FINDINGS:

There is kyphoscoliosis of lumbar spine noted with concavity towards right.

Fluid collection noted in the L5-S1 intervertebral disc without apposing end plate erosion and subtle resolving marrow edematous signals. No pre and paravertebral phlegmonous soft tissue is noted. As compared to previous MRI dated 28<sup>th</sup> April 2020, no change is seen suggestive of Residual changes of previous Infective Etiology.

Rest of the findings remains unchanged.

Dr. Sanjay Gupta,  
MD (Radio-Diagnosis)  
Mobile No. 9412201491

Dr. Shalabh Bansal,  
DMRD, FRCR (U.K.)  
Mobile No. 9997999516

Please correlate clinically

Note: Impression is a Professional opinion & not a Diagnosis. All Modern Machines/Procedures have their limitations. If there is variance clinically this examination may be repeated or reevaluated by other investigations. Typing errors sometimes are inevitable. Not for medico-legal purposes. Patient's identity cannot be verified.

Result Entered By : RUCHI





# AGARWAL CHEST & DENTAL CARE CENTER



## Dr. Amit Agarwal

MD (Chest & TB), FCCS  
MNCCP, MICS, MISCCM, MIAB, MAPI  
Consultant Chest Physician & Bronchoscopist  
Critical Care Specialist

## Dr. Ruchi Agarwal

BDS, FAGE, MIDA  
Consultant Dental Surgeon  
Cosmetic Dentist & Implantologist

Date - 21/07/20

BP -

Pulse - 100/min

Temp. -

SpO<sub>2</sub> - 98.1

Weight -

PEFR -

Cl. Breathlessness

Ons Psk low dose corticosteroids

Mr. Sheela Rani 72y/f

Tab Demiphy 300

Tab Luminol 600

Tab Dytar 10mg

x 7 day

Valid Till .....

21/07/20

ddr  
Digital chest xray review

HRCT chest

Cap Camyda 300mg

Tab Amuvonae

Tab Dytar 10mg

Cap Becelae forte

x 7 day

20/07/20

Next Visit -

### TIMING:

Morning 11:00 am to 3:00 pm

Evening 7:00 pm to 8:00 pm

Tuesday 4:00 pm to 8:00 pm

Saturday Closed

Mobile No. : +91-8791231009  
+91-8057875658

WhatsApp : +91-8057875658

E-mail : acdcc2017@gmail.com

Clinic : New Market, Begum Bridge, Meerut

Emergency No. 9760009626 (Dr. Amit Agarwal)

Member : National College of Chest Physician, New Delhi, Indian Chest Society, Varanasi, Indian Society of Critical Care Medicine, Mumbai, Indian Asso. for Bronchology, Mumbai, The Asso. of Physicians of India, Mumbai, Indian Medical Asso., Meerut Branch

Not for Medicolegal Purpose





**Dr. Amit Bindal**  
 M.S., M.Ch.  
 Brain & Spine Surgeon

**Specially trained in**  
 Microscopic & Endoscopic Brain & Spine Surgery  
 U.P. Medical Council Reg. No. : 4005



7/8/2020

— Sheela Rani Ji



— 1st/2, Pott's Spine new




Cap. Preega M 7.5 Hl.

Tas. Taphree 30 1/2

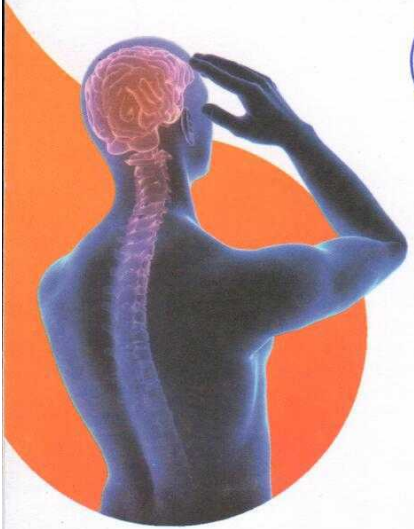


15 clu



— Dr. Pansau Jakkola  
 1st 2nd line ATT.

→ wait for 3 months after  
 2nd line Drugs.



आप प्रधानमंत्री जन औषधि  
 केन्द्र से दवा लेने के लिए  
 स्वतंत्र है।  
 न्यू मार्केट देवम ब्रिज, मेरठ

Dev Shri Plaza, Opp. State Bank, Baghat Road,  
 Near Transport Nagar Police Station, Meerut City.  
 For appointment : 8958004590 (Dev Shri Plaza)

Citi Center, Near Baccha Park,  
 Begum Bridge Road, Meerut City.  
 9756101557 (Citi Center)

11:00 AM to 1:00 PM **SUNDAY CLOSED**

2:00 PM to 4:00 PM **SUNDAY CLOSED**

\*Single consultation fees valid for only 5 days.

www.BindalClinics.com | info@BindalClinics.com /bindalclinicsmeerut /Bindal Clinics



14/8/20 EVC Large Thromb  
Hernia  
IHD LVD 40-45%  
EF

40 Dysphagia  
more to liquids

belching

Backache

Itching

Numbness feet

170/100

wt 73 kg  
SPO<sub>2</sub> 95%

On ATY X 14

for L5-S1 Discs Spine  
Mild worse

Bas Swallow

Skin Sp. Ointment ✓

MCV 65

ESR 24

Hb 8.9

July

ALC 6.1

~~BIG TUG TEST~~

Ser Creat 0.7

- CBC ESD

TSH 7.60

NT PROBNP

Urine Routine ACD

Hb 8.3

Vit D 9.9

7400 P67

MCV 62

RBC 4.2

ALC 6.4

CRP +

ACR 30

transferrin sat 7%

Ser ALB 3.2  
Glu 2.5

Cr 0.7

Na 126

11/9/20

Same th

+  
1/2 IRON  
therapy

- Cap ORISE 60K  
1/week

X 1 month

Adh

- Ser Iron studies ↓

- stool routine OCBT Negative

- Ser Ferritin ↓

- CRP ↑

- NT PROBNP (N)

- Urine routine ACD

अपॉइन्टमेंट लेकर ही आयें।

Emergency & Admission Facility not Available

रविवार अवकाश (Sunday Closed)

Omnibus™  
DENTAL CARE

Omnibus™  
Institute of Clinical Excellence

Omnibus™  
EYE CARE

vaikarya  
THE MEDISPA

📍 1, Ansal Town, Near Bikanerwala Sweets Meerut Bypass, Meerut.

📞 For Appointment : 0121-2577426, 2576700, 7060330127, 8755614477

🚫 Ⓜ️ हॉस्पिटल में मरीजों को भर्ती करने की सुविधा उपलब्ध नहीं है।





# JASWANT RAI SPECIALITY HOSPITAL

Opp. Sports Stadium, Mawana Road, Meerut-250001

Ph. +91121-2663887, 2663888, 2651700

E-mail: jrs\_mrt@yahoo.com

## ECHOCARDIOGRAM REPORT

NAME: MRS. SHEELA RANI

AGE/SEX: 74Y/FEMALE

Referring Diagnosis : CAD/POST CABG (2013)

DATE: 04/09/2021

Referred By : DR. VEEROTTAM TOMER MD

Echogenicity : GOOD

DIMENSIONS	MEASURING	NORMAL/M2
AO	26 mm	(12 - 22)
LA	34 mm	(12 - 22)
LVID (Diast)	44 mm	(24 - 32)
LVID (Systo)	27 mm	(14 - 26)
IVS (Diast)	12 mm	(6 -- 12 mm)
IVS (Systo)	15 mm	(6 -- 30 mm)
LVPW (Diast)	12 mm	(8 -- 13 mm)
LVPW (Systo)	20 mm	(8 -- 30 mm)
LVEF	55%	(50 - 75 %)
LVFS	28%	(25 -- 45 %)

### MORPHOLOGICAL DATA

MITRAL VALVE	: MAC	INTERATRIAL SEPTUM	: INTACT
AORTIC VALVE	: CALCIFICATION	INTERVENTRICULAR SEPTUM	: INTACT
TRICUSPID VALVE	: NORMAL	PULMONARY ARTERY	: NORMAL
PULMONARY VALVE	: NORMAL	AORTA	: NORMAL
RIGHT VENTRICLE	: NORMAL	RIGHT ATRIUM	: NORMAL
LEFT VENTRICLE	: NORMAL	LEFT ATRIUM	: NORMAL





**JASWANT RAI SPECIALITY HOSPITAL**  
**Pathology & Blood Bank**

Opp. Sports Stadium,  
Civil Lines, Meerut

Path. Lab. - 0121-2644577  
Blood Bank - 0121-2644677  
Hospital - 0121-2663887, 2663888  
E-mail: jrsh.path.bb@gmail.com




Name:	<b>Mrs. SHEELA RANI</b>	Registration No.:	139090
Age/Gender:	74 Y/Female	Registered:	06/Sep/2021 03:40PM
Patient ID:	012109060097	Sample Collection:	06/Sep/2021 04:12PM
BarcodeNo:	10123169	Reported:	06/Sep/2021 04:26PM
Referred By:	Dr. VIROTAM TOMAR	Report Status:	Final
Collection Place:	OPD	UHID:	

Test Name	Result	HAEMATOLOGY		
		Unit	Biological Ref.Interval	Method
<b>COMPLETE BLOOD COUNT</b>				
HEMOGLOBIN	9.6	g/dl	12.0 - 15.0	
PCV	30.2	%	36-46	Electronic Impedance
TOTAL LEUCOCYTE COUNT	12,900	/cu.mm	4000 - 10000	Calculated
<b>DIFFERENTIAL LEUCOCYTE COUNT</b>				
NEUTROPHILS	74	%	40 - 80	Light Scattering
LYMPHOCYTES	18	%	20 - 40	Microscope
EOSINOPHILS	1	%	1 - 6	Microscope
MONOCYTES	7	%	2 - 10	Microscope
BASOPHILS	0	%	0 - 2	Microscope
BLAST CELLS	0.0	%		Microscope
IMMATURE CELLS	0.0	%		
RBC	3.9	Million/cu.mm	3.8 - 4.8	
MCV	76.8	fl	83 - 101	Electrical Impedance
MCH	24.4	pg	27 - 32	Electrical Impedance
MCHC	31.8	gm/dl	31 - 35	Calculated
PLATELET COUNT	3.65	Lac/cu.mm	1.5 - 4.10	Calculated
MPV	10.30	FL	7 - 10.5	Electrical/Microscope
PDW	11.10	FL	9.3 - 16	Electrical Impedance
RDW-SD	41.70	FL	40-55	Electrical Impedance
RDW-CV	14.90	%	11-15	Electrical Impedance
				CALCULATED

ISO 9001: 2008  
Wish you A Speedy Recovery

Dr. Priyanka Yadav  
M.D. (Path)

Dr. Shagun Aggarwal  
M.D (Micro)

  
Dr. Jyoti Singh  
M.D. (Path)

Dr. Shivangi Singhal  
M.D. (Path)

- ❖ Test Values may vary with different lab standards, methods, kits used and other physiological & biological factors.
- ❖ The clinico pathological lab tests involve Man-Machine-Computer interface with slight chances of inadvertent discrepancy and should be immediately discussed & alleviated.
- ❖ Report purports for patients care and not for medicalegal documents.





**JASWANT RAI SPECIALITY HOSPITAL**  
**Pathology & Blood Bank**

Opp. Sports Stadium,  
Civil Lines, Meerut

Path. Lab. - 0121-2644577  
Blood Bank - 0121-2644677  
Hospital - 0121-2663887, 2663888  
E-mail: jrsh.path.bb@gmail.com



Name:	Mrs. SHEELA RANI	Registration No.:	139090
Age/Gender:	74 Y/Female	Registered:	06/Sep/2021 03:40PM
Patient ID:	012109060097	Sample Collection:	06/Sep/2021 04:12PM
BarcodeNo:	10123169	Reported:	06/Sep/2021 04:36PM
Referred By:	Dr. VIROTAM TOMAR	Report Status:	Final
Collection Place:	OPD	UHID:	

Test Name	Result	Unit	Biological Ref.Interval	Method
PROCALCITONIN	0.39	ng/ml	0-0.1	ECLIA

Serum procalcitonin (PCT) levels is an early indicator of bacterial infection.  
PCT levels rise rapidly (within 6-12 hours) after bacterials infection with systemic consequences.  
PCT can also raise independently after multiple trauma, major surgery, severe burns or in neonates.  
PCT levels > 2ng/ml may reflect severe sepsis.

**REFERENCE RANGE:-**


< 0.05ng/mL	Healthy
0.05-0.5	Local Infection
0.5-2.0	Systemic Infection are sepsis
2-10	Severe Sepsis
>10.0	Septic Shock

KINDLY CORRELATE CLINICALLY.

\*\*\* End Of Report \*\*\*

Dr. Priyanka Yadav  
M.D. (Path)

Dr. Shagun Aggarwal  
M.D (Micro)

  
Dr. Jyoti Singh  
M.D. (Path)

Dr. Shivangi Singhal  
M.D. (Path)

- ❖ Test Values may vary with different lab standards, methods, kits used and other physiological & biological factors.
- ❖ The clinico pathological lab tests involve Man-Machine-Computer interface with slight chances of inadvertent discrepancy and should be immediately discussed & alleviated.
- ❖ Report purports for patients care and not for medicalegal documents.



OMN-01055 : MRS.SHEELA RANI (72y, Female) - 8750331133

Date: 09-Nov-2020

BP 180 / 107<sup>\*</sup> mmHg Pulse 108 bpm Weight 72 kg Temperature 96.4 F SPO2 96 %

Diagnosis:

- ISCHAEMIC HEART DISEASE
- HIATUS HERNIA WITH GERD
- POTTS SPINE since 15 months
- FUNCTIONAL BELCHING
- HYPERTENSION
- HYPOTHYROIDISM
- IRON DEFICIENCY ANAEMIA

— ON ATT X 15 months

22/11/20

STOP ATT ✓

Rx

Medicine	Dosage	Timing - Freq. - Duration
3) DOMSTAL TABLET <i>Composition: DOMPERIDONE 5 MG</i> <i>Timing : 1 - नाश्ते से पहले, 1 - रात - खाने से पहले</i>	1 — 0 — 1	नाश्ते से पहले - रोज - 15 दिन
4) NEXPRO 40MG TABLET <i>Composition: ESOMEPRAZOLE 40 MG</i> <i>Timing : 1 - नाश्ते से पहले</i>	1 — 0 — 0	नाश्ते से पहले - हर दूसरे दिन - 15 दिन
150 mcg 3) THYRONORM 137.5MCG TABLET <i>Composition: LEVOTHYROXINE 137 MCG</i> <i>Timing : 1 - नाश्ते से पहले</i>	1 — 0 — 0	नाश्ते से पहले - रोज - 15 दिन <i>150mcg ✓</i>
1) MOXOVAS 0.3MG TABLET <i>Composition: MOXONIDINE 0.3 MG</i> <i>Timing : 1 - रात - खाने के बाद</i>	0 — 0 — 1	रात - खाने के बाद - रोज - 15 दिन
3) OLMETIME H 20MG TABLET <i>Composition: HYDROCHLOROTHIAZIDE 12.5 MG + OLMESARTAN 20 MG</i> <i>Timing : 1 - नाश्ते के बाद</i>	1 — 0 — 0	नाश्ते के बाद - रोज - 15 दिन
6) SOLOPOISE TAB <i>0.25 mg</i> <i>Timing : 1 - नाश्ते के बाद, 1 - रात - खाने के बाद</i>	1 — 0 — 1	खाने के बाद - रोज - 15 दिन

निर्धारित परीक्षण : MRI L S SPINE, C B C E S R, SERUM CREATININE, L F T, SERUM CALCIUM, T S H

अगली तारीख : 24-Nov-2020 - Tuesday Hb 9.1 0.7 Alb 3.3 8.9 7.23

Baswallow 2 ESR 23

LS-SI  
recheck

Dr. S P SONDHI

2 packet (A) Cap Dilisegek 1/week & 2 month

1 "अपॉइन्टमेन्ट लेकर ही आये। (B) Low ALDACTONE 25 1

Emergency & Admission Facility not Available

रविवार अवकाश (Sunday Closed)

Omnibus<sup>TM</sup>  
DENTAL CARE

Omnibus<sup>TM</sup>  
Institute of Clinical Excellence

Omnibus<sup>TM</sup>  
EYE CARE

Powered by HealthPlus EHR  
www.healthplus.com

1, Ansal Town, Near Bikanerwala Sweets Meerut Bypass, Meerut.

For Appointment : 0121-2577123, 2578769, 7060330127, 8755614477

मरीजों को भर्ती करने की सुविधा उपलब्ध नहीं है।





# JASWANT RAI SPECIALITY HOSPITAL

Opp. Sports Stadium, Mawana Road, Meerut

Ph. +91121-2663887, 2663888, 2651700

E-mail: jrsh\_mrt@yahoo.com



Date 20/11/2022

RUN BY: MEERUT MEDICARE CENTRE PVT. LTD.)

CIN: U85110UP1995PTC019162

7:15 AM

Pt Name. Smt Sheela. Rani Age 72 years F

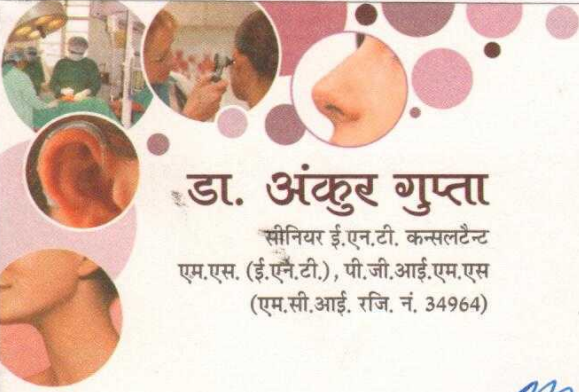Δ Anemia

Adv

39 ferinject 1 vial song Idaw 1m  
2 100ml MSIV Start Slow

*[Signature]*





# डा. अंकुर गुप्ता

सीनियर ई.एन.टी. कन्सल्टंट  
 एम.एस. (ई.एन.टी.), पी.जी.आई.एम.एस  
 (एम.सी.आई. रजि. नं. 34964)

# Dr. Ankur Gupta

SR. E.N.T. CONSULTANT  
 M.S. (E.N.T.), P.G.I.M.S.  
 VOICE, SINUS, EAR, ENDOSCOPY  
 & MICROSCOPIC SPECIALIST  
 (MCI Reg. No. 34964)

*Mrs. Anurag...*  
 (NO)

*Mrs. Shula Agarwal*  
 7/10/20

4103 CABG  
 TKR

*कलकत्ता*  
*(Amrohtala)*

*C. dysentery*

*M. M. 78/100*  
*दमप्रेसर*

- ① *Lab. Parvix 100*
- ② *Lab. Calcium 100*
- ③ *Lab. Iron 200*
- ④ *Lab. Both 200*

*B/L V-C mobile*

Timings :  
 Monday to Friday  
 10 am to 2.00 pm  
 Sunday Closed

Ph. 0121-4032247, 9997811114  
 9058307860, 7417839928  
 E-mail : ankurgupta1967@gmail.com

For any Query Dial : 9368827037

रविवार अवकाश  
 EMERGENCY 24 HOURS  
 NOT FOR MEDICO LEGAL USE

Formerly at :  
 Post Graduate Institute of Medical Sciences, RTK, Seth G. S. Medical College & KEM Hospital, Mumbai, Tata Memorial Hospital, Mumbai  
 Life Member : IMA, AOI, Indian Society of Otolaryngology, Sinus Endoscopy Society of India, Neuro Otolaryngologist & Equilibriometric Society of India  
 Association of Phonosurgeons of India

निदेशक : लवीना ई.एन.टी. केयर सेंटर, बच्चा पार्क, मेरठ। डा० एम.के.गुप्ता चैरिटेबिल क्लीनिक, खैर नगर, मेरठ। फोन : 0121-2527119



**डा० आलोक कुमार गुप्ता**

एम०डी०, डी०एम० (न्यूरोलोजी)

**न्यूरोलोजिस्ट**

मस्तिष्क नाड़ी एवं मिर्गी रोग विशेषज्ञ  
भूतपूर्व विभागाध्यक्ष न्यूरोलोजी विभाग  
कामिनेनि अस्पताल, हैदाराबाद  
U.P.M.C.I. Reg. - 31553  
CMO Reg. - 1205

सुबह 8:30 बजे से 11:00 बजे तक  
फीस जमा करके ही नम्बर लगेगा।

क्लीनिक : 5, मैडीसेन्टर, हापुड़ रोड  
ईव्ज पैट्रोल पम्प के सामने, मेरठ।

क्लीनिक : 9012451575

☎ : 9690574012

**परामर्श समय :**

सुबह 09.00 बजे से दोपहर 2.00 बजे तक  
सायं 3.00 बजे से सायं 5.00 बजे तक

**रविवार अवकाश**

Mrs. Shreela Rami

दिनांक 24/7/2020

Rx

MRI L.S. Spine

with

Screening of Cervical

2

T-MRI-P

1

✓

फोन पर नम्बर लिखवाने की सुविधा उपलब्ध नहीं है।

हमारे यहाँ इमरजेन्सी सुविधा उपलब्ध नहीं है।

नोट : यह पर्चा केवल 3 दिन के लिए मान्य है।

क्लीनिक बन्द रहेगी - ता० ..... से ..... तक



# किरण मैमोरियल रि-कन केयर क्लीनिक

195 पुलिस स्ट्रीट, (टैक्सी स्टैण्ड के पास) सदर, मेरठ

**Dr. Anurag Mathur**  
M.B.B.S., D.V.D.

Smt. Sheela Rani

24 OCT 2020

72425

XD

R

Tab Atarax (25) Tab 100 2tm.

Venusiamax ene

+

(2:1)

Topinate ene

Ac 10 =

2:1 10tm

Dersil moisturizing lotion..

X 3wks

Amoeg

नम्बर लिखाने के लिए  
9520784744 पर कॉल करें

परामर्श समय : प्रातः 9.30 से 12.30 बजे तक  
प्रत्येक दिन दोपहर 3.30 से 7.00 बजे तक

रविवार पूर्ण अवकाश