

# PAEC-4101



## अ० भा० आ० सं० अस्पताल / A.I.I.M.S. HOSPITAL

### विभिन्न श्रेणी विभाग / Out Patient Department

General Consultation Time: 9.00 AM-1.00 PM



DeptSeq: 306

SPITAL PREMISES

PO 103946349

Dept: Endocrinology

OPR-6

Clinic No: PAEC- Clinic No.2018/PAEC/4101

Unit: Unit-I

Name: AVKIRAL RAI

Room: 1 Endo

S/O AK RAI, 16Y 7D, M

N/19

Ph: 9868940983

Days:

OMEGA GREATER NOIDA, UTTAR PRADESH, Pin:0, INDIA

App. Date: 27/08/2018

/O.P.D. Regn. No. \_\_\_\_\_

एकक/Unit \_\_\_\_\_

विभाग/Dept. \_\_\_\_\_

नाम/Name \_\_\_\_\_

पता/Address \_\_\_\_\_

Appt. ID:



2018082713239

निदान/Diagnosis

Pediatric & Adolescent Endocrinology Clinic (PAEC)  
Department of Endocrinology & Metabolism, AIIMS  
Every Monday, 2 to 4 pm, 2nd Floor, Main OPD Block

दिनांक/Date

उपचार/Treatment

Ht - 149.2 cm

wt - 37.2 kg

mht - 164.6 cm

fht - 169.6 cm

MPH - 173.6

HT SDS - 2.6

Wakeup - (4)

Subclinical Hypothyroid

Significant Short stature

Short for MAH

Multiple dysmorphic features  
operated for cleft palate

Bone age 13<sup>6</sup>/<sub>12</sub> yrs Chronage 15<sup>6</sup>/<sub>12</sub>

? Araskog Syndrome

HT prognosis explained

Plan:

- Dental Problem - Dr Vijay Malhotra  
Dental OPD, CDER
- Voice problem - ENT consultation

CLEAN AND GREEN AIIMS / एम्स का यही संकल्प, स्वच्छता से काया कल्प

अंगदान-जीवन का बहुमूल्य उपहार / ORGAN DONATION - A GIFT OF LIFE

O.R.B.O., AIIMS, 26588360, 26593444, www.orbo.org Helpline - 1060 (24 hrs service)

Dr Praveen Sharma faculty cell



अ० भा० आ० सं० अस्पताल / A.I.I.M.S. HOSPITAL  
बहिरंग रोगी विभाग / Out Patient Department

4

अस्पताल के अन्दर धूम्रपान मना है। / SMOKING IS PROHIBITED IN HOSPITAL PREMISES

शरीरमापन सन्तु सर्वसाधनम्

New Patient

Dept. Reg. 2018/025/0008282

General / 10

OPR-6

एकक / Unit

Endocrinology / Unit-I

कक्ष/Room: 1 Endo

विभाग / Dept.

Name: AVKIRAL RAI

Days: Mon, Fri

नाम / Name

नाम: अवकिराल राय

S/O Av RAI


16Y पुत्र/son

पं. No.

पिता: अव र

Ph. 9868940983

पता / Address



UHQ: 103946349

Date: 20/08/2018

निदान / Diagnosis

? Short stature.

दिनांक / Date

उपचार / Treatment

Ht = 151 cm  
wt = 38 kg.

C/S/B h-4-4upta

P wt 169.0 gm / 75%  
M wt 781. Kg.  
- 164.0 gm

RAV

R / A in r/hydr

Thick

Plz provide file.

27/8

For. opinion. of Sir.  
and registration  
in PAEC Clinic

22/8/18

Please Register in  
PAEC 2.00 PM OPD

Handwritten signature

DR. RAJESH KHADGAWAT

CLEAN AND GREEN AIIMS / एम्स का यही संकल्प, स्वच्छता से काया कल्प

अंगदान-जीवन का बहुमूल्य उपहार / ORGAN DONATION - A GIFT OF LIFE

O.R.B.O., AIIMS, 26588360, 26593444, www.orbo.org Helpline - 1060 (24 hrs service)



Rx

high protein diet

↑↑ calcium intake

Toylash Sakut - one month

---

F/U 3 months



DR. RAJESH KHADGAWAT

Professor

Dept. of Endocrinology & Metabolism  
AIIMS, New Delhi-110029

11/1

1001



आत्मना सर्वो जित

# OUT PATIENT RECORD

DEPARTMENT OF MEDICAL GENETICS  
SANJAY GANDHI POSTGRADUATE INSTITUTE  
OF MEDICAL SCIENCES, LUCKNOW- 226014

: 2494076 (OPD)  
Tel. : 2494325 (Office)  
: 2494380/2494334

Name Avril Roy. CR No. 2013618425 Diagnosis

Date Clinical Condition 11 years male Advice

26/2/14

△

- cleft palate operated.

- left sided undescended testis with inguinal hernia.

2/1/14

HT - 125 cm.  
(-2SD to -3SD)  
WT - 23 kg (3rd - 5th centile)  
HC - 50.2 cm.

Adv:  
↳ Syp.

Zincovit 1 tsf OD x  
1m

- Normal Development milestones.

- Paediatric <sup>surgery</sup> Consultation.

- Karyotype

- MLPA (for <sup>specific</sup> velocardiofacial <sup>cardiomatry probe set</sup>)

- TTA - N Normal

- ECHO - Normal


- MLPA (common microdeletia including VCF) - Normal

↓  
Anxited.

- Face → Small palpebral fissure.

- Facial changes can be attributed to cleft palate.  
Please bring this Card at each visit.

Pom

Date	Clinical Condition	Advice
	<p>Short stature</p> <p>ich-narrow palpebral fissures</p> <ul style="list-style-type: none"> <li>- Flattened tip of nose</li> <li>- mild retrognathia.</li> <li>- Everted umbilicus</li> <li>- Mild soft tissue syndactyly.</li> <li>- No shaft scutum.</li> <li>- Externally rotated ear</li> <li>- hypoplastic alae nasi</li> <li>- cleftic..</li> </ul> <p>-?? Aarskog syndrome</p> <p>Review 6 months.</p>	<p style="text-align: right;">28/11</p> <p style="text-align: center;">         Dr. R. Madhe        23/7/15     </p>



0522-2494082 (2.30-4.00 PM)

Dr. V. Bhatia

Professor  
Department of Endocrinology  
S.G.P.G.I.M.S., Lucknow

Wed/Thurs.



Sanjay Gandhi Postgraduate Institute of Medical Sciences, Lucknow  
Deptt. of Endocrinology

Patient OPD Record

DOB - 26/12/02

For appointments: Tel.: (0522)-2494075, 2495004

Medical Social Worker, OPD Hall No. 1

Doctor's signature for medical reimbursement to be taken within 6 months of expenditure.

Name Avni

CR No. 2013618425 - Diagnosis

Age/Sex 10<sup>10</sup>/12 yrs

24/10/13

Short stature /  
Multiple dysmaturisms

- WT = 21.6 kg
- HT = 124.4 cm
- OFL = 49 cm
- Broad forehead
- Microphthalmia
- Broad nasal bridge
- Prominent columella
- ? Micrognathia

TV ~ 2-3rd, SPL (+), PH,

Plan =>

- Genetic follow up
- Chemistry
- Thyroid profile
- 6 month date shu

TTC (n)  
Chem } (n)  
Hb }  
T<sub>4</sub>  
TSH


23/7/15  
12/7/12

25.7  
132

GV<sub>21</sub> = 4.4 cm/yr  
Prepubertal TV 3ml b/l

Al To follow for onset  
of puberty.  
6 month date

28/01/16

Date	Clinical Condition	Advice
<p>Short stature with-normal palpable fissures</p>	<ul style="list-style-type: none"> <li>- Flattened tip nose</li> <li>- mild retrognathia.</li> <li>- Everted umbilicus</li> <li>- mild soft fissure syndactyly.</li> <li>- No sweat scurfum.</li> <li>- Externally rotated. ears</li> <li>- hypoplastic, alae nasi</li> <li>- cardiac.</li> </ul>	<p>-?? Acanthosis syndrom Revised 6 months.</p>  <p>Responsible 2317115</p>

Date	Clinical Condition	Advice
<p>28/Jan/16</p>		



बहिरंग-पत्र

क्रमांक-च 641913

सर सुन्दरलाल चिकित्सालय, काशी हिन्दू विश्वविद्यालय

नाम

Arival

आयु

Arival

पुं/स्त्री/बा०

दिनांक

चिकित्सा

5/3/05

संक्षिप्त विवरण

PLASTIC SURGERY,

Regd. No. 1329/05

16/6/05

(46)

To come in person Saturday at 8:30 AM for speech therapy

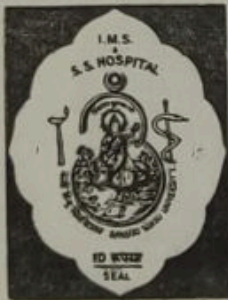
Speech therapy given  
Be in regular follow up  
Review after 3 months.

(28)

21/6/05

For teeth problem please contact  
Dentist  
& ~~visit~~ Mental Retardation. Dept.  
Refer to Paed. medicine  
for evaluation.

h  
21/6.



डॉ० वी० महाचार्या  
प्रोफेसर प्लास्टिक सर्जरी  
पूर्व दिग्गजाय

एम०एस०एम०एस०एम०पी०एच०डी०  
एफ०आई०सि०एस०एम०एन०एम०एम०एम०  
मंगलवार



79

105

बहिरंग-पत्र  
कमांक-च 707284  
सर सुन्दरलाल चिकित्सालय, काशी हिन्दू विश्वविद्यालय

नाम अश्विनी  
आयु 2 पु०/स्त्री०/बा०

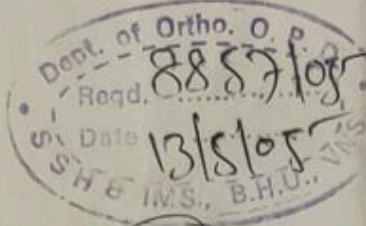
दिनांक

चिकित्सा

13/5/05

संक्षिप्त विवरण

X-ray Pelvis - both Hips - AP.  
GML



79

Pedicle length - 4pp.

- Ext. Rotation of both lower limbs at hip
- ~~Flat~~ Plano Valgus
- genu Valgum

To. Physiotherapy (Tech)  
P). evaluate the care of discum  
GML

AS - Splintage for walk  
- Exercises

शुक्रवार

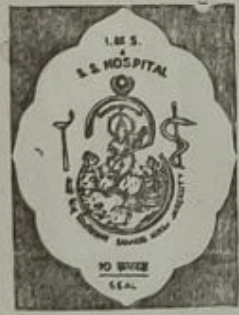NO H/O Asthma, Asphyxia, still term cesarean delivery, hyperbilirubinosis. Photo therapy done for 9 weeks

H/O mild delayed milestones.

- can walk independently but c(4)
- operated for cleft palate hemiplegic

O/E. Cor. lined (4) 4L

- voluntary control (4) 4L GM. / fair FM. / fair
- plano valgus feet
- genu valgum
- (4) hemiplegic gait -



बृहस्पतिवार

09.6.05



# जिला चिकित्सालय, फैजाबाद



रोगी का नाम ओबिरल

उम्र/लिंग 1.07.24

रजिस्ट्रेशन नं० 222023

हिन्दू, मुस्लिम, सिख, ईसाई  
उद्देश का स्वतंत्र सबको भाई

रजिस्ट्रेशन नं०

व्यावसायिक रक्तदान, खतरे का निशान  
स्वैच्छिक रक्तदान, सुरक्षित रक्तदान

पन्द्रह दिन के लिये वैद्य

दिनांक	लक्षण तथा उपचार
28 AUG 2017 <del>1 AUG 2017</del>	<p><u>Dr. Rakesh Grewal</u></p> <p>Referral to - Endocrinology 55091 LKO.</p>

E.M.O.  
District Hospital, Faizabad