



PATIENT NAME: ANCHAL RANA
REFERRED BY: SELF

August 19, 2022
AGE/SEX :- 32 YRS / F

ULTRA SOUND BILATERAL BREAST (SONO MAMOGRAPHY)

Right Breast:

- Small cystic lesion is noted in upper outer quadrant measuring ~ 3.0x2.0 mm. S/o fibrocystic disease of breast .
- Fatty tissue is noted in right axilla ..? lypoma D/D accessory breast tissue.
- Rest of right breast parenchyma is normal in echotexture for age.
- Skin and subcutaneous fat unremarkable.
- No mass lesion or axillary lymphadenopathy.
- Right nipple and subareolar region is unremarkable.

Left Breast:


- Left breast parenchyma is normal in echotexture for age. No focal lesion.
- Skin and subcutaneous fat unremarkable.
- Left axilla clear. No mass lesion or axillary lymphadenopathy.
- Left nipple and subareolar region is unremarkable.

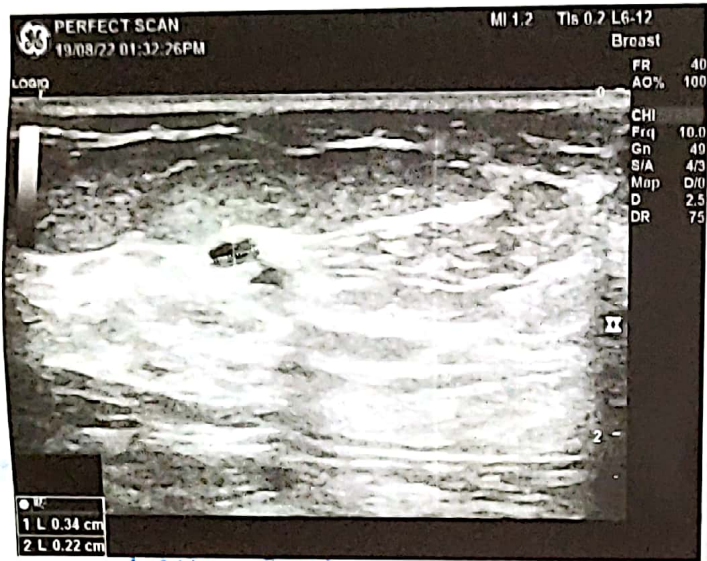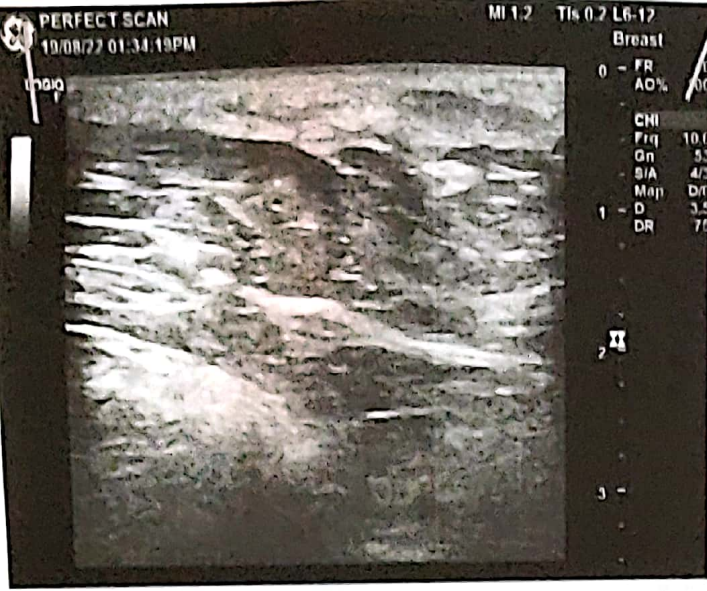Please correlate clinically

Kindly Note

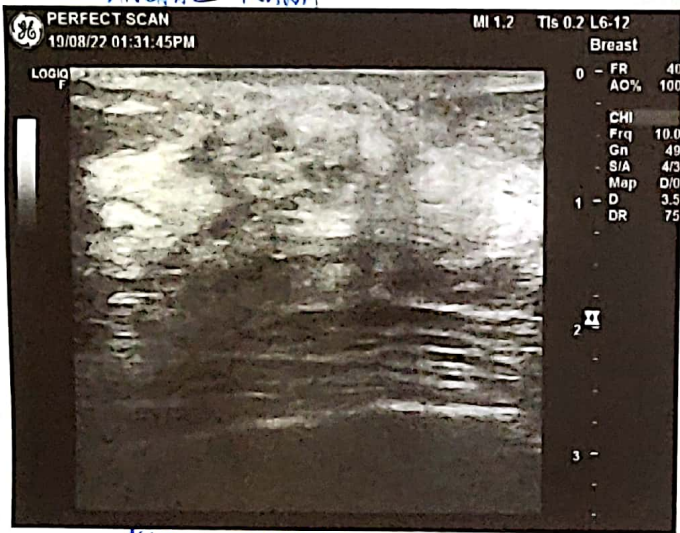
- ❖ Please Intimate us for any typing mistakes and send the report for correction within 7 days.
- ❖ The science of Radiological diagnosis is based on the Interpretation of various shadows produced by both the normal and abnormal tissues and are not always conclusive. Further biochemical and radiological investigation & clinical correlation are required to enable the clinician to reach the final diagnosis.

The report and films are not valid for medico - legal purpose.

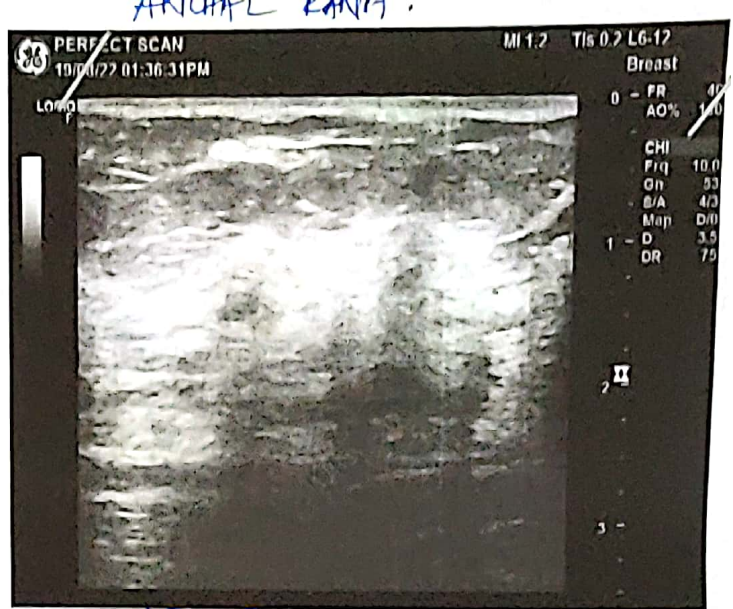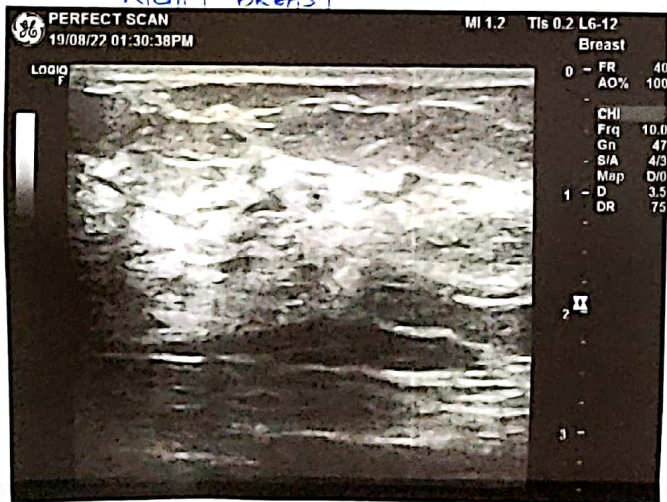

DR. MITUSHI KATIYAR
(SONOLOGIST)



ANCIHAL KANA



RIGHT BREAST



LEFT BREAST

