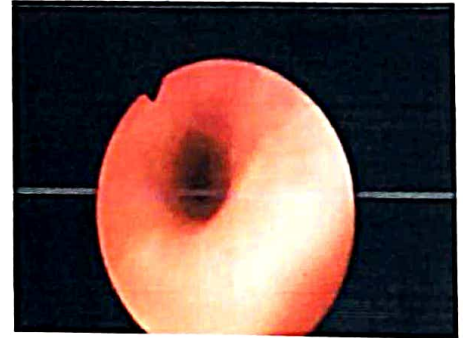


Patient ID: 2022090041
Name: Mr. VINOD GAUR
Age: 69 Y
Sex: M
Date: 23-Sep-2022

Ref By: SELF
Study: Flexible Cystoscopy
Examined By: Dr. Aditya Pradhan
Hospital ID: BLKH.501072

Clinical Diagnosis :



Urine : **Turbid** / Clear / Hematuria / Pyuria

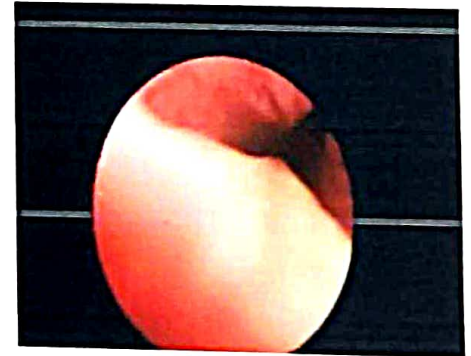
PROCEDURE :Flexible Cystoscopy

Ant urethra -

(N)

Post urethra - Lateral prostate lobe-
Median prostate lobe-
Bladder Neck-

Prominent



Bladder - Trigone

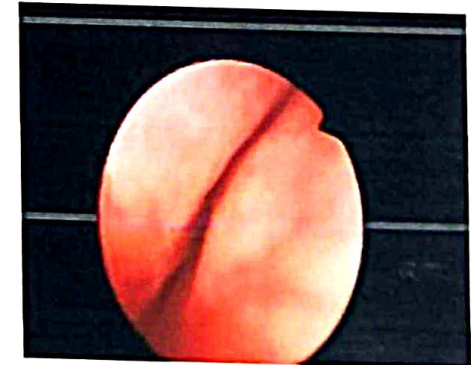
Ureteric orifice- Left-

(N)

Right-

(N)

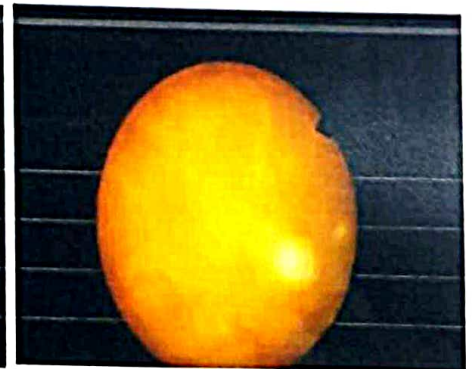
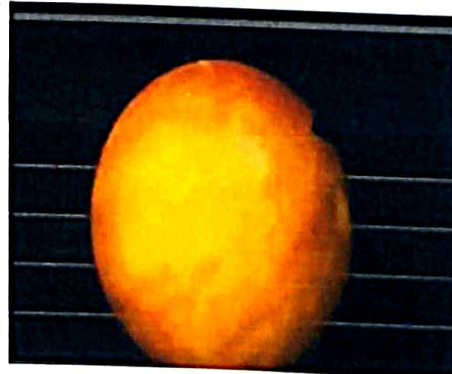
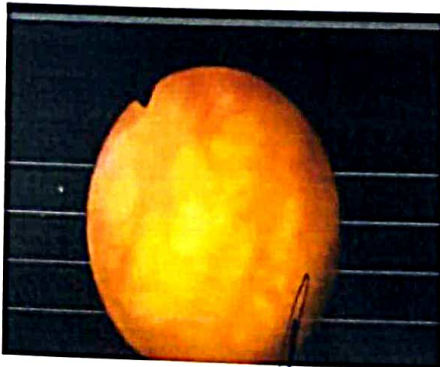
Rest of the mucosa-
Trabeculations-
Capacity-
Sensation-



Endoscopic Impression :

Advice :

DPE - 60-70g prostate
- To consider TURP.



Dr Aditya Pradhan

