



K.D.M Imaging & Diagnostic Centre

Dr. Kamendra Singh

M.D. (RADIOLOGY)
(Civil Hospital)
M.B.B.S. (1981) M.D. (1984) D.I.D.

Faculty of I.I.T.M. Madhav Pradhani Hospital

Pt. Name: MRS. LALITA SHARMA
Ref. By: Dr. MEENA DIXITA (D.G.O.)
(Identity of the patient can't be verified)

Age/SEX: 50 Y/F
Date: 04/JULY/2022

USG LOWER ABDOMEN WITH TVS

Uterus measures approx 11x46x71 mm in size and Myometrial echotexture is normal. Approx 10x8 mm heterogeneously hypoechoic lesion seen arising from anterior uterine wall of the uterus suggestive of subserosal fibroid. Approx 14x12 mm well defined heterogeneously hypoechoic lesion in posterior uterine wall of the uterus suggestive of intramural fibroid. Endometrial thickness is 7.5 mm. Cervix is normal in size and measures approx 25.6 mm. Few nabothian cysts measuring largest approx 8x7 mm & approx 8x7 mm and approx 8x5 mm noted in cervix.

Ovaries: Right ovary measures approx 37x15 mm in size. Left ovary measures approx 33x11 mm in size. Both ovaries shows normal in echopattern. Both adnexal sites are clear. No fluid is seen in cul de sac.

IMPRESSION:

❖ Intramural & Subserosal fibroid as describe above.

Please correlate clinically.

K.S.
DR. KAMENDRA SINGH
M.B.B.S. MD. RADIODIAGNOSIS
(CONSULTANT RADIOLOGIST)

All tests have technical limitations. Correlation of clinical features and other investigations are mandatory to arrive at proper diagnosis. This report is a professional opinion and not a diagnosis. Not for Medical/legal Purpose.

संस्था: माधव प्रधनी हॉस्पिटल, गिफ्ट, गल्लमिवाला एस्टेट, गल्ल, नजीबा रोड, दिल्ली, फोन: 9557995574



RCCR PATH LABS

Opp. Head Office Co-operative Bank
Shaheed Chowk, Western Kutchery Road
Meerut-250002 (U.P.) Ph. 7300708014, 7300708015
Timings : 7:00 a.m. to 9:00 p.m.
(Emergency 24 Hrs.)

Dr. Reeta Jain, DCP

Dr. Rajan Goel, DCP

Dr. Charu Gar



Name:	Mrs. CHITRA SHARMA	Branch:	Micropath Speciality Lab
Age/Gender:	51 Y/Female	Registered:	03/May/2022 12:15PM
Patient ID:	042205030019	Analysed:	04/May/2022 01:48PM
BarcodeNo:	10134911	Reported:	04/May/2022 01:48PM
Referred By:	Dr. MEENA BHATIA MBBS DGO	Place:	OPD

CYTOLOGY

Liquid Based Cytology- Cervical Smears

C-055/2022

Microscopic Description: By BETHESDA SYSTEM

Specimen Type Liquid Based Preparation

- a) Specimen adequacy Smears are satisfactory and adequate for evaluation
- b) Microscopy Smears show superficial squamous cells, intermediate squamous cells and few parabasal cells. Reactive cellular changes associated with inflammation seen. Few candida spores and budding yeast like cells are seen.
- c) Endocervical cells Absent
- d) Koilocytotic cells Absent
- e) Dysplastic cells Absent
- f) Malignant cells Absent

Interpretation Candida vaginitis

Comments

- 1) PAP smear study is a screening procedure for cervical cancer with inherent false negative results, hence should be interpreted with caution.
- 2) No cytologic evidence of HPV infection in the smears studied.

*** End Of Report ***

PATHOLOGIST
Dr. RAJAN GOEL, DCP

PATHOLOGIST
Dr. CHARU GARG

CENTERS

Goel Pathology Clinic
(Dr. Rajan Goel)
5, Rani Mill, Delhi Road
Meerut-250002

Shastrinagar Diagnostic Center
(Dr. Reeta Jain)
2, A-Block Market, Tejgarhi Crossing
Garh Road, Meerut-250004

Micropath Speciality Lab
(Dr. Charu Garg)
E.K. Road, Opp. Shanker Ashram
Meerut-250001



RCR PATH LABS

Opp. Head Office Co-operative Bank
Shaheed Chowk, Western Kutchery Road
Meerut-250002 (U.P.) Ph. 7300708014, 7300708015

Timings : 7.00 a.m. to 9.00 p.m.
(Emergency 24 Hrs.)

Dr. Reeta Jain, DCP

Dr. Rajan Goel, DCP

Dr. Charu Gar



Name:	Mrs. CHITRA SHARMA	Branch:	Micropath Speciality Lab
Age/Gender:	51 Y/Female	Registered:	03/May/2022 12:16PM
Patient ID:	042205030019	Analysed:	04/May/2022 01:48PM
BarcodeNo:	10134911	Reported:	04/May/2022 01:48PM
Referred By:	Dr. MEENA BHATIA MBBS DGO	Place:	OPD

CYTOLOGY

Liquid Based Cytology- Cervical Smears

C-055/2022

Microscopic Description: By BETHESDA SYSTEM

Speimen Type Liquid Based Preparation

a) Specimen adequacy Smears are satisfactory and adequate for evaluation

b) Microscopy Smears show superficial squamous cells, intermediate squamous cells and few parabasal cells. Reactive cellular changes associated with inflammation seen. Few candida spores and budding yeast like cells are seen.

c) Endocervical cells Absent

d) Koilocytotic cells Absent

e) Dysplastic cells Absent

f) Malignant cells Absent

Interpretation Candida vaginitis

Comments

- 1) PAP smear study is a screening procedure for cervical cancer with inherent false negative results, hence should be interpreted with caution.
- 2) No cytologic evidence of HPV infection in the smears studied.

*** End Of Report ***

PATHOLOGIST
Dr. RAJAN GOEL, DCP

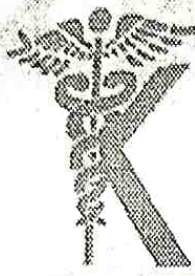PATHOLOGIST
Dr. CHARU GARG, MD

CENTERS

Goel Pathology Clinic
(Dr. Rajan Goel)
5, Rani Mill, Delhi Road
Meerut-250002

Shastrinagar Diagnostic Center
(Dr. Reeta Jain)
2, A-Block Market, Tejgarhi Crossing
Garh Road, Meerut-250004

Micropath Speciality Lab
(Dr. Charu Garg)
E.K. Road, Opp. Shanker Ashram
Meerut-250001



K.D.M Imaging & Diagnostic Centre

Dr. Kamendra Singh

MBBS, MD Radiodiagnosis
(Gold Medalist)

Mob. : +91-9557995574

Formerly at: L.L.R.M Medical College, Meerut

Pt. Name :- **MRS. CHITRA SHARMA**

Ref. By :- **Dr. MEENA BHATIA**

Age/SEX :- **50 Y/F**

Date :- **05/MAY/2022**

(Identity of the patient can't be verified).

USG WHOLE ABDOMEN

Liver is normal in size (approx 129 mm) and mildly increased in parenchyma echopattern. No focal/diffuse mass lesion seen. IHBVs are normal. Margins are regular.

Gall Bladder is partially contracted. Wall thickness is normal. No calculus / focal mass seen. No pericholecystic collection seen.

CBD is normal in caliber (approx 2.7 mm). No calculus / focal mass seen.

Portal Vein is normal in caliber.

Pancreas is normal in size and echotexture. No focal mass seen. No peripancreatic collection seen.

Spleen is normal in size (approx 69x45 mm) and echopattern.

Right kidney is normal in size (approx 101x39 mm) and cortical echotexture. No calculus/ hydronephrosis seen. Corticomedullary differentiation is maintained. Renal margins are regular.

Left kidney is normal in size (approx 89x43 mm) and cortical echotexture. No calculus/ hydronephrosis seen. Corticomedullary differentiation is maintained. Renal margins are regular.

Urinary bladder is partially filled with normal wall thickness. No calculus / focal mass seen.

Uterus measures approx 79x48x52 mm in size and Myometrial echotexture is normal. Approx 13x11 mm heterogeneously hypoechoic lesion in anterior uterine wall of the uterus suggestive of intramural fibroid. Approx 12x8 mm well defined heterogeneously hypoechoic lesion seen arising from posterior wall of the uterus suggestive of subserosal fibroid. Endometrial thickness is 10.7 mm. Cervix is bulky and measures approx 40.7 mm. Few nabothian cysts measuring largest approx 7x7 mm & approx 7x6 mm and approx 5x5 mm noted in cervix.

Ovaries: Right ovary measures approx 35x23 mm and shows approx 16x11 mm & approx 14x7 mm dominant follicles. Left ovary measures approx 32x19 mm. Both ovaries shows normal in echopattern.

Both adnexal sites are clear.

Mild fluid is seen in cul de sac.

Bowel loops are normal in caliber.

No evidence of ascites, bilateral pleural effusion and retroperitoneal lymphadenopathy seen.

IMPRESSION:

- ❖ Fatty grade I liver changes.
- ❖ Intramural & Subserosal fibroid as describe above.
- ❖ Cervix is bulky (approx 40.7 mm) with few nabothian cysts suggestive of Cervicitis.

Please correlate clinically.

DR. KAMENDRA SINGH
M.B.B.S, MD, RADIODIAGNOSIS
(CONSULTANT RADIOLOGIST)



K.D.M Imaging & Diagnostic Centre

Dr. Kamendra Singh

MBBS, MD Radiodiagnosis
(Gold Medalist)

Mob. : +91-9557995574

Formerly at: L.L.R.M Medical College, Meerut

Pt. Name :- MRS. CHITRA SHARMA

Age/SEX:- 50 Y/F

Ref. By :- Dr. MEENA BHATIA

Date :- 05/MAY/2022

(Identity of the patient can't be verified).

USG WHOLE ABDOMEN

Liver is normal in size (approx 129 mm) and mildly increased in parenchyma echopattern. No focal/diffuse mass lesion seen. IHBRs are normal. Margins are regular.

Gall Bladder is partially contracted, Wall thickness is normal. No calculus / focal mass seen. No pericholecystic collection seen.

CBD is normal in caliber (approx 2.7 mm). No calculus / focal mass seen.

Portal Vein is normal in caliber.

Pancreas is normal in size and echotexture. No focal mass seen. No peripancreatic collection seen.

Spleen is normal in size (approx 69x45 mm) and echopattern.

Right kidney is normal in size (approx 101x39 mm) and cortical echotexture. No calculus/ hydronephrosis seen. Corticomedullary differentiation is maintained. Renal margins are regular.

Left kidney is normal in size (approx 89x43 mm) and cortical echotexture. No calculus/ hydronephrosis seen. Corticomedullary differentiation is maintained. Renal margins are regular.

Urinary bladder is partially filled with normal wall thickness. No calculus / focal mass seen.

Uterus measures approx 79x48x52 mm in size and Myometrial echotexture is normal. **Approx 13x11 mm heterogeneously hypoechoic lesion in anterior uterine wall of the uterus suggestive of intramural fibroid. Approx 12x8 mm well defined heterogeneously hypoechoic lesion seen arising from posterior wall of the uterus suggestive of subserosal fibroid.** Endometrial thickness is 10.7 mm. **Cervix is bulky and measures approx 40.7 mm. Few nabothian cysts measuring largest approx 7x7 mm & approx 7x6 mm and approx 5x5 mm noted in cervix.**

Ovaries: Right ovary measures approx 35x23 mm and shows approx 18x11 mm & approx 14x7 mm **dominant follicles.** Left ovary measures approx 32x19 mm. Both ovaries shows normal in echopattern.

Both adnexal sites are clear.

Mild fluid is seen in cul de sac.

Bowel loops are normal in caliber.

No evidence of ascites, bilateral pleural effusion and retroperitoneal lymphadenopathy seen.

IMPRESSION:


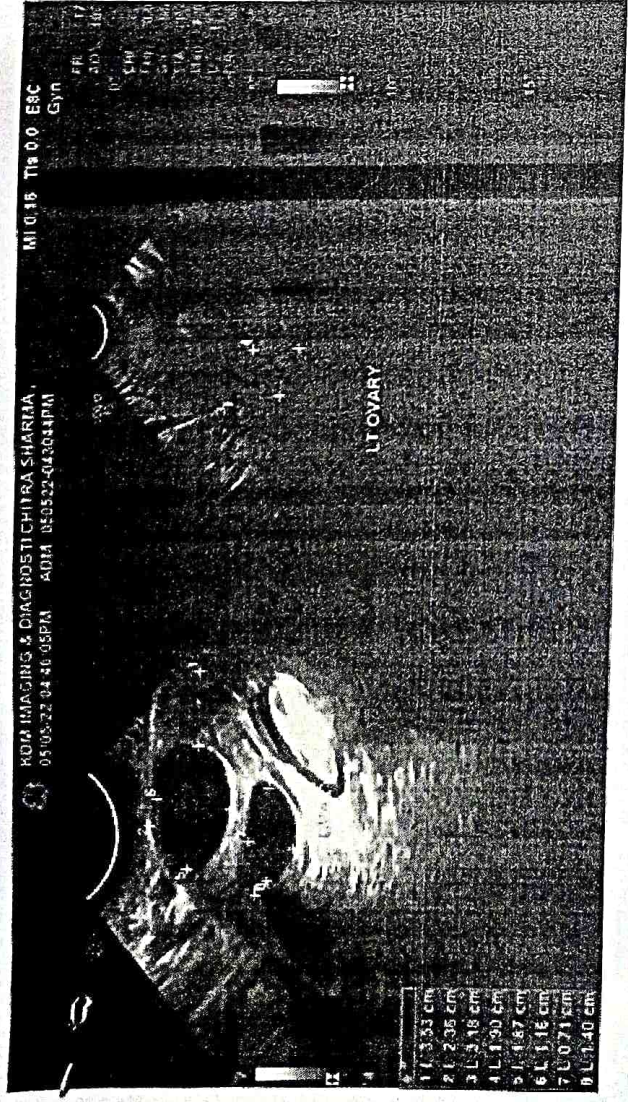
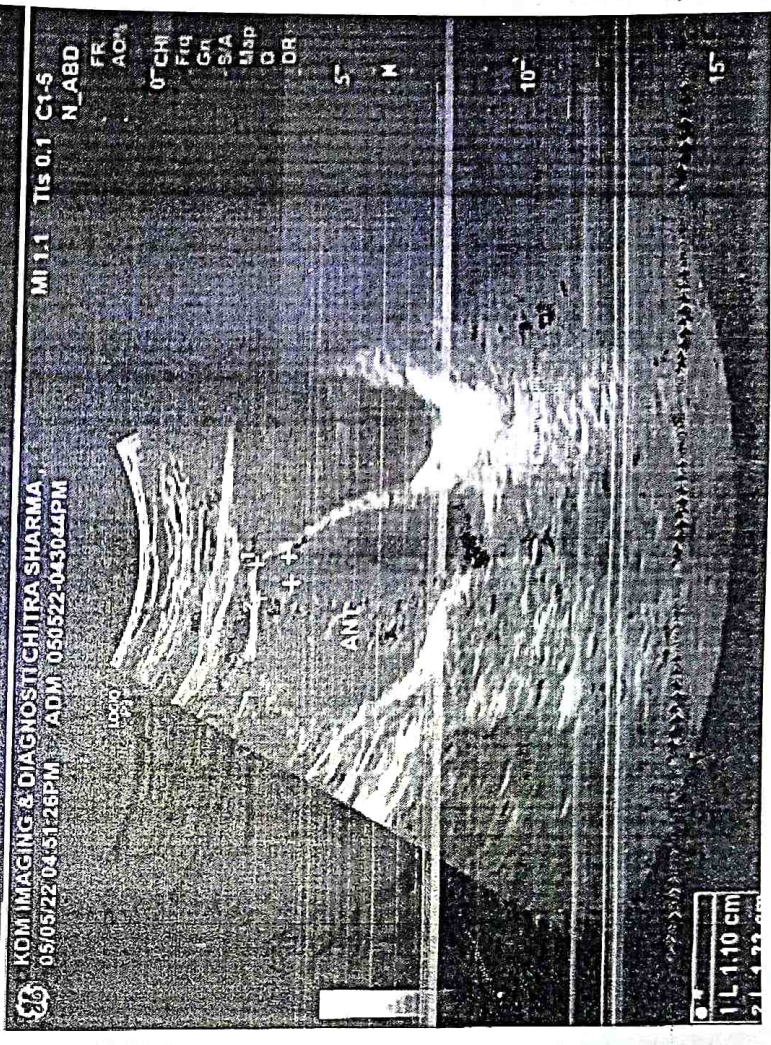
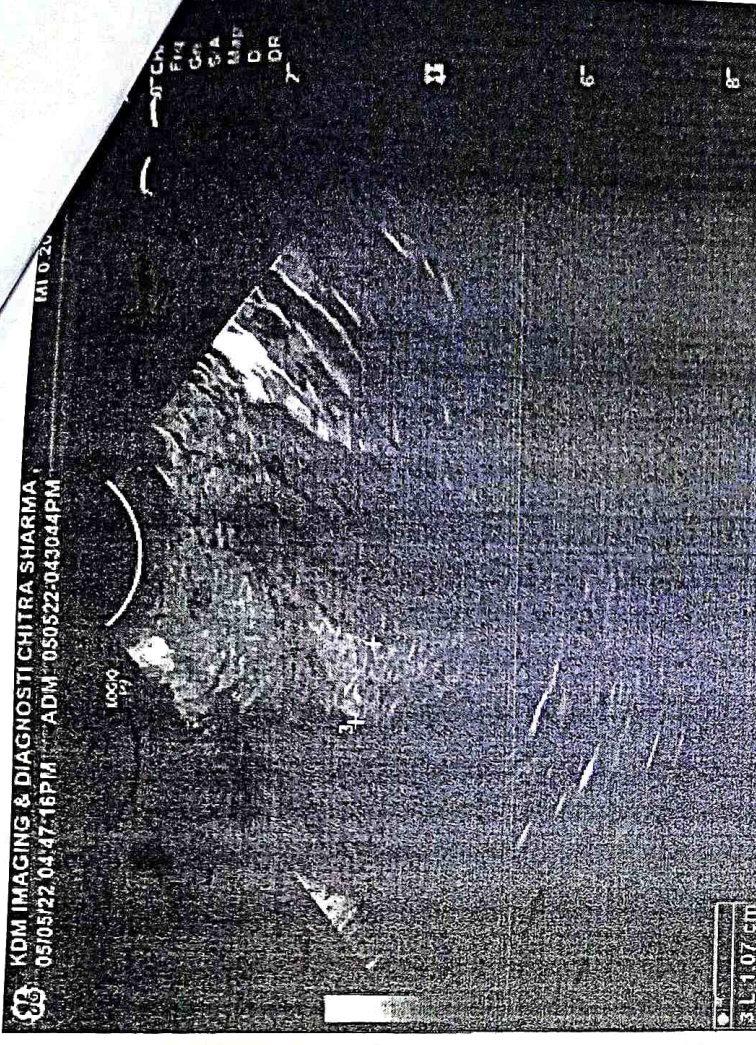
- ❖ Fatty grade I liver changes.
- ❖ Intramural & Subserosal fibroid as describe above.
- ❖ Cervix is bulky (approx 40.7 mm) with few nabothian cysts suggestive of Cervicitis.

Please correlate clinically.

K.S.
DR. KAMENDRA SINGH
M.B.B.S, MD. RADIODIAGNOSIS
(CONSULTANT RADIOLOGIST)

All tests have technical limitations. Correlation of clinical features and other investigations are mandatory to arrive at proper diagnosis.
This report is a professional opinion and not a diagnosis. Not for Medicolegal Purpose

मो. 9557995574



ऋषि भाटिया

MS SURGERY (MCI UP 29936)

आंत, पथरी व मूत्र रोग विशेषज्ञ

सर्व सर्जन : वैद्य कानून अस्पताल, मेरठ



श्री 0 राष्ट्रीय भाटिया (भरहुडा वाले) मैगरेटिवन

साथीकल व गोट्रिनिटी क्लीनिक

डा० मीना भाटिया

MBBS, DGO (MCI UP 33860)

स्त्री एवं प्रसूति रोग विशेषज्ञ

पूर्व चिकित्सक : मुशीत नखवना ग्रह अस्पताल, मेरठ

नाम मरीज

Mr. Chubra

दिनांक

9/5/22

Dr. Meena Bhatia
to Dr. Chubra

रिपोर्ट

- ★ दूरबीन द्वारा जोष व अभिप्राय
- उपेक्षित
- पित्त की घंटी की पथरी
- मूत्र की पथरी व गदर
- बच्चेदानी
- जख्मेदानी की रसोली
- जख्मे रच्चा की खोच
- गर्भ समापन सुविधा
- कोपर-टी व परिवार नियोजन साधन
- निःसंतान स्त्री-पुरुष का इलाज
- बच्चेदानी के तख्तों की ठीकी सिकाई

Adv

Small Abnormal

Labo Instruct

→ 9997677897

9.0pm daily x 1m-16

(Dr. Rashmi Agrawal)

Labo Supracal

2000 mg x 1m-16

Dr. Smridhi Khasthi

Labo Etosmen MR on

→ 9582475108
Cancellin

Labo Fluicade 150 x 5cl

Reew after 4wth

● कभी भी परेशानी होने पर या बढ़ने पर तुरन्त चिकित्सक से सम्पर्क करें।

● फोन पर नाम लिखने का समय : सुबह 9 बजे से 11 बजे
फोन : 0121-2664006

● एक बार की फीस चार दिन के लिए माहव
● नाम निकल जाने पर नाम पर कीसल हो जा
फोन : 0121-2977910

क्लीनिक

नैच्यर पैलेस के पास
मालकुर्ती पैठ हरिया
मेरठ
फोन : 0121-2664006

परामर्श समय :


सुबह 10 बजे से दोपहर 12 बजे तक

रविवार अवकाश

*Name as told by Patient but not verified

निवास

शुभम् बी-
जवाहर क्वार्टर,
(क्लीनिक के सामने) मेरठ
फोन : 2664006



K.D.M Imaging & Diagnostic Centre

Dr. Kamendra Singh

M.B.B.S. (D) Radiodiagnosis

(Fellow Member)

Membership No. 10105700026

Faculty of K.D.M. Institute of Postgraduate Medical Education

Pt Name: MRN CHITRA NEERAM
Ref By: Dr. MEENA JOTIA [D.O.]
(Identity of the patient can't be verified)

Age/Sex: 50 Y/F
Date: 03/JULY/2022

USG LOWER ABDOMEN WITH TVS

Uterus measures approx 81x46x71 mm in size and Myometrial echotexture is normal. Approx 10x8 mm heterogeneously hypochoic lesion seen arising from anterior uterine wall of the uterus suggestive of subserosal fibroid. Approx 14x12 mm well defined heterogeneously hypochoic lesion in posterior uterine wall of the uterus suggestive of intramural fibroid. Endometrial thickness is 7.5 mm. Cervix is normal in size and measures approx 25.6 mm. Few nabothian cysts measuring largest approx 8x7 mm & approx 8x7 mm and approx 8x5 mm noted in cervix.
Ovaries: Right ovary measures approx 37x15 mm in size. Left ovary measures approx 33x11 mm in size. Both ovaries shows normal in echopattern.
Both adnexal sites are clear.
No fluid is seen in cul de sac.

IMPRESSION:

❖ Intramural & Subserosal fibroid as describe above.

Please correlate clinically.


DR. KAMENDRA SINGH
M.B.B.S. (D) RADIODIAGNOSIS
(CONSULTANT RADIOLOGIST)

All tests have technical limitations. Correlation of clinical features and other investigations are mandatory to arrive at correct diagnosis. This report is a professional opinion and not a diagnosis. Not for Medical/Legal Purpose.

DR. KAMENDRA SINGH, M.B.B.S. (D) RADIODIAGNOSIS, CONSULTANT RADIOLOGIST, K.D.M. IMAGING & DIAGNOSTIC CENTRE, 101, RAJIV GANDHI ROAD, BANGALORE, KARNATAKA, INDIA. TEL: 9557995574

डॉ० शशि भाटिया

SURGERY (MCI UP 29936)

ए. पथरी व गुल्म रोग विशेषज्ञ

संलग्न : कैम्प जनरल अस्पताल, मेरठ



इं० रामतीर्थ भाटिया (आग्नेय काले) मेडिकल

सर्जिकल व गेस्ट्रोइंटेरी क्लीनिक

डा० मीना भाटिया

MBBS, DGO (MCI UP 33860)

स्त्री एवं प्रसूति रोग विशेषज्ञ

पूर्व चिकित्सक : सुग्रीला नरसिंह राय अस्पताल, मेरठ

विशेष सुविधाएँ

- सुपरीन द्वारा जीव व ऑपरेशन
- एपेंडिसाइटिस
- पित्त की पथरी की पथरी
- गुर्दे की पथरी व मद्द
- बन्धेदानी
- अम्लेदानी की रसोली
- ललाटे रकबा की जीव
- गर्भ संचालन सुविधा
- कोपर-टी व परिकर निबोधन साधन
- निःसंज्ञक स्त्री-पुरुष का इलाज
- बन्धेदानी के जलमों की ठंडी सिजन

नाम मरीज Michaelson

दिनांक 5/7/21

Backache

Adv: -

o-Labo fibrocase
dmg
o-Labo Ferrous plus

x 2 months

o-Labo Tridolo 400
o-Labo Kenyhal plus
o-Labo Racedam on

MCCOY
5/7/21

• कभी भी घरेलूाजी होने पर या बढ़ने पर तुरन्त चिकित्सक से सम्पर्क करें।

• फोन पर नाम लिखने का समय : सुबह 9 बजे से 11 बजे
फोन : 0121-2664006

• एक बार की फीस चार दिव के लिए मान्य
• नाम निकल जाने पर नम्बर कैंसिल हो जायेगा
फोन : 0121-2977976

क्लीनिक

नेव्हर पैलेस के पास
लालकुर्मी गेट हरिया
मेरठ
फोन : 0121-2664008

घरामर्ग समय :

सुबह 10 बजे से दोपहर 1 बजे तक

सविद्यालय अस्पताल

*Name as told by Patient but not verified

विवरण :

शुभम् बी-1
जवाहर वार्डर्स, मे
(क्लीनिक के सामने कॉलोनी :
फोन : 26645