

Out Patient Record

Please Bring This Record With You



Date Name **OMKAR GANGWAR** Regn No. **00508326**
F/H Name **J B LAL GANGWAR** Age/Sex **65 Year/Male**
Doc Name **DR. Z S MEHARWAL**

00508326
o. 00508326

Address

Bareilly (16.4.2014)

Phone No.

9415668426

Broklet No.



FOLLOW UP VISIT

Date _____

Name of Patient _____

Salient Complaints _____

History _____

General Examination _____

Weight _____

BMI : Low High Within limits

Pain Score (0-10) _____

Systemic Examination _____

Investigations advised/results _____

Treatment Advised _____

Reg. No. _____

Fortis Esco
HEART INSTITUTE

Name of Patient _____

Date 18/05/2015

Cecelia Physio

Salient Complaints _____

No c/o any musculoskeletal digital

History _____

General Examination _____

— Pain — 0/10
— All RA — low
— functionally — (2)

Weight _____

BMI : Low High Within limits

Pain Score (0-10) _____

Systemic Examination _____

— All — 5 hrs/day

— Active lifestyle —

Investigations advised/results _____

Treatment Advised _____

— Continue same

Consultant Sign. : _____

ID No.: _____

Consultant Sign. : _____

ID No.: _____

(175-15-04)

Fortis Escorts HEALTH RESEARCH INSTITUTE

Health Checkup Details

Escorts Heart Institute and
Research Centre Ltd.
Okhla Road, New Delhi - 110 025 (India)
Tel. : +91-11-47135000
Emergency Tel. : +91-11-105010
Fax : +91-11- 2682-5013
Email : contactus.escorts@fortishealthcare.com
Website : www.fortisescorts.in
: **NABH Accredited Institute**


UHID : 6101655 Patient Name : Mr. Omkar Gangwar Mobile No :
Episode No : 137531/21/12 Doctor Name : Dr. Z S Meharwal
Age/Sex : 71 YEAR(S)/Male
Bill No : 120121OPCS1 Bill Date : 20-Aug-2021
72050
PHC Timing : PHC HelpLine No :
Package : COMPREHENSIVE PACKAGE

Sl. No.	Investigation (S)	Admission No.
1	MEDICAL EXAMINATION	PHC.2180925
2	URIC ACID, SERUM (1310H-SRL)	PHC.2180926
3	BLOOD UREA NITROGEN, SERUM (1079H-SRL)	PHC.2180927
4	GLUCOSE, FASTING, PLASMA / URINE (1302H-SRL)	PHC.2180928
5	ELECTROCARDIOGRAPHY (ECG) 12 LEAD	PHC.2180929
6	CBC WITH ESR (CBC+PS+ESR) EDTA WHOLE BLOOD/SMEAR (5111-SRL)	PHC.2180930
7	URINALYSIS (5200U-SRL)	PHC.2180931
8	CORONARY RISK PROFILL (LIPID PROFILE), SERUM (1209AD-SRL)[1209AD][1209AD]	PHC.2180932
9	A&O GROUP & RH TYPE, EDTA WHOLE BLOOD	PHC.2180933
10	CREATININE EGFR: EPI (1320HGFREP - SRL)	PHC.2180934
11	CHEST X-RAY (PA VIEW)	PHC.2180935
12	GLUCOSE POST PRANDIAL, PLASMA (WITHOUT URINE)[1302GP][1302GP]	PHC.2180936
13	CONSULTATION(PHYSIOTHERAPY)	PHC.2180937



OUTPATIENT BILL

GST No. : 07AAACEB731F1Z5



L
itics

Name : Mr Dmkar Gangwar
UHID : 6101655
EpisodeNo : 137531/21/1201
Age/Sex : 71 YEAR(S)/Male
Primary Doctor : Dr Z S Meharwal
Contact No. : 915668456 94-1566 8426
Payor Name : NA
Ref Doctor : Dr Z S Meharwal
Insurance : NA
Patient Address : A 77 SURTISH SHARMA BAREILLY Bareilly Uttar Pradesh India

Bill No : 1201210PC5172050
Bill Type : CASH
Bill Date : 20-Aug-2021 10:13 AM
Print Date : 20-Aug-2021 10:13 AM
Discount Scheme : NA
CIN No. : U85110CH2000PLC023744
Payor Site Name : NA
Old UHID : 508326D
Employer Name : NA
TPA Name :

S.No	Particulars	Accession No	HSN Code	Batch No	Expiry Date	Qty	Service Amount	Contractual Discount	Net Gross Amount
1	Upgrade to 2D ECHO	OP.3948428	999316			1	1000.00	0.00	1000.00
2	COMPREHENSIVE PACKAGE	PHC.2180925	999312			1	1600.00	0.00	1600.00
TOTAL AMOUNT							2600.00	0.00	2600.00
Less Contractual discount									0.00
TOTAL TAX AMOUNT								0.00	0.00
BILL AMOUNT									2600.00
PAYOR SHARE									0.00
PATIENT SHARE									2600.00
TOTAL DISCR. DISCOUNT								0.00	0.00
PAID BY PATIENT									2600.00
NET PATIENT PAYABLE									2600.00
BILL ROUND OFF AMOUNT									0.00

Rupees In Words : Rupees Two Thousand Six Hundred only

Payor Details

Name : NA
Address : NA
GSTIN : NA

Prepared By Priyanka Dhingra Cashier Manager

Note :

Receipt Detail


S.No	Receipt No.	Receipt Date	Amount	Balance Amount	Payment Mode
1	1201/DP/2108/150444	20-Aug-2021 10:13 AM	2600.00	0.00	Cash



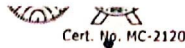
NABH Accredited

Regd. Office : OPD CITY CENTRE, SCO 11, Sector-11-D, Chandigarh-160 011, INDIA, Ph. : (0172) 5061222, 5055442, Fax No. : (0172) 5055441
CIN : U85110CH2000PLC023744

NEW DELHI, INDIA
Tel : 47134972, 47135511. Fax :



ATORY REPORT



Fortis Escorts

SRL
Diagnostics

IENT NAME : MR. OMKAR GANGWAR

IENT ID : FH.6101655

CLIENT PATIENT ID : UID:6101655

(सिम्पल-06)

SESSION NO : 0057UH010980 AGE : 71 Years SEX : Male DATE OF BIRTH : 01/01/1950
 AWN : 20/08/2021 10:33 RECEIVED : 20/08/2021 10:36 REPORTED : 20/08/2021 14:27

IENT NAME : EHIRC-OKHLA (CORPORATE)

REFERRING DOCTOR : DR. Z S Meharwal

CLINICAL INFORMATION :

ID:6101655 REQNO-976010
 ORP-OPD
 ILLNO-120121OPCS172050

Test Report Status	Final	Results	Biological Reference Interval	Units
--------------------	-------	---------	-------------------------------	-------

HAEMATOLOGY

CBC WITH ESR (CBC+PS+ESR) EDTA WHOLE BLOOD/SMEAR

BLOOD COUNTS

HEMOGLOBIN	13.6	13.0 - 17.0	g/dL
METHOD : PHOTOMETRY, NON-CYANMETHEMOGLOBIN			
RED BLOOD CELL COUNT	4.22	Low 4.5 - 5.5	mil/ μ L
METHOD : COULTER PRINCIPLE			
WHITE BLOOD CELL COUNT	5.20	4.0 - 10.0	thou/ μ L
METHOD : COULTER PRINCIPLE			
PLATELET COUNT	218	150 - 410	thou/ μ L
METHOD : COULTER PRINCIPLE			

RBC AND PLATELET INDICES

HEMATOCRIT	40.6	40.0 - 50.0	%
METHOD : CALCULATED PARAMETER			
MEAN CORPUSCULAR VOL.	96.3	83.0 - 101.0	fL
METHOD : DERIVED PARAMETER			
MEAN CORPUSCULAR HGB.	32.1	High 27.0 - 32.0	pg
METHOD : CALCULATED PARAMETER			
MEAN CORPUSCULAR HEMOGLOBIN CONCENTRATION	33.4	31.5 - 34.5	g/dL
METHOD : CALCULATED PARAMETER			
RED CELL DISTRIBUTION WIDTH	13.7	11.6 - 14.0	%
METHOD : DERIVED/COULTER PRINCIPLE			
MEAN PLATELET VOLUME	10.9	6.8 - 10.9	fL
METHOD : DERIVED PARAMETER			

WBC DIFFERENTIAL COUNT - NLR

SEGMENTED NEUTROPHILS	47	40 - 80	%
METHOD : VCSN TECHNOLOGY/ MICROSCOPY			
ABSOLUTE NEUTROPHIL COUNT	2.44	2.0 - 7.0	thou/ μ L
METHOD : CALCULATED PARAMETER			
LYMPHOCYTES	39	20 - 40	%
METHOD : VCSN TECHNOLOGY/ MICROSCOPY			
ABSOLUTE LYMPHOCYTE COUNT	2.03	1.0 - 3.0	thou/ μ L
METHOD : CALCULATED PARAMETER			
EOSINOPHILS	5	1.0 - 6.0	%
METHOD : VCSN TECHNOLOGY/ MICROSCOPY			

SRL DIAGNOSTICS


ESCORTS HEART INSTITUTE AND RESEARCH CENTRE
 LTD,OKHLA ROAD
 OKHLA, 110025
 NEW DELHI, INDIA
 Tel : 47134972, 47135511, Fax :
 CIN - U74899PB1995PLC045956

Page 1 Of 7



Scan to View Details

ATORY REPORT



Fortis Escorts

SRL
Diagnostics

PATIENT NAME : MR. OMKAR GANGWAR

IDENT ID : FH.6101655

CLIENT PATIENT ID : UID:6101655

(संज्ञक-०७)

SESSION NO : 0057UH010980 AGE : 71 Years SEX : Male DATE OF BIRTH : 01/01/1950
 AWWN : 20/08/2021 10:33 RECEIVED : 20/08/2021 10:36 REPORTED : 20/08/2021 14:27

PATIENT NAME : EHIRC-OKHLA (CORPORATE) REFERRING DOCTOR : DR. Z S Meharwal

INITIAL INFORMATION :

ID:6101655 REQNO-976010
 CRP-OPD
 ILLNO-1201210PCS172050

Test Report Status	Final	Results	Biological Reference Interval	Units
ABSOLUTE EOSINOPHIL COUNT		0.26	0.02 - 0.50	thou/ μ L
METHOD : CALCULATED PARAMETER				
MONOCYTES		09	2.0 - 10.0	%
METHOD : VCSN TECHNOLOGY/ MICROSCOPY				
ABSOLUTE MONOCYTE COUNT		0.47	0.2 - 1.0	thou/ μ L
METHOD : CALCULATED PARAMETER				
BASOPHILS		0	0 - 1	%
METHOD : VCSN TECHNOLOGY/ MICROSCOPY				
DIFFERENTIAL COUNT PERFORMED ON:		AUTOMATED ANALYZER		
PERIPHERAL SMEAR EXAM, EDTA WHOLE BLOOD				
RBC		PREDOMINANTLY NORMOCYTIC NORMOCHROMIC		
WBC		WBCS ARE NORMAL IN NUMBER & MORPHOLOGY		
PLATELETS		ADEQUATE		
* ERYTHRO SEDIMENTATION RATE, BLOOD				
SEDIMENTATION RATE (ESR)		24	0 - 30	mm at 1 hr
METHOD : OPTO ELECTRONIC SENSOR, AUTOMATED				

Interpretation(s)

BLOOD COUNTS-
 The cell morphology is well preserved for 24hrs. However after 24-48 hrs a progressive increase in MCV and HCT is observed leading to a decrease in MCHC. A direct smear is recommended for an accurate differential count and for examination of RBC morphology.
RBC AND PLATELET INDICES-
 The cell morphology is well preserved for 24hrs. However after 24-48 hrs a progressive increase in MCV and HCT is observed leading to a decrease in MCHC. A direct smear is recommended for an accurate differential count and for examination of RBC morphology.
WBC DIFFERENTIAL COUNT - NLR-
 The optimal threshold of 3.3 for NLR showed a prognostic possibility of clinical symptoms to change from mild to severe in COVID positive patients. When age = 49.5 years old and NLR = 3.3, 46.1% COVID-19 patients with mild disease might become severe. By contrast, when age < 49.5 years old and NLR < 3.3, COVID-19 patients tend to show mild disease.
 (Reference to - The diagnostic and predictive role of NLR, d-NLR and PLR in COVID-19 patients ; A.-P. Yang, et al.; International Immunopharmacology 84 (2020) 106504
 This ratio element is a calculated parameter and out of NABL scope.
ERYTHRO SEDIMENTATION RATE, BLOOD-
 Erythrocyte sedimentation rate (ESR) is a non-specific phenomena and is clinically useful in the diagnosis and monitoring of disorders associated with an increased production of acute phase reactants. The ESR is increased in pregnancy from about the 3rd month and returns to normal by the 4th week post partum. ESR is influenced by age, sex, menstrual cycle and drugs (eg. corticosteroids, contraceptives). It is especially low (0-1mm) in polycythaemia, hypofibrinogenemia or congestive cardiac failure and when there are abnormalities of the red cells such as poikilocytosis, spherocytosis or sickle cells.

Reference :

1. Nathan and Oski's Haematology of Infancy and Childhood, 5th edition
2. Paediatric reference intervals, AACCPress, 7th edition. Edited by S. Soldin
3. The reference for the adult reference range is "Practical Haematology by Dacie and Lewis, 10th Edition"

IMMUNOHAEMATOLOGY

ABO GROUP & RH TYPE, EDTA WHOLE BLOOD

ABO GROUP O
 METHOD : COLUMN AGGLUTINATION TECHNOLOGY, AUTOMATED
 RH TYPE POSITIVE

SRL DIAGNOSTICS
 ESCORTS HEART INSTITUTE AND RESEARCH CENTRE
 LTD, OKHLA ROAD
 OKHLA, 110025
 NEW DELHI, INDIA
 Tel : 47134972, 47135511, Fax :
 CIN - U74899PB1995PLC045956



Scan to View Details

SENT NAME : MR. OMKAR GANGWAR

Fortis Escorts

CLIENT ID : FH.6101655

CLIENT PATIENT ID : UID:6101655

SESSION NO : 0057UH010980

AGE : 71 Years

SEX : Male

DATE OF BIRTH : 01/01/1950

AWN : 20/08/2021 10:33

RECEIVED : 20/08/2021 10:36

REPORTED : 20/08/2021 14:27

CLIENT NAME : EHIRC-OKHLA (CORPORATE)

REFERRING DOCTOR : DR. Z S Meharwal

ADDITIONAL INFORMATION :

ID:6101655 REQNO-976010

CLINIC: OPD

BILLNO-120121OPCS172050

Test Report Status	Final	Results	Biological Reference Interval
--------------------	-------	---------	-------------------------------

METHOD : COLUMN AGGLUTINATION TECHNOLOGY, AUTOMATED

Interpretation(s)

ABO GROUP & RH TYPE, EDTA WHOLE BLOOD-Column Agglutination technology, Automated

BIO CHEMISTRY

GLUCOSE, FASTING, PLASMA

GLUCOSE, FASTING, PLASMA	90	82 - 115	mg/dL
METHOD : HEXOKINASE	<u> </u>		

SERUM BLOOD UREA NITROGEN

BLOOD UREA NITROGEN	16	8 - 23	mg/dL
METHOD : UREASE - UV	<u> </u>		

URIC ACID, SERUM

URIC ACID	6.3	3.4 - 7.0	mg/dL
METHOD : URICASE, COLORIMETRIC	<u> </u>		

CORONARY RISK PROFILE (LIPID PROFILE), SERUM

CHOLESTEROL	113	< 200 Desirable 200 - 239 Borderline High >/= 240 High	mg/dL
METHOD : CHOLESTEROL OXIDASE, ESTERASE, PEROXIDASE	<u> </u>		

TRIGLYCERIDES	86	< 150 Normal 150 - 199 Borderline High 200 - 499 High >/= 500 Very High	mg/dL
METHOD : ENZYMATIC WITH GLYCEROL BLANK			

HDL CHOLESTEROL	43	< 40 Low >/=60 High	mg/dL
METHOD : DIRECT MEASURE - PEG	<u> </u>		

DIRECT LDL CHOLESTEROL	66	< 100 Optimal 100 - 129 Near or above optimal 130 - 160 Borderline High 161 - 189 High >/= 190 Very High	mg/dL
METHOD : DIRECT MEASURE	<u> </u>		

NON HDL CHOLESTEROL	70	Desirable: Less than 130 Above Desirable: 130 - 159 Borderline High: 160 - 189 High: 190 - 219	mg/dL
METHOD : DIRECT MEASURE	<u> </u>		

SRL DIAGNOSTICS
ESCORTS HEART INSTITUTE AND RESEARCH CENTRE
LTD, OKHLA ROAD
OKHLA, 110025
NEW DELHI, INDIA
Tel : 47134972, 47135511, Fax :
CIN - U74899PB1995PLC045956





laser
urology centre

(संलग्न-०९)

DR. SHEKHAR VAJPEYI
M.S M.Ch (UROLOGY)
CONSULTANT UROLOGIST

शुभ ओंकार गणेश
age 68y

10-1-17

CATG 2013

Dr. Collette

BPH G-I/II

Use for Cl.



Candidi self assessment
fitness for TURP/HoLEP

Repts Rpt Dr. VK Jain
M.D.S.U

✓ Las Monolev 500 — 1 Q

✓ Las Celin 500 — 2

✓ Las Tandura — 2

Repts to higher centre
for TURP/HoLEP

लेजर यूरोलोजी सेंटर

रामरघु अस्पताल

संजय प्लेस के सामने, आगरा

Mob : 9027422666 (8 am to 7 pm)

Ph : 0562-4025100 (7pm to 8 am)

9412259144

डा. शेखर वाजपेयी

एम.एस., एम.सीएच. (यूरोलॉजी)

कन्सल्टेंट यूरोलॉजिस्ट

NAME

MR. OM KAR

65 YRS / M

REF. BY

DR. S. D. MAURYA / SIDDHARTH DHAR

12TH JANUARY, 2017**ULTRASOUND WHOLE ABDOMEN**

Liver is normal in size, outline with normal echotexture. No focal parenchymal lesion is noted. Hepatic veins and portal venous radicals are normal. IHBR is not dilated.

Bladder is well distended and reveals an echo-free lumen. No calculus is seen. No GB wall edema is seen. CBD is not dilated. Portal vein is normal.

Pancreas is normal in outline and showing normal echopattern. No evidence of any focal lesion or calcification is seen. MPD not dilated.

Spleen is normal in size and shows normal echopattern. No focal lesion is noted.

Both kidneys are normal in outline, shape, location, size and reveal normal echogenicity. The CM differentiation is maintained with maintained cortical thickness. Right sided moderate hydronephrosis is noted with non dilated upper ureter ---? Pelviureteric junction obstruction. No definite calculus is noted in the right kidney. No calculus or hydronephrosis is noted in left kidney. B/L ureters are not dilated. Cyst measuring 20mm noted in mid pole of right kidney. Another cyst measuring 35mm noted in the lower pole of left kidney.

No ascites is noted in the peritoneal cavity. No significant enlarged lymph nodes are seen.

No evidence of any pleural effusion was evident at the costophrenic angles.

Urinary Bladder is distended with thickened and irregular outline --- Cystitis. Foley's bulb is seen in situ. No definite calculus is noted.


Prostate is enlarged in size measuring 49 x 40 x 38mm & volume is 40gms & normal echogenicity. Median lobe is enlarged. Margins are regular.

IMPRESSION:

- ① **RIGHT SIDED MODERATE HYDRONEPHROSIS IS NOTED WITH NON DILATED UPPER URETER ---? PELVIURETERIC JUNCTION OBSTRUCTION.**
- ② **BILATERAL RENAL CORTICAL CYST.**
- ③ **BENIGN PROSTATIC HYPERTROPHY GRADE - II WITH ENLARGED MEDIAN LOBE.**
- ④ **CYSTITIS.**

Correlate clinically.

DR. RAMESH COEL
MB (RADIODIAGNOSIS)


DR. RAMESH SETHI
MB (RADIODIAGNOSIS)

WHOLE BODY CT SCAN

ULTRASOUND

COLOUR DOPPLER

DIGITAL X-RAY

PATHOLOGY

KINDLY CORRELATE CLINICALLY. NOT FOR MEDICO LEGAL PURPOSE

**Agra Diagnostic
Imaging Research
Centre**

(A UNIT OF AGRA CAT SCAN CENTRE)

Near Shree Talkies, Bye Pass Road, Agra-2
Ph.: +91-562-2520868, 4001264
Visit us : www.agradiagnostic.com

(H212-11)

PT. NAME: OMKAR GANGWAR 65 YRS/M
REF BY : DR. SHEKHAR VAJPEYI

DATE: 14-05-2017

NCCT UROGRAM

NON-CONTRAST ENHANCED HELICAL SECTIONS OF 5mm. THICKNESS OF KUB REGION WERE TAKEN.

THERE IS FEW SIMPLE RENAL CORTICAL CYSTS IN BOTH KIDNEYS LARGEST MEASURING 5.2 X 4.2 CMS IN LOWER POLE POSTERIORLY ON RIGHT SIDE AND OF SIZE 4.0 X 4.0 CMS IN MID POLE ANTERIORLY ON LEFT SIDE.

PELVICALYCEAL SYSTEMS OF BOTH KIDNEYS ARE MILDLY DILATED WITH NORMAL CALIBRE OF BOTH URETERS. NO CALCULUS IS SEEN.

BOTH ADRENAL GLANDS ARE NORMAL IN SIZE AND ATTENUATION.

URINARY BLADDER IS WELL DISTENDED. WALL THICKNESS IS NORMAL. NO EVIDENCE OF RADIO-OPAQUE CALCULUS IS NOTED.

PROSTATE IS MILDLY ENLARGED IN SIZE, SHAPE AND NORMAL IN ATTENUATION.

ABDOMINAL WALL MUSCULATURE AND FAT PLANES APPEAR NORMAL.
PELVIC MUSCULATURE AND VASCULATURE APPEAR NORMAL.
THERE IS NO PELVIC LYMPHADENOPATHY. THERE IS NO PELVIC ASCITES.

VISUALISED SPINE AND BILATERAL HIP JOINTS SHOW DEGENERATIVE CHANGES.

IMPRESSION:-

- SIMPLE RENAL CORTICAL CYSTS IN BOTH KIDNEYS LARGEST MEASURING 5.2 X 4.2 CMS IN LOWER POLE POSTERIORLY ON RIGHT SIDE AND OF SIZE 4.0 X 4.0 CMS IN MID POLE ANTERIORLY ON LEFT SIDE.
- MILDLY DILATED BILATERAL RENAL PELVICALYCEAL SYSTEMS WITH NORMAL CALIBRE OF BOTH URETERS. NO CALCULUS IS SEEN.

KINDLY CORRELATE CLINICALLY.

DR. DEEPSHIKHA GUPTA
MD (RADIOLOGICAL DIAGNOSIS)
CONSULTANT RADIOLOGIST

Wx
DR. WASEEM AKHTAR
MD (RADIOLOGICAL DIAGNOSIS)
CONSULTANT RADIOLOGIST

24x7
HELPLINE 7500001311
9917470450

THE SCIENCE OF RADIOLOGICAL DIAGNOSIS IS BASED ON THE INTERPRETATION OF VARIOUS SHADOWS PRODUCED BY NORMAL & ABNORMAL TISSUES & ARE NOT ALWAYS CONCLUSIVE FURTHER CLINICOPATHOLOGICAL CORRELATION IS NECESSARY. IN CASE OF ANY DISCREPANCY OR ANY TYPING OR MACHINE ERROR, PLEASE GET IT RECTIFIED IMMEDIATELY.


THANKS FOR THE REFERENCE, KINDLY LET US KNOW THE FOLLOW UP OF THE PATIENT

NOT VALID FOR MEDICOLEGAL PURPOSES.

DR. ROY'S
PATHOLOGY CENTRE

Address : 4/127, Bank Colony,
Near Sanjay X-Ray Centre, Bagh Farzana, Agra

(फ़ारज़ाना-12)



UPI/AGR/2005/AL/1634/2018-19

Net Amount 200

Date	18/05/2019	Srl No.	18	Sex	M
Name	MR CMKAR	Age	69 Yrs.	Mobile No.	
Ref. By	Dr. SHEKHAR VAJPEYI,, M.S. M.Ch. (Sr Consultant Uro)				

Test Name	Value	Unit	Normal Value
-----------	-------	------	--------------

BIOCHEMISTRY

BLOOD SUGAR RANDOM	103.7	mg/dl	70.0 - 170.0
SERUM CREATININE	✓ 1.12	mg/dl	0.7 - 1.4

**** End Of Report ****

DR. PREETI TYAGI
M.B.B.S., M.D. (Path.)

DR. SHUBHENDHU ROY
M.D. (Path. & Bact.)
Sr. CONSULTANT PATHOLOGIST

All tests have technical limitations. Collaborative clinicopathological interpretation is mandatory. In case of disparity test may be repeated immediately.
Sample Collection From Hospital & Home Contact No. Ph : 0562-2521482, Mob : 9412301040, 9358507378

Tulika Agarwal
(PATH.)



MEDICHECK PATHOLOGY LAB

AN ISO CERTIFIED LABORATORY

(सितम्बर-13)



Date: 18/05/2019 Srl No: 4001 Mob: _____
Pt Name: MR OMKAR Age: 69 Yrs. Sex: M
Ref By: Dr. SHEKHAR VAJPEYI M.S., M.Ch. OUT DOOR PATIENT

Test Name	Value	Unit	Normal Value
-----------	-------	------	--------------

CANCER MARKER

PROSTATE SPECIFIC ANTIGEN

PSA 0.48

ng/ml

NORMAL RANGE : 0 - 4
BORDER LINE : 4 - 10 ✓

Serum testing for PSA is a very important tool to screen for prostate cancer and to monitor therapy of this disease. PSA is prostate-specific but not cancer-specific and apart from prostate cancer, increased levels may be found in benign prostate hypertrophy, Prostatitis, increasing age, acute retention of urine, infection and prostate biopsy. PSA is rarely raised in healthy men and is absent in normal women. There is no PSA present in any other normal tissue form men or in patients with other cancers of the breast, lung, colon, rectum, stomach, pancreas or thyroid.

**** End Of Report ****

Reported by: BAL

Checked By: _____

Dr. Tulika Agarwal
MD (Path)
Regd No. 56603

All Tests have technical limitations. Corroborative clinicopathological interpretation is mandatory. In case of disparity test may be repeated immediately.

Phone: 011-26700478 (M) + 91 8267004781

Address: 202, 2420077 (M) + 91 8267004781 | Email: medicheckpathlab@gmail.com

Home Sample Collection: (M) + 91 8267004781

CMO Reg. No. - UP/AGR/AL/2209/12-11/12



laser
urology centre

(11/11/20 - 14)

DR. SHEKHAR VAJPEYI
M.S. M.Ch. (UROLOGY)
CONSULTANT UROLOGIST

10/5/19

Dr. Dinkar Gaurhae
69y

Dr. Vaidip wad

Dr. G. T.

is not taking medicine

1. P. SA
Use Am C
Bhaya
Shear

NCC URO
A & C
Caution

Repeat
29/11/20
L

लेजर यूरोलॉजी सेन्टर
रामरघु अस्पताल
संजय प्लेस के सामने, आगरा
Mob. : 9027422666
Timing (8 am to 7 pm)

डा. शेखर वाजपेयी
एम.एस., एम.सीएच. (यूरोलॉजी)
कन्सल्टेन्ट यूरोलॉजिस्ट



THEY WILL SAVE YOU



aser
urology centre

(संलग्नक-15)
14/5

DR. SHEKHAR VAJPEYI

M.S M Ch (UROLOGY)

CONSULTANT UROLOGIST

S 17

Dr. Omkar Gampwal
60y

C₁₁ Rapibf D

→ to combine.

uro for Rad HON

NCCr uro

- Schic acid
- Stalium
- Sceabim
- Bonea

↓

U. B. H

C₁₁ Rapibf D

oo

x 6 months

d

लेजर यूरोलोजी सेंटर

शंकरा अस्पताल

संजय प्लेस के सामने, आगरा

Mob : 9027422666 (8 am to 7 pm)

Ph : 0562-4025100 (7pm to 8 am)

डा. शेखर वाजपेयी

एम.एस., एम.सी.एच. (यूरोलॉजी)

कन्सल्टेंट यूरोलॉजिस्ट



BASS ULTRASOUND CENTRE

C-26, RAJENDRA NAGAR, NEAR BANK OF BARODA, BAREILLY.
PH.. 98375-45054, 2300904

(संज्ञक-16)

Dr. Ankur Bass

M.B.B.S., D.M.R.D.

Consultant Radiologist

MRI, CT Scan, X-ray &

Ultrasound Specialist

Ex-Registrar, Apollo Hospital Hyd.

● X-RAY ● ULTRASOUND ● COLOR DOPPLER

PATIENT'S NAME: MR. OMKAR GANGWAR
AGE/SEX: 67Y/M DATE: 10.08.17
REFERRED BY: DR. M.L. MAURYA M.B.B.S.
USG WHOLE ABDOMEN

LIVER :- Is normal in size and contours, shows diffuse increase in echogenicity of parenchyma. No focal mass lesion is seen. Hepatic and portal veins are normal. Intra-hepatic biliary radicles are not dilated.

GALL BLADDER :- Could not be seen - ? contracted.
-CBD is normal in caliber.

SPLEEN :- Is normal in size with homogenous parenchyma. No focal mass lesion is seen.

PANCREAS :- Is normal in size & echotexture. No mass / calcification is seen. Pancreatic duct is not dilated.

BOTH KIDNEYS:- Are normal in size, shape and position. Parenchymal echogenicity is normal. Corticomedullary differentiation is maintained. There is grade II dilatation of bilateral pelvicalyceal system and the visualized upper parts of both the ureters. No calculus is seen in either kidney.

URINARY BLADDER :- Is well distended with a volume of 396cc. No mass/calculus is seen. Walls are not thickened. Post void residual urine is insignificant in amount measures 16cc.

PROSTATE:- Is normal in size, contours and echotexture measures 31X36X30mm (18.7gms in weight).

-No significant pre/para-aortic lymphadenopathy is seen.

-No abnormal dilatation of bowel loops is seen.

-There is no evidence of ascites.

-No pleural effusion is seen.

OPINION :- USG FINDINGS ARE SUGGESTIVE OF FATTY CHANGES IN THE LIVER.

- BILATERAL GRADE II HYDRONEPHROSIS AND HYDROURETER UPPER PARTS.

-PLEASE CORRELATE CLINICALLY.

DR. ANKUR BASS

- Ultrasonography is an indirect investigation and has its own limitations. Its findings must be viewed in correlation with clinical observation and other investigations.
- All fetal anomalies may not be detected on Ultrasound.
- NOT FOR MEDICOLEGAL PURPOSE.



BASS ULTRASOUND CENTRE

C-26, RAJENDRA NAGAR, NEAR BANK OF BARODA, BAREILLY.
Mob. : 98373-45054

(11-12-17)

Dr. Ankur Bass

M.B.B.S., D.M.R.D.

Consultant Radiologist

MRI, CT Scan, X-ray &

Ultrasound Specialist

Ex-Registrar, Apollo Hospital Hyd.

X-RAY • 3D/4D ULTRASOUND • COLOR DOPPLER

PATIENT'S NAME: MR.OMKAR GANGWAR

AGE/SEX:69Y/M DATE: 10.08.18

REFERRED BY : DR.M.L.MAURYA M.B.B.S.

USG WHOLE ABDOMEN

LIVER :- Is normal in size, contours and echotexture. No focal mass lesion is seen. Hepatic and portal veins are normal. Intra-hepatic biliary radicles are not dilated.

- **GALL BLADDER** :- Is contracted. A calculus measuring approx 7.5mm is seen in the lumen casting posterior acoustic shadow. Walls are not thickened.

-CBD is normal in caliber.

SPLEEN :- Is normal in size with homogenous parenchyma. No focal mass lesion is seen.

PANCREAS :- Is normal in size & echotexture. No mass / calcification is seen. Pancreatic duct is not dilated.

BOTH KIDNEYS:- Are normal in size, shape and position. Parenchymal echogenicity is normal. Corticomedullary differentiation is maintained. There is grade II dilatation of the right pelvicalyceal system and the upper part of the right ureter. A calculus measuring approx 8.1mm is seen in the lower calyx of the left kidney. There is grade II dilatation of the left pelvicalyceal system. A cortical cyst measuring approx 52x47mm is seen in the middle part of the right kidney. Multiple cortical cysts are seen in the left kidney, largest measuring approx 14x12mm.

URINARY BLADDER :- Is moderately distended. No mass/calculus is seen. Walls are not thickened.

- **PROSTATE**:- Is enlarged in size, normal in contours and echotexture, measures 34x41x34mm (24.8cc in volume).

-No significant pre/para-aortic lymphadenopathy is seen.

-No abnormal dilatation of bowel loops is seen.

-There is no evidence of ascites.

-No pleural effusion is seen.

OPINION :- USG FINDINGS ARE SUGGESTIVE OF GB CALCULUS.

-BILATERAL GRADE II HYDRONEPHROSIS AND HYDROURETER UPPER PART.

-LEFT RENAL CALCULUS.

-BILATERAL RENAL CORTICAL CYSTS.

-GRADE I PROSTATIC ENLARGEMENT WITH SIGNIFICANT AMOUNT OF POST-VOID RESIDUAL URINE.

-PLEASE CORRELATE CLINICALLY.


DR. ANKUR BASS

- Ultrasonography is an indirect investigation and has its own limitations. Its findings must be viewed in correlation with clinical observation and other investigations.
- All fetal anomalies may not be detected on Ultrasound.
- NOT FOR MEDICOLEGAL PURPOSE.

ie : Mrs. DHAN DEVI GANGWAR
Female/65 Y-0 M-0 D
30/10/2021
Dr. MAZHAR HUSAIN, M.B.B.S, M.S., M.Ch, Med.Reg.No:-UPMFC/29767
NEURO SURGEON
SELF



PRESCRIPTION SLIP

Room No : T14 - THIRD FLOOR

Complaints

Physical Examination

Provisional Diagnosis

Nutritional Assessment
whenever required)

Investigation

Preventive Aspects

R
Tab NVM 1 X BD

Tab Gabapin-SR-450
1 X BD

2 Month

Tab Tridol-P
(Consultant)
1 X BD

Tab Neuroleind plus
1 amp 1 X BD
7 Injection

Act
1) X-Ray
L5/S1 spine
AP Differsia
Lat In Extensio
2) MRI Lumbar
spine

nil

SAHARA HOSPITAL, Viraj Khand, Gomti Nagar, Lucknow - 226010

24x7 HOUR HELP DESK FOR EMERGENCY AND TRAUMA CARE CALL: 0522 6780001/0002

दवाओं की विश्वसनीयता हेतु अस्पताल की फॉर्मसी (दवाखाना) से ही दवाएं लें।

OPD Registration and Appointment Call : 0522 6782159/63
from 9 am. to 5 pm. (प्रातः 9 बजे से सायं 5 बजे तक)
Telefax: +91 522 6782110, Website : www.saharahospitals.com

सुविधाएं-24x7 फॉर्मसी (दवाखाना), पैथालॉजी एवं रेडियोलॉजी

ओ.पी.डी. समय: सोमवार से शनिवार प्रातः 9 बजे से सायं 5 बजे तक (OPD TIMING: MONDAY TO SATURDAY 9 am. to 5 pm.)
परामर्श की वैधता 5 दिनों के लिए मान्य (CONSULTATION IS VALID FOR 5 DAYS)

Cashless facility for insured patients/Home sample pathology: 0522 6781841/1842
Cost effective packages 0522 6782111, Ambulance 24x7: 0522 6780001/0002

Sahara Hospital:

Khand Gomti Nagar, Lucknow-226010 India.

2-6780001, 6780002, OPD Aprt:0522-6782159, Fax:0522-6782110

mail:hospital@hqsimil.sahara.co.in,Website:www.saharahospitalas.com



(११११३-१९)

Bill cum Cash Receipt

No : 21-22CA/164510 Cash Receipt No : 21-22CA/159348
ID : 21070804 Bill Date/Time : 30/10/2021 10:25 hrs.
Patient Name : M/s. DHAN DEVI GANGWAR Gender/Age : Female/65 Y- 0 M- 0 D
referred By/Dr. : Dr. MAZHAR HUSAIN
ponsor : SELF
address : A/77 SURESH SHARMA NAGAR DISTT , BAREILLY, Uttar Pradesh, INDIA
Contact No : 9415668426

SL#	Service Particulars	Medical Provider	Units	Amount (Rupees)
1	CONSULTATION NEUROSURGERY FIRST CONSULTATION (M.HU)	Dr. MAZHAR HUSAIN	1	1200.00
Total				1200.00
Net Amount				1200.00
Amt Received				1200.00
Balance Amount				0

By Cash : ₹1200.00
(Rupees) One Thousand Two Hundred Only

Remarks:

* Discrepancy noticed if any be informed to Hospital within three days

To Download Pathology Report Please Go to URL : <http://115.113.91.222/Home.aspx>

** If you are unable to download report please visit to Sahara Hospital
To view COVID-19 report on Government portal -
<https://labreports.upcovid19tracks.in/>

(Signature)

Stay Vaccinated Stay Safe
24*7 Radiology (CT,MRI,X-RAV) Pathology & Emergency services available
Customized Health Packages

Registered Office:Sahara India Point, CTS 40-44,Swami Vivekanand Road,Goregaon(West),Mumbai-400104
Printed By: 530.F.C.11777
Prepared By: 530.F.C.11777

Printed at: 30/10/2021 10:21 AM (GMT)



METRO HOSPITAL & CANCER INSTITUTE

(A Unit of Metro Medical Services Ltd.)

CIN : U24232DL1988PLC184955

OPD INITIAL ASSESSMENT

ADULT INITIAL ASSESSMENT (EMERGENCY)

(HMD-20)

QUALITY CERTIFICATIONS



NAME OF PATIENT Dhan Devi Gangul

AGE/SEX 60y/f

ID NO. 2991002343

DATE / IN TIME

PRESENT COMPLAINT :

H/o ↑ SOB - 3-4 years
↑ exertional Dyspnea
No fever
No weight loss

INVESTIGATION / TREATMENT / PREVENTIVE CARE / NUTRITION ADVISED

Plan -12^{mo} Dr. Gangul

- CBC / LFT

- PFT EDLCO₂ & SD Reviewing Mild Pt

PAST HISTORY: HRCF Multiple MIAP
World Calcified nodules

- HRCF Chut Imp →
Emp

FAMILY HISTORY: Mild fibrotic nodules

H/o AP₂ ⊕
EXAMINATION: ADH's fever (-)

R

Sp₂ 97% H/o Bimanual basal Sep ⊕
Moist - 20mm ⊕

Lab Isosole Leucy R/D (Asp⁺ Refurb)

PR = SB 20 B/LV ⊕

T. AB₂ 100 mg R/D

Cut = B/LC NY

↑. Montek-LC 1 HD

BP = 140/80

Neb₂ Formicort (1.0) R/D

Neb₂ Duhe to Shalmy x 5 days
than 50.

DIAGNOSIS: Imp! ? COPD
? ACS
? GERD

Review reports.

DRUG ALLERGY :

(DOCTOR SIGNATURE)

OUT TIME

Dr. Gangul

FOR OPD APPOINTMENT: +91 11 4928 6666

Next Followup:

NUTRITIONAL SCREENING: Wt. Loss Loss Of Appetite Muscle Wasting Delay Wound Healing Lethargy Decrease Mobility

Pain scale

0. NO PAIN 02 Mild Pain 04 Annoying Pain 06 Moderate Pain 08 Severe Pain 10 Worst Pain

Regd. Office : 21, Community Centre, Preet Vihar, Delhi-110092

MHCI/CL/0001 (Rev. No. 01)

Phone : +91 11 2246 0000, 4928 6666, Fax : +91 11 2252 6671 | E-mail : metropreetvihar@metrohospitals.com



METRO HOSPITAL & CANCER INSTITUTE

(A Unit of Metro Medical Services Ltd.)

CIN : U24232DL1988PLC184955

OPD INITIAL ASSESSMENT

ADULT INITIAL ASSESSMENT (EMERGENCY)

(H-10-15-21)

QUALITY CERTIFICATIONS



NAME OF PATIENT Dhan Devi Pangwal

AGE/SEX 60yF

ID NO. 2019002343

DATE / IN TIME 5/3/19

PRESENT COMPLAINT :

T SOB - 3-4 years.
↑ in Cant. Durm.
No fever / wt loss / Appetite loss.

↑ Hb ARS (+)
PAST HISTORY:
↑ Hb GERD (+)

FAMILY HISTORY:

Diabet - non diabetic MHP

EXAMINATION

Mauch = 2mm.
Eds (+) ↑ Hb BMF & per (+)
Sunny (+)

SpO₂ = 97%

PR = 82

Chest = Bell Nuss

BP = 140/80

DIAGNOSIS: Sup Mild COPD
? OSA

DRUG ALLERGY: GERD
HIN

INVESTIGATION / TREATMENT / PREVENTIVE CARE / NUTRITION ADVISED

CRP = 12.2

Wt = 68 kg

APF - Mild Ob.

↑ Hb ARS (+)

R

T. Esograms - L 1 BID 30min before Meal

Neb c Formicest (1:0) 1 BID - Run. 2 times after

Kehec Durho KD (505) 3

T. Montek

T. Montegans - XL 1 Hl. 2x

P. ABJO SR 1 OD (12pm)

T. Bonagen 1 OD

Diet & life style Modification

Plan for sleep study

(DOCTOR SIGNATURE)

T. Telma Gony

2 months
OPT TIME

FOR OPD APPOINTMENT: +91 11 4928 6666

Next Followup:

NUTRITIONAL SCREENING: Wt. Loss Loss Of Appetite Muscle Wasting Delay Wound Healing Lethargy Decrease Mobility

Pain scale



0. NO PAIN



02 Mild Pain



04 Annoying Pain



06 Moderate Pain



08 Severe Pain



10 Worst Pain

Regd. Office : 21, Community Centre, Preet Vihar, Delhi-110092

MHCI/CL/0001 (Rev. No. 01)

Phone : +91 11 2246 0000, 4928 6666, Fax : +91 11 2252 6671 | E-mail : metropreetvihar@metrohospitals.com



METRO

HOSPITALS & CANCER INSTITUTE

(a unit of Metro Institutes of Medical Sciences Pvt. Ltd.)

Diseases 21, Community Centre, Preet Vihar, Delhi-92-110092

Tel: +91 11 2246 0000, 2201 9855, 22520480 Fax : +91 11 22526671

METRO CENTRE FOR RESPIRATORY DISEASES COMPLETE PFT WITH DIFFUSION STUDY TEST REPORT

05 MARCH 2019

PATIENT INFORMATION: -

NAME: MRS. DHAN DEVI GANGWAL

AGE/SEX: 60/YEARS/F

PFT NO: 2019002343 REFERRED BY : DR. RAHUL K SHARMA

HEIGHT: 144 CMS, WEIGHT: 68 KGS

CLINICAL DIAGNOSIS: COPD

NON-SMOKER: BMI :32.8

INTERPRETATION:

Comprehensive lung function Testing performed on MEDISOFT,S HYPAIR PFT System with optimal patient co-operation. Three consecutive tests were performed and the best curve and the best test was used for analysis . All the tests qualified ATS criterion of acceptability.

Dynamic lung function revealed " Mild Obstructive Ventilatory Defect". FVC is 90% of the predicted normal, FEV₁ is 81% of the predicted normal. FEV₁/FVC ratio is 74.47% FV curve are suggestive of obstructive defect.

Repeat evaluation after Salbutamol (2.5 mg) Nebulizer showed non responsive airways.

Single breath diffusion study revealed diffusion capacity i.e. Tlco being 18.13 Hb.L (100% of the predicted normal.) VA is 111% of the predicted normal . Kco (DLCO/L) is 94% of the predicted normal.

Lung Volumes show VC is 77% ERV is 63% , IC is 96% and FRC is 135% of the predicted

IMPRESSION:

- Patient has " Mild Airflow Obstruction "with non responsive airways at the present testing.& Normal diffusion capacity at the present testing.

ADVICE:

- Patient needs bronchodilator and anti-inflammatory therapy and repeat evaluation after 4-8 week of adequate treatment.

Dr. Deepak Talwar

MD,DTCD,DNB (Respiratory Diseases)

DM (Pulmonary & Critical Care Medicine) MNAMS

FNCCP,FCCS, FCCP (USA)

Director:-

Pulmonary, Sleep, Allergy & Critical Care

Dr. Rahul Kumar Sharma

MD, DNB, DM (Pulmonary & Critical Care

Senior Consultant

Pulmonary, Sleep, Allergy & Critical Care

Please note that the report given is that of the procedure done today and needs to be assessed in conjunction with the clinical findings and other tests. is not for medico legal purpose. No record of this report is kept with the physician.

TETRO CENTRE FOR RESPIRATORY DISEASES

21, COMMUNITY CENTRE, PREET VIHAR, DELHI.

DR. DEEPAK TALWAR MD,DTCD, DNB, DM (PULMONARY & CRITICAL CARE MEDICINE)

PULMONARY FUNCTION TEST REPORTName- F Name : GANGWAL MRS. DHAN DEVI
Patient number : 2019002343Sex : F
Height (cm) : 144
Weight (kg) : 68Exam date : 3/5/2019
Physician : DR. RAHUL.K SHARMA
B.M.I. : 32.8

Age : 60

Smoker : NON

DYNAMIC LUNG VOLUMES & FLOW RATES

	PRED	LLN PRED	PRE OBSERVED	% PRED	POST OBSERVED	% PRED	% CHANGE
VC(L)	1.92	1.22	1.73	90	1.78	93	3
EV1(L)	1.58	0.96	1.29	81	1.34	84	4
EV 3s(L)	---	---	1.56	---	1.65	---	0
EV1/FVC(%)	77.67	66.96	74.47	96	75.07	97	1
VEF(L/S)	5.00	3.52	3.38	68	4.00	80	18
VEF(L/S)	2.67	1.28	1.71	64	1.88	70	10
VEF75(L/S)	4.73	3.60	3.12	66	3.43	72	10
VEF50(L/S)	3.18	1.37	1.55	49	1.55	49	0
VEF25(L/S)	1.12	-1.10	0.30	26	0.34	31	16
FVC-ins(L)	---	---	1.66	---	1.64	---	-1
PIF(L/S)	---	---	3.95	---	2.92	---	-26
PI50(L/S)	---	---	3.86	---	2.80	---	-28
Texp(Sec)	---	---	6.81	---	6.22	---	-9

SVC

Tidal Vol(L)	---	---	1.10	---	---	---	---
VC(L)	1.87	1.17	1.45	77	---	---	---
IRV(L)	---	---	---	---	---	---	---
ERV(L)	0.72	---	0.45	63	---	---	---
IC(L)	1.15	---	1.10	96	---	---	---

MVV

EV(L/min)	45.00	---	---	---	---	---	---
RF(#/min)	---	---	---	---	---	---	---

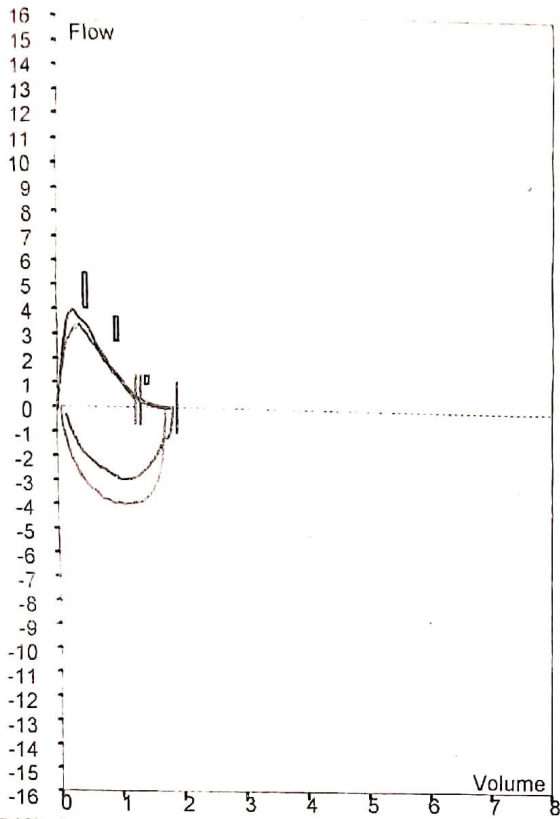
DIFFUSION TEST

Tlco(mL/mmHg/Min)	18.21	16.29	18.97	104	---	---	---
Tlco (Hb)(L)	18.21	16.29	18.13	100	---	---	---
Va(L)	3.71	---	4.13	111	---	---	---
Kco(DLCO/L)	4.90	---	4.60	94	---	---	---
Vol Insp (L)	1.87	1.39	1.54	82	---	---	---
RV'sb(DLCO/L)	1.57	1.21	2.59	165	---	---	---
FRC'sb(L)	2.29	1.46	3.08	135	---	---	---

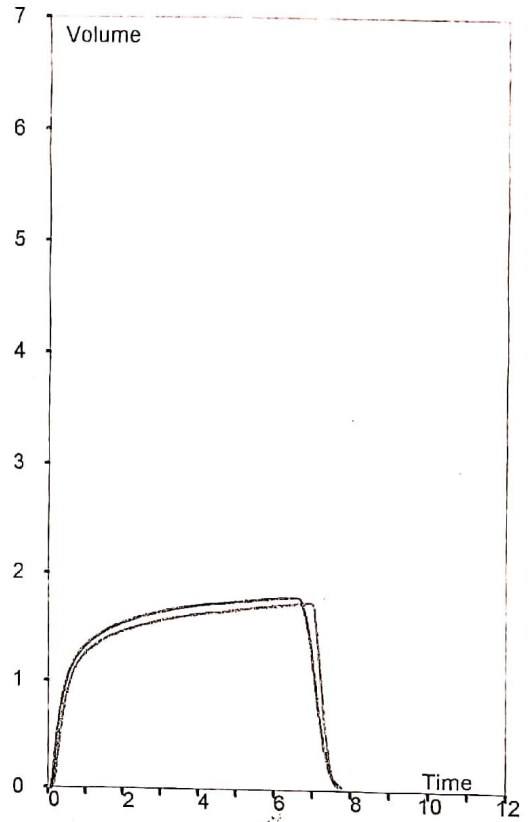
(संलग्नक-24)

L Name- F Name : GANGWAL MRS. DHAN DEVI
Identity number : 2019002343

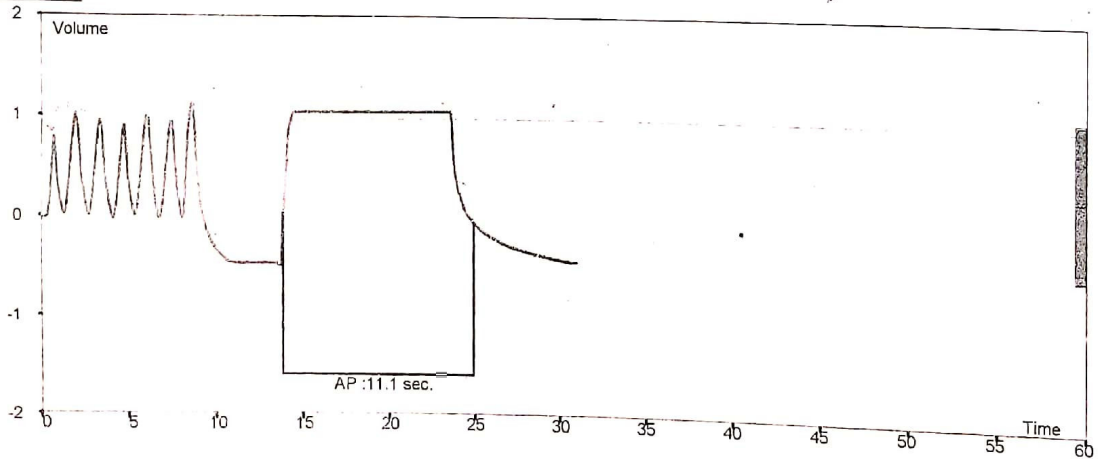
FLOW VOLUME LOOP



VOLUME TIME GRAPHIC



Diffusion



Medi sub Expir 1.28.20



METRO HOSPITAL & CANCER INSTITUTE

(A Unit of Metro Medical Services Ltd.)

CIN : U24232DL1988PLC184955

OPD INITIAL ASSESSMENT

ADULT INITIAL ASSESSMENT (EMERGENCY)

(610505-25)

QUALITY CERTIFICATIONS



M-0016

ICVQA

NAME OF PATIENT Dhan Devi Bangwal

AGE/SEX 60y/f

ID NO. 2019002343

DATE / IN TIME 5/3/19

PRESENT COMPLAINT :

T SOB - 3-4 years
↑ on exertion
No fever / wt loss / Appetite loss.
↑ Ho ARS ⊕
PAST HISTORY:
Ho GERD ⊕

INVESTIGATION / TREATMENT / PREVENTIVE CARE / NUTRITION ADVISED

ECG = 12.2
APF - Mild DM.
↑ RBC count →

wt - 68 kg

FAMILY HISTORY:

DM - non diabetic

EXAMINATION lauche = 2mm

EDX ⊕ Ho BMF ⊕
Surre ⊕

SpO₂ 97%

PR = 82

Chest = BIL NLS

BP = 140/80

- T. Esoprens - L 1 BID 30min before Meal
- Neb C Formoterol (1.0) 1 BID - Runi Mouth spray
- Levo Dulo XL (50) 3
- T. Montek
- T. Montegran - XL 1 HD 2h
- T. ABJO SR 1 OD (12pm)
- T. Bonagen 1 OD
- Diet & life style modification

DIAGNOSIS: Sup Mild COPD
? OSA

DRUG ALLERGY: GERD
HIN

(DOCTOR SIGNATURE)

T. Telma Kony

2 months
OUT TIME

FOR OPD APPOINTMENT: +91 11 4928 6666

Next Followup:

NUTRITIONAL SCREENING: Wt. Loss Loss Of Appetite Muscle Wasting Delay Wound Healing Lethargy Decrease Mobility

Pain scale



0. NO PAIN



02 Mild Pain



04 Annoying Pain



06 Moderate Pain



08 Severe Pain



10 Worst Pain

Regd. Office : 21, Community Centre, Preet Vihar, Delhi-110092

MHCI/CL/0001 (Rev. No. 01)

Phone : +91 11 2246 0000, 4928 6666, Fax : +91 11 2252 6671 | E-mail : metropreetvihar@metrohospitals.com



METRO HOSPITAL & CANCER INSTITUTE (फर्मास्यूटिक्स-२६)

(A Unit of Metro Medical Services Ltd.)

CIN : U24232DL1988PLC184955

OPD INITIAL ASSESSMENT

ADULT INITIAL ASSESSMENT (EMERGENCY)



NAME OF PATIENT: Dhan Devi Gargwal.

AGE/SEX: 60y F.

ID NO. 22101002343

DATE / IN TIME

<p>PRESENT COMPLAINT: <u>tlg 1 1/2 - 3 years</u> <u>↑ on last admission</u> <u>No fever</u> <u>No soft stool.</u></p>	<p>INVESTIGATION / TREATMENT / PREVENTIVE CARE / NUTRITION ADVISED</p> <p><u>Plan 12-0</u> <u>- CBC/MP</u> <u>- PFT & ICD & SD Examination</u> <u>Med/OA</u></p> <p><u>TRT cont - Imp →</u> <u>Emp</u></p> <p><u>Dr. Gargwal</u></p>
<p>PAST HISTORY: <u>HRT - Menopausal</u> <u>Nov 10</u> <u>Calcif and steroids.</u> <u>Med/Phyto/Mod/Ins</u></p>	<p>EXAMINATION: <u>tlg. H&T (N)</u> <u>tlg. Bowel</u> <u>Sp 99%</u> <u>PR = SK</u> <u>Ext = RL NY</u> <u>Bp 2 140/80</u></p>
<p>DIAGNOSIS: <u>tlg 1 1/2 yrs</u> <u>CRON</u></p> <p>DRUG ALLERGY:</p>	<p>Next Followup:</p> <p><u>tlg 1/2</u> <u>Job 1/2 hr</u> <u>T. Apto 100 mg BID</u> <u>7. Pantek-1c 1tg</u> <u>Medi forecast (Nov) BID</u> <u>Medi Distri to Shriy. & X-ray</u> <u>than 1st.</u></p> <p>DOCTOR SIGNATURE: <u>[Signature]</u></p> <p>OUT TIME: <u>11</u></p>

FOR OPD APPOINTMENT: +91 11 4928 6666

NUTRITIONAL SCREENING: Wt. Loss Loss Of Appetite Muscle Wasting Delay Wound Healing Lethargy Decrease Mobility

Pain scale: 0 No Pain 02 Mild Pain 04 Amoying Pain 06 Moderate Pain 08 Severe Pain 10 Worst Pain

Regd. Office : 21, Community Centre, Preet Vihar, Delhi-110092
 Phone : +91 11 2246 0000, 4928 6666, Fax : +91 11 2252 6671 | E-mail : metropreetvihar@metrohospital.com
 MHCI/CL/0001 (Rev. No. 01)

- Fellow American College of Chest Physicians (USA)
- Member American Academy of Sleep Medicine
- Member American Thoracic Society
- Member European Respiratory Society
- Life Member Indian Society for Critical Care Medicine
- Life Member National College of Chest Physician New Delhi
- Life Member Indian Chest Society
- Life Member Indian Medical Association
- Regn. No. : 28428

1st visit

Smt Dhandevi Gangwar
65 years F.

2021

COPE HTN
OSA, GERD
ring during sleep.

c/o cough & little white sputum
Dyspnoea - at mild exertion
Dysstasia

DM

moderate
OSA - 10/14/10
Adv: AHI 18.2
Supine AHI 22.6
Apnea Hypopnea Index 27.9%

advised inhalers - nowadays
not prescribed

ENT
Sinus
NOSE
NOSE

Use CPAP during sleep
Pulm Rehab, & WP

- X-ray chest PA view
- CBC

- Roped up

- fluticone 2mg b.i.d

3/5/19
FVC 90%
FEV1 81%
FEV1/FVC 74.47
TLC 105%

CT 20/11/18
Fiberoptic bronchoscopy
Small mediastinal lymph nodes

11/2/21
Hb 12.8
TLC 105
PFT 100%

- Levofloxacin
2mg b.i.d

vital please

wt - 74 kg
BP - 172/85 mmHg

Calmit LC
Modabrat 200
Formosol Synchronon
200, 2mg b.i.d
(Rinse mouth after)

Pulm - 79%
SpO2 - 98%
Temp - 97.8°F
RR - 26/min

ENT
ENT
ENT
ENT

Last visit CT 10/10/21

TOLL No. : 1860 333 33 33

- Synchronon D

Ph. : 0522-2977777, 4042888, 8004024365, 9196024365, E-mail : midlandlko@gmail.com, (कृपया सभी पर्व व रिपोर्ट साथ लाये)
CONSULTATION TIMING : MONDAY TO SATURDAY (12.00 AM TO 10.00 PM), SUNDAY CLOSED

- Telicast A

- Fellow American College of Chest Physicians (USA)
- Member American Academy of Sleep Medicine
- Member American Thoracic Society
- Member European Respiratory Society
- Life Member Indian Society for Critical Care Medicine
- Life Member National College of Chest Physician New Delhi
- Life Member Indian Chest Society
- Life Member Indian Medical Association
- Regn. No. : 28428

Tue 16.Mar.2021 20:20

Devi, 65Y/F
 Uttar Pradesh, Mob: +919415668426
 MID No: , R.No:
 visited on:

20/80 mmHg	Pulse: 66 bpm	Weight: 72 Kg
Temperature: 97.4 °F	Respiratory Rate: 22 bpm	SPO2: 97 %

Dr. Prabhat K. Sahai
 MBBS, DIP. PSG/SLEEP MEDICINE
 (Edinburgh, U.K.)
 Reg. No. : 43048

Complaint: Difficulty Breathing for 4 Months
 Dyspnea on light walk, Cough, White
 sputum, Fatigue, Weakness, Bloating,
 Hypertension
 Previous X Ray/MRI etc.: YES
 Additional Notes: Last visit-11/2/21

Better
 Cough Throat irritation | x 3 days
 Dyspepsia ⊕

↓ with Pulm Rehab

ACO/COPD
 HTN, OSA EF 65%
 mild TR
 Non DM ⊖

1. Use CPAP during sleep
2. Combination Aq 2 puffs 2 times/day
 fluticone 2 spray once/day
 each side
3. Levlin Synchronbreath
 2 puffs 800/600
 + Foracort Synchronbreath
 200 2 puffs x 200
 (since month after it)
4. Sompraz D 800
5. Calrit LC 800
 + Dr 60 a once/month
6. Telikast 800

7. Wakefast lozenges
 x 800 → 24

⊕ 800 Asti 0/4/2000
 with Revigen

2000

16/3/21

TOLL No. : 1860 333 33 33

Ph. : 0522-2977777, 4042888, 8004024365, 9196024365, E-mail : midlandlko@gmail.com, (कृपया सभी पर्व व रिपोर्ट साथ लायें)
 CONSULTATION TIMING : MONDAY TO SATURDAY (12.00 AM TO 10.00 PM), SUNDAY CLOSED



Powered By Evolko

Page 1 of 1



Name:	DHAN DEVI GANGWAR	Lab NO:	012106160191
Age/Sex:	64 Y O M O D /Female	Test Date:	16-Jun-2021
Referred By:	Dr. V K KHETAN MS ORTHO	Report Date:	16-Jun-2021

MRI LUMBAR SPINE WITH SCREENING OF WHOLE SPINE & B/L SI JOINTS
TECHNIQUE: AXIAL: T2WI, SAGITTAL: T1 & T2 WI, CORONAL: STIR.
FINDINGS:

Lumbarization of S1 vertebra.

Mild straightening of lumbar lordosis noted. Few marginal anterior osteophytes and schmorl's nodes at lower lumbar levels with patchy fatty marrow changes along endplates.

Disc dessication and diffuse disc bulge at L4-5 and L5-S1 levels causing mild canal stenosis, indentation over ventral thecal sac, B/L neural foramina & B/L exiting nerve roots.

Disc dessication and mild diffuse disc bulge at L1-2, L2-3 and L3-4 levels without significant canal stenosis/ neural foramina narrowing/ radiculopathy

Spinal canal diameters (in mm) at disc levels are-

L1-2	L2-3	L3-4	L4-5	L5-S1
16	15	16	12	10

Rest of the IV discs & vertebrae are unremarkable.

Posterior bony elements, facet joints and rest of B/L neural foramina are normal.

Rest of thecal sac is adequate to accommodate the intraneural component. Lower part of the spinal cord & conus medullaris are normal.

Para spinal soft tissues are normal. B/L sacroiliac joints are normal. No infective/ mitotic lesion.

Screening cervical spine reveals altered curvature, marginal anterior osteophytes at lower levels with patchy fatty marrow changes along endplates and reduced disc space height, disc dessication and diffuse disc bulge at C3-4, C4-5, C5-6 and C6-7 levels causing mild indentation over ventral thecal sac, B/L neural foramina & B/L exiting nerve roots.

Screening dorsal spine reveals few marginal anterior osteophytes at lower levels with patchy fatty marrow changes along endplates.

Note: Impression is a professional opinion & not a diagnosis. All modern machines/procedures have their limitations, if there is a variance clinically this examination may be repeated or reevaluated by other investigations. If test results are alarming or find any typographical error then contact the laboratory immediately for possible remedial action.

Focus Helpline
731-098-7005


www.focushealthcareindia.com
focushealthcarebly@gmail.com


 Registered Office:- 116 D, Gulmohar Park, Rajendra Nagar, Bareilly
 Corporate Office:- F19/D2, Sunshine, Sector 78, Noida (U.P.)



Name:	DHAN DEVI GANGWAR	Lab NO:	012106160191
Age/Sex:	64 Y O M O D /Female	Test Date:	16-Jun-2021
Referred By:	Dr. V K KHETAN MS ORTHO	Report Date:	16-Jun-2021

IMPRESSION

- LUMBARISATION OF S1 VERTEBRA.
- MILD STRAIGHTENING OF LUMBAR LORDOSIS NOTED. FEW MARGINAL ANTERIOR OSTEOPHYTES AND SCHMORL'S NODES AT LOWER LUMBAR LEVELS WITH PATCHY FATTY MARROW CHANGES ALONG ENDPLATES.
- DISC DESSICATION AND DIFFUSE DISC BULGE AT L4-5 AND L5-S1 LEVELS CAUSING MILD CANAL STENOSIS, INDENTATION OVER VENTRAL THECAL SAC, B/L NEURAL FORAMINA & B/L EXITING NERVE ROOTS.
- DISC DESSICATION AND MILD DIFFUSE DISC BULGE AT L1-2, L2-3 AND L3-4 LEVELS WITHOUT SIGNIFICANT CANAL STENOSIS/ NEURAL FORAMINA NARROWING/ RADICULOPATHY
ADV - CLINICAL CORRELATION AND FOLLOW UP STUDY.


Dr. Mohit Agarwal
MBBS, MD (Radiodiagnosis).
Ex-Safdarjung Hospital & VMHC, New Delhi.
Consultant Radiologist


Dr. Manali Agarwal
MBBS, MD (Radiodiagnosis)
IMS, BHU

Note: Impression is a professional opinion & not a diagnosis. All modern machines/procedures have their limitations, if there is a variance clinically this examination may be repeated or reevaluated by other investigations. If test results are alarming or find any typographical error then contact the laboratory immediately for possible remedial action.

 Focus Helpline
731-098-7005

 www.focushealthcareindia.com
focushealthcarebly@gmail.com

 Registered Office:- 116 D, Gulmohar Park, Rajendra Nagar, Bareilly
Corporate Office:- F19/02, Sunshine, Sector 78, Noida (U.P.)



Respiratory, Critical Care & Specialist for Sleep Medicine

MD, FCCP (USA)
Respiratory, Critical Care & Specialist for Sleep Medicine
Fellow American College of Chest Physicians
Fellow American Society of Sleep Medicine
Member American Thoracic Society
Member European Respiratory Society
Life Member Indian Society for Critical Care Medicine
Life Member National College of Chest Physicians
Life Member Indian Chest Society
Life Member Indian Medical Association
- Regn. No. : 28428

APRIVA MEDICARE PVT LTD)

10/21

Mrs. Dhan Devi Mangwar

Age - 63y/f

Visit - 21/10/21

AECOPD
HTN
CSH
GERD

Chronic cough & sneezing attack
w/ast
= MAD

MBBS DIP PSYC/SLEEP MEDICINE
(Edinburgh, U.K.)
Reg. No. 43044

Pulmonary Rehabilitation

1. use nasal CPAP during sleep & humidifier
2. levamis 2puffs 4x daily
+ Foracort 200 2puffs 4x daily
+ Chlorine mouth spray
+ Tiotna 2puffs 2x daily

Ref to Neurologist/Neurophysiologist

Alprazolam 114

WT - 76 Kg
B.P. - 130/70 mmHg
SpO₂ - 97% (R/A)
PR - 69 bpm
RR - 22 b/m
Temp - 97.8°F

T₃, T₄, TSH ⊕
lipid profile ⊕
KFT, LFT
Total IgE
PFT
HbA1C
Chung BT

Calcit LC
+
28/10/21

3. Alprazolam 2x 1mg
4. Sompraz 30 2x
5. Combimax Aq 2mg orally
6. Telekast f 200
7. Lupitus SF 5mg



विनय कुमार अग्रवाल

MD, DM, (AIIMS, New Delhi)
सीनियर न्यूरोलोजिस्ट

- Registration No. UP 32117
- MEMBER - AMERICAN ACADEMY OF NEUROLOGY
 - MEMBER - AMERICAN ASSOCIATION OF NEUROMUSCULAR & ELECTRO DIAGNOSTIC MEDICINE
 - MEMBER - AMERICAN HEADACHE SOCIETY
 - MEMBER - THE MOVEMENT DISORDER SOCIETY (INTERNATIONAL)
 - MEMBER - WORLD STROKE ORGANISATION

प्रगति मेटरिटी होम एवं इनफर्टिलिटी सेन्टर, पी-5/4, दीन दयाल पुरम, स्टेडियम रोड, सेंट प्रॉक्सिम स्कूल के सामने, बरेली।
फोन : 08449044889, 0581-2302978

समय-प्रातः 11:00 से सांय 5:00 बजे तक

दिनांक 05 JUL 2021

पूर्व परामर्श तिथि

(संलग्नक-32)

घन देवी

62y/f

40 kv u Radicular pain (nondermatomal)

= Lumbar

(T12 level)

(Lof Dr Khatam)

Dr. D.S. Gangwan

Adv.

Recd adv by Dr D.S. Gangwan.
MS.

Tea PEGANT

1/2 गोजली रात

↓ x की डि 2 लर क

खगोली रात

x 26/3/21

यह पर्चा केवल छः दिन के लिए मान्य है। (पहले दिन को मिलाकर) रविवार पूर्ण अवकाश

ओ.पी.डी. परामर्श शुल्क केवल ओ.पी.डी. समय में ही मान्य है।

पूर्व क्लीनिक : ई-3, टीबरी जय कॉम्प्लेक्स, सुद धर्म काँटा पौराहे के पास (प्रेमनगर), बसन्त (तारा टाकीज के सामने, मैकनियर रोड, स्टेट बैंक के बगल में, बरेली (30900)

P.T.O.

Societies Regn. No. 1335/2005

CMO Regn. No. CMO/ST/03 dt. 05.08.03

(Under Ministry of Social Justice and Empowerment, Govt. of India)



U.P. SPINAL INJURIES CENTRE

(लखनऊ-33)

(Specialised treatment for Spine & Back ache Problems)

5TH KM. FROM SATELLITE BUS STAND,
PILIBHIT BYE-PASS ROAD, BAREILLY. - 243 006
Phone & Fax No. : 0581-2526400

Sl. No. _____

Name..... Dhan Dey Age..... 65 M/F

S/o, W/o, D/o..... Om Kar

Address..... S. S. Nagar D/2

Consultant..... _____

OPD-CARD

Regd. No..... 1897

131 AUG 2021

Dr. D.S. Gangwar
M.S. (Ortho)
Orthopaedic Surgeon
U.P. Spinal Injuries Centre, Bareilly.

For (IV) 15, 20, 25, 30, 35, 40, 45, 50, 55, 60, 65, 70, 75, 80, 85, 90, 95, 100, 105, 110, 115, 120, 125, 130, 135, 140, 145, 150, 155, 160, 165, 170, 175, 180, 185, 190, 195, 200, 205, 210, 215, 220, 225, 230, 235, 240, 245, 250, 255, 260, 265, 270, 275, 280, 285, 290, 295, 300, 305, 310, 315, 320, 325, 330, 335, 340, 345, 350, 355, 360, 365, 370, 375, 380, 385, 390, 395, 400, 405, 410, 415, 420, 425, 430, 435, 440, 445, 450, 455, 460, 465, 470, 475, 480, 485, 490, 495, 500, 505, 510, 515, 520, 525, 530, 535, 540, 545, 550, 555, 560, 565, 570, 575, 580, 585, 590, 595, 600, 605, 610, 615, 620, 625, 630, 635, 640, 645, 650, 655, 660, 665, 670, 675, 680, 685, 690, 695, 700, 705, 710, 715, 720, 725, 730, 735, 740, 745, 750, 755, 760, 765, 770, 775, 780, 785, 790, 795, 800, 805, 810, 815, 820, 825, 830, 835, 840, 845, 850, 855, 860, 865, 870, 875, 880, 885, 890, 895, 900, 905, 910, 915, 920, 925, 930, 935, 940, 945, 950, 955, 960, 965, 970, 975, 980, 985, 990, 995, 1000

- Rx Physiotherapy LT
- Acetylsalicylic acid 100
- B10 D3 fem 100
- Mometasone 100
- B12 100
- R1A 1WK
- ~~PTD~~ Mobility 1WK
- 31/8/21

Valid for 7 days / 7 दिनों के लिए मान्य

Societies Regn. No. 1335/2005

CMO Regn. No. CMO/ST/03 dt. 05.08.03

(Under Ministry of Social Justice and Empowerment, Govt. of India)



U.P. SPINAL INJURIES CENTRE

(नमक-34)

(Specialised treatment for Spine & Back ache Problems)

5TH KM. FROM SATELLITE BUS STAND,
PILIBHIT BYE-PASS ROAD, BAREILLY. - 243 006

Phone & Fax No. : 0581-2526400

OPD-CARD

Sl. No.

Regd. No. 2270

Name

Dhan Singh

Age 65 M/F F

Sp, W/O, D/O

son Deekoo

Address

S.S. Nagar

Consultant

Dr. D.S. Gangwar

M.S. (Ortho)

Orthopaedic Surgeon
U.P. Spinal Injuries Centre, Bareilly.

17 SEP 2021

Free PIND 4/3/5 GJ

- Rx
- Physiotherapy LT, SWP IFT
Quadriceps drill
 - Aceproxym (R) 100 - 0 -
 - Biods fem (0)
 - Bineum HC (0)
 - Monorals DSR (0)
 - Mobility (100)
 - RA. (1WR)

D. S. Gangwar
17/9/2021

Valid for 7 days / 7 दिनों के लिए मान्य

Societies Regn. No. 1335/2005

CMO Regn. No. CMO/ST/03 dt. 05.08.03

(Under Ministry of Social Justice and Empowerment, Govt. of India)

U.P.C

U.P. SPINAL INJURIES CENTRE

(7/11/21/3-35)

(Specialised treatment for Spine & Back ache Problems)

5TH KM. FROM SATELLITE BUS STAND,
PILIBHIT BYE-PASS ROAD, BAREILLY. - 243 006

Phone & Fax No. : 0581-2526400

OPD-CARD

Sl. No.

Regd. No. 2615

Name

Sham Shri

Age 57 M/F (-)

S/o, W/o, D/o

Sr. Anwar

Address

S.S. Nagar 27

Consultant

Dr. D.S. Gangwar

M.S. (Ortho)

Orthopaedic Surgeon

U.P. Spinal Injuries Centre, Bareilly.

Oct 2021

Free PWD by 5/35

- R - Myoistherapy LT, SWD, FT
- RAC SR 1 OD
- B10 D3 fem 1 OD
- Nervmax Active 1 OD
- Mon sub D&R 1 OD
- Cerv joint 1 OD
- RIA 1 WR

D. S. Gangwar
15/9/2021

Valid for 7 days / 7 दिनों के लिए मान्य

Societies Regn. No. 1335/2005

CMO Regn. No. CMO/ST/03 dt. 05.08.03

(Under Ministry of Social Justice and Empowerment, Govt. of India)



U.P. SPINAL INJURIES CENTRE

(111115-36)

(Specialised treatment for Spine & Back ache Problems)

5TH KM. FROM SATELLITE BUS STAND,

PILIBHIT BYE-PASS ROAD, BAREILLY. - 243 006

Phone & Fax No. : 0581-2526400

OPD-CARD

Sl. No.

Regd. No. 2883

Name

Shree Devi

Age

65

M/F

F

S/o, W/o, D/o

anukul

Address

C.S. Nagar

Consultant

Dr. D.S. Gangwar

M.S. (Ortho)

Orthopaedic Surgeon

U.P. Spinal Injuries Centre, Bareilly.

27 SEP 2021

- Rx - Physiotherapy LT, SWD IPT
 - RAC SR 100 PKC
 - Momet 100
 - BiD₃ fem 100
 - Momet Active 100
 - Gerijoint 100
 - RIA 1 WK

21/9/2021

Valid for 7 days / 7 दिनों के लिए मान्य

Societies Regn. No. 1335/2005

CMO Regn. No. CMO/ST/03 dt. 05.08.03

(Under Ministry of Social Justice and Empowerment, Govt. of India)



U.P. SPINAL INJURIES CENTRE

(संसाधक-37)

(Specialised treatment for Spine & Back ache Problems)

5TH KM. FROM SATELLITE BUS STAND,
PILIBHIT BYE-PASS ROAD, BAREILLY. - 243 006

Phone & Fax No. : 0581-2526400

OPD-CARD

Sl. No.

Regd. No.....

Name..... Mou Devi Age..... 65 M/F..... F

S/o, W/o, D/o..... Sun Seelka

Address..... S.S. Nagar

Consultant.....

Dr. D.S. Gangwar

M.S. (Ortho)

Orthopaedic Surgeon

U.P. Spinal Injuries Centre, Bareilly.

28 SEP 2021

for PIVD L4, L5, S1, EKS

- R_p
- Physiotherapy L7
 - 8WD
 - 1RT
 - RAC SR 1 duty
 - Massage D/R 100 cr
 - BIODs fem 100
 - Cervi joint 100
 - Mahafaba MTS 1HS
 - R/A 1WK

Dr. D.S. Gangwar
28/9/2021

Valid for 7 days / 7 दिनों के लिए मान्य

9909

Regn. No. 1335/2005

CMO Regn. No. CMO/ST/03 dt. 05.08.03

(Under Ministry of Social Justice and Empowerment, Govt. of India)



U.P. SPINAL INJURIES CENTRE

(Specialised treatment for Spine & Back ache Problems)

5TH KM. FROM SATELLITE BUS STAND,

PILIBHIT BYE-PASS ROAD, BAREILLY. - 243 006

Phone & Fax No. : 0581-2526400

(हमारा क-38)

OPD-CARD

Sl. No.

Regd. No. 6036

Name Sham Devi Age 60 M/F F

Sp, W/o, D/o Sh. Subal

Address S.C. village

Counsellant

Dr. D.S. Gangwar

M.S. (Ortho)

Orthopaedic Surgeon

U.P. Spinal Injuries Centre, Bareilly.

OA B/L knee

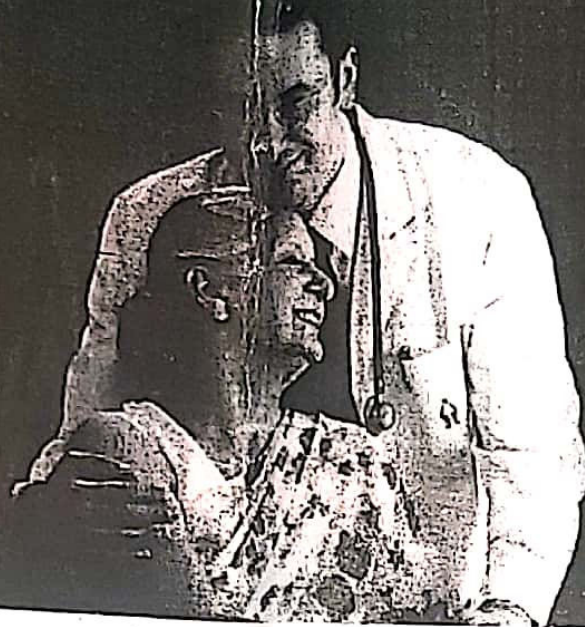- R_o Hyfeneal SA 1 daily PRN No Pain but some
- Mometab DSR 100 tab
- BLOD₃ strong 100
- ORCERIN C₂ 100
- D Gain 60R 1 weekly
- R.I.T 1WB

D. S. Gangwar
10/11/2002

Valid for 7 days / 7 दिनों के लिए मान्य

Out Patient Record

Please Bring This Record With You



Date of Registration _____ Registration No. 513684
Name MRS. DHANDEVI GANGWAR 1832704
Age 64 (D.O.B.) _____ Sex: M / F Consultant DR. Neeraj Gupta

Address _____

Phone No. _____

Booklet No. _____



Fortis Escorts
HEART INSTITUTE



Okhla Road, New Delhi - 110025 Phones : +91-11-47135000 Fax : +91-11-26825013
E-mail : contactus.escorts@fortishealthcare.com Website : www.fortisescorts.in
Please contact in Emergency : +91-11- 26825002 Use Ambulance Helpline : 105010



ROHILKHAND MEDICAL COLLEGE & HOSPITAL

रोहिलखंड मेडिकल कॉलेज एंड हास्पिटल (तलमक-41)

Pilibhit Bye Pass Road, Bareilly PH.: 0581-2526011, 2526012

पीलीभीत बाईपास रोड, बरेली

O.P.D. CARD

Date 10/11/23

R. No.

Name Dhan duni

Age 62y Sex F

Department of

140/80

डॉ० विमलेश्वर शर्मा
एमडी (भारत मेडिकल)
डी०एम० (कॉमिनिस्ट्री)
हृदय रोग विशेषज्ञ
रोहिलखंड मेडिकल कॉलेज, बरेली

DOE

HT

2

Dr. Arshad Gu To En

T. Dilraj MD (M) T. Jagjit (M) MD

T. Emesh 25 4

T. Calpue T m (3000)

ECG

Ms. M. DK & M

S. 207 / 5407

S. Anelun

S. Nekt 1kt

B. 2-200 @

e. J2M.

e

3000

e
Dr. Duni

वाह्य रोग विभाग का समय : सुबह 9:00 बजे से दोपहर 3:00 बजे तक

RMCH-21/11/2017/100

(GMB-43)



AHICHHATRA
APEX

MULTI SUPERSPECIALITY HOSPITAL
(A UNIT OF AHICHHATRA HEALTH CARE PVT. LTD.)

Pilibhit Bypass Road, In Front of Mahanagar Colony, Near Phoenix Mall, Bareilly
Ph. 8791999197, 0581-4000628

ELECTROCARDIOGRAM

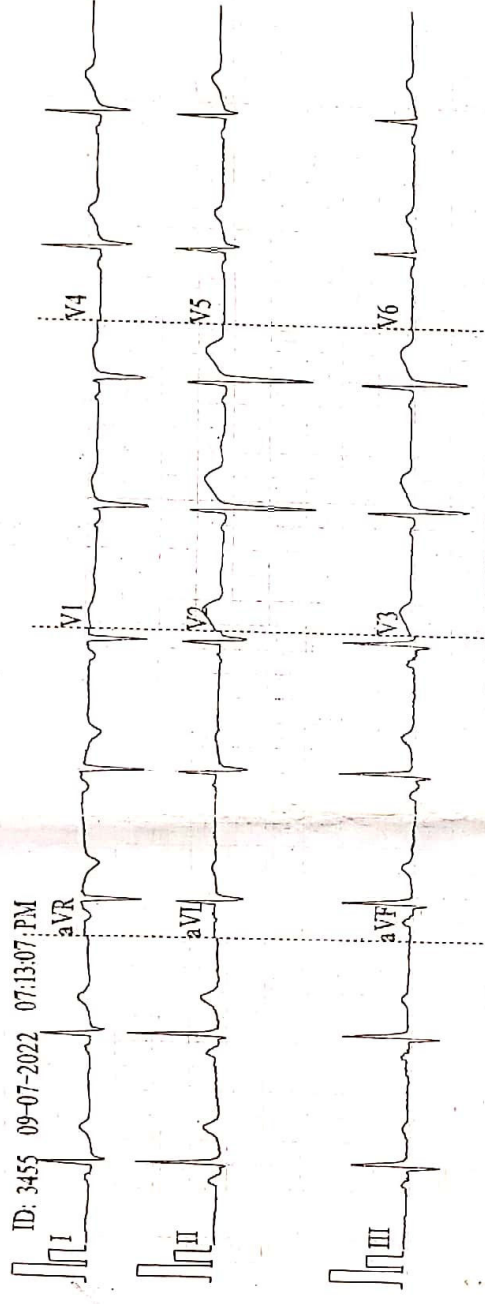
Name..... Omkar Chaudhary Age..... 72.....
Ward/Bed.....
Ref. by..... Dr. Aggarwal Date..... 09/07/22.....

43-A

Omkar Chaudhary. Age 72
Diagnosis Information
Sinus Bradycardia

ID: 3455
72 Years
cm
mmHg
kg

HR : 56 bpm
P : 111 ms
PR : 156 ms
QRS : 91 ms
QT/QTc : 422/410 ms
P/QRS/T : 58/64/54 °
RV5/SVI : 1.377/1.316 mV Report Confirmed by:



0.5-35Hz ACS0 25mm/s 10/5mm/mV 56 V1.0 SEMIP V1.7 APEX HOSPITAL

"Rajat Lung Care" Center

डा० रजत अथवाल

एम.बी.बी.एस., एम.डी.
साँस, टी.बी. एलर्जी व छाती रोग विशेषज्ञ
ब्रान्कोस्कोपिस्ट एवं परामर्श चिकित्सक

क्लीनिक : 45-ए, मैकनियार रोड, निकट बसंत सिनेमा, बरेली। क्लीनिक/मोबाइल : 92592 - 66391
रविवार अवकाश

Name Dhan Devi Age 66 M/F Wt Date 8/12/22

HTN → cor

cough
cramps

b. [serrato 250 mdi - 2puff BD.
riova mdi - 2puff OD
with spacer.

150/70
SpO2 96
BPM 86

Tab Duolin TRF
Tab ~~syn~~ calcium bit - cor
Tab Neurokend - LC cor
Syr axelplus smf BD

Tab. ~~Coecost~~ 6mg 1puff
Tab ceflox 500 - cor | sd
Caplantabar 150 cor

Q

❖ यह पर्चा मेडिकोलीगल कार्यवाही के लिये मान्य नहीं है।

शुविधाएँ :

- दूरबीन द्वारा (Fibre-Video Bronchoscopy) फेफड़ों में साँस की नली में गांठे, ट्यूमर, अल्सर, खून आना, टी.बी. आदि की जाँच - Biopsy, TBLB, TBNA, Stent, BAL etc.
- साँस रोगियों के फेफड़ों की कार्य एवं क्षमता नापने की कम्प्यूटराइज्ड मशीन (Spirometry) द्वारा जाँच (PFT)
- आब्सट्रक्टिव स्लीप एपनिया (O.S.A.) की जाँच एवं इलाज - स्लीप टेस्ट (Sleep Study / Polysomnography PSG) - जिनको खरटे आते हों, वजन ज्यादा हो, सोते समय साँस का रुकना, दिन में क्षपकी / नींद आना
- साँस एवं (O.S.A.) के रोगियों के लिये CPAP, BiPAP
- MDR / Resistant - TB का इलाज
- Medical Thorascopy - दूरबीन द्वारा फेफड़े की झिल्ली की Biopsy एवं Pleurodesis
- धूम्रपान छोड़वाने में सहायता
- Pulmonary Rehabilitation

फेफड़े से सम्बन्धित सभी रोगों की जाचों एवं उच्च स्तरीय इलाज की शुविधा

"Rajat Lung Care" Center

डा० रजत अश्रवाल

एम.बी.बी.एस., एम.डी.
साँस, टी.बी. एलजी व छाती रोग विशेषज्ञ
ब्रान्कोस्कोपिस्ट एवं परामर्श चिकित्सक

क्लीनिक : 45-ए, मैकनियर रोड, निकट बसंत सिनेमा, बरेली। क्लीनिक/मोबाइल : 92592 - 66391

रविवार अवकाश

Dr. Rajat Ashwal

Name: Dhan Devi Age: 66y M/F Wt: 60kg Date: 28/11/22

FEV1 → COUL

cough
Breathless

Fever sd back

weight - 70 kg

b. { seroflo 250 MDI - 2 puff BD
riova MDI - 2 puff OD - 5 puff
with Zerostat vt spacer

(Med) Tab. montair AB - 100 2/1/10

S-96

P-81

- CXR PA
- CBC
- RBS

MOB - Duplex MS ()
Cap Caldicens flow - 100 - 2/1/10

Cap Pantecor DSF - 100 -
Tab. Coecost B - 100 -
Tab. Coeamox 600 - 100 -
~~Cap Caldicens flow - 100 -~~

2/1/2

Syp axol plus 5ml MOB

CEL 54

4

08/12

BP-150/70

S-96

P-86

❖ यह पर्चा मेडिकोलीगल कार्यवाही के लिये मान्य नहीं है।

सुविधाएँ :

- दूरबीन द्वारा (Fibre-Video Bronchoscopy) फेफड़ों में सांस की नली में गांठे, ट्यूमर, अल्सर, खून आना, टी.बी. आदि की जाँच - Biopsy, TBLB, TBNA, Stent, BAL etc.
- सांस रोगियों के फेफड़ों की कार्य एवं क्षमता नापने की कम्प्यूटराइज्ड मशीन (Spirometry) द्वारा जाँच (PFT)
- आब्सट्रक्टिव स्लीप एपनिया (O.S.A.) की जाँच एवं इलाज - स्लीप टेस्ट (Sleep Study / Polysomnography PSG) - जिनको खरटे आते हों, वजन ज्यादा हो, सोते समय सांस का रुकना, दिन में क्षपकी / नींद आना
- सांस एवं (O.S.A.) के रोगियों के लिये CPAP, BiPAP
- MDR / Resistant - TB का इलाज
- Medical Thorascopy - दूरबीन द्वारा फेफड़े की झिल्ली की Biopsy एवं Pleurodesis
- धूमपान छुड़वाने में सहायता
- Pulmonary Rehabilitation

फेफड़े से सम्बन्धित सभी रोगों की जाचों एवं उच्च स्तरीय इलाज की सुविधा



AHICHHATRA
APEX

MULTI SUPERSPECIALITY HOSPITAL
(A UNIT OF AHICHHATRA HEALTH CARE PVT. LTD.)

Mrs. Dhan Devi gangwar - Age - 66 - Y/Female

19/12/2022

C/O - Hypertension -
Ischaemic.
Weakness -
Cough & Sputum

Adv -

Tab - Tazolacung - OD - (TSD F)
Tab - Medrolung - TSD
Tab - Abiwayg - TSD
Tab - Montair LC - HS
Cap - Maxisich - HS
SP - Macbery αT - 2 TSD - TSD
Mob - Dullen + Budicart - TSD

for 7-day

19/12/2022

DR. NITHSAGARWAL
MD., DM. (CARDIOLOGY)
CONSULTANT CARDIOLOGIST
Reg No. - 48765

वाह्य रोगी विभाग

राजकीय नेशनल होम्योपैथिक मेडिकल कॉलेज एवं चिकित्सालय

1, विराज खण्ड, गोमती नगर, लखनऊ

पंजीकरण सं०: 53918

नाम: SHRIMATI DHAN DEVI
GANGWAR

लिंग: महिला

तारीख: 20/06/2022

आयु: 68

धर्म: हिन्दू



चिकित्सक का नाम: DR RAJEEV KUMAR

समय: 9:00:00-15:00:00

विभाग:

रूम संख्या: 10

यह पर्चा 05-07-2022 तक मान्य है।

दिनांक	रोग का लक्षण एवं जाँच	उपचार	हस्ताक्षर
	<p><i>R₂</i></p> <p><i>cough</i></p> <p><i>Breathlessness</i></p> <p><i>Appetite - (N)</i></p> <p><i>desire for salt things</i></p> <p><i>Thirst - (N)</i></p> <p><i>stool unsatisfactory</i></p> <p><i>sleep - (N)</i></p>	<p><i>Nat Sulph 200</i></p> <p><i>3 doses</i></p> <p><i>Ars alb 30</i></p> <p><i>100</i></p> <p><i>x 7 days</i></p>	<p><i>Rajeev</i></p>

नोट :- (1) डॉक्टर को दिखाने के समय पुराना पर्चा तथा अपनी पुरानी रिपोर्ट सकारात्मक रूप से लाए।

(2) बार-बार डॉक्टर को मत बदलें।

संगम हॉस्पिटल

डॉ. एम.एल. मोर्य

बी.एस.सी., एम.बी.बी.एस. (लखनऊ)
भूतपूर्व राजकीय मेडिकल ऑफिसर
फैमिली फिजीशियन रजि. नं. 34089

जोगी नवादा,
(चक महमूद नगर)
पुराना शहर, बरेली

Date 2/12/22

Rx

Smt Dhan Devi

Ra Tab clanging 500 1000
Tch Histajre 1000 →
Tch Deriphylini Retd 1500/1000
Sgn Brozedex 1000/1000
Tch Paraguet 600 1000
Dolin Resum @
Cep Myeout 4 600 @ 10
Cem Zemetrol 1000 @ 10
di amoxicid Gold @
I.U.
aspirin @

Adv
X-ray
chest
PA -



AHICHHATRA

APEX

MULTI SUPERSPECIALITY HOSPITAL
(A UNIT OF AHICHHATRA HEALTH CARE PVT. LTD.)

19/12/2022

Mrs. Dhan Devi gangwar - Age - 66 - Y/Female

C/O - Hypertension -
Diabetes mellitus -
Weakness -
Cough & Sputum

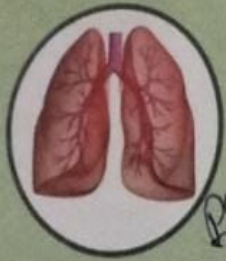
Adv -

- Tab - Tazolacung . OD - (TSD) (TSBF)
- Tab - Medrol ung - TSD
- Tab - Abirwayy - TSD
- Tab - Montair LC - HS
- Cap - moxidich - HS
- SP - Macberg AT - 2 TSD - TDS
- Meb - Dullin + Tsdicort - TSD

for 7-day

19/12/2022

DR. NITIN SAGARWAL
MD., DM. (CARDIOLOGY)
CONSULTANT CARDIOLOGIST
Reg No. - 48785



डॉ. अमित कुमार कुशवाहा

एम.बी.बी.एस., एम.डी. (चेस्ट स्पेशलिस्ट)

यू.पी.एम.सी. रजि. नं. 50365

मो० 9411477351

श्वास, दमा, टी.बी., फेफड़ों के कैंसर व अन्य छाती की बीमारियों के विशेषज्ञ।

नाम: Ms Dhan Devi Changuar उम्र/लिंग: 66y / F वजन: 70 kg दिनांक: 22-12-22

BP → 140/80 mmHg

Spo2 → 97%

Pulse → 86bpm

Temp.

10 yrs
~~10 yrs~~
~~10 yrs~~
2 yrs
Red mouth
COPD / HTN

Breathless

Actu

- Nebulisation
- ① Nebulisation {
 - Duoalini {
 - 100mg
 - 100mg
 - Nebmax 2 {
 - 100mg
 - 100mg
 - FB (mg)
 - ② Tab Lorazepam 500mg BD
 - ③ Tab Duoalini 200mg
 - ④ Tab Aldactone 25mg
 - ⑤ Cap Propranolol 100mg
 - ⑥ Tab Ronicost 5mg P.T.O

नोट : कृपया फोन से सम्पर्क करके आयें।

पता : अमित अभिनव चेस्ट एवं ई० एन० टी० क्लिनिक, टयूलिप ग्राउन्ड बिल्डिंग, पीलीभीत रोड, बरेली - 243006

पचां 5 दिन के लिए मान्य

समय : दोपहर 1 बजे से सायं 4 बजे तक सायं 6 बजे से रात्रि 8 बजे तक

सोमवार से शुक्रवा