



# ARIHANT DIAGNOSTIC CENTRE

CENTRE FOR 3T MRI, 64 SLICE CT SCAN, DEXA SCAN, DIGITAL OPG, USG & DIGITAL X-RAY  
23, Jagannathpuri Colony, Rathyatra-Mahmoorganj Road, Varanasi -10, Mob. 9580401616, 9935041111

WORLD BEST TOP END **3T** MRI MAGNETOM VIDA (64 CHANNELS) WITH ARTIFICIAL INTELLIGENCE FOR SUB SPECIALITY WORK

Name : NIKITA GOUR

Ref.By : SELF

Age : 29 Year

Sex : F

Date : 22/08/2022



## ULTRASOUND SCAN OF WHOLE ABDOMEN:

- \* Liver is mildly enlarged in size and shows normal echotexture. IHBD'S are not dilated. No focal mass is seen.
- \* Gall bladder is normal in size and shows a stone of 7 to 8 mm in lumen.
- \* Portal vein and CBD are not dilated.
- \* Pancrease is normal in size and shows normal echotexture. Pancreatic duct is not dilated . No mass / stone is seen.
- \* Spleen is normal in size and appears normal.
- \* Both kidneys are normal in size and shows suspicious tiny soft 2 mm stone one on each side .
- \* No enlarged nodes are seen in retroperitoneum.
- \* Uterus is normal in size and shows normal , central endometrial echoes. No mass is seen. Cervix is normal.
- \* Small collection seen in culde sac.
- \* No adnexal mass or cyst are seen.
- \* Urinary bladder is normal in size and shows echofree lumen.

### IMPRESSION:

- => MILD HEPATOMEGALY.
- => GALL BLADDER STONE.
- => ? TINY B/L RENAL NON-OBSTRUCTING STONE ONE ON EACH SIDE.

**TYPO DISCLAIMER:** This report has been created using an automated system with voice recognition for efficiency purposes. Typographical and other errors may occasionally inadvertently occur. Rarely even operative organ (without any pathology) can be reported as normal inadvertently due to typological error (please report the same in case of discrepancy). Should you notice any such errors or have concerns about your report, please contact us at +91-9935041111 by phone or WhatsApp on 9580007677 or email us at arihantdiag.19@gmail.com.

**Dr. Kshitij Jain**

MD (IPGMER, Kolkata), FRCR (UK)  
Former Asst. Prof. (CMC, Vellore)  
Visiting Fellow MSK MRI (U.S.A.)  
Ex. SR. AIIMS (Delhi)  
Consultant Radiologist  
Reg. No. : UPMC 72073

**Dr. Anshita Agrawal Jain**

M.D. (Radiodiagnosis)  
Consultant Radiologist  
Reg. No. : UPMC 81071

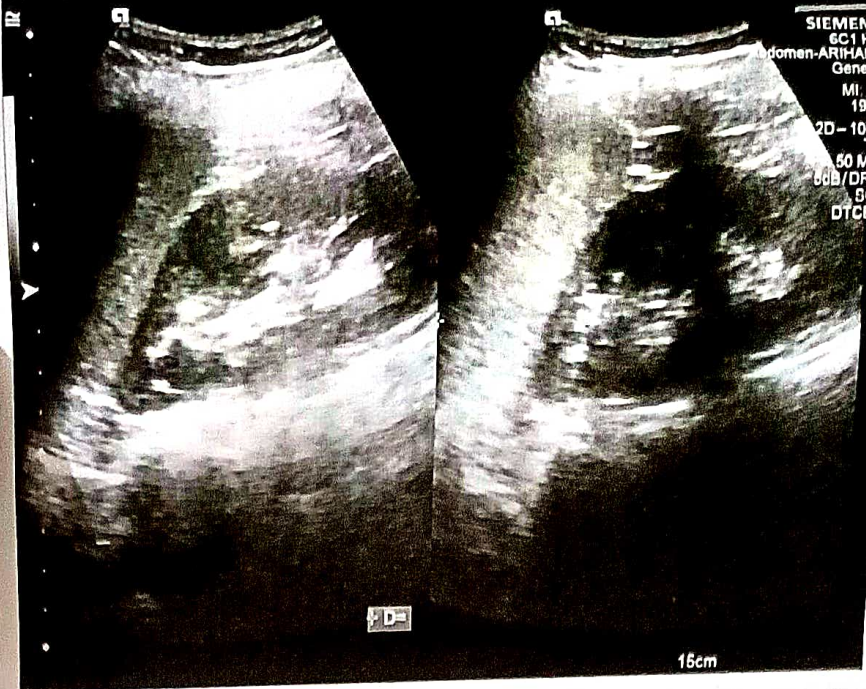
**Dr. Nirmal Jain**

M.D. (Radiodiagnosis)  
Consultant Radiologist  
Reg. No. : UPMC 51181

Above impression is not the final diagnosis. Please correlate clinically, if discrepancy please send patient for review (free) Not valid for medicolegal purpose.  
(Please intimate, for any typing mistake within 3 days if not, Centre is not responsible.)

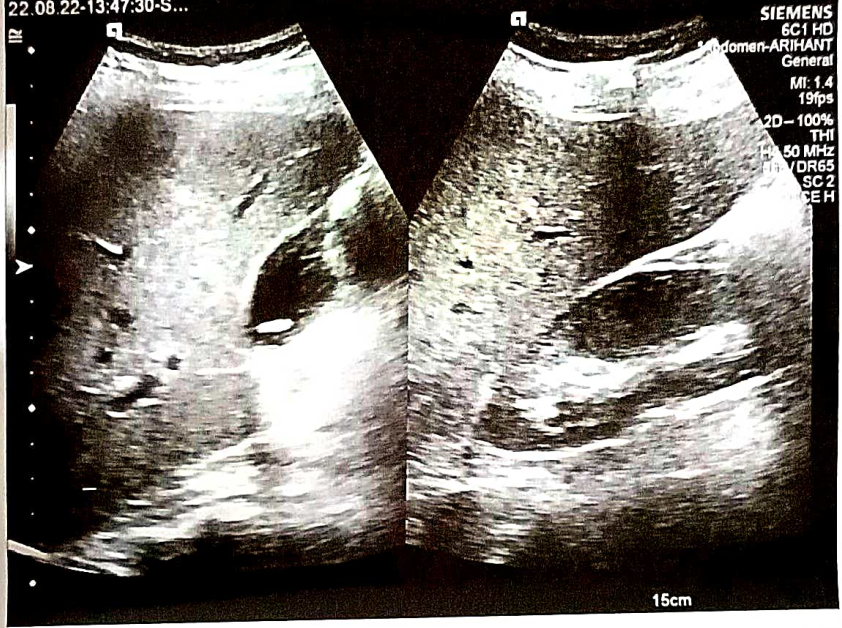
NIKITA GOUR 29 F  
22.08.22-13:47:30-S...

ARIHANT DIAGNOSTIC CENTREA... 13:49:49 22/08/2022



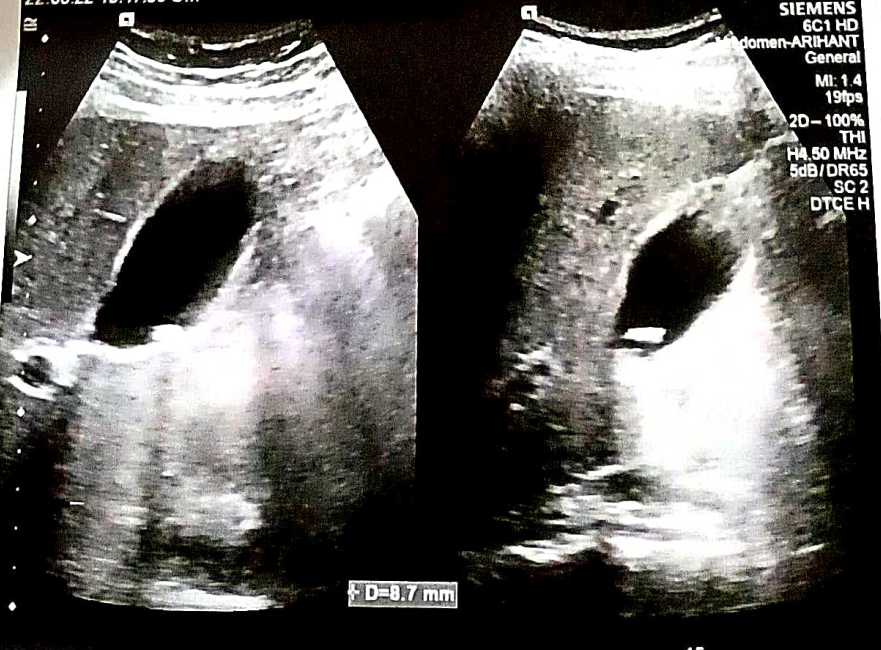
NIKITA GOUR 29 F  
22.08.22-13:47:30-S...

ARIHANT DIAGNOSTIC CENTREA... 13:48:56 22/08/2022



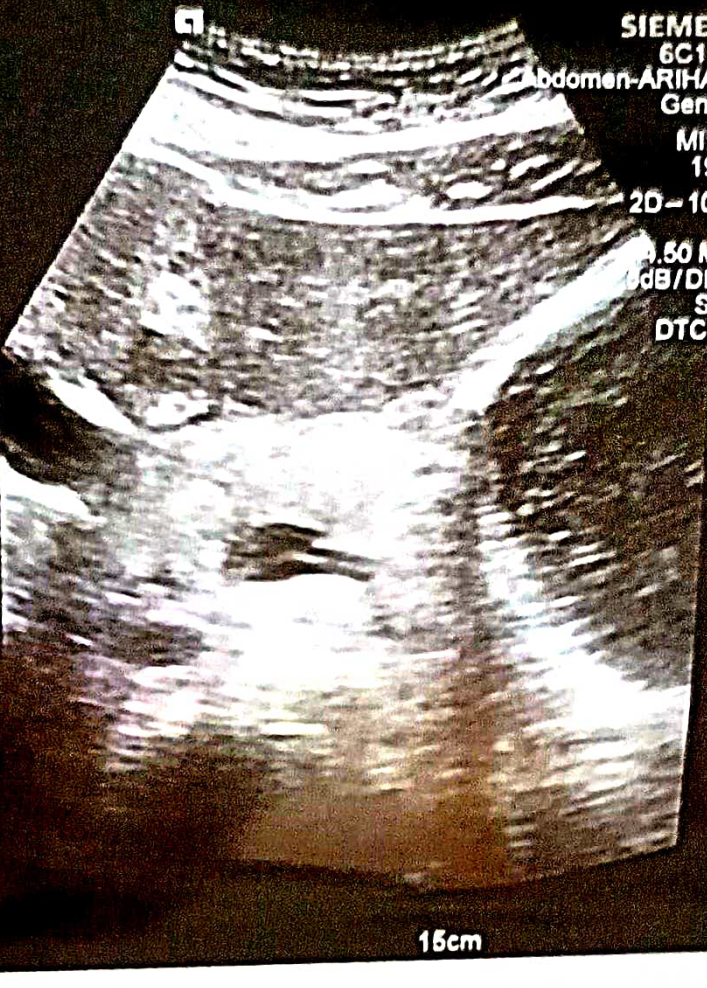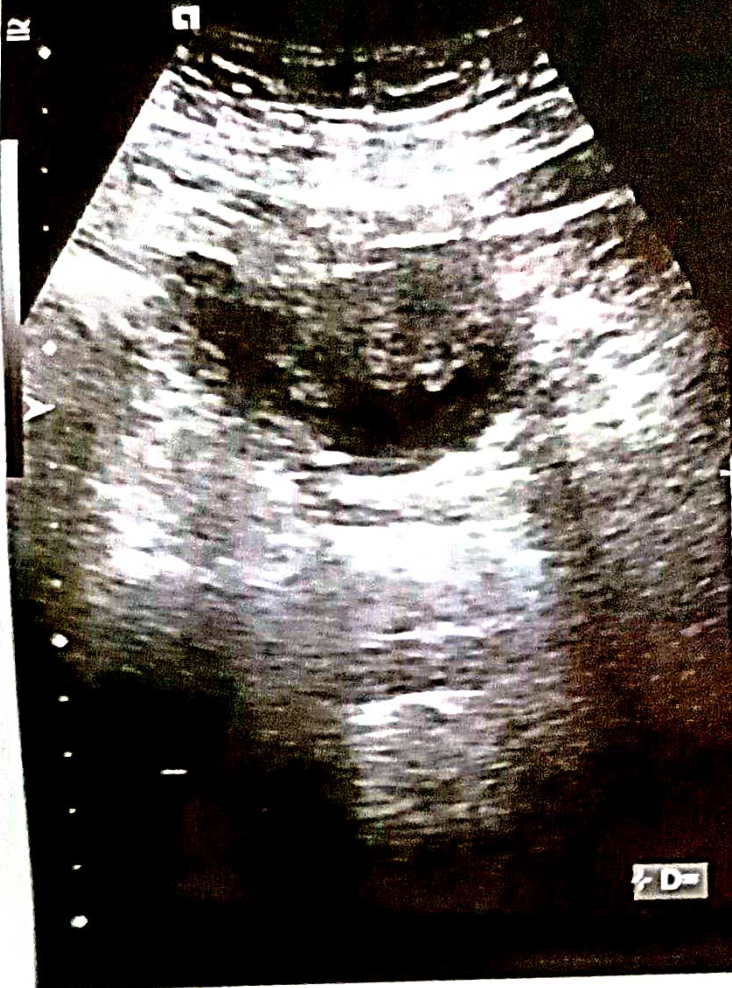
NIKITA GOUR 29 F  
22.08.22-13:47:30-S...

ARIHANT DIAGNOSTIC CENTREA... 13:48:30 22/08/2022



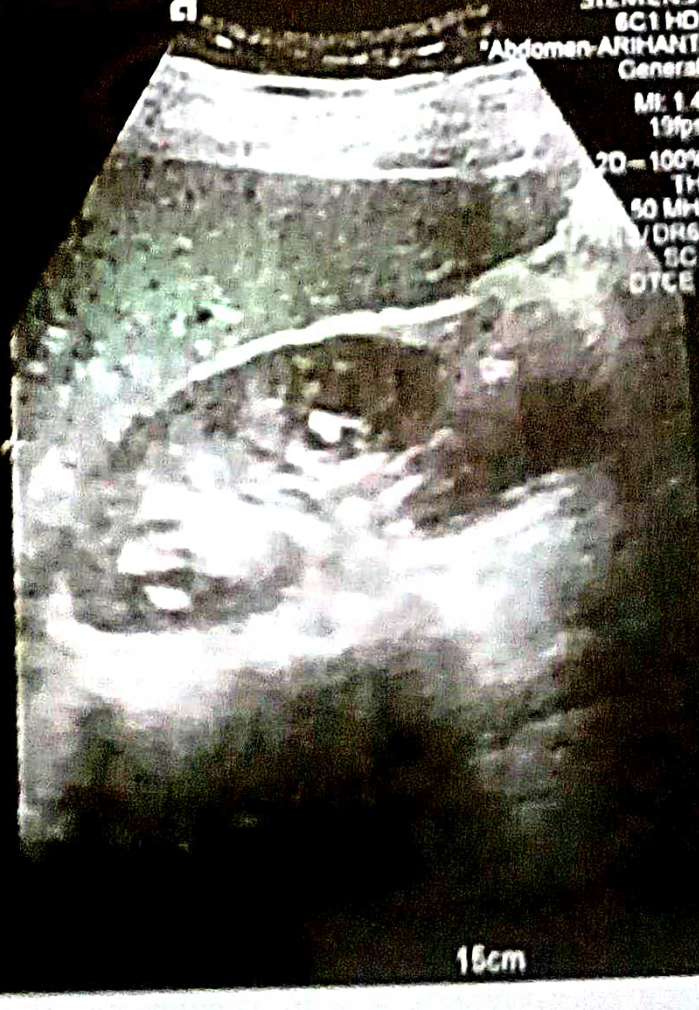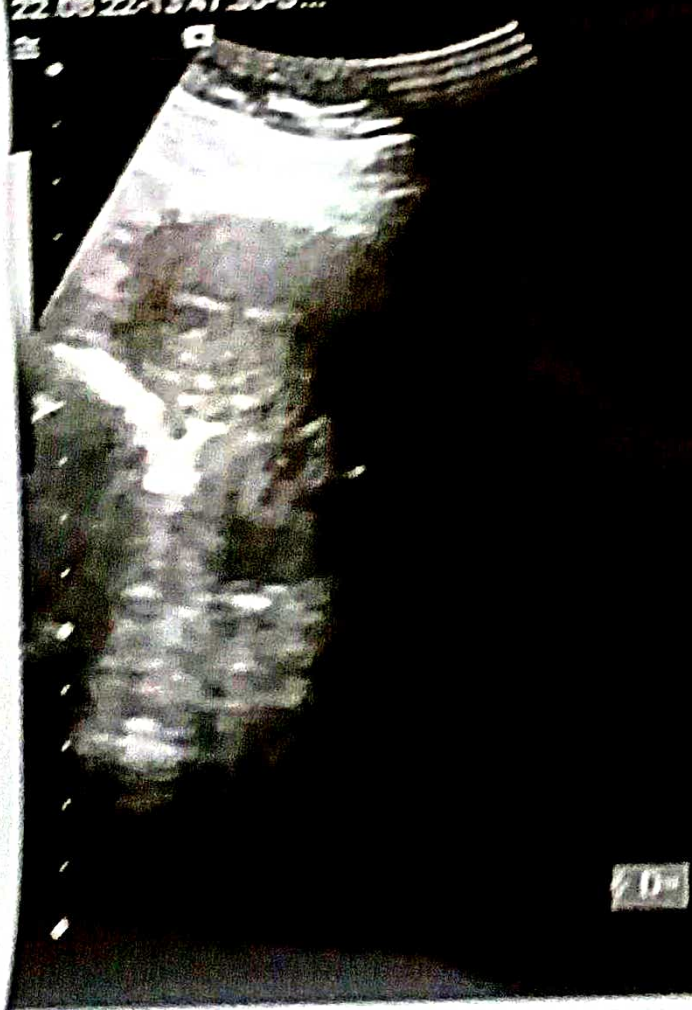
NIKITA GOUR 29 F  
22.08.22-13:47:30-S...

ARIHANT DIAGNOSTIC CENTREA... 13:51:31 22/08/2022



NIKITA GOUR 29 F  
22.08.22-13:47:30-S...

ARIHANT DIAGNOSTIC CENTREA... 13:51:10 22/08/2022





# ARIHANT DIAGNOSTIC CENTRE

23, Jagannathpuri Colony  
Rathyatra-Mahmoorganj Road, Varanasi -10  
Mob. 9580401616, 9935041111

## ULTRASONOGRAPHY REPORT

Patient's Name NIKITA GOUR Age 23yrs Sex F  
Doctor's Name Smt  
Scan Whole Abd. Dated 27/05/22