

एक नू सच्चा तेरा नाम सच्चा



Ph.: 0591-2483425, 9837192211

मानसरोवर नर्सिंग होम

मानसरोवर पैराडाइस के सामने, मानसरोवर कालोनी, टंकी के पास, दिल्ली रोड, मुरादाबाद

डॉ. (श्रीमती रंजना सिंह)

M.B.B.S., M.D. (Obstetrician & Gynaecologist)

स्त्री एवं प्रसूति रोग विशेषज्ञ, सर्जन

भूतपूर्व चिकित्सक :

- सफदरगंज हॉस्पिटल, नई दिल्ली
- हिन्दू राव अस्पताल, नई दिल्ली
- सर गंगा राम अस्पताल, नई दिल्ली
- मेरठ मेडिकल कॉलेज, मेरठ

Wt. 6.1 kg Name Smt. Rupali Age/Sex 28y/M/O 110 Rehit Date 12/12/22

BP 120/70 mmHg Address Banpur Valid Up.....

Temp. 98.4

PR - 85
SpO2 - 98%

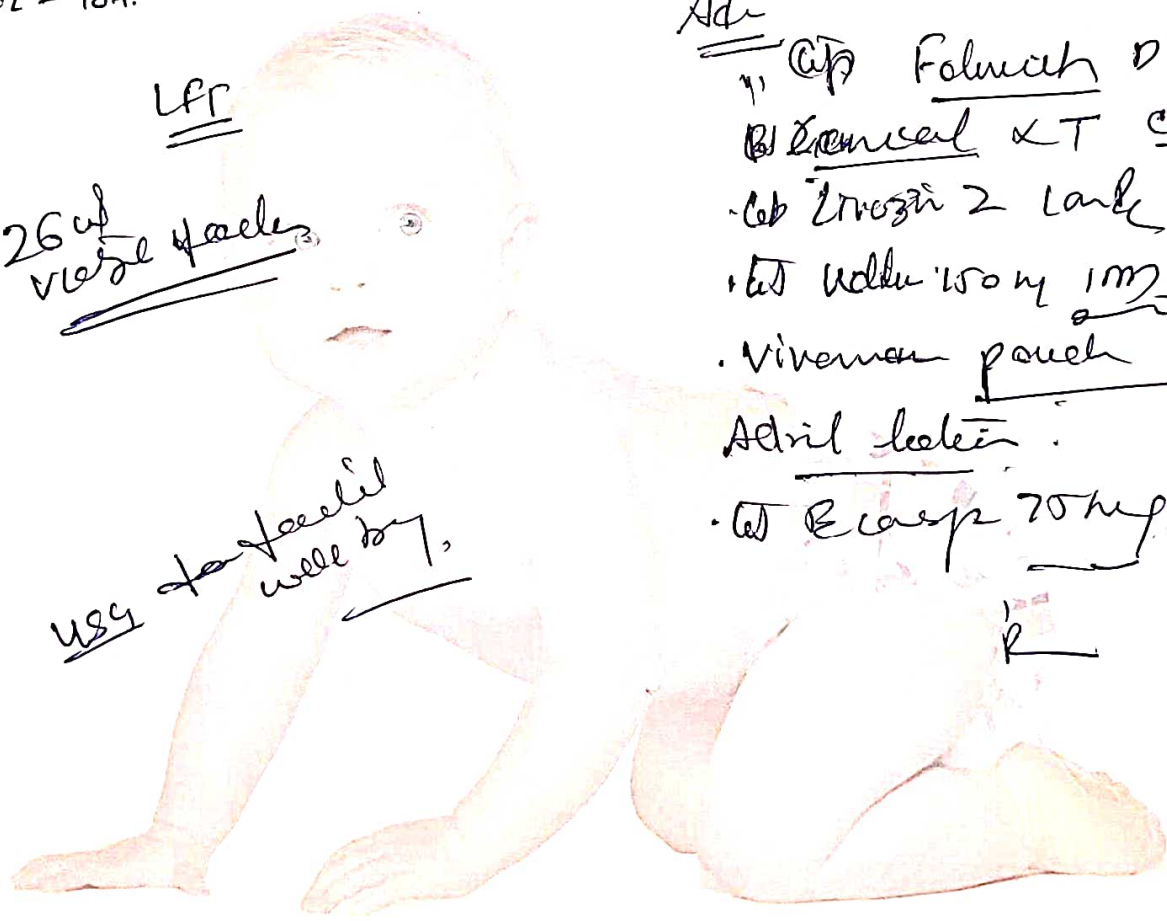
no body temp

Tetnae covered 2nd dose

LFT
26 wks
veste patches

USG for foetal
well boy

Adm
1) Cap Folmich DR
B. Immunol & T cell
• Cap Trozin 2 large prom
• Vit K 100 mg 1mg a/c LFT
• Viveman pouch 2000 mg
Adril lekin
• Vit E 200 mg



- अल्ट्रासाउण्ड, डिलीवरी सभी प्रकार के ऑपरेशन की सुविधा उपलब्ध है।
- दूरबीन द्वारा बच्चेदानी की जाँच।
- बच्चेदानी का ऑपरेशन
- निःसंतान दम्पतियों का इलाज
- फैमिली प्लानिंग से सम्बन्धित सलाह।
- रविवार अवकाश
- पर्चा 7 दिन में दो बार के लिये मान्य
- यह पर्चा कानूनी कार्यवाही के लिये मान्य नहीं है।

सुविधायें :- 24 घन्टे इमरजेन्सी सुविधा भर्ती की सुविधा परामर्श समय : सबुह 11.00 से 2.00 / सायं 6.30 से 8.00

PT.NAME	MRS.ROOPALI SINGH W/O ROHIT SONI	AGE & SEX :28 YRS/ F
RFD.BY	DR. AMIT TANDON	DATE :-23 October 2022

USG PREGNANCY – LEVEL II SCAN

LMP: 10/06/2022

GA BY LMP: 19 W 2 DAYS

There is evidence of a single fetus in CEPHALIC presentation at the time of scan.

Fetal movements and cardiac activity are present (FHR: 157 Bpm).

Placenta is along POSTERIOR WITH RIGHT LATERAL WALL EXTENSION in position, lower margin is approx. 4.8 cm away from internal OS. It shows grade II maturity.

Liquor is adequate (AFI measures approx 10 cms).

The Internal OS is closed. (Cervical length measures 3.8 cm)

Parameter	Dimension	POG
BPD	43mm	19 W 1 DAYS
HC	159.8mm	18 W 6 DAYS
AC	136.6mm	19 W 1 DAYS
FL	31.5mm	19 W 6 DAYS
TIB	27.1mm	19 W 5 DAYS
HL	29.2mm	19 W 4 DAYS
Cereb	19.4mm	18 W 6 DAYS

GA by USG : 19 W 2 DAYS; Fetal weight: 288 +/- 42 GRAMS.

EDD by USG : 17/ 03/2023

SONOGRAPHIC SUBJECTIVE FETAL EVALUATION REVEALS

FETAL HEAD-

Normal echogenic well defined cranial vault with midline septum, midline falx, thalamus and symmetrical normal echopattern of bilateral visualized cerebral structures. Transverse cerebral diameter is normal. Cisterna magna is normal. No obvious ventricular dilatation visualized. Nuchal fold thickness is normal.

FETAL FACE-

The visualized nasofacial structures and inter ocular distance is within normal limits. Both lips and mouth appears normal.

Dr. Abhinav Pandit

M.B.B.S., M.D. (Radiodiagnosis)
Reg. No.- 86408

Dr. Shraddha Chandraker

M.D. (Radiodiagnosis)
Reg. No.- 83225

Dr. Vaishali Tandon

M.B.B.S., M.S. (Gold Medalist)
IVF & Infertility Specialist
Reg. No.- 55889

4/48-B, Lajpat Kunj, Agra
Tel.: 0562-2525369, 9411083955
E-mail: tandonvaishali123@gmail.com

PAGE 1/2 CONT

PT.NAME	MRS.ROOPALI SINGH W/O ROHIT SONI	AGE & SEX :28 YRS/ F
RFD.BY	DR. AMIT TANDON	DATE :-23 October 2022

PAGE 2/2;

FETAL SPINE-

Cranio vertebral junction and visualized spine appears normal in alignment and curvature. No evidence of dysraphism of spine seen.

FETAL HEART:

Cardiac rhythm appears normal.
All four cardiac chambers are seen. RVOT and LVOT seen.

FETAL THORAX-

Both fetal lungs appears normal. No evidence of focal cystic lesion is seen. Diaphragmatic outline is normally visualized.

FETAL ABDOMEN-

Abdominal structures including liver, stomach and intestines appear normal for gestational age.
Both fetal kidneys and urinary bladder appear normal.

FETAL EXTREMITY-

The visualized bones of both upper and lower limbs appear normal.


Artery	PI	RI	S/D ratio
left Uterine artery	1.23 (66 PERCENTILE)	0.51	2.05
Right Uterine artery	1.29 (66 PERCENTILE)	0.37	1.58

IMPRESSION:

- **SINGLE LIVE INTRAUTERINE PREGNANCY OF GA 19 WEEKS AND 2 DAYS.**

I, Dr. Abhinav Pandit, declare that while conducting ultrasonography of Mrs. Roopali, I have neither detected nor disclosed the sex of the fetus to anybody in any manner.

All fetal body parameters, including fetal weight are subject to statistical variation. All congenital anomalies cannot be detected by sonography alone. Not valid for medico-legal purpose.


Dr. Abhinav Pandit
M.B.B.S., M.D. (Radiodiagnosis)
Reg. No.- 86408

Dr. Shraddha Chandraker
M.D. (Radiodiagnosis)
Reg. No.- 83225

Dr. Vaishali Tandon
M.B.B.S., M.S.(Gold Medalist)
IVF & Infertility Specialist
Reg. No.- 55889

4/48-B, Lajpat Kunj, Agra
Tel.: 0562-2525369, 9411083955
E-mail: tandonvaishali123@gmail.com