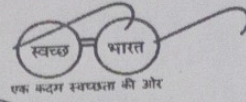


शौचालय का उपयोग करें - बीमारियों को दूर भगायें



हर रविवार - मच्छर पर वार


जिला संयुक्त चिकित्सालय सोनभद्र

सीमित परिवार - समय की पुकार

पर्ची शुल्क

1 रूपया

बाह्यरोगी-प्रपत्र



पंजीकरण संख्या 10505

रोगी का नाम मारुती 11046 / स्त्री / पुरुष

रोग उम्र 30

नोट - यह प्रपत्र 15 दिन तक वैध रहेगा।

दिनांक	लक्षण और उपचार
31/2	HRP no Post 5 months fem abs
Uml - 8 Cu IUD 2	① - 4 months missed absent on SW Bael ② - 1 1/2 months missed absents ③ - ♀ alive (Prev LSCs)
USG Report 19 wks 05 days FUS 147/mi EDD - 30-4-2023	& Lab Ironi - as let calcium as any चिकित्साधिकारी 1-12-22 जिला संयुक्त चिकित्सालय सोनभद्र Dr Geeta Jaiswal LMO DCH S.M.S.
Inde Beel Rkt	



Reception- 9454988855, 05444-222898, 05444-222897

LAXMI DIAGNOSTIC CENTRE

159, Mandi Mohal, Badhuali Chauraha, Pipari Road, ROBERTSGANJ, Sonbhadra (U.P.)

Patient's Name: ARADHANA TRIPATHI
Referred by DR. NEELAM OHARI
ADVISED- U.S.G. FOR OBST [Level II scan]

Age/Sex 30Y/F
DATE-December 9, 2022

ULTRA SONOGRAPHY REPORT:

** uterus shows a single normal intra uterine fetus with normal movement, FHR 147/mt, with breech [variable] presentation, placenta lie Rt lateral wall in upper uterine segment with **grade 0 maturity** no evidence of retro or intra placental blood clot, placental - myometrial junction line [stratum basalis] is maintained, no evidence of increta, accreta or percreta placenta
* Liquor amni shows adequate AFI 15.44cm [normal range 5cm -25cm], no gross fetal anomaly

uterine wall and cervix is normal, and cervix not dilated, CX length 3.99cm

LMP 10-07-2022

EDD 16-04-2023

Gest. Age 19weeks 05days -+ 02 week 01 day

EDD 30-04-2023 AD +02week 01 day

EFW is- 319gms +- 46gms

No adnexal or ovarian mass

Targeted scan reveals—

Nasal bone present 8.52mm

Nuchal fold = 2.25mms

Cerebellum = 2.08cm

Cisterna magna = 3.20mms

Lateral ventricles = 8.31mm

Facial structure = normal

Spine =normal

Upper extremities =normal

Lower extremities =normal

cord insertion normal

3vessels cord seen

kidney =normal

urinary bladder =normal

diaphragm =normal

bowel =normal

stomach =normal

four chambers =normal

No obvious mediastinal shift seen at present

B.P.D = 4.56CM: 19weeks and 5days

H.C. = 17.27CM: 19weeks and 6days

A.C. = 14.39CM: 19weeks and 5days

F.L. = 3.20CM: 20weeks and 0days

Comment : 19weeks 05days gestation, fetal size about 2week smaller than LMP, assigned with previous scan [expected LMP 24-07-2022], doppler—Lt Uta shows high resistance flow but average of both Uta PI within 5-95%le range

----- fetal structures grossly appear normal.

DR. R.S. SINGH
PC&PNDT 3/2001

P.N. all measurements including estimated fetal weight, are subject to statistical variations. Not all anomalies can be detected on sonography. [accuracy for anomaly in level II scan IS ABOUT 50% to60% without blood marker, and about 70% with blood marker-- [IUSOG 2012]

Dr. R.S.Singh declare that while performing sonography on Mrs. ARADHANA TRIPATHI I have neither detected nor disclosed the sex of the fetus to anybody in any manner. Signature:

DR. R.S. SINGH
MBBS, DMRD
SONOLOGIST

एम.आर.आई, 2डी/3डी सीटी स्कैन, 2डी/3डी कलर व पावर डॉप्लर, 2डी/3डी अल्ट्रासाउण्ड, कम्यूटराइज्ड ई.सी.जी., डिजिटल ओ.पी.जी., टी.एम.जे., सीफैलोग्राम, डिजिटल मैमोग्राफी, डिजिटल एक्सरे व पैथॉलाजी सेंटर

समय - प्रातः 8 बजे से सायं 6 बजे तक, रविवार बन्दी