

# SAMEER ULTRASOUND CENTRE

KARTIK HOSPITAL, NAGINA ROAD, BIJNOR

Ph. : 260394

Pt Name- Mrs. Reetu  
Ref by- Dr. Nirupma Chaudhary MD

Age/Sex- Yr/F  
Date-21-10-2023

## ANTE- NATAL ULTRASOUND

- Single live Foetus having CRL—60 mms is seen in Uterus
- Foetal Heart rate – 162 bpm.
- Placenta appears anterior, grade type 0 maturity.
- Amniotic fluid is adequate .

OPINION - Single live Foetus having CRL— 60 mms is seen in  
uterus. Sonological gestational age- 12 wks 4 days +/-  
7 days

-NB-1.9 mms

-NT-1.1 mms

-EDD-30-4-2024

Dr. Nirupma Chaudhary  
MD  
Obs. & Gyne.

Dr Sunil Chowdhry  
M.B.B.S.  
Consultant Sonologist

**Dr. Sunil Chowdhry**  
M.B.B.S.

Declaration of Doctor conducting the Ultrasonography

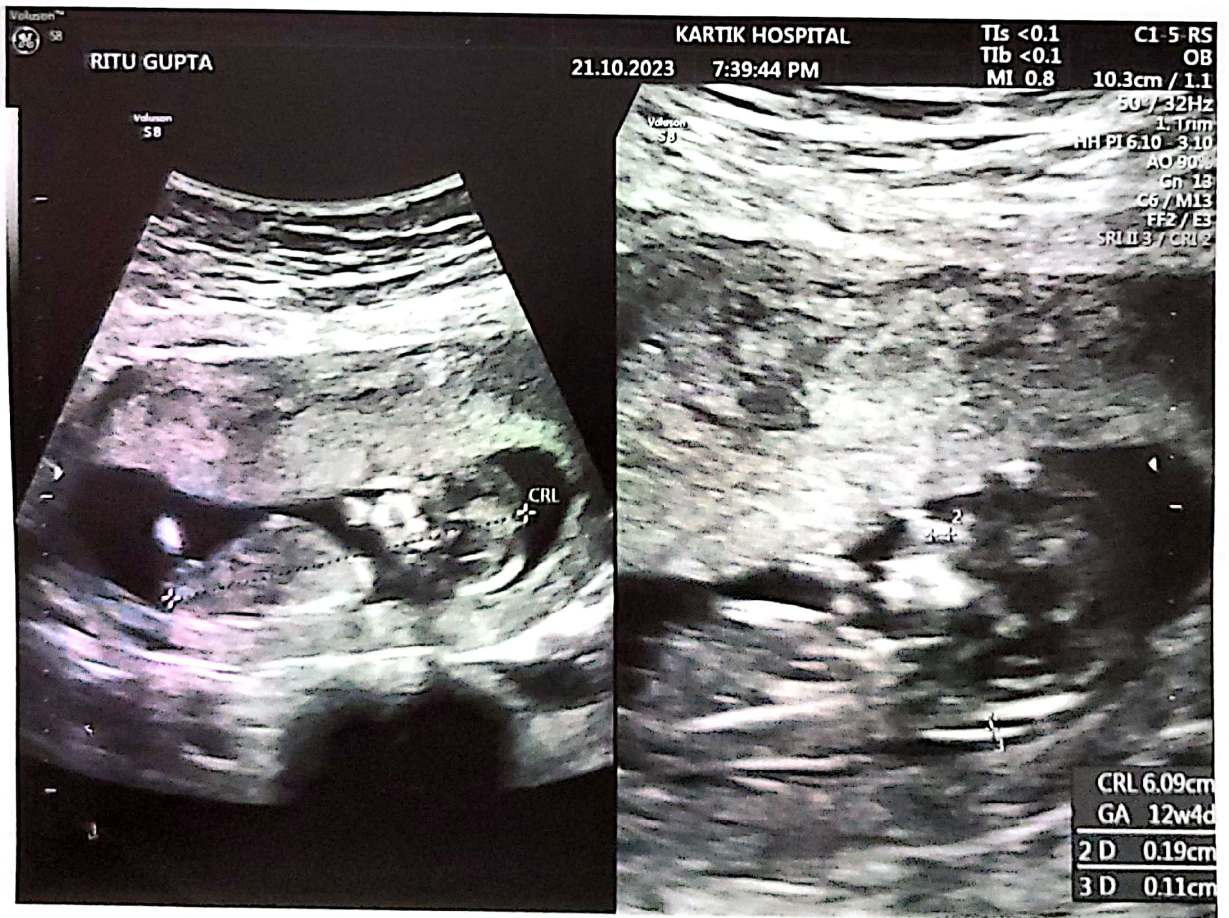
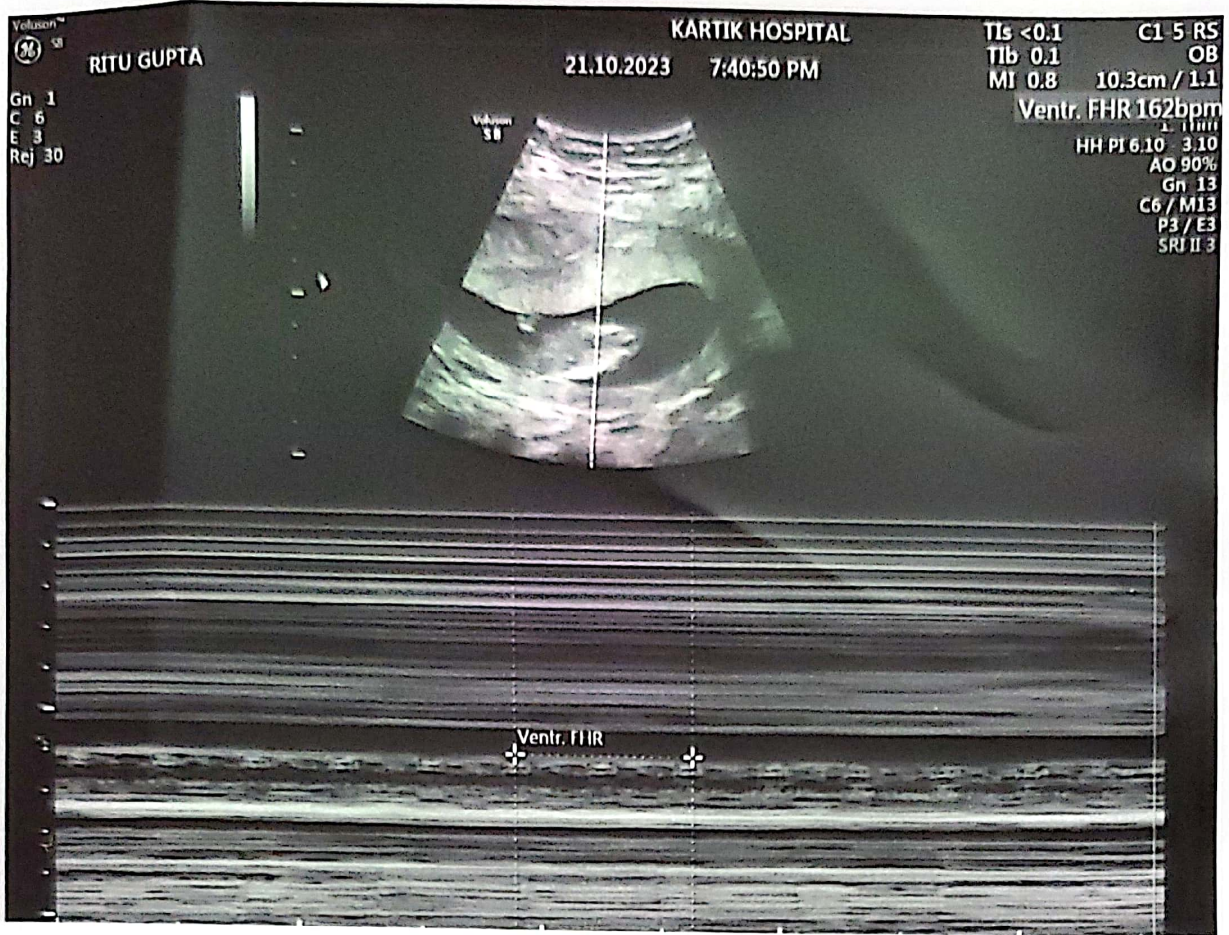
I Dr Sunil Chowdhry declare that while conducting ultrasonography on Mrs. Reetu I have neither detected nor disclose the sex of her to any body in any manner

Shiv Kumar Spte  
Self Attested

Please Correlate Clinically

Not For Medico Legal Purpose





Shrinant Zyle  
 Self started