

UHID : VH-12697/2023

Date : 18-Oct-2023



Name : Mrs. PAWAN TYAGI 52Y / Female

Mobile : 9410650022 (Previous Visit: NA)

Address : 62, AKHLOR ROHANA MUZAFFARNAGAR UTTAR PRADESH

BP(mmHg): 164/103 Weight (Kg): 70 SPO<sub>2</sub>(%): 98 Pulse(bpm): 87

Pain Score: 6 (Score 0: No Pain, 1-3 Mild Pain, 4-7 Moderate Pain, 8-10 Severe Pain)

CHIEF COMPLAINTS : BOTH KNEE PAIN X 5-6 MONTHS

LBA, RIGHT RADIATION

MEDICAL ILLNESS : HTN

INVESTIGATION FINDINGS : X-RAY SHOWS OA BOTH KNEES

MRI SHOWS L4-5 STENOSIS

S.No.	Ⓡ Medicine	Frequency	Duration
1.	TAB GEMCAL DS	1-0-0	30 DAYS
2.	TAB WILLGO CR	1-0-0	30 DAY(S)
3.	TAB REBILD	1-0-0	30 DAY(S)
4.	TAB DVION	WEEKLY	4 WEEKS

DRUG ALLERGY : NIL

*Naughtin m 211 11*

INSTRUCTION(S) : WALKING ALLOWED

KNEE EXERCISES

SOS KNEE REPLACEMENT

*B/L*

*Stress Echo/PAC  
7500360994  
Gaurav Jain*

Please come after ..... days.

Dr. ANUBHAV JAIN  
(M.S (ORTHO))

VTLC/SHEET/OPD/ORTHO/2022/VER2.0

Printed on: 18-Oct-2023 11:25:01 AM

Printed by: Neeraj

Designed by www.softcure.in

*auth*

3rd Km., Jansath Road, Muzaffarnagar-251001 (U.P.)

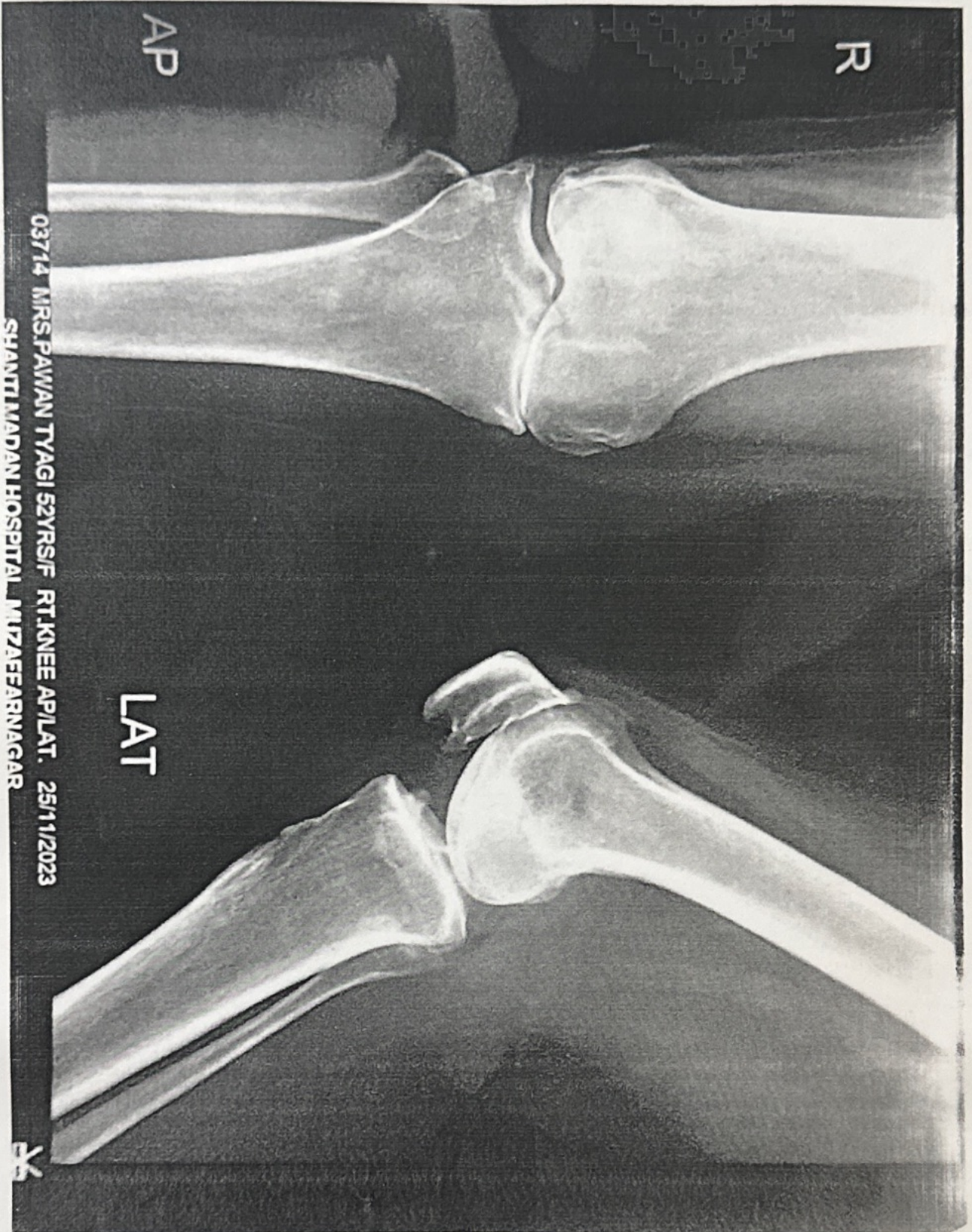
Reg. Office : C-209, Defence Colony, New Delhi-110024, India

www.vardhmanhospital.com

7830803084 / 7830803085 / 9219416543

opdvardhmanhospital@gmail.com

OPD Registration : 3 PM. to 6 PM. 9219456235



R

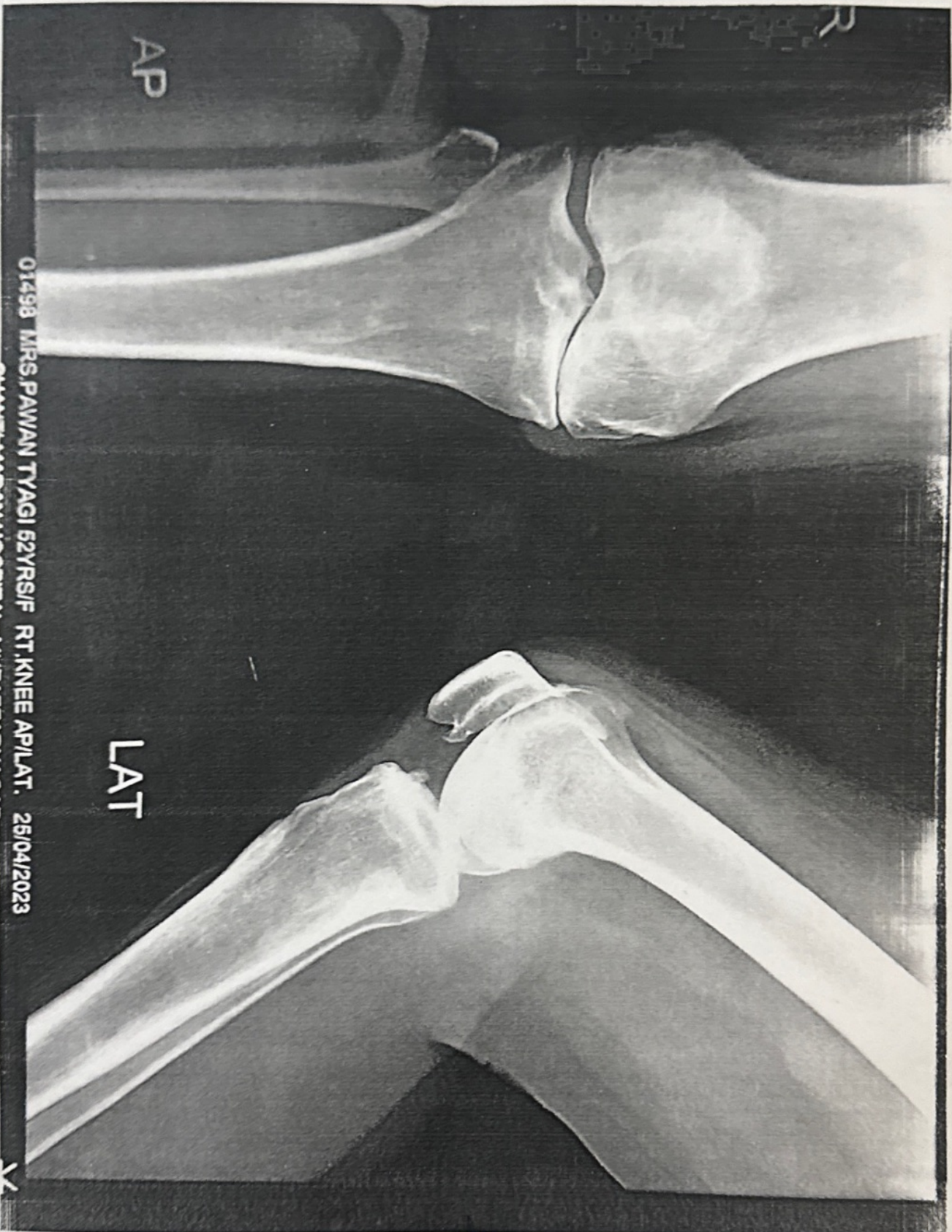
AP

LAT

03714 MRS. PAWAN TYAGI 52YRS/F RT. KNEE AP/LAT. 25/11/2023  
SHANTI MADAN HOSPITAL, MUZAFFARNAGAR

K

*am*



AP

LAT

01498 MRS. PAWAN TYAGI 52YRS/F RT. KNEE AP/LAT. 25/04/2023

*Handwritten signature*



# शान्ति मदन हॉस्पिटल

244, उत्तरी सिविल लाईन, ( धाना सिविल लाईन के सामने )

मुजफ्फरनगर-251001 ( उप्र )

फोन : 9760254747, 9634183737

www.shantimadhanhospital.com | info.shantimadhan@gmail.com

2023/2585

Smt Pawan Tyagi  
57y / Female

26/10/20

Xray (B/L) knee - R/C stance  
Valial

MPV

B/L OA knee

Tab Rac su	100
Cap celestus	100

Linic oil for local app.

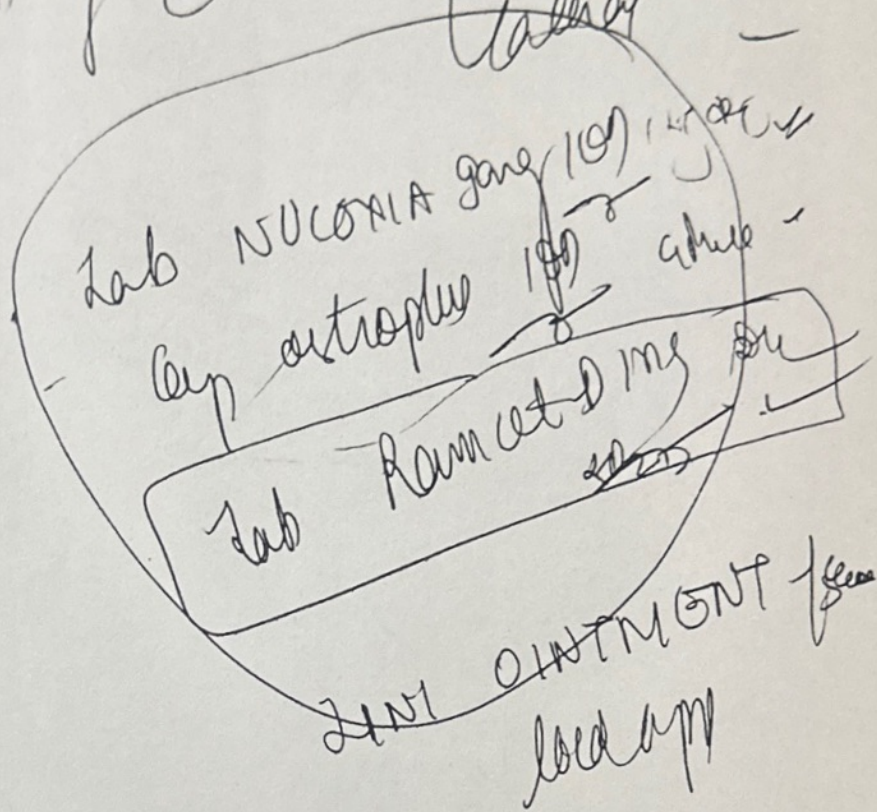
X 7dy

ced

24/11/2023

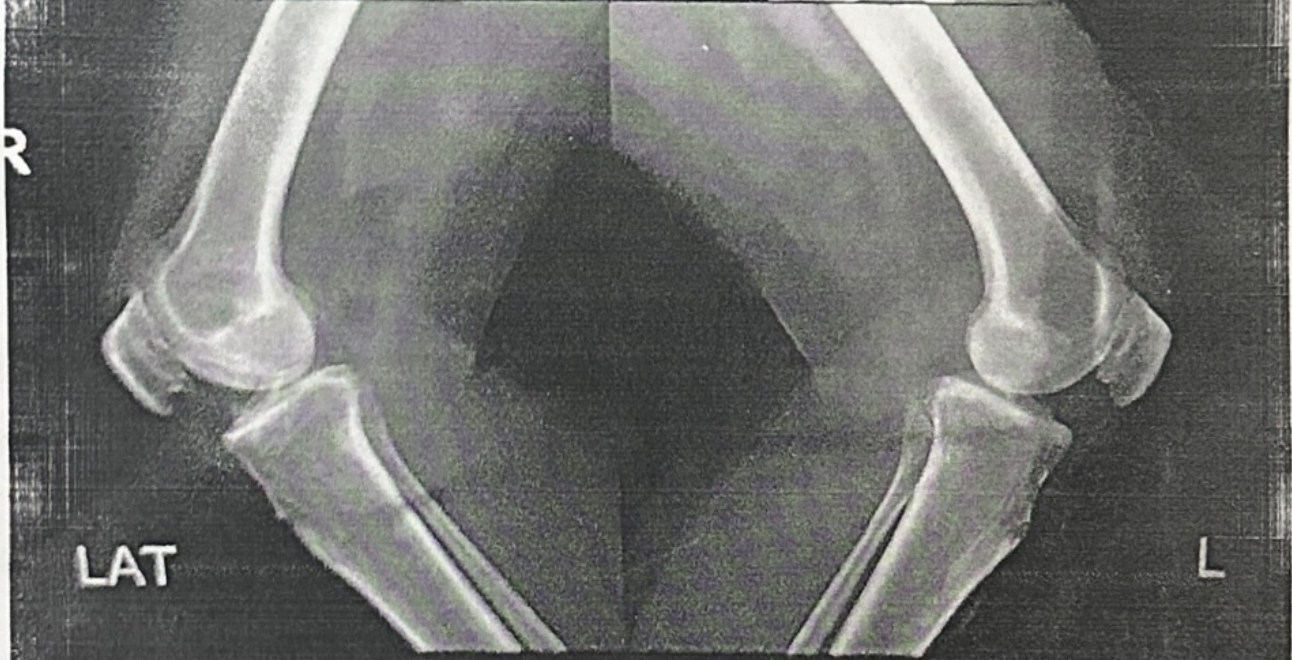
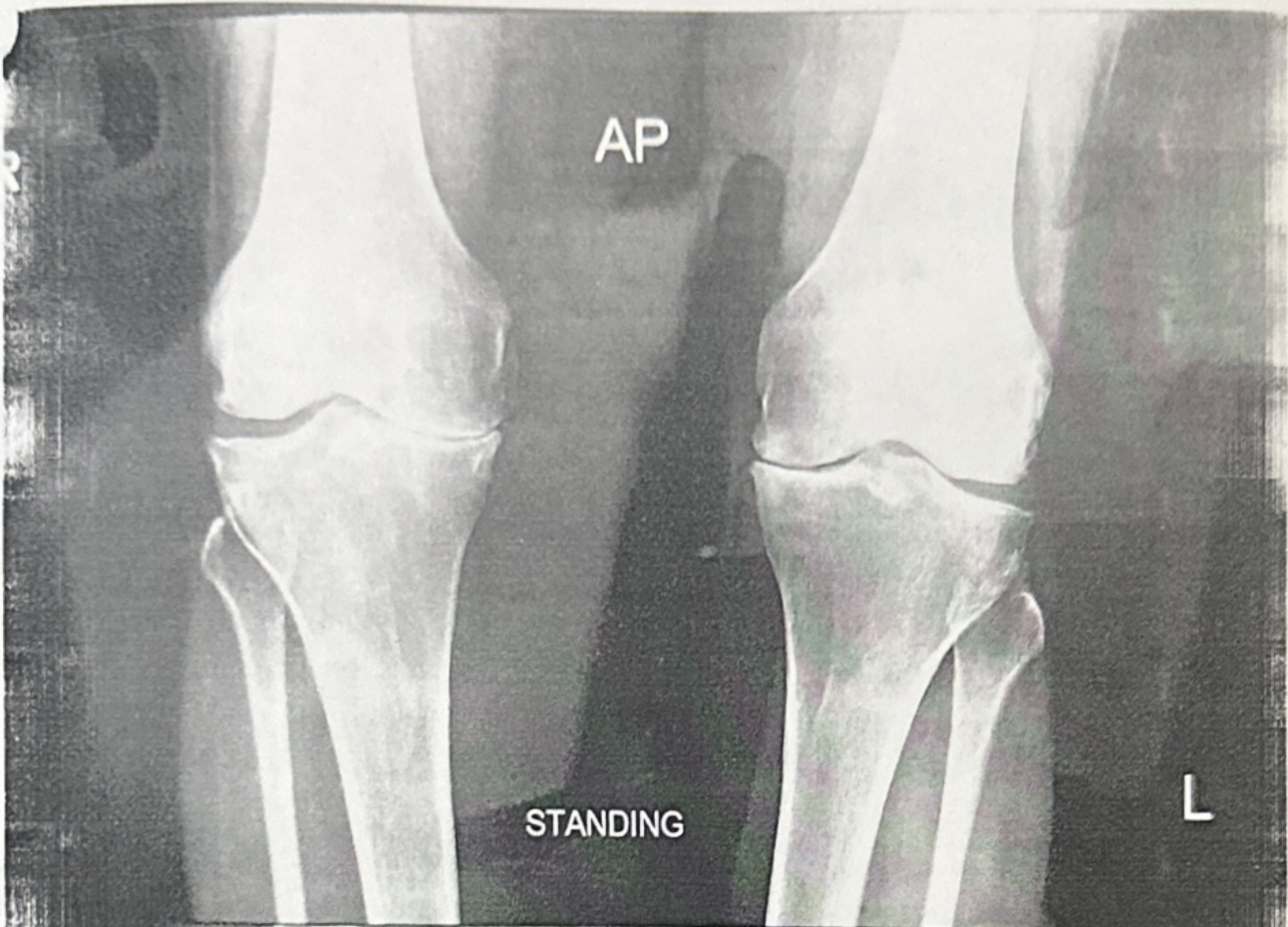
MRI (R) knee

May (R) knee - AP (standing)  
Lateral



Wally

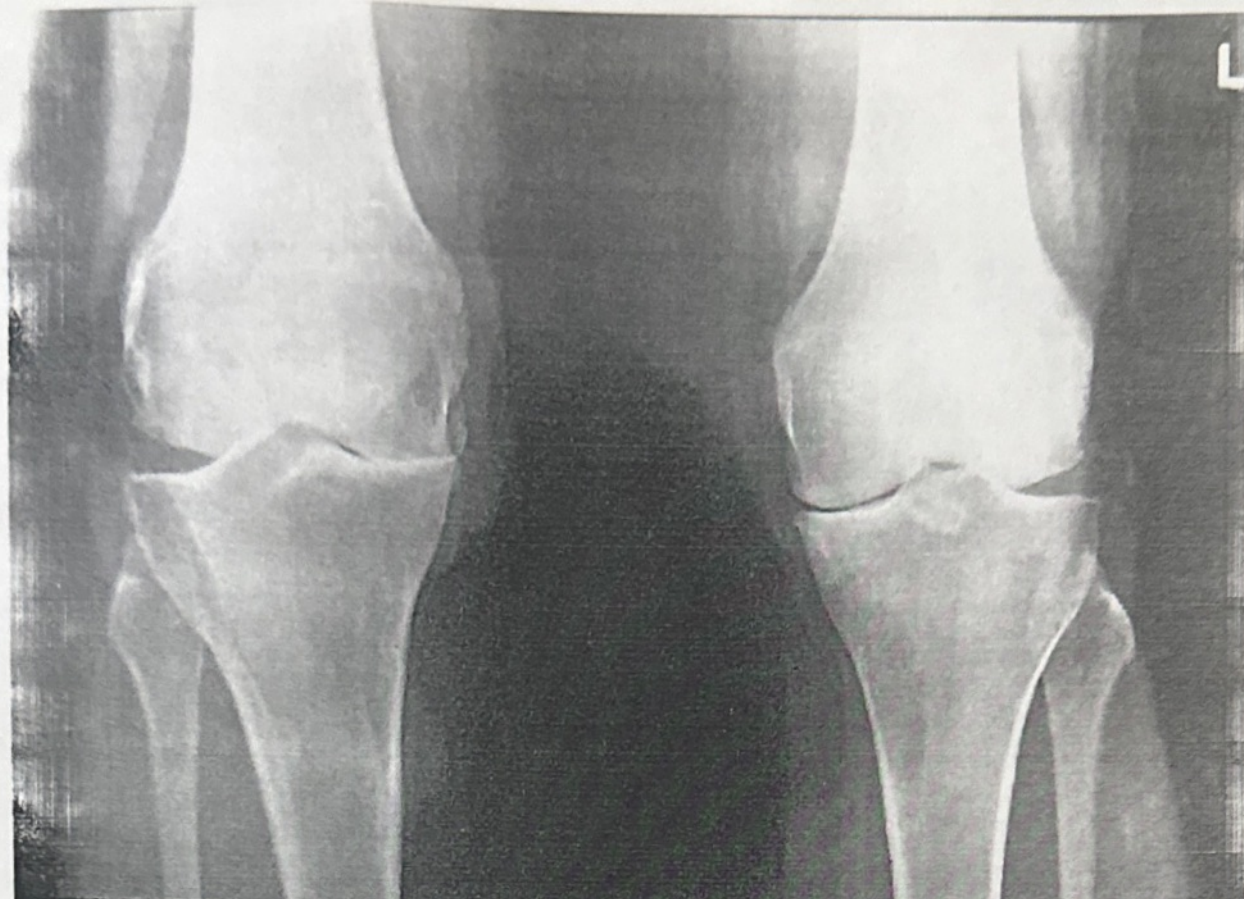
and



03455 MRS.PAWAN TYAGI 62YRS/F B/L KNEES AP/LAT. 27/10/2023  
SHANTI MADAN HOSPITAL. MUZAFFARNAGAR

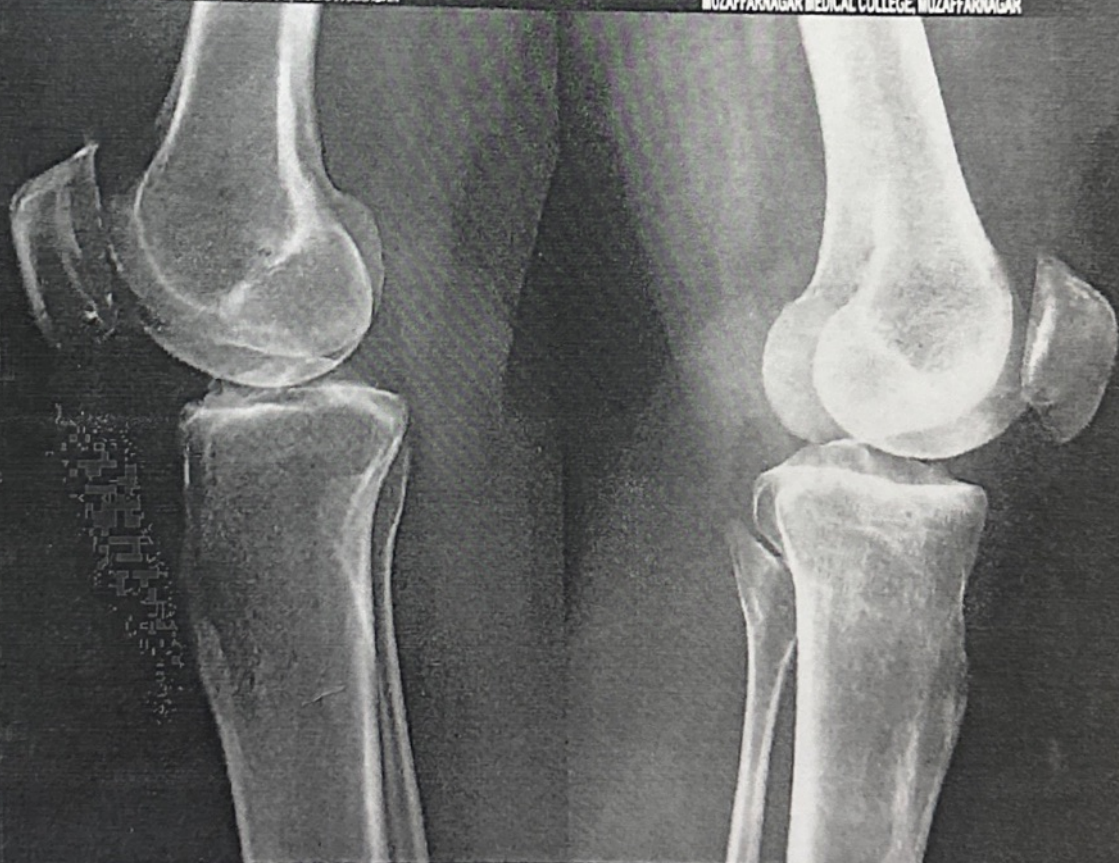

*auth*



PAWAN TYAGI 50YM 060063102.63 B/L Knee AP (ST) LAT 06-Mar-23  
MUZAFFARNAGAR MEDICAL COLLEGE, MUZAFFARNAGAR

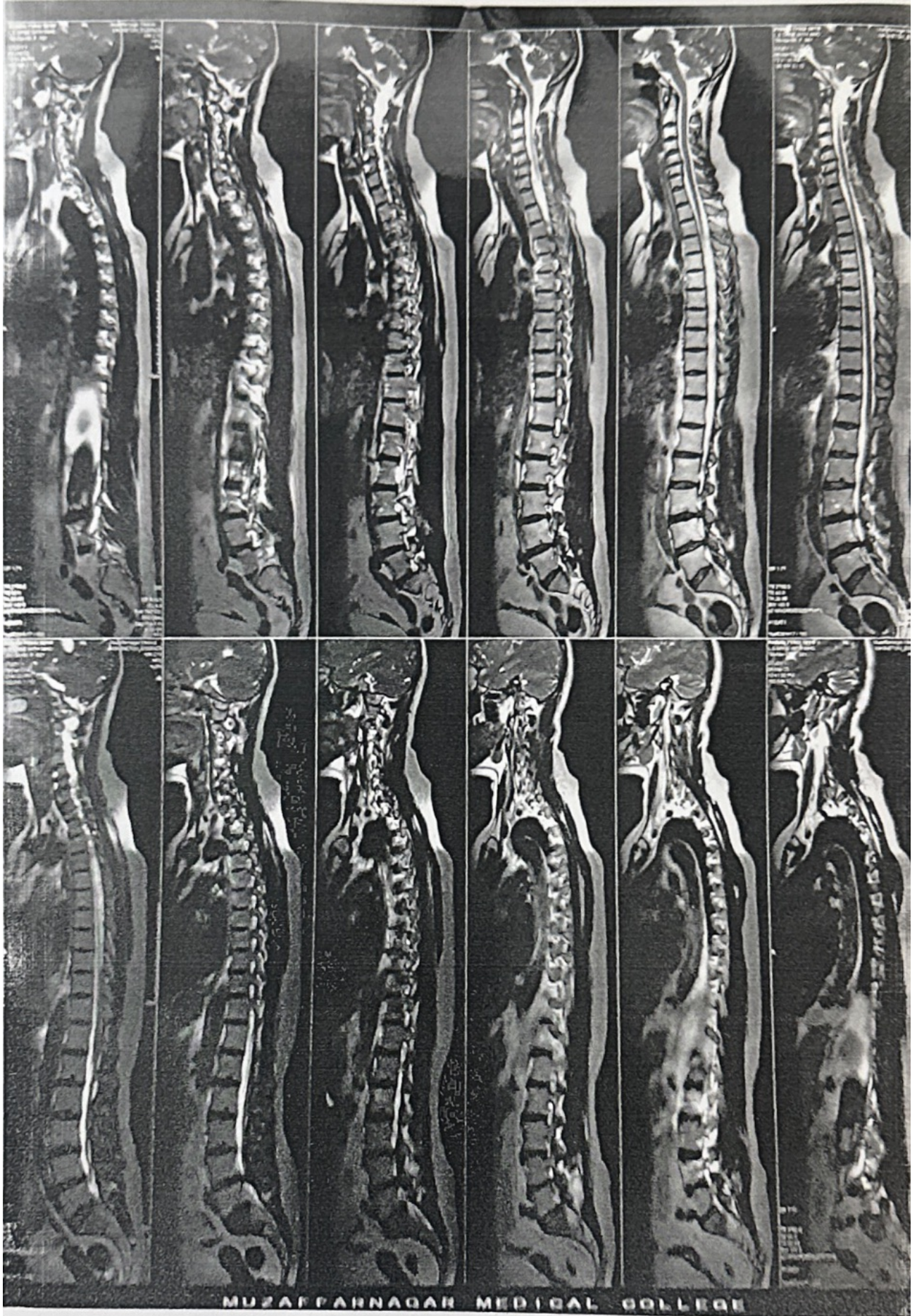PAWAN TYAGI 50YM 060063102.63 Knee AP 06-Mar-23  
MUZAFFARNAGAR MEDICAL COLLEGE, MUZAFFARNAGAR



PAWAN TYAGI 50YF 060130102.63 06-Mar-23  
MUZAFFARNAGAR MEDICAL COLLEGE, MUZAFFARNAGAR

PAWAN TYAGI 50YF 060130102.63 00Y BOTH KNEE LAT 06-Mar-23  
MUZAFFARNAGAR MEDICAL COLLEGE, MUZAFFARNAGAR

acid



MUZAFFARNAQAR MEDICAL COLLEGE

axial





# MUZAFFARNAGAR MEDICAL COLLEGE & HOSPITAL

Opp. Begrajpur Industrial Area, Ghasipura, Meerut Road, Muzaffarnagar (U.P.)

(Department Of Radio - Diagnosis & Modern Imaging)

NAME :- PAWAN TYAGI	AGE / SEX :- 50 Y / FEMALE
REFD BY :- Dr. ANIL SINGH	
DATE :- 06.03.2023	OPD No. & WARD :- 3787018

## MRI L.S. SPINE WITH SCREENING OF WHOLE SPINE

Clinically - LBA

Sequences done:- T1 & T2 SAG; Ax T1 & T2; STIR, COR STIR.

### Report:

- Straightening of lumbar spine curvature is noted.
- Anterior and posterior marginal osteophytes are noted at multiple levels.
- Desiccative disc changes are seen at multiple levels.
- Schmorl's nodes are noted at multiple levels.
- Hemangioma noted in L2 vertebral body.
- L2-L3: Mild diffuse disc bulge causing ventral thecal sac indentation, no nerve root compression.
- L3-L4: Mild asymmetric diffuse disc bulge with propensity towards right side with posterior annular tear causing ventral thecal sac indentation, B/L neural foramina compromise (Rt>Lt), abutting right exiting nerve root.
- L4-L5: Moderate asymmetric diffuse disc bulge causing ventral thecal sac indentation, B/L neural foramina compromise, impinging B/L exiting nerve roots and abutting B/L traversing nerve roots.
- L5-S1: Mild diffuse disc bulge causing ventral thecal sac indentation, abutting right exiting and B/L traversing nerve roots.
- Facetal hypertrophy noted at multiple levels.
- Rest of the vertebral bodies are normal in size, shape & signal intensity.
- The imaged portions of cord & conus medullaris are normal.
- The posterior neural arches are normal.
- No obvious pre/ para vertebral or epidural collection or soft tissue mass seen.
- The para spinal musculature appears normal.
- Bilateral S.I. Joints are normal.

Measurements ( AP distance of spinal canal ) on axial scans					
Level	L1-L2	L2-L3	L3-L4	L4-L5	L5-S1
mm	17	13	12.6	11	9.6

Note: Mild right hydronephrosis.

### Impression:-

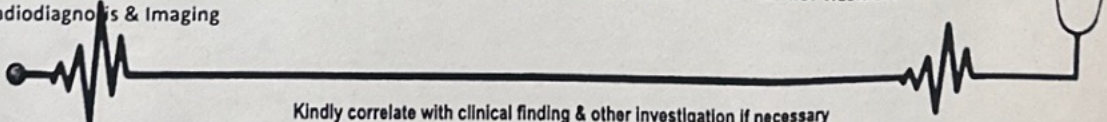
- ❖ Lumbar spondylotic changes as explained above.

Dr Bindu Agrawal  
Prof & HOD  
Radiodiagnosis & Imaging

Dr Gaurav Garg  
Associate Prof

Dr Mayank Chauhan  
Assistant Professor

Dr Manoj Kumar  
Senior Resident



Kindly correlate with clinical finding & other investigation if necessary

Note: Impression is a professional opinion and not a diagnosis. All Modern Machines / Procedures have their limitation.  
If there is variance clinically this examination may be repeated or reevaluated by other investigation.

*acul*


**MUZAFFARNAGAR MEDICAL COLLEGE & HOSPITAL**  
Opp Begrajpur, Industrial Area, Ghasipura, Meerut Road, Muzaffarnagar  
Ph:-01396-252702, 252704

Department of Radiology

NAME:- PAWAN TYAGI	AGE/SEX:- 50Y/M
REFD.BY DR:-	
DATE:- 06.03.2020	O.P.D.NO.:- 62-63
PART TO BE X-RAYED:- B/L KNEE A.P. LATERAL STANDING	

**REPORT:-**

- Joint space is reduced in B/L knee joint (medial>lateral)
- Osteophytes are noted in bones of knee B/L joints.
- No abnormal soft tissue shadow around the knee joint seen.



Dr. SUPREETHI KOHLI  
Professor  
Radiodiagnosis

**Kindly correlate with clinical findings & other investigation if necessary**

Note - Impression is a professional opinion and not a diagnosis. ● All Modern Machine/Procedures have their limitation. If there is variance clinically this examination may be repeated may be repeated or reevaluated by other investigations.





# MUZAFFARNAGAR MEDICAL COLLEGE & HOSPITAL

Opp. Begrajpur Industrial Area, Ghasipura, Meerut Road, Muzaffarnagar (U.P.)

(Department Of Radio - Diagnosis & Modern Imaging)

NAME :- PAWAN TYAGI	AGE / SEX :- 50 Y / FEMALE
REFD BY :- Dr. ANIL SINGH	
DATE :- 06.03.2023	OPD No. & WARD :- 3787018

## MRI L.S. SPINE WITH SCREENING OF WHOLE SPINE

### Screening of Cervical Spine:

- Straightening of cervical spine curvature is noted.
- Anterior and posterior marginal osteophytes are noted at multiple levels.
- Disc osteophyte complex seen indenting ventral thecal sac at multiple levels in cervical spine.
- Altered marrow signal intensity seen at C6-C7 level.
- Rest of the vertebral bodies are normal in shape, size & signal intensity.
- Spinal canal diameters at various cervical levels are within normal range.
- The imaged portions of cord is normal.
- The posterior neural arches are normal.

### Screening of Thoracic Spine:

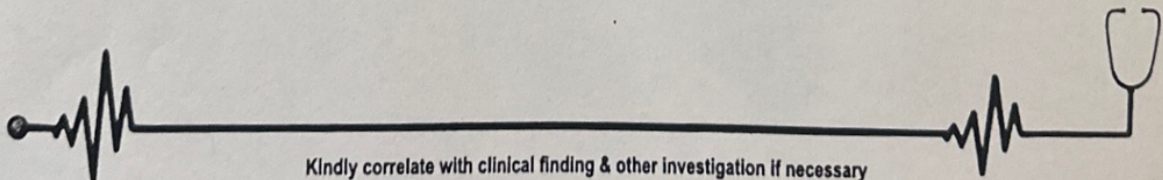
- Normal dorsal curvature is noted.
- Schmorl's nodes noted along superior end plate of D12 vertebral body.
- Anterior and posterior marginal osteophytes are noted at multiple levels.
- Desiccative disc changes are seen at multiple levels.
- No significant disc bulge, herniation noted.
- The posterior neural arches are normal.
- The imaged portion of cord is normal.

Dr Bindu Agrawal  
Prof & HOD  
Radiodiagnosis & Imaging

Dr Gaurav Garg  
Associate Prof

Dr Mayank Chauhan  
Assistant Professor

*May*  
Dr Manoj Kumar  
Senior Resident



Kindly correlate with clinical finding & other investigation if necessary

Note: Impression is a professional opinion and not a diagnosis. All Modern Machines / Procedures have their limitation.  
If there is variance clinically this examination may be repeated or reevaluated by other investigation.

*anil*



Dr. राजगोपाल  
 9897779147

52

OPD CASE PAPER

Patient	PAWAN YAGI	Registration No	2023/3/3787018
Visit No	OPD-1	Visit Date	11/03/06/2023 11:11:02 AM
Ref Organization		Address	MZN
Organization		Department	ORTHOAEDIC
AGE	50		
SEX	F		

मरीज दिनांक 11/03/2023  
 सोमवार (पीर)  
 बृहस्पतिवार (जुमरात)

NPT ✓

LBA is radiolucida (R) low level

is Pain B/L knee

Ads

MRI Lumbo-sacral spine +  
 screening of whole spine

Xray B/L knee (standing)  
 Valial

CBC ✓  
 S. ure acid ✓  
 RA factor ✓  
 vit D3 level ✓  
 ✓  
 ✓

Please bring this slip with every visit. Not for medico legal purposes

RB &

Slightly low

ant

~~(S)~~ (7)

g. uposelath  
+  
g. Nandras  
nsh  
2m

Adi

Tab Sagnoflan 180

—————  
o                      o  
1x1x1                      1x1x1

Cap Pmoden 100

—————  
o                      o  
1x1x1                      1x1x1

Cap Astropus 100

—————  
o                      o  
1x1x1                      1x1x1

X7da

Tab CARTIGEN PRO  
100  
—————  
o  
X4 mas

and

B/L OA tncd zLBN (radikulatid) 8/1 des

70 day  
99

Tab Myontung 100  
Tab Paksan 100  
Cap Asthoplex 100

Tab Cartigen Pro  
3 month 100

8445849072  
Mondal

Tab Ultracet 1ms  
5mg qd ctd

Tramadol + Paracetamol  
375 + 325mg

29/08/2023

DEVIVO GOLF (Ec) 100

- 1) Tab Nacoma Gome 100
- 2) Cap Asthoplex 100
- 3) Tab Ultracet 1ms

aul

Prof. (Dr.) Parvez Ahmed

M.S. (Orthopaedics)  
Consultant Orthopaedic Surgeon  
(Spine, Joint Replacement & Bone Tumor Surgeon)

Patient's Name:

Kawan Yagi

प्रो० (डा०) परवेज अहमद

M.S. (Orthopaedics)

Date: 03 DEC 2023

Age/Sex:

59yrs/F

OA BIL knee walsynow

Quadriceps str 500 (10)

ETROBAX 900 (10)

osicaceto (10)

Bone NT (10)

Caprefino P3000000

Rejoint of fl w

kg

For Appointment: Ph.: 8126408468  
Dr. D.K. Jain Hospital - 9568004955

Email: drahmedparvez@yahoo.com  
drahmedparvez@gmail.com

Sunday Closed

well



Regd. No. RMEE1901351

# शान्ति अद्वैत हॉस्पिटल





244, उत्तरी सिविल लाईन, आना सिविल लाईन के सामने,  
गुजफरनगर-251001 (बि०प्र०)

## रेडियालोजी विभागा

Patient Name... *Dr. Kishor* ..... Age... *62/m* .....

Part of X-Ray... *chest AB/RT shoulder* ..... Date... *17.5.23* .....

Referred by... *P. Gaurav Jain* .....

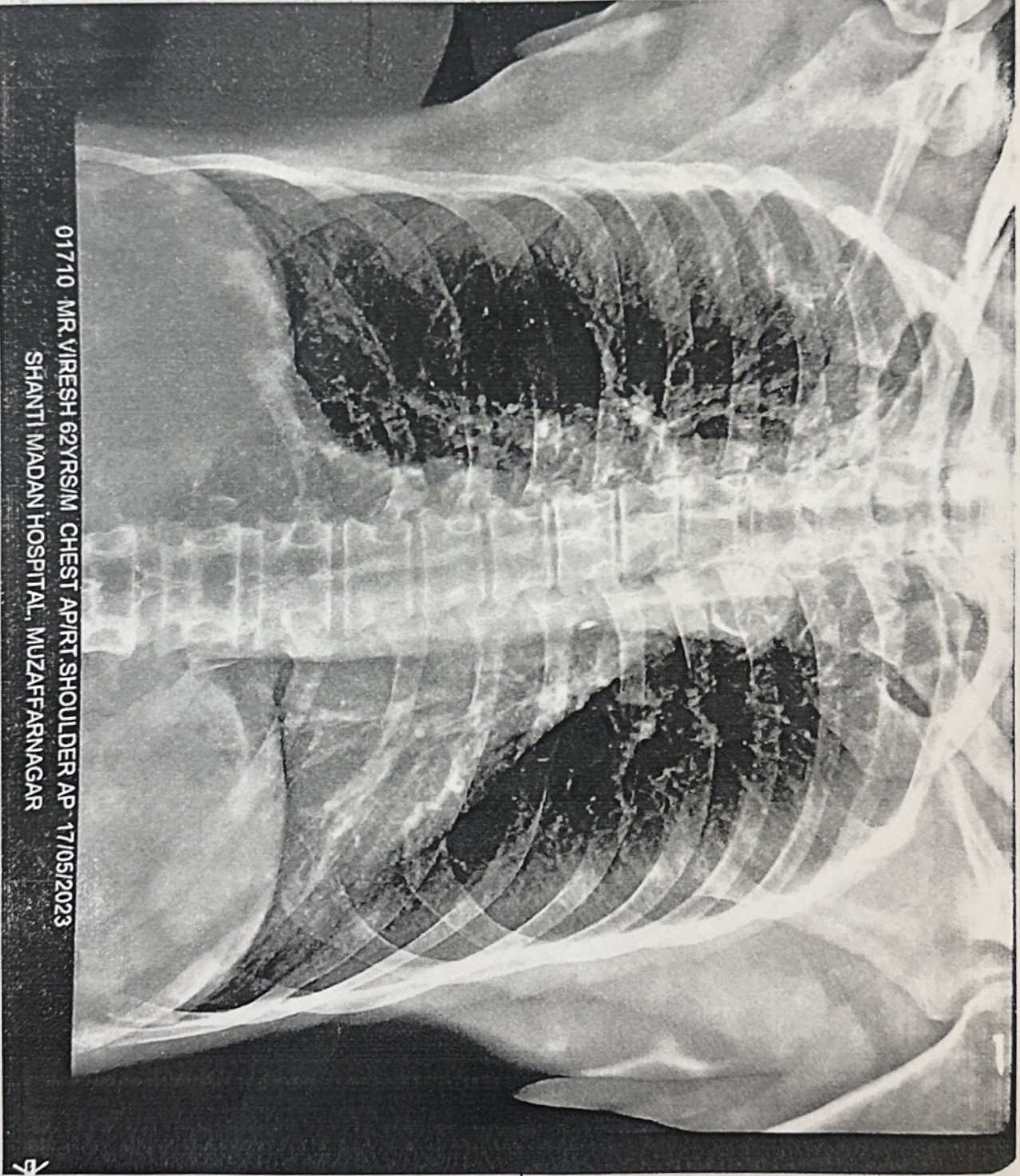


0131-2646211 Reception Mob. 09760254747, 09634183737  
Website - www.smgroupshospital.com E-mail- info@shantimadanhospital.com



*auth*





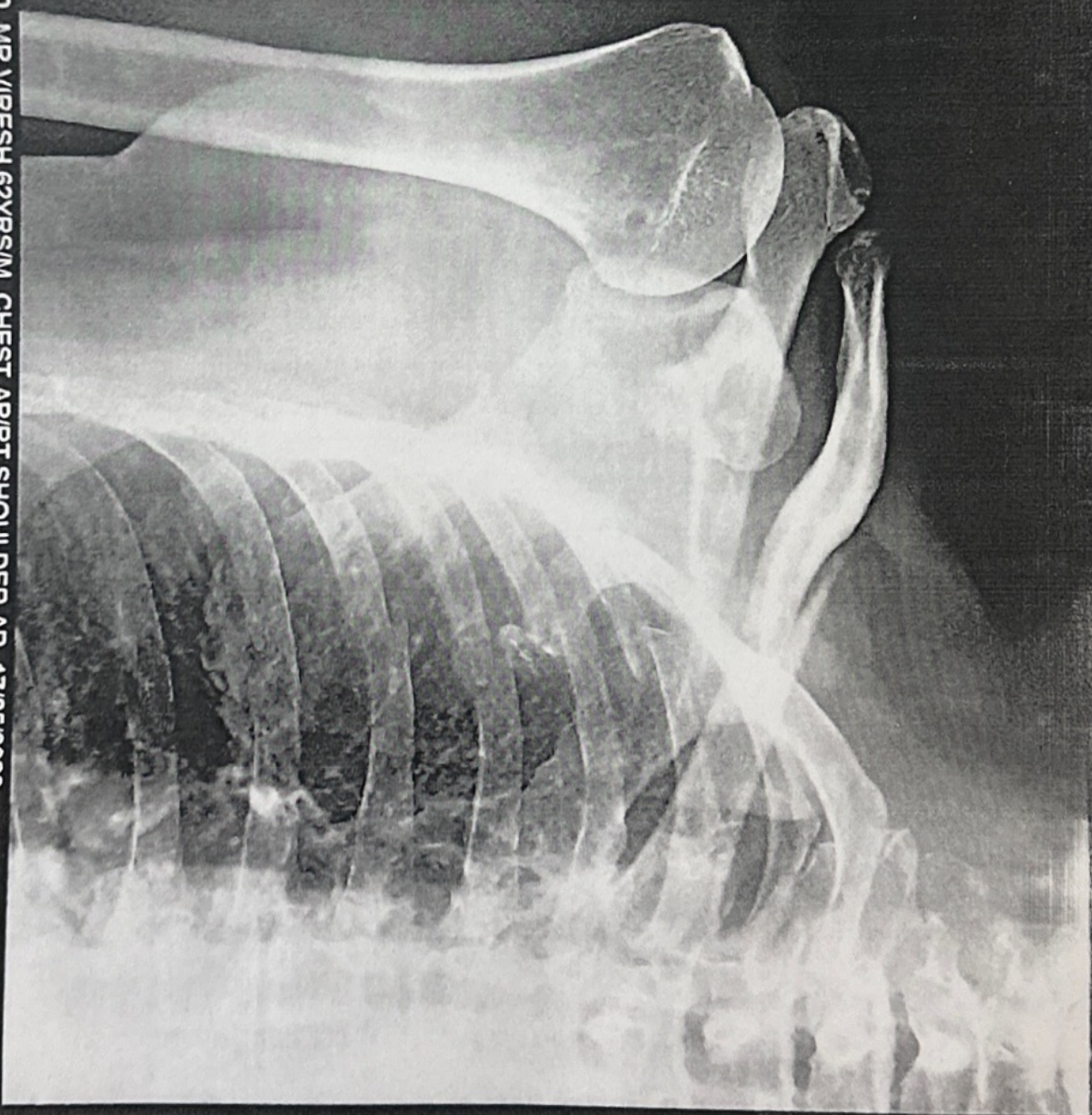
01710 -MR. VIRESH 62YRS/M CHEST AP/RT.SHOULDER AP - 17/05/2023  
SHANTI MADAN HOSPITAL, MUZAFFARNAGAR

*aml*



R

01710 MR. VIRESHH 62YRSM CHEST AP/RT SHOULDER AP 17/05/2023  
SHANTI MADAN HOSPITAL, MUZAFFARNAGAR



*Handwritten signature or initials in blue ink.*

22

# डा० गौरव जैन

एम०एस० (ऑर्थो)  
के०जी०एम०सी०, तरुनऊ

Reg. No. RMEE1901351

## शान्ति मदन हॉस्पिटल



244, उत्तरी सिविल लाईन  
धाना सिविल लाईन के सामने  
मुजफ्फरनगर

Shri Veresh

17/05/2023

62y 1M

Diabetes Mellitus  
Hypertension  
Asthma  
Thyroid Function  
Allergies  
CAD

ITC of Hxnts (R) c# cloude

c# scapula

Xray (R) shoulder - c cloude - MR

Xray chest - MR view

Cap ashiopus 100  
tab MUCOXIA MR 4mg  
5ml 40

समय : दोपहर 3 बजे से 7 सायं बजे तक  
रविवार दोपहर 12 बजे से 3 बजे तक  
24 घण्टे इमरजेन्सी सुविधा

रजि० नं० 48870 (उ० प्र०)

नोट:- इस पर्चे पर 10 दिन में एक बार  
ओर दिखा सकते है।

सम्पर्क:- 09760254747

Not for medico legal purpose.

सुविधायें • फ्रैक्चर का इलाज • कुल्हा एवं घुटना प्रत्यारोपण (जोइन्ट रिप्लेसमेन्ट) • दूरबीन विधि द्वारा घुटने की जांच व इलाज (आर्थोस्कोपी)  
• शिद की हड्डी के ऑपरेशन (स्पाइनल सर्जरी) • जन्मजात टेढ़े पैरों के ऑपरेशन • इलियाजरोव विधि द्वारा पैरों की लम्बाई बढ़ाना

and