

Patient Name	: Mr. Sunil Kumar Singh	Patient UHID	: MM02407258
Age	: 55Y	Gender	: Male
Admission Date	: 02/11/2022 13:48	Discharge Date	:
Encounter Type	: Inpatient	Encounter ID	: 19410893
Consultant Incharge	: Dr Rajesh Puri	Specialty	: Gastroenterology
Location	: 15th Floor B2B3	Bed No	: 4404

Patients Address : H.NO Q91 ,PHASE 2,PALLAVPURAM ,MODIPURAM ,Modipuram S.O,MEERUT,India,250110

Date of Discharge : 03/11/2022 17:18

Name of Consultant : Dr Rajesh Puri

Bed No : 15th Floor B2B3/SINGL1_F15/4404

Discharge Status : Discharged to Home (Routine Discharge)

Diagnosis & Co-morbidities

Current Admission : Small internal haemorrhoids (Colonoscopy 03/11/2022)
Ileojejunul Ulcers ?Inflammatory ?Infective

Previous Illness : Diabetes Mellitus type -2
Cervical spondylosis

Advice on Discharge

Discharge Medication :

- ✓ Tablet PANTOCID 40mg once daily before breakfast ^{7 AM}
- Tablet AMARYL 1mg twice daily 10 AM - 10 PM
- Tablet GLYCOMET 500mg twice daily 10 - 10
- Tablet RIFAGUT 400mg twice daily for 2 days 10 - 10
- ✓ Tablet DROTIN-DS 1 tablet twice daily for 2 days then as and when needed for abdominal pain 10 - 10
- ✓ Capsule VSL#3 twice daily for 5 days 8 AM - 8 PM
- ✓ Capsule MYORIL 8 mg twice daily for 3 days 10 - 10
- ✓ Syrup SPARACID - O 10ml thrice daily before food for 10 days 1 - 1 - 1
- ALEX LOZENGES twice daily for 2 days 10 - 10
- BETADINE Gargles (2 teaspoon) rinse thrice daily for 3 days 1 - 1 - 1
- THROMOPHOB Ointment twice daily for local application for 5 days 1 - 1
- VOLINI SPRAY thrice daily (on neck) for 5 days 1 - 1 - 1

OD - Once a day ; BD - Twice a day ; TDS - Thrice a day ; QID - Four times a day ; HS - Bedtime ; tsf- Tea spoon full.

Diet : Fiber free Soft Diet

Discharge Instructions : Continue Anti-Diabetic Medication as per Endocrinologist advice
Hot water fomentation, Soft cervical collar

Follow up :

Review with Gastroenterology OPD with Dr. Rajesh Puri after 3 days with biopsy report.
(before coming contact (before coming contact Ms. Sukhjeet Kaur @ 9999411125)

Accredited by



JCI Certificate (CN 3628.2)



Certificate No H-2011-0073



Certificate No MC-2346

For Emergency & Ambulance: Dial @ 1068

Medanta - Gurugram

✚ Sector - 38, Gurugram, Haryana - 122 001, India
☎ +91 124 4141 414 Fax: +91 124 4834 111

Medanta - Mediclinic

✚ E-18, Defence Colony, New Delhi - 110 024
☎ +91 11 4411 4411 Fax: +91 11-2433 1433

Medanta - Mediclinic Cybercity

✚ UG Floor, Building 10C, DLF Cybercity, Phase II, Gurugram 122 001
☎ +91 124 4141 472

Regd. Office: Global Health Limited, E-18, Defence Colony, New Delhi - 110 024, India Tel: +91 11 4411 4411 Fax: +91 11 2433 1433

✉ info@medanta.org

www.medanta.org

Corporate Identity Number - U85110DL2004PLC128319

11/4/2022

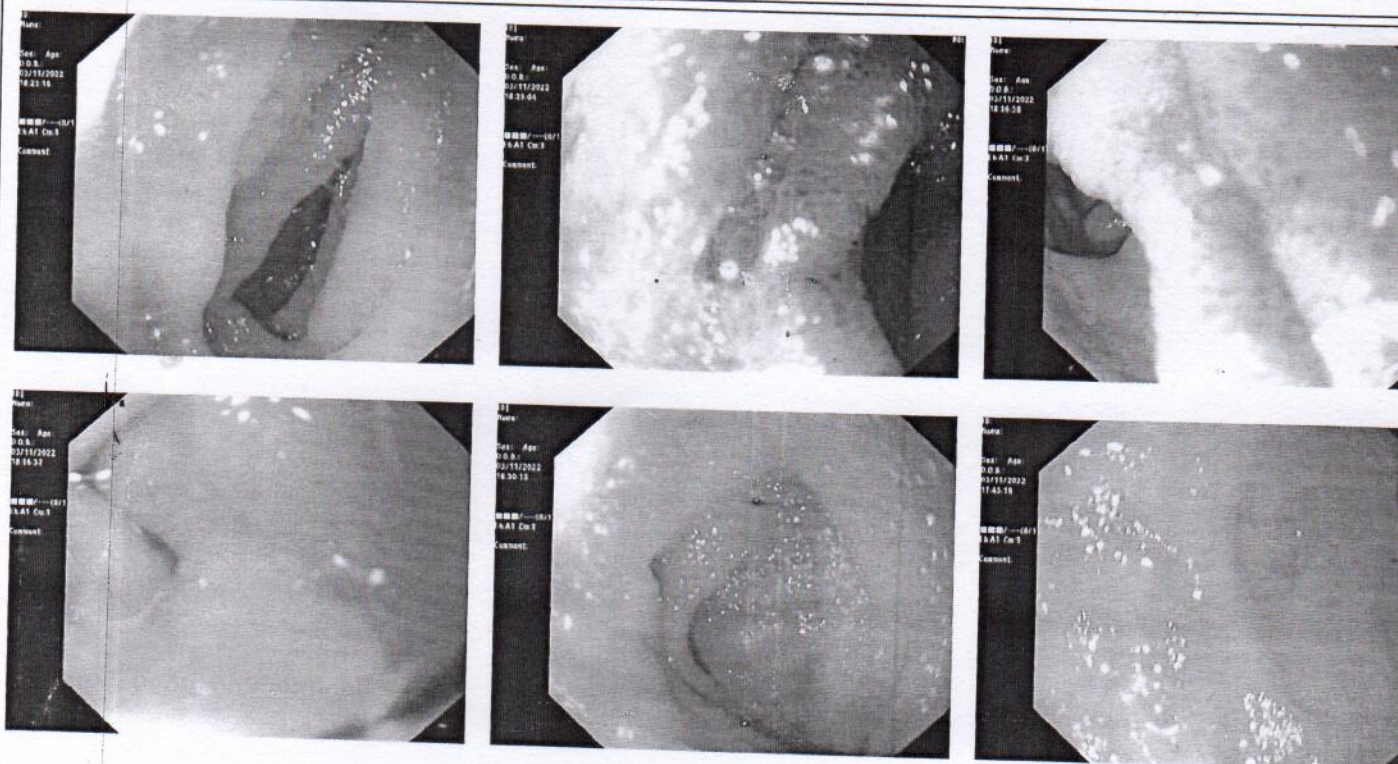


Medanta Institute of Digestive and Hepatobiliary Sciences
 DIVISION OF GASTROENTEROLOGY AND HEPATOLOGY
 SECTOR - 38, GURGAON HARYANA - 122001 (INDIA)
 Ph NO.- 0124 4141414

Patient Name: Mr. Sunil Kumar Singh
 UHID: MM02407258
 Encounter No.: 19410893

Age/Sex: 55/M

Ref By: Dr Rajesh Puri
 Date: 03-11-2022 04:05:00 PM
 Procedure: SBE antegrade



SBE ANTEGRADE REPORT

Procedure was done after explaining the benefits / complications / alternative treatments strategy to the patient.

Due consent for procedure as well as for sedation was obtained.

Findings

Antegrade single balloon enteroscopy done.

Seen upto proximal ileum.

Few small superficial ulcers with erosions noted in distal jejunum and proximal ileum, from which multiple biopsies taken and sample sent for histopathological examination.

Second part of duodenum shows few erosions.

No immediate post procedure complications.

Conclusions

Ileojejunal ulcers ?inflammatory ?Infective

To collect biopsy report from histopathology lab and consult your doctor.

Please follow post procedure instructions given

Prepared by - TZ (Time - 5:55pm)

DR. R. SUD DR. A. S. PURI DR. R. PURI DR. N. SARAF DR. S. R. MISHRA DR. N S CHOUDHARY
 DR. A. KATHURIA DR. Z. SHARMA DR. S SUD DR. B K SAHU DR. S KOUL

Tirupati Liver and Gastro Care Center



Complete Day Care Center Of Gastro & Gynae

डा० प्रशान्त सोलंकी

एम०डी०, डी०एम० (गैस्ट्रोएन्ट्रोलॉजी)

पेट, आँत, जिगर, पित्ताशय, पैनक्रियाज रोग एवं एण्डोस्कोपिस्ट

Dr. Prashant Solanki

M.D., D.M.

Senior Consultant Gastroenterologist
Therapeutic Endoscopist

Formerly at :

- GB Pant Hospital, N. Delhi
- SGPGI, Lucknow
- Sir Ganga Ram Hospital, N. Delhi

Date: 27/10/22

INVESTIGATION

- Mantoux Test
- CBC / Hemogram
- Urine ^R_{M/E} & C/S
- Bld Sugar F, PP, HBA1C
- Bld Urea / S. Creatinine
- S. Bilirubin ^T_D ✓
- SGPT / SGOT ✓
- S. Alk. Phosphatase ✓
- PT with Control ✓
- S. Albumin ✓
- T3, T4, TSH
- Lipid Profile ✓
- S. Uric Acid
- S. Na⁺ / K⁺ / Ca²⁺ ✓
- HBs Ag / Anti HCV / HIV 1&2
- S. Amylase, S. Lipase
- USG ABD / CECT
- CxR-PA view
- X-ray Abd Erect
- UGI Endoscopy
- Colonoscopy
- ERCP
- EUS / FNAC
- Fibro Scan
- HBV DNA Quantitative
- HCV RNA Quantitative
- HCV Genotype
- Wt. Kg.
- PR Mt.
- BP MMHG
- SPO₂

~~Mr. Smit Kumar Singh~~
Mr. Smit Kumar Singh
Hc T2DM, RA.P. FLD
Hyperlipidemic
Actu

Specimen from higher center
(AIIMS New Delhi / Medanta Medcity Gurgaon)
May need - Capsule endoscopy for small bowel.

DBE both antegrade & retrograde
LACE & Glesopy.
Bx from affected area in small bowel slope biopsy

Refer to Gastroenterologist for Fibroscan.
Difal 400 1mg
Cal NIZONIDE 500 & B1
Ceftaz 200 1B1
LFT-N
Kg

In Emergency / Visiting Consultant Gastroenterologist

SIDDHI VINAYAK MEDICAL CENTER

Jagriti Vihar, Opp. Medical College, Gate No. 1, Meerut

एडवांस बुकिंग कराकर आगे का अपॉइंटमेंट लेकर जाएँ।

फोन पर नाम लिखवाने के लिए

10:00 से 12:00 बजे के बीच फोन करें।

Ph.: 0121-2603166, 9997756918

अपॉइंटमेंट द्वारा दिया गया समय अनुमानित
अद्यानक इमरजेंसी आने पर समय बिना पूर्व
दिये बदला या कैंसिल भी किया जा सकता है।

SUNDAY CLOSED (रविवार अवकाश)

CLINIC

डी-4, सम्राट पैलेस
(लोकप्रिय अस्पताल के सामने)
गढ़ रोड, मेरठ।

क्लीनिक खुलने का समय : 9 बजे से 6 बजे तक

डॉ० साहब के बैठने का समय : 11 बजे से 6 बजे तक

Dr. Rajesh Puri
 MBBS, MD (Med), DNB (Gastro), MNAMS
 Senior Director - Interventional Gastroenterology
 rajesh.puri@medanta.org
 Mobile: 99994 11125, 98116 38338
 Regd. No. 004599

Patient Name: Mr Sunil Kumar Singh
 Age: _____
 UHID: _____ Sex: _____

Chief Complaint:

- NIDDA Diagnosis:

History of Present illness/ Medical History:

40-50
 - TB

Past History:

Family History:

Plaw

Co-Morbidity:

Diarrhoea CT film

H/O Allergy:

- HR CT chest

Medical H/D:

- man tur turt
 - Quanch fosen TB gold

Current Medication:

Plaw
 C Amv.
 + Centurmy
 C single kull

Physical Examination:

Amv

Accredited by



JCI certificate
 (CN - 3628.2)



Certificate No
 H-2011-0073

For Emergency & Ambulance Dial: 1068

Medanta - Gurugram
 + Sector - 38, Gurugram, Haryana, India
) 0124 4141 414

Medanta - Medielinic
 + E-18, Defence Colony, New Delhi
) 011 4411 4411

Medanta - Medielinic Cybercity
 + UG Floor, Building 10C, DLF Cybercity, Phase II, Gurugram
) 0124 4141 472

Regd. Office: Global Health Limited, E-18, Defence Colony, New Delhi, India Tel: 011 4411 4411

info@medanta.org

www.medanta.org

Corporate Identity Number - U85110DL200

Department of Laboratory Medicine - HISTOPATHOLOGY**GI Endoscopic Biopsy 1 Container- HPE with IHC/Special Stains if needed**

Biopsy Number: B/19427/22

Histopathology Report

SPECIMEN: Jejunal Lesion

GROSS: Received multiple soft tissue bits ranging from 2 to 3 mm. All processed in one block.**MICROSCOPIC EXAMINATION:**

Section shows jejunal mucosa with focal surface ulceration which is covered by granulation tissue. There is focal increase in IELs. Lamina propria shows a moderate acute and chronic inflammatory infiltrate admixed with lymphoid aggregates. Focal cryptitis is seen. Gastric metaplasia is not seen.

No giardia/ granulomas seen.

IMPRESSION: Jejunal Lesion: Active jejunitis.

- Negative for granulomas/specific pathology.

NOTE: Similar picture can be seen in infections, NSAIDs and other drug induced mucosal damage and also as mucosal manifestation of Underlying Crohn's disease.

Grossed By: Dr. Swastika

Transcribed By: Ziauddin

*****End of Report*****



Department of Laboratory Medicine - HISTOPATHOLOGY


Please Note

1. Test results are to be clinically correlated.
2. Storage and discard of biological specimen/materials shall be as per Medanta's specimen retention policy.
3. The biological specimen/ materials may be used for educational and research purposes.
4. Test results are not valid for medico-legal purposes.
5. In case of any query related to the test results, please contact [0124 4141414].

Authorized by

Dr Lipika Lipi
Senior Consultant

Released by

Dr Lipika Lipi
Senior Consultant

Specimen No: 3022021710, Specimen Type: GI Mucosal Biopsy

Authorized: 07 Nov 2022 14:49, Released: 07 Nov 2022 14:36, Ordered: 03 Nov 2022 18:18, Collected: 03 Nov 2022 18:20,
Received: 03 Nov 2022 18:43, Registered: 03 Nov 2022 18:44*Slides can be issued after 48 hrs (Between 3-5 pm) | Specimen will be discarded after 1 month | Original set of slides will be retained in the department*



Medanta, Sec-38, Gurgaon

Discharge Summary

Patient Name	: Mr. Sunil Kumar Singh	Patient UHID	: MM02407258
Age	: 55Y	Gender	: Male
Admission Date	: 02/11/2022 13:48	Discharge Date	:
Encounter Type	: Inpatient	Encounter ID	: 19410893
Consultant Incharge	: Dr Rajesh Puri	Specialty	: Gastroenterology
Location	: 15th Floor B2B3	Bed No	: 4404

Patients Address : H.NO Q91 ,PHASE 2,PALLAVPURAM ,MODIPURAM ,Modipuram S.O,MEERUT,India,250110

Date of Discharge : 03/11/2022 17:18

Name of Consultant : Dr Rajesh Puri

Bed No : 15th Floor B2B3/SINGL1_F15/4404

Discharge Status : Discharged to Home (Routine Discharge)

Diagnosis & Co-morbidities

Current Admission : Small internal haemorrhoids (Colonoscopy 03/11/2022)
Ileocejunal Ulcers ?Inflammatory ?Infective

Previous Illness : Diabetes Mellitus type -2
Cervical spondylosis

Advice on Discharge

Discharge Medication :

- Tablet **PANTOCID** 40mg once daily before breakfast
- Tablet **AMARYL** 1mg twice daily
- Tablet **GLYCOMET** 500mg twice daily
- Tablet **RIFAGUT** 400mg twice daily for 2 days
- Tablet **DROTIN-DS** 1 tablet twice daily for 2 days then as and when needed for abdominal pain
- Capsule **VSL#3** twice daily for 5 days
- Capsule **MYORIL** 8 mg twice daily for 3 days
- Syrup **SPARACID - O** 10ml thrice daily before food for 10 days
- ALEX LOZENGES** twice daily for 2 days
- BETADINE** Gargles (2 teaspoon) rinse thrice daily for 3 days
- THROMOPHOB** Ointment twice daily for local application for 5 days
- VOLINI SPRAY** thrice daily (on neck) for 5 days

OD - Once a day ; BD - Twice a day ; TDS - Thrice a day ; QID - Four times a day ; HS - Bedtime ; tsf- Tea spoon full.

Diet : Fiber free Soft Diet

Discharge Instructions : Continue Anti-Diabetic Medication as per Endocrinologist advice
Hot water fomentation, Soft cervical collar

Follow up

: Review with Gastroenterology OPD with Dr. Rajesh Puri after 3 days with biopsy report.
(before coming contact (before coming contact Ms. Sukhjeet Kaur @ 9999411125))

Accredited by



Dr. RAJESH PURI
MBBS, MD (Med), D.N.D. (Gastro), M.N.A.M.S.
Senior Director-Interventional Gastroenterology
Medanta Institute of Digestive & Hepatobiliary Sciences
Medanta-The Medicity
Sector-38, Gurgaon-122001
Gen. No. 12, Reg. No. 004559, DMC-3123

Dr. Abhishek Kathuria
MBBS, MD (Medicine), DM (Gastroenterology)
Consultant-Gastroenterology
Medanta Institute of Digestive and Hepatobiliary Sciences
Medanta-Gurugram
Sector-38, Gurugram-122 001
Gen. No. 10096, EMC-4018
For Emergency & After Hours Contact @ 1068

Medanta - Gurugram

✦ Sector-38, Gurugram Haryana - 122 001, India
T: +91 11 4411 4411 Fax: +91 124 4634 111

Medanta - Mediclinic

✦ E-18, Defence Colony, New Delhi - 110 024
T: +91 11 4411 4411 Fax: +91 11 2433 1433

Medanta - Mediclinic Cybercity

✦ JE Floor, Building 100, DLF Cybercity, Phase II, Gurgaon
T: +91 124 4141 472

Patient Name	: Mr. Sunil Kumar Singh	Patient UHID	: MM02407258
Age	: 55Y	Gender	: Male
Admission Date	: 02/11/2022 13:48	Discharge Date	:
Encounter Type	: Inpatient	Encounter ID	: 19410893
Consultant Incharge	: Dr Rajesh Puri	Specialty	: Gastroenterology
Location	: 15th Floor B2B3	Bed No	: 4404

Diet was upgraded as tolerated. During hospital stay, he was managed with Intravenous fluids and other supportive measures. Now patient is being discharged with follow up advice and medication.

Significant Medication Given : Injection PANTOCID, Injection PERINORM, Injection TRAMADOL

Procedure/Surgery

: - Colonoscopy was done on 03/11/2022.
 Findings :- Colonoscope passed till terminal ileum, Visualized terminal ileum is normal, Ileocecal valve, caecum, ascending colon, transverse colon, descending colon, sigmoid colon and rectum shows normal mucosal and vascular pattern. Small internal haemorrhoids noted. No immediate post procedure complications.
 Conclusion :- Small internal haemorrhoids.

- Single balloon enteroscopy antegrade was done on 03-11-2022
 Findings :- Antegrade single balloon enteroscopy done. Seen upto proximal ileum. Few small superficial ulcers with erosions noted in distal jejunum and proximal ileum, from which multiple biopsies taken and sample sent for histopathological examination. Second part of duodenum shows few erosions. No immediate post procedure complications.
 Conclusions :- Ileojunal ulcers ?inflammatory ?infective.

Gastro-Intestinal Surgery / Procedure : No *

Condition at Discharge

: Stable.

INVESTIGATIONS

Laboratory : Attached

Consultant Incharge

WHEN TO OBTAIN URGENT CARE:

In case of any problem like:-

1. Fever/Jaundice
2. Loose stools/motions/vomiting/vomit contain blood or passing black stools like coal tar.
3. Bleeding from any site
4. Chest pain, breathing difficulty, profuse sweating, giddiness, pain in abdomen.
5. Reduced urine output.
6. Severe weakness/severe mouth ulcers.
7. Rash over skin, swelling over body.
8. Unconscious

In case of Emergency contact
 RESIDENT INCHARGE - 9560398932

Accredited by



For Emergency & Ambulance: Dial @ 1068

Dr. RAJESH PURI
 M.B.B.S, MD (Med), D.M.B. (Gastro), M.N.A.M.S
 Senior Director-Interventional Gastroenterology
 National Institute of Classical & Hepatobiliary Sciences
 Medanta-The Medicity
 Sector-38, Gurgaon-122001
 R-3, No. HM-054594, PNC-3125

Medanta - Gurugram

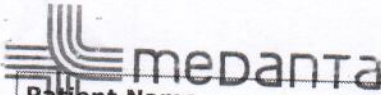
✦ Sector - 38, Gurugram, Haryana - 122 001, India
 ☎ +91 124 4141 414 Fax: +91 124 4834 111

Medanta - Medielinic

✦ E-18, Defence Colony, New Delhi - 110 024
 ☎ +91 11 4411 4411 Fax: +91 11 2433 1433

Medanta - Medielinic Cybercity

✦ UG Floor, Building 10C, DLF Cybercity, Phase-II, Gurgaon
 ☎ +91 124 4141 472



Patient Name	: Mr. Sunil Kumar Singh	Patient UHID	: MM02407258
Age	: 55Y	Gender	: Male
Admission Date	: 02/11/2022 13:48	Discharge Date	:
Encounter Type	: Inpatient	Encounter ID	: 19410893
Consultant Incharge	: Dr Rajesh Puri	Specialty	: Gastroenterology
Location	: 15th Floor B2B3	Bed No	: 4404

Follow up in ORTHOPEDIC Outpatient Department after 3 days with prior telephonic appointment for neck pain.

Medical History & Presenting Complaints

: Mr. Sunil Kumar Singh, 55 years old male, presented with complaints of pain in abdomen and weight loss since 1 month. History of diarrhea on and off. He was admitted here for further evaluation and management.

Physical & Systemic Examination

Pulse : 78 /min
Blood Pressure(mmHg) : 120/80
Respiratory rate : 20 /min
Respiratory : Air entry equal bilaterally
Per Abdomen : Soft and non-tender
Cardio Vascular System : S1, S2 normal

Allergies

: ALLOPATHIC MEDICATION

Course in Hospital

: Patient was admitted with above mentioned complaints for which relevant investigations were done which showed Hemoglobin- 14.2 gm/dl, White blood cells- 7.81×10^3 , Bilirubin- 0.82 mg/dl, Albumin- 4.38 gm/dl, Serum Glutamic Oxaloacetic Transaminase (SGOT) / Serum Glutamate-Pyruvate Transaminase (SGPT) - 41U/L/ 52U/L, Gamma-Glutamyl Transferase (GGT)- 19 U/L, Alkaline Phosphatase- 118 U/L, Serum Creatinine- 0.50 mg/dl, Calcium - 9.3 mg/dl, Sodium- 143 mmol/L, Potassium- 40.0 mmol/L, Prothrombin Time (PT) / International Normalized Ratio (INR) - 10.4 Sec/ 0.98.

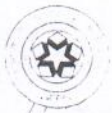He was started on Intravenous fluids along with supportive measures.

After informed consent, patient underwent colonoscopy was done on 03/11/2022, which small internal haemorrhoids noted. No immediate post procedure complications. Patient underwent single balloon enteroscopy (antegrade) was done on 03-11-2022 which showed few small superficial ulcers with erosions noted in distal jejunum and proximal ileum from which multiple biopsies taken and sample sent for histopathological examination. Second part of duodenum shows few erosions. No immediate post procedure complications.

Orthopedic opinion taken in view of neck pain and advice followed. Patient was requested to stay in hospital in view of neck pain; however, he was not willing for the same.

Dr. RAJESH PURI
 MBBS, MD (Med), D.N.B. (Gastro), M.N.A.M.S.
 Senior Director-Interventional Gastroenterology
 Medanta Institute of Digestive & Hepatobiliary Sciences
 Medanta-The Medicity
 Sector-38, Gurgaon-122001
 Reg. No. H-122001-DMC-3193

Accredited by



For Emergency & Ambulance: Dial @ 1068

Medanta - Gurugram

+ Sector - 38, Gurugram, Haryana - 122 001, India
 +91 124 4141 414 Fax: +91 124 4834 111

Medanta - MedClinic

+ E-18, Defence Colony, New Delhi - 110 024
 +91 11 4411 4411 Fax: +91 11 2433 433

Medanta - MedClinic Cybercity

+ UG Floor, Building 10C, DLF Cybercity, Phase II, Gurugram 122 002
 +91 124 4141 472

Regd. Office: Global Health Limited, E-18, Defence Colony, New Delhi - 110 024, India Tel: +91 11 4411 4411 Fax: +91 11 2433 1433
 info@medanta.org www.medanta.org



Patient Name	: Mr. Sunil Kumar Singh	Patient UHID	: MM02407258
Age	: 55Y	Gender	: Male
Admission Date	: 02/11/2022 13:48	Discharge Date	:
Encounter Type	: Inpatient	Encounter ID	: 19410893
Consultant Incharge	: Dr Rajesh Puri	Specialty	: Gastroenterology
Location	: 15th Floor B2B3	Bed No	: 4404

PHYSICIAN ASSISTANT - 8219255182 (For Dr Randhir Sud)

Or any other medical problem for which you think urgent attention is required report to emergency at Medanta-The Medicity at the earliest possible. (0124-4141414, Ext.No. 2404 & 2406).

Access your medical reports and follow up with Doctors through video conferencing by downloading Medanta eCLINIC App by visiting www.medanta.eclinic.org

Activate your eCLINIC account using Medanta Patient UHID (MM*****)

For any assistance or query call +124-4855017 or write to eclinic@medanta.org

FOR EMERGENCY AND AMBULANCE PLEASE CONTACT: 1068.

Summary prepared by (MT):

Consultant Dr Rajesh Puri **Phone No** 9811638338/9999411125/8700747406

Sr. Resident Dr. Hitesh **Phone No** 7984434399

Signature

Book your video/Tele consultation through MEDANTA eCLINIC App:

- Download **MEDANTA eCLINIC app** from **Google Play Store/iOS App store**.
- Old patients can book the appointment by log in to the app.
- Medanta hospital **UHID** (Example: MM01234567) is the **log in ID** & your **mobile number** is the **password**.
- Choose date/slot as per the availability of the doctor.
- Upload all your previous prescription & reports in the app.
- Pay the fee online.
- Call 0124-4855017/9311985750/9313985750, if you have any queries.

Medanta Care at Home provides services in the comfort of your home.

- Sample Collection
- Nursing Visits
- Medicine Delivery
- Child and Adult Vaccination

To book, Call +91 124 4834565 or Whatsapp 8130771414.

Signature

Consultant :



JCI Certificate
ICN 3628 21



Certificate No
H-2011-0073



Certificate No
MC-2346

Accredited by

For Emergency & Ambulance: Dial @ 1068

Medanta - Gurugram

✚ Sector - 38, Gurugram, Haryana - 122 001, India
☎ +91 124 4141 414 Fax: +91 124 4834 111

Medanta - Mediclinic

✚ E-18, Defence Colony, New Delhi - 110 024
☎ +91 11 4411 4411 Fax: +91 11 2433 1433

Medanta - Mediclinic Cybercity

✚ UG Floor, Building 10C, DLF Cybercity, Phase II, Gurgaon - 122 002
☎ +91 124 4141 472

Regd. Office: Global Health Limited; E-18, Defence Colony, New Delhi - 110 024, India Tel: +91 11 4411 4411 Fax: +91 11 2433 1433

✉ info@medanta.org

www.medanta.org

Corporate Identity Number - U85110DL2004PLC

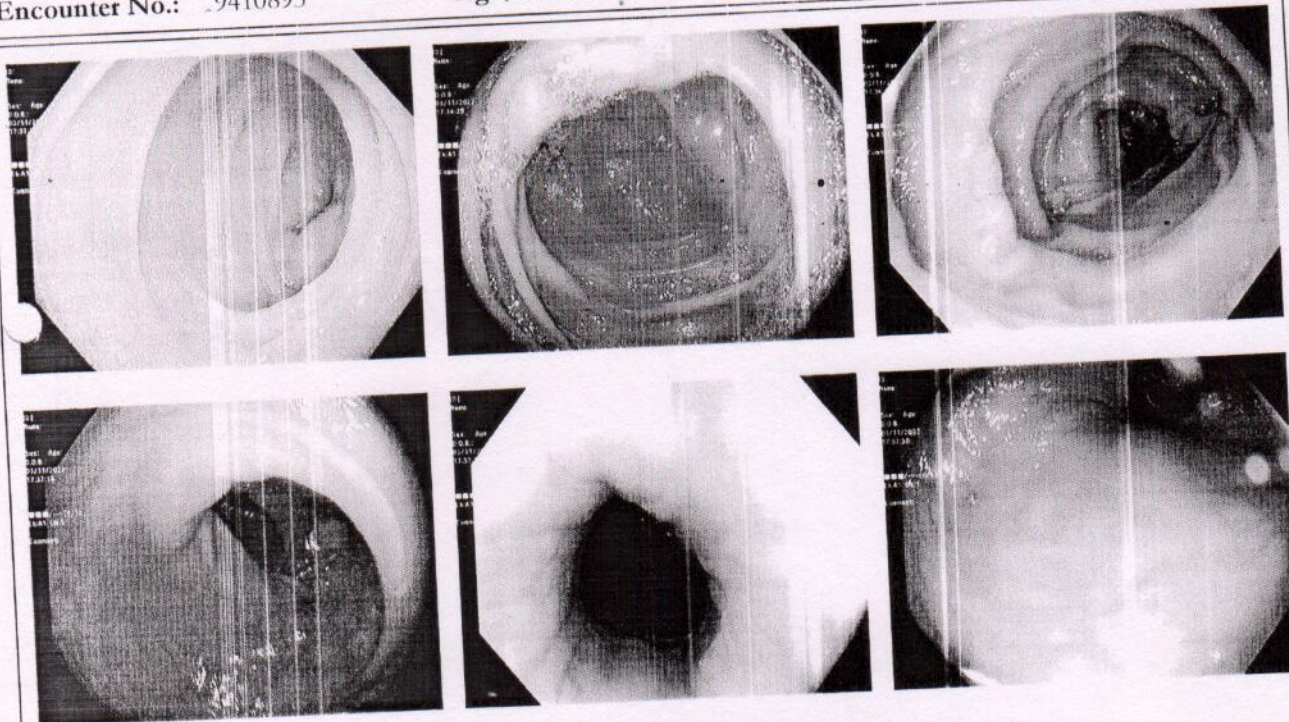


Medanta Institute of Digestive and Hepatobiliary Sciences
DIVISION OF GASTROENTEROLOGY AND HEPATOLOGY
SECTOR - 38, GURGAON HARYANA - 122001 (INDIA)
Ph NO.- 0124 4141414

Patient Name: Mr. Sunil Kumar Singh
UHID: MM02407258
Encounter No.: 19410893

Age/Sex: 55/M

Ref By: Dr Rajesh Puri
Date: 03-11-2022 04:04:00 PM
Procedure: COLONOSCOPY



COLONOSCOPY REPORT

Procedure was done after explaining the benefits / complications / alternative treatments strategy to the patient.
Due consent for procedure as well as for sedation was obtained.

Findings

Colonoscope passed till terminal ileum
Visualized terminal ileum is normal
Ileocecal valve, caecum, ascending colon, transverse colon, descending colon, sigmoid colon and rectum shows normal mucosal and vascular pattern.
Small internal haemorrhoids noted.
No immediate post procedure complications.

Conclusion

Small internal haemorrhoids

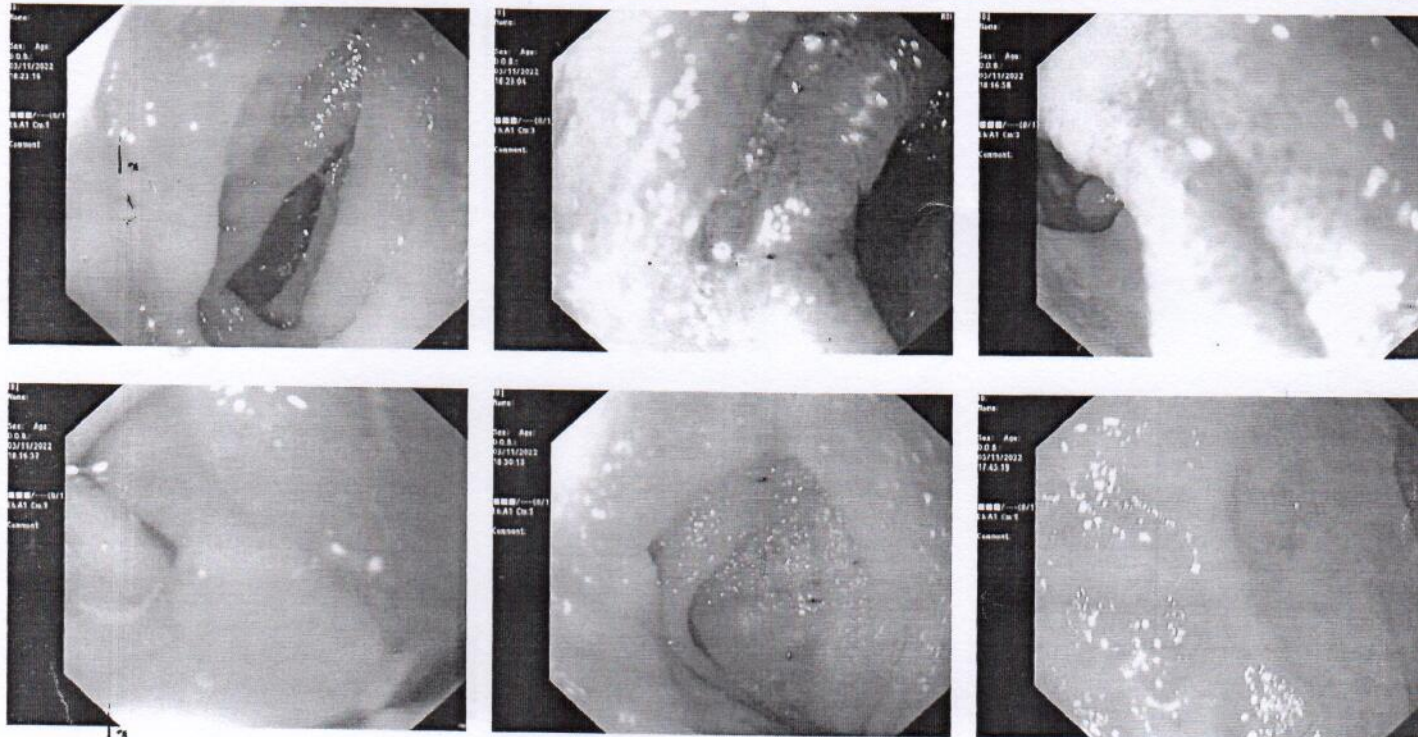
Please follow post procedure instructions given
Prepared by - TZ (Time - 4:48pm)

DR. R.SUD DR. A. S. PURI DR. R. PURI DR. N.SARAF DR. S. R. MISHRA DR. N S CHOUDHARY
DR. A. KATHURIA DR. Z. SHARMA DR. S SUD DR. B K SAHU DR. S KOUL

Patient Name: Mr. Sunil Kumar Singh
UHID: MM02407258
Encounter No.: 19410893

Age/Sex: 55/M

Ref By: Dr Rajesh Puri
Date: 03-11-2022 04:05:00 PM
Procedure: SBE antegrade



SBE ANTEGRADE REPORT

Procedure was done after explaining the benefits / complications / alternative treatments strategy to the patient.
 Due consent for procedure as well as for sedation was obtained.

Findings

Antegrade single balloon enteroscopy done.
 Seen upto proximal ileum.
 Few small superficial ulcers with erosions noted in distal jejunum and proximal ileum, from which multiple biopsies taken and sample sent for histopathological examination.
 Second part of duodenum shows few erosions.
 No immediate post procedure complications.

Conclusions

Ileojejunal ulcers ?inflammatory ?Infective

To collect biopsy report from histopathology lab and consult your doctor.
 Please follow post procedure instructions given.
 Prepared by - TZ (Time - 5:55pm)

DR. R.SUD DR. A. S. PURI DR. R.PURI DR. N.SARAF DR. S. R. MISHRA DR. N S CHOUDHARY
 DR. A. KATHURIA DR. Z. SHARMA DR. S SUD DR. B K SAHU DR. S KOUL



Patient Name	Mr. Sunil Kumar Singh	Age/sex	55 Yrs/ M	Date	October 26, 2022
Referred by	Dr. Malay Sharma, DM	Slip No	17955	Films	04

(Identity of the patient can't be verified)

NCCT+CECT WHOLE ABDOMEN

PROTOCOL: Serial thin axial sections in arterial and venous phase were obtained in the spiral mode on a 16 slice CT-scanner from the level domes of diaphragms to the pubic symphysis after administration of oral, rectal and I.V. contrast media. Thereafter coronal and sagittal reformats were done for further references.

FINDINGS:

- CT study reveals evidence of homogeneously enhancing mildly thickened small bowel loops predominantly involving jejunal & ileal loops on post contrast study.
- Mild homogeneously enhancing mucosal thickening is noted in recto-sigmoid & sigmoid colon with no evidence of fat stranding.
- Homogeneously enhancing multiple lymphnodes noted at left para aortic, right para caval, mesenteric (Jejunal) & right common iliac region, largest measuring 11x8.7 mm at left para aortic region.
- Liver is enlarged in size, measuring approx. 17.6 cm in cranio-caudal extent with diffuse low CT attenuation pattern. No dilatation of intrahepatic biliary radicles is seen. Liver margins are normal. Hepatic veins are normally opening into IVC. Hepatic vasculature appears normal. Portal venous system of liver appears normal.
- Gall bladder is well distended. Walls are normal. No hyperdense calculus or focal mass lesion is seen.
- CBD is normal
- Pancreas has normal CT appearance. Portal and splenic veins are normal and reveals normal enhancement.
- Spleen is normal in size, shape and C.T. appearance.
- Both kidneys are normal in their anatomical structure and functions. Pelvicalyceal system is not dilated. Renal cortical thickness is normal bilaterally. Renal marginal are smooth and regular bilaterally. Peri-nephric fat and gerotas fascias are normal. Renal arteries and renal veins are normal bilaterally. Both ureters are normal in their course and caliber. Psoas muscles are normal bilaterally.
- Urinary-bladder is well distended with presence of homogeneously enhancing conferential wall thickening of maximum thickness 7.2 mm at dome of urinary bladder.
- Prostate is enlarged in size, measuring approx. 4.1x5.1x4.8 cm volume 50 cc.
- Seminal vesicles appear normal
- Contrast filled stomach appears normal.

Dr. Akhil Sharma
Dr. Akhil Sharma
MD (Consultant Radiologist)

Dr. Hemant Agrawal DMRD	Dr. Prakash Chandra Datta DMRD, DMAB	Dr. Suresh Chandra DMRD, DMAB	Dr. Harsh Mehta DMRD	Dr. K. K. Gupta DMRD
----------------------------	---	----------------------------------	-------------------------	-------------------------

B.S. Tomar
Contd...2



Om Imaging & Diagnostic Centre Pvt. Ltd

E.K. Road, Adjacent Meghdoot Cinema, Meerut - 250 002 • Phones : (0121) 2664277 • 94122 25847

2

- Contrast filled descending colon, transverse colon, ascending colon and caecum appears normal. Peri-rectal fat planes are normal. Ischio-rectal fossae are normal.
- Aorta and IVC appear normal. Pelvic musculature appears normal and bilaterally symmetrical.
- Degenerative changes are noted in visualized spine.


IMPRESSION: CT findings suggestive of:

- Homogeneously enhancing mildly thickened small bowel loops predominantly involving jejunal & ileal loops on post contrast study.
- Mild homogeneously enhancing mucosal thickening in recto-sigmoid & sigmoid colon with no evidence of fat stranding.
- Abdominal lymphadenopathy.

--- Findings likely suggestive of Inflammatory vs Infective etiology
Adv: Clinico-pathological correlation.

- Hepatomegaly with hepatic steatosis. Adv: LFT correlation.
- Cystitis. Adv: Urine R/M.
- Prostatomegaly.

Please correlate clinically.


Dr. Akhil Sharma
MD (Consultant Radiologist)

Dr. Hemant Agarwal DMRD	Dr. Prayanshu Dixit DMRD, DNB	Dr. Smita Garg MBBS, FAI	Dr. Hemant Mittal DMRD	Dr. R. K. Gupta DMRD
----------------------------	----------------------------------	-----------------------------	---------------------------	-------------------------

B.S. Tomar

Name: Mr. Sunil Singh

Dated: 22.10.2022

Examination: ULTRASONOGRAPHY OF THE WHOLE ABDOMEN.

Referred By: Dr. Malay Sharma MD DM

LIVER – Appears mildly enlarged in size and shows generalised increase in parenchymal echogenicity. No major focal mass or intrahepatic bile duct dilatation seen.

GALL BLADDER – Is normally distended.
No major abnormal echoes seen in the lumen with no wall thickening.

CBD measures 3 mm in diameter.
PORTAL VEIN appears normal in diameter.

PANCREAS – Shows no alteration of echopattern in the visualised area.

SPLEEN – Appears normal in size and echopattern.

BOTH KIDNEYS – Appears normal in size and echopattern.
No major calcific area or obstructive changes seen.

URINARY BLADDER – Is moderately distended (volume about 221 ml).
No abnormal echoes seen in the lumen with no major wall thickening.
No calcific area is seen at lower end of either ureter.
Post-void residual urine - 33 ml.

PROSTATE – Weight about 32 gm.

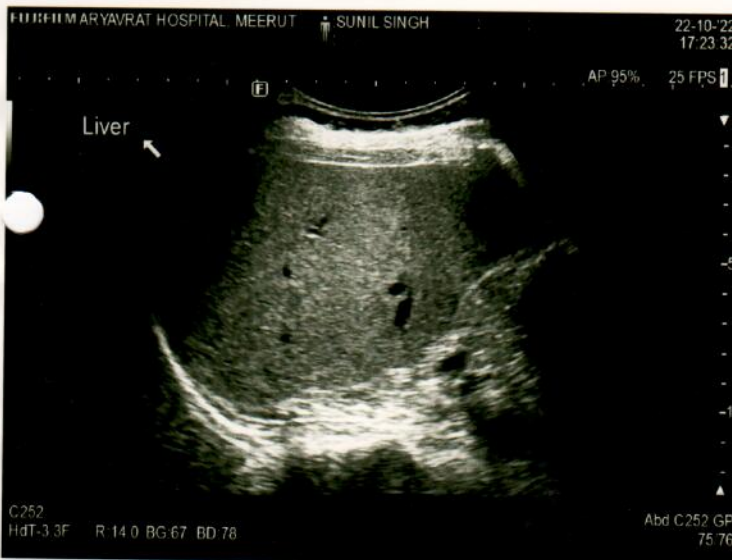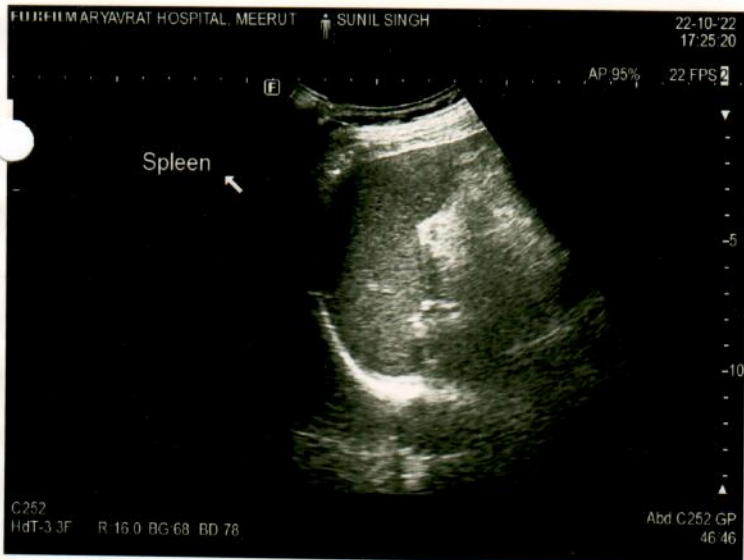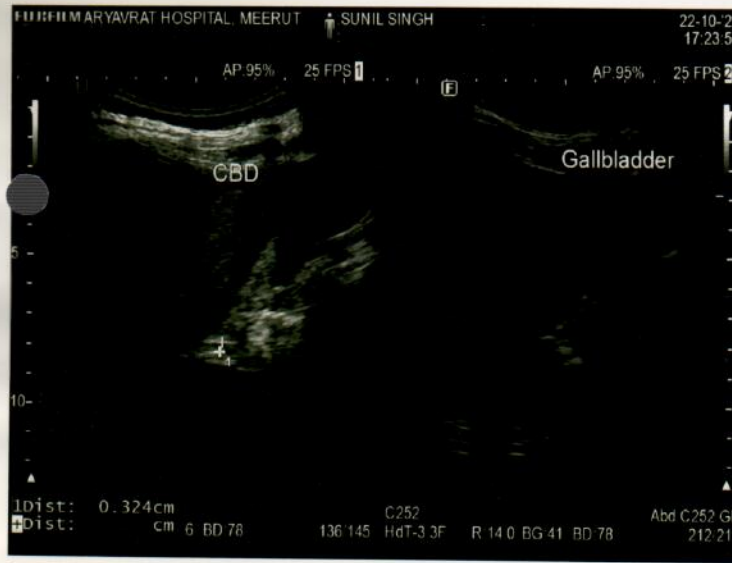
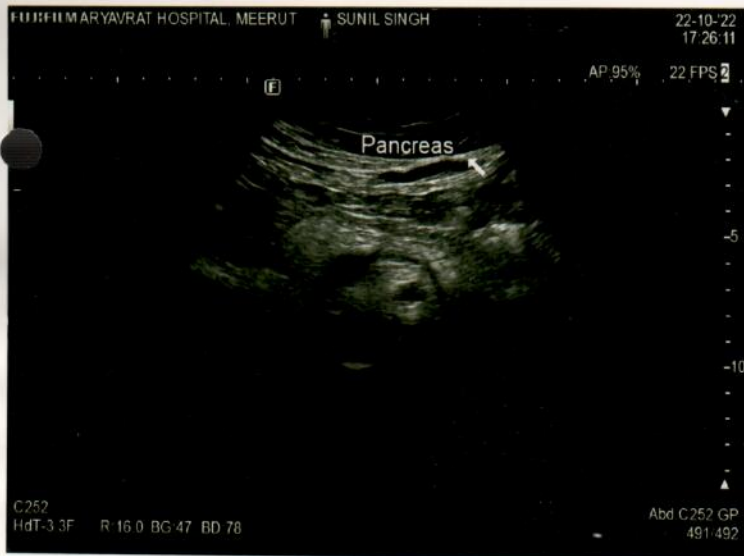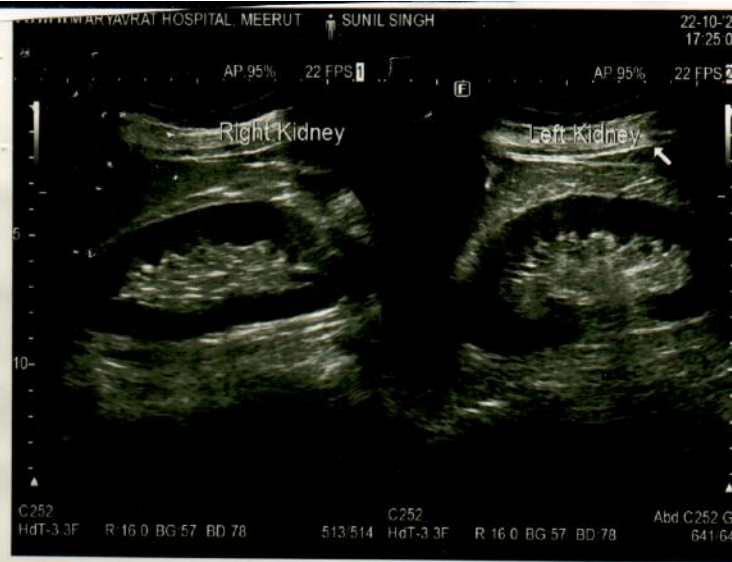
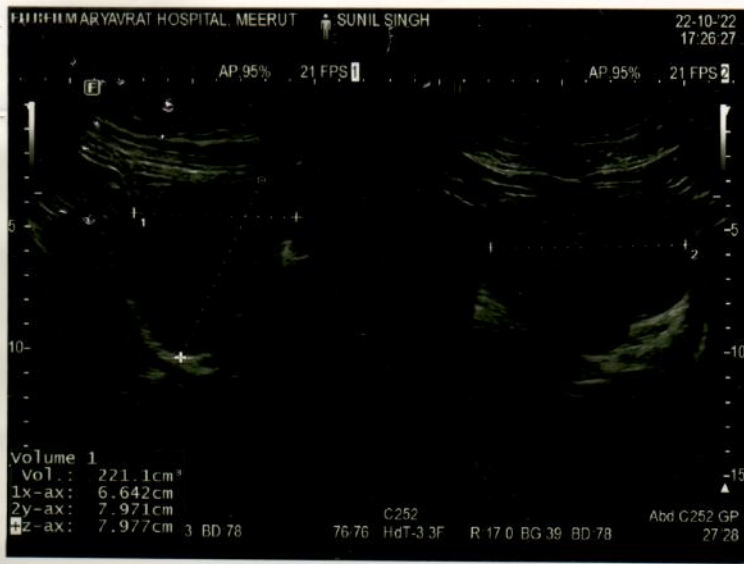
No anechoic FLUID seen in either posterior costo-phrenic angle.
No anechoic FLUID seen in the Abdomen.

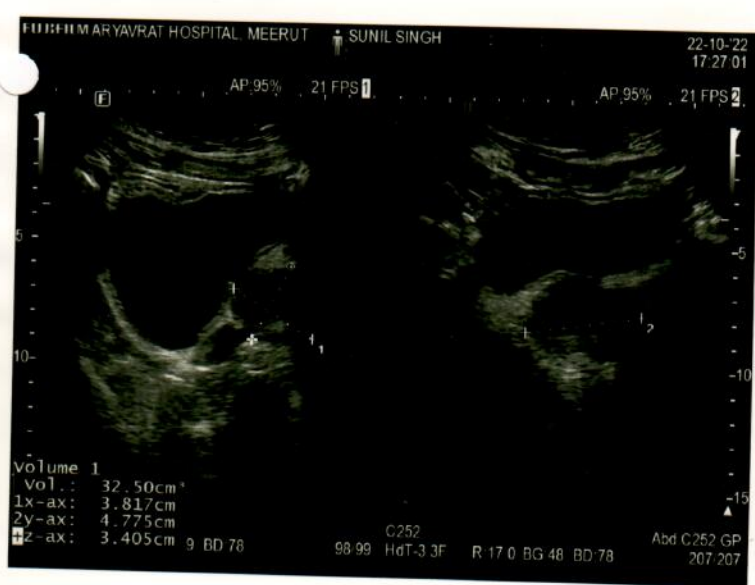
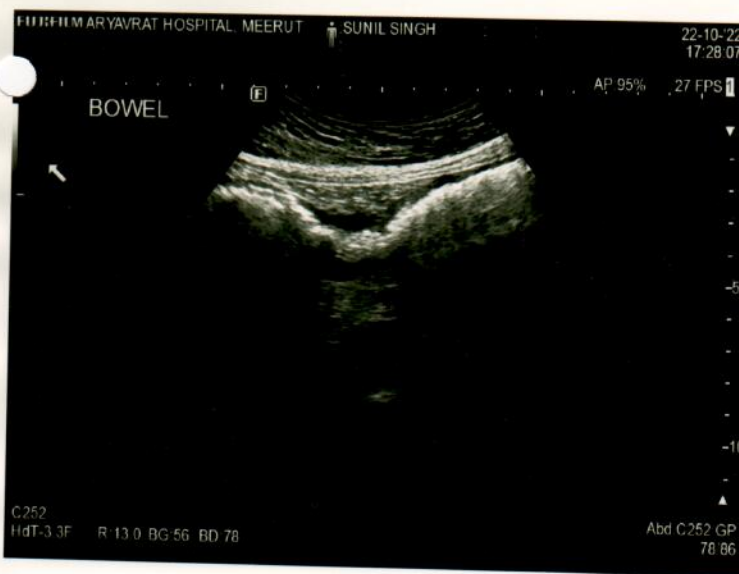
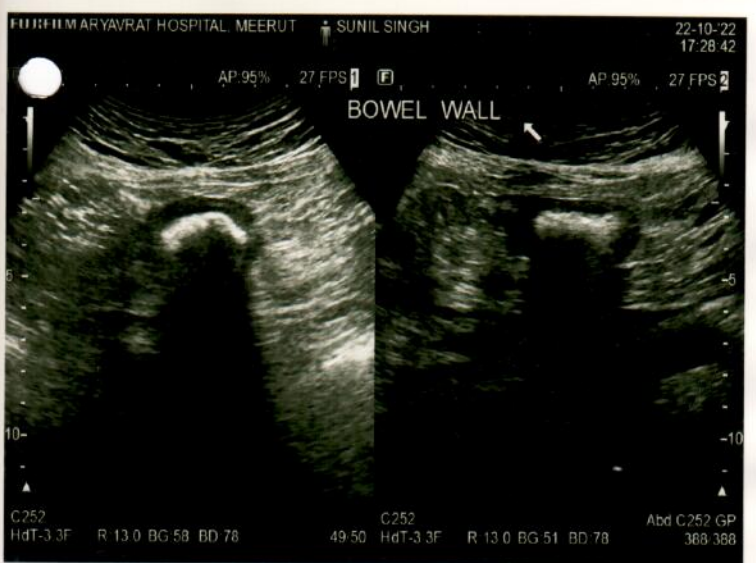
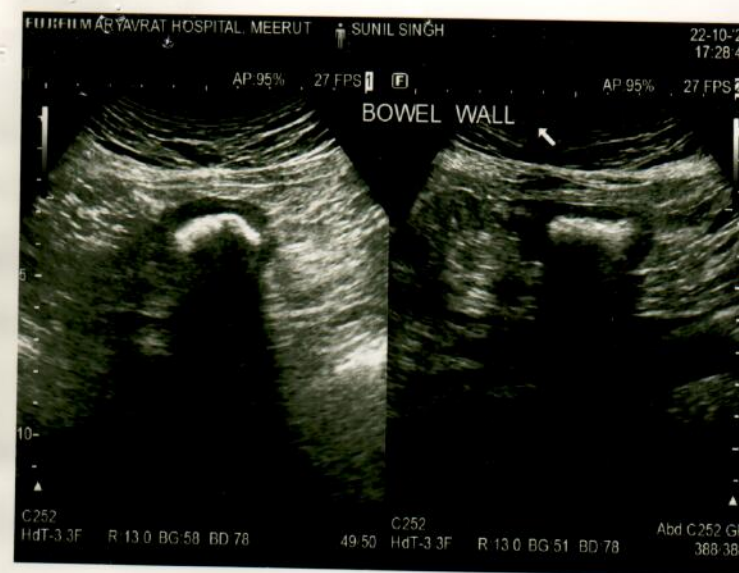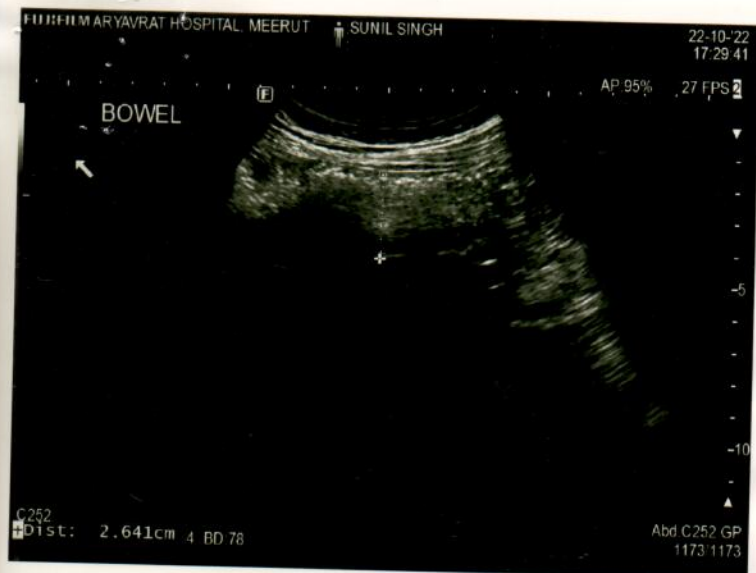There is a segment of concentric wall thickening in a Bowel Loop extending obliquely along the right upper abdomen. There is associated focal dilatation of a bowel loop proximal to it, the dilatation measures 2.6 cm in diameter.

IMPRESSION :- Mild hepatomegaly with fatty hepatic infiltration.
- A segment of bowel showing concentric wall thickening in right upper abdomen with mild focal obstruction (? small bowel or ?? mid transverse colon).

Please correlate clinically and with other investigations.

DR. AMIT PATHAK
DMRD



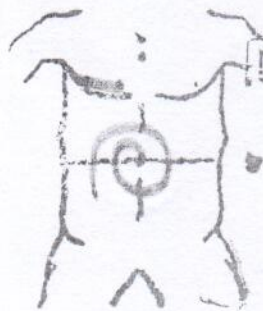



MRS K. FAAL

15 MAR 2023

6615



DOMINANT PROBLEMS:

vague pain
abdom
colic
audible gurgles
no
GI upset

DIET ↑
LIFE-STYLE →
NEXT VISIT ↓

antegrade
intensions

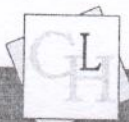NOV 22
bleed/leakage
ulcers

300
NO coarctation

Dr. VINOD K. MISHRA
MD, DM (Gastro)
Consultant Gastroenterologist
Crystal Medical Centre Pvt. Ltd.
Registration No. 78741

Adv
TAB Mexicem 40
TAB Spasmodic
0200
TAB Artemizol
0200
cap USG-30

TAB FOLIC



Dr. Sangeeta Shukla

M.B.B.S., M.S.
Consultant Ophthalmologist
Micro and Refractive Surgery Specialist
Reg. No. : 33281 MC-U.P.



Dr. Mohit Khattri

M.B.B.S., M.S.
Vitreous Retinal Surgeon
Regn. No. : 50398 MC-UP

9335924988

OPHTHALMOLOGY UNIT

Patient Name: Mr. Sunil Singh

Age/Gender :

Date: / Time : 11/12/23

UHID:

Ref. by:

Known Allergy :

VA <
NV
IOP

History & Chief Complaints :

Diagnosis :

Investigations :

Allergic conjunctivitis
E Punctal Stenosis.

Treatment :

Adv:

Punctal Dilatation done.

E.d LOTE PRED - T
o o o

E.d ECOMDIST ULTRA | BEC
o o o
or Systane Ultra.

x 15 days

Indim.

Cap. EVION - - x 3 months

Facilities Available :

- Phacomulsification, with (Monofocal, Multifocal, Toric IOLS
- Fundus Imaging, FFA, OCT
- Retinal Laser
- Ascan, Bscan
- NCT, AT
- ARK
- Refraction, Contact Lens
- Field Charting
- Glaucoma Workup & M/M
- Lid Surgeries
- Ocular Trauma

Next Follow up :

REGENCY HOSPITAL LTD.

A-2, Sarvodaya Nagar, Kanpur 208005, India T 0512 3501111

CIN No. : U85110UP1987PLC008792

OPD TIMING

Dr. Sangeeta : 10:00 A.M. - 01:00 P.M.

(Mon, Tues, Wed, Fri)

Dr. Mohit Khattri: 1.00 - 3.00 P.M. (Mon. - Sat.)

एमजेन्सी में रीजेन्सी अस्पताल सम्पर्क करें 0512-3501111 (Ext. - 1281) (अपना पुराना पर्चा साथ लाएं)

Dr. Rajan Bhargava

M.S. (ENT) AIIMS
D.L.O. (London), FACS
Reg. No. : 7557 MCI



Patient Name: Mr. Sunil Singh

Age/Gender :

Date: / Time : 11/12/23

UHID:

Ref. by:

Known Allergy :

Chief Complaints

Ac Epiphora

Diagnosis :

P/H : T2AM

Investigations :

Nutritional Advice :

Treatment :
(Preventive aspects with food and drug interaction)

Adv: opinion of Dr. Sanjeeta Shukla for probing and syringing.

O/E
Ear

TW

A/R



Oral Cavity/Throat



I/L

LN

Next follow up :

REGENCY HOSPITAL LTD.

A-2, Sarvodaya Nagar, Kanpur 208005, India T 0512 3501111
CIN No. : U85110UP1987PLC008792

OPD TIMING

11:00 AM - 2:00 PM (Mon to Sat)

REGENCY CITY CLINIC

14/122, 'Ratan Unique', Opp. PPN Market, The Mall, Kanpur-208 001, India | T 0512-3501818

10:00 AM - 12:00 PM (Wed)

इमर्जेन्सी में रीजेन्सी अस्पताल सम्पर्क करें 0512-3501111 (Ext. - 1281) (अपना पुराना पर्चा साथ लाएं)



NUTEMA HOSPITAL

Bringing New Hope To Life!

आरोग्यम् सुख सम्पदा

Department of Ophthalmology

Dr. Priyank Garg

M.B.B.S., MS (Ophthalmology) Gold Medalist
FNB, FICO (London), FAICO, FVRS

Eye Vitreo - Retinal Surgeon & ROP Specialist

Reg. No. UPMCI-52806 MBBS | MS-338

Patient Name: Mr. Sunil Singh Age: 58/M Sex: M

UHID No.

S/D/W/O: Dr. Vinod Sir Contact No.

OPD No. 1418

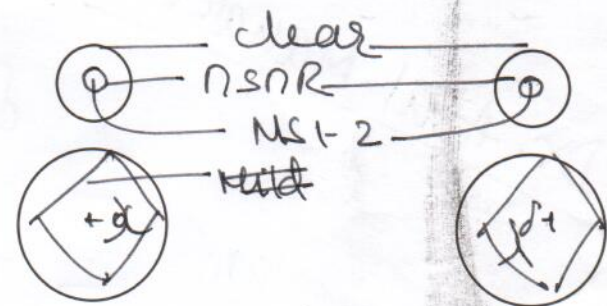
Initial Assessment

Date/Time: 24/10/23

VN<	6/9 6/6 6/6	loP<	19.0 19.0 mm	Pupillary Reaction<	MR
-----	-------------------	------	-----------------	---------------------	----

Investigation:

	Right Eye	Left Eye
Distance	+1 +2.50 x 180 6/6	+1 +2.50 x 180 6/6
Near	Add +2.0 Dsch MR	



clo H/O watery L&R

Bas. Mild MR

H/O DM + 15 yrs
+ clo H/O discharge

Rx - Steroid ultra eye drops

Biomech done
Advise Toric lens

- change glass.

Syngis
forcefully open.
Repeat syngis after 1 week

- lens after 3 weeks

नाम लिखवाने के लिए (For appointment)

98370 56192

मरीज को देखने का समय (OPD Timings)

11 am to 3 pm



H-2022-1072

Next Followup:

www.nutemahospital.com

Please call for any enquiry: 96756 00666

For Ambulance: 70881 60666 / 70882 60666

Opp. L.L.R.M. Medical College, Garh Road, Meerut.

P: 0121-2600666, 94126 00666 | m: info@nutemahospital.com

Saturday & Sunday Off

27/10/23

Surgery BS

Milate BS

Syngit *Forcefully open patient*

Rp

- DCR Surgery

RS

- Carbazol Plus eye drops

○○○○○

- Doflus-kt eye drops

○○

- Trechated / Maxaloid ultra eye

drops

○○○○○



GSTIN. 09AAFCN4496B1ZC

Nutema Pharmacy Pvt . Ltd.**CASH**

ऑनलाइन दवाई मंगवाने के लिए इस न० पर पचा Whatsapp करे
 7055444445

Invoice No. : 79813/23-2 Dated : 16-Nov-2023

Patient Name : SUNIL KUMAR

कम से कम 500 रुपये और हॉस्पिटल के 5 km के दायरे के अन्दर.

IPD/OPD NO

Dr. Priyank Garg

SNo	Particulars	HSN	Batch no	Expiry	QTY	UOM	RATE	Discount	%GST	Amount(Rs.)
1	Carbozol plus e. d.	3004	BE2306-34	May-2025	1	PCS	120.00	5.00	12	114.01
2	Oloplus kt e/d	3004	2358	Feb-2025	1	PCS	190.00	5.00	12	180.50
3	Trehatod e/d	3004	23DF48	May 2025	1	PCS	249.00	5.00	12	236.55
SUB TOTAL										531.06
4	ROUND OFF				0		-0.05			

SUB TOTAL**531.06****SUB TOTAL**

Dr. PRIYANK GARG
 MS (Gold Medalist) Reg. No. MCI 3378
 FNB, FICO (UK), FAICO, FVRS, PDCR
 VITREO-RETINAL SURGEON

NUTEMA PHARMACY
CASH PAID
 Rs.....

Total

531.00

Items	Sub Total	Concession / छूट
4	559.01	27.95

(+/-) NET AMOUNT PAYABLE

531.00

RUPEES FIVE HUNDRED THIRTY ONE ONLY

Sale @12 =474.16 , SGST=28.45 , CGST=28.45

Print Time : 3:10:27PM

Authorised Signature

बिना बिल के दवाई वापिस नहीं होगी

Signature

MOHIT ROY



Dr. B. K. Jain

Director & Trustee

E- Mail: drbkjain@sadgurustrust.org

Dr. Alok Sen

Medical Superintendent

E- Mail: draloksen@gmail.com

Dr. Elesh Jain

Administrator

E- Mail: drelesh@sadgurustrust.org

General Ophthalmology

Dr. Anjaneya P. Agashe

Children's Eye Care Centre

Dr. Pradhya Sen (HOD)

Dr. Elesh Jain

Dr. Amit Mohan

Dr. Chintan Shah

Dr. Easha Ramawat

Cornea & Refractive Surgery:

Dr. Gautam Singh Parmar (HOD)

Dr. Ashok Kumar

Dr. Sharmila Jamwar

Glaucoma:

Dr. Rakesh Shakya (HOD)

Dr. Navjot Singh Ahluwalia

Oculoplasty:

Dr. Narendra Patidar (HOD)

Retina:

Dr. Alok Sen (HOD)

Dr. Shubhi Tripathi

Dr. Sachin B. Shetty

Dr. Pradeep Tekwani

Dr. Tina Agrawal

Dr. Vrusali D. Athavale

Dr. Gaurav Mohan Kohli

Dr. Pratik Shenoy

Cataract IOL Clinic:

Dr. Rajesh Joshi (HOD)

Dr. Asheesh Bajaj

Dr. Devendra Ku. Sharma

Dr. Aniruddha Nimbhorkar

Centre for Community

Ophthalmology:

Dr. Elesh Jain

Mr. Subeesh Kuyyadiyil

Advisory Board:

Dr. Keiki Mehta, Mumbai

Prof. A.K. Grover, New Delhi

Dr. Ranjit Maniar, Mumbai

Dr. Rajiv Raman, Chennai

Dr. Ramesh R. Shah, USA

Dr. Jitendra J. Toliya, UK

Case Summary

Hospital Registration No: 82338220

Patient Name: Sumil K. Singh

Age/Sex: 56/M
01/12/2013

Date of Examination: 01/12/2013

Chief Complaints: 40-yr old (mc)

Ocular Examination:

	Right Eye	Left Eye
BCVA:	<u>6/6</u>	<u>6/6</u>
Anterior Segment:	<u>Normal</u>	<u>Normal</u>
Fundus Examination:	<u>N.N.L</u>	<u>N.N.L</u>

Investigation : Slit Lamp Microscopy, Syringing (Be-Pakent)

Clinical Diagnosis: Ch. Fuchs's Corneal Dystrophy

Treatment Advised: Conservative Management

1/d. VOREX - QID/oc

Medical Officer



CASH RECEIPT

A.V. MEDICAL CENTER

R-92, Pallavpuram, Phase-2, Meerut (U.P.) 250 110

Ph. : 9719190601, 9719190602

No.

552

Dated

27/10/23

Received with thanks from

Sunil Kumar Singh

C/o

Shri Hukum Singh

Mob.

7055754283

Address

A-91 Platter puram phase -2

the sum of Rupees

US\$ for KUV

for

One thousands rupees only



1000/-

Cheque / D.D. subject to realisation.

Dr. Shaleen Sharma

M.B.B.S, M.S, Mch.

Urologist and Transplant Surgeon

A.V. MEDICAL CENTRE
Nutema Hospital Garh Road, Meerut, U.P. Phase-II,

Reg. No.-UPMCI. 43051000

Auth. Signatory



NUTEMA HOSPITAL

Bringing New Hope To Life!

आरोग्यम् सुख सम्पदा

Department of Urology

Dr. Shaleen Sharma

M.B.B.S., M.S., MCh (Urology)

ADJ.

Urologist, Andrologist & Kidney Transplant Surgeon

Reg. No. MCI-4305

27/10/23.

Shri Sunil Singh Ji 54.

WIS. frequency. flow good
morning.
nocturia. - 2.

urine.
- 2 months
- significant
rust.

AM - 15 yrs.

PIR. us II Prast.

Sm. cul

T Maxroid 5 - HS. 10 days

37gm 15/191.

USG. KUB region & PIR.

KIM.

used

SPSA

us flow metkey

350/13/7.
12-5
mon
fri

T Maxroid. plus
HS.

15 days



DR. SHALEEN SHARMA

नाम लिखवाने के लिए (For appointment)

73512 22234

मरीज को देखने का समय (OPD Timings)

12 noon to 4 pm

Emergency Number : 84453 98112

98375 14414 / 94295 07104



H-2022-1072

Next Followup :

www.nutemahospital.

Please call for any enquiry : 96756 00

For Ambulance : 70881 60666 / 70882 60

Opp. L.L.R.M. Medical College, Garh Road, Me

P: 0121-2600666, 94126 00666 | m: info@nutemahospita

Saturday & Sunday



**NUTEMA
HOSPITAL**

Bringing New Hope To Life!
आरोग्यम् सुख सम्पदा

Department of Urology

Dr. Shaleen Sharma

M.B.B.S., M.S., MCh (Urology)

Urologist, Andrologist & Kidney Transplant Surgeon

Reg. No. MCI-4303

15.11.23

Shri Sunil Singh ji

M.S.

had problems & stadosis
flow better & use msc

SPCA 172

By

cup wremax .unf H.S

→ 2 mania

1
S...

नाम लिखवाने के लिए (For appointment)

☎ 73512 22234

मरीज को देखने का समय (OPD Timings)

12 noon to 4 pm

**Emergency Number : 84453 98112
98375 14414 / 94295 07104**



H-2022-1072

Next Followup :

➔ www.nutemahospital.com

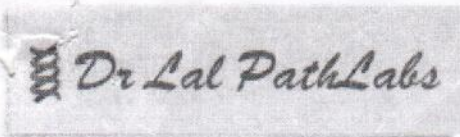Please call for any enquiry : **96756 00666**

For Ambulance : **70881 60666 / 70882 60666**

Opp. L.L.R.M. Medical College, Garh Road, Meerut

P: 0121-2600666, 94126 00666 | m: info@nutemahospital.com

Saturday & Sunday Open



011-49885050 (National Customer Care)
Customer.Care@lalpathlabs.com

FPSC MODIPURAM

SHOP NO.- 9, VADHMAN PLAZA, ROORKEE ROAD, C-POCKET, PALLAVPURAM, MEERUT
,MEERUT,MEERUT250502 M-9411261452
9897860610

AUTHORISED COLLECTION CENTER

INVOICE CUM CASH RECEIPT

(PLEASE BRING THIS RECEIPT FOR REPORT COLLECTION)



176120529

Patient Name Mr. SUNIL KUMAR SINGH
Age & Sex 56 year(s) / Male
Ref. Doctor DR SHALEEN SHARMA MS
Contact No 7055754283
Date & Time 28-10-2023 09:01:49

Invoice cum Receipt no OIDL231028033215889170
Lab No **176120529**
LPL Client Code CC6643
Reporting Location FPSC MODIPURAM

S. No.	Test Code	Test Name	Estimate of report by #	Amount (Rs.)
1	U105	URINE EXAMINATION, ROUTINE; URINE R/E, AUTOMATED	28-10-2023 17:00	150
2	F014	PSA (PROSTATE - SPECIFIC ANTIGEN), TOTAL	28-10-2023 15:00	750
				Order Value: 900
				Home Collection Charges: 0
				Total Order Value : 900
				Net Payable Amount : 900
				Paid Amount: 900
				Balance Amount: 0

Note:

1. Please check your Name, Tests and contact details. These will be used to send Report related notifications.
2. To download the Reports, please visit www.lalpathlabs.com or Download the App and click on 'VIEW ALL YOUR TEST REPORTS'.
3. Enter Lab No. (as given on receipt) as your Lab/Visit ID' and your surname (as given on receipt) as password. e.g. if your name is RAM KUMAR, then KUMAR is your Password.
4. Partially paid or unpaid reports cannot be accessed on the Website or App.
5. You can now get the Cumulative Report (One Report for all your Values) by downloading the App and creating an account with the same mobile number given at the time of registration. All your previous reports will also be available on the same dashboard. Download the App now from Play Store/ App Store
6. Services provided hereunder are healthcare services which are exempt from GST under serial no. 74 of notification 12/2017 - Central Tax(Rate).
7. # Reports may be delayed due to unforeseen circumstances; inconvenience regretted.
8. * Report will be available as per the Schedule of test.
9. By accepting this invoice / transacting with the Company, I agree/confirm having understood the Terms and Conditions mentioned in Dr. Lal PathLabs Privacy Policy and Terms of Use (also available on the website).

For FPSC MODIPURAM
Authorised Signatory

Download Our App:

Download our apps from these links to access our services & reports on digital platform seamlessly





Name : Mr. SUNIL KUMARSINGH
 Lab No. : 176120529
 Ref By : DR SHALEEN SHARMA MS
 Collected : 28/10/2023 9:01:00AM
 A/c Status : P
 Collected at : FPSC MODIPURAM
 Shop No.9 Vardhman Palaza,Roorkee Road C
 Pocket Pallavpuram Meerut - 9411261452

Age : 56 Years
 Gender : Male
 Reported : 28/10/2023 2:41:10PM
 Report Status : Final

Processed at : LPL-MEERUT LAB
 1st Floor, Hall No. 101, 1st Floor of Shree Ram
 Commercial Complex, Shradhdhapuri, Phase 2,
 NH-58, Meerut, UP - 250001

Test Report

Test Name	Results	Units	Bio. Ref. Interval
-----------	---------	-------	--------------------

URINE EXAMINATION, ROUTINE; URINE R/E, AUTOMATED

Physical

Colour	Pale Yellow		Pale Yellow
Specific gravity	1.010		1.000 -1.030
Ph	5.5		5.0 - 8.0

Chemical

Proteins	Negative		Negative
Glucose	Present 4+(1.0 g/dL)		Negative

Result Rechecked,
 Please Correlate Clinically.

Ketones	Negative		Negative
Bilirubin	Negative		Negative
Urobilinogen	Negative		Negative
Blood	Negative		Negative
Leukocyte esterase	Negative		Negative
Nitrite	Negative		Negative
Ascorbic Acid	Negative		Negative

Microscopy

RBC	0.00	/hpf	0.0 - 2.0
Pus cells	0.20	/hpf	0.0 - 5.0
Epithelial cells	0.80	/hpf	0.0 - 5.0
Calcium oxalate monohydrate crystals	0.00	/hpf	0.0 - 0.99
Calcium oxalate dihydrate crystals	0.00	/hpf	0.0 - 0.99
Triple Phosphate crystals	0.00	/hpf	0.0 - 0.99
Uric acid crystals	0.00	/hpf	0.0 - 0.99
Calcium Phosphate	0.00	/hpf	0.0 - 0.99
Cystine crystals	0.00	/hpf	0.0 - 0.99
Leucine crystals	0.00	/hpf	0.0 - 0.99
Tyrosine crystals	0.00	/hpf	0.0 - 0.99



Name : Mr. SUNIL KUMARSINGH
 Lab No. : 176120529
 Ref By : DR SHALEEN SHARMA MS
 Collected : 28/10/2023 9:01:00AM
 A/c Status : P
 Collected at : FPSC MODIPURAM
 Shop No.9 Vardhman Palaza,Roorkee Road C
 Pocket Pallavpuram Meert - 9411261452

Age : 56 Years
 Gender : Male
 Reported : 28/10/2023 2:41:10PM
 Report Status : Final



Processed at : LPL-MEERUT LAB
 1st Floor, Hall No. 101, 1st Floor of Shree Ram
 Commercial Complex, Shraddhapuri, Phase 2,
 NH-58, Meerut, UP - 250001

Test Report

Test Name	Results	Units	Bio. Ref. Interval
Amorphous urates crystals	0.00	/hpf	0.0 - 0.99
Amorphous phosphate crystals	0.00	/hpf	0.0 - 0.99
Hyaline casts	0.00	/hpf	0.0 - 5.0
Hyaline-Granular casts	0.00	/hpf	0.0 - 0.99
Granular casts	0.00	/hpf	0.0 - 0.99
RBC casts	0.00	/hpf	0.0 - 0.99
WBC casts	0.00	/hpf	0.0 - 0.99
Fatty casts	0.00	/hpf	0.0 - 0.99
Waxy casts	0.00	/hpf	0.0 - 0.99
Microorganism Casts	0.00	/hpf	0.0 - 0.99
Yeast cells	0.00	/hpf	0.0 - 1.0
Bacteria Rod	0.00	/hpf	0.0 - 80.0
Bacteria cocci	8.20	/hpf	0.0 - 80.0
Mucus	6.10	/hpf	0.0 - 80.0
Others	0.00	/hpf	



Name : Mr. SUNIL KUMAR SINGH
 Lab No. : 176120529
 Ref By : DR SHALEEN SHARMA MS
 Collected : 28/10/2023 9:01:00AM
 A/c Status : P
 Collected at : FPSC MODIPURAM
 Shop No.9 Vardhman Palaza,Roorkee Road C
 Pocket Pallavpuram Meerut - 9411261452

Age : 56 Years
 Gender : Male
 Reported : 28/10/2023 2:41:10PM
 Report Status : Final
 Processed at : LPL-MEERUT LAB
 1st Floor, Hall No. 101, 1st Floor of Shree
 Ram Commercial Complex, Shraddhapuri,
 Phase 2, NH-58, Meerut, UP - 250001



Test Report

Test Name	Results	Units	Bio. Ref. Interval
PSA (PROSTATE SPECIFIC ANTIGEN), TOTAL, SERUM (CLIA)			
PSA, TOTAL	0.720	ng/mL	<4.00

Note

1. This is a recommended test for detection of prostate cancer along with Digital Rectal Examination (DRE) in males above 50 years of age.
2. False negative / positive results are observed in patients receiving mouse monoclonal antibodies for diagnosis or therapy
3. PSA levels may appear consistently elevated / depressed due to the interference by heterophilic antibodies & nonspecific protein binding
4. Immediate PSA testing following digital rectal examination, ejaculation, prostatic massage; indwelling catheterization, ultrasonography and needle biopsy of prostate is not recommended as they falsely elevate levels
5. PSA values regardless of levels should not be interpreted as absolute evidence of the presence or absence of disease. All values should be correlated with clinical findings and results of other investigations
6. Sites of Non-prostatic PSA production are breast epithelium, salivary glands, peri-urethral & anal glands, cells of male urethra & breast milk
7. Physiological decrease in PSA level by 18% has been observed in hospitalized / sedentary patients either due to supine position or suspended sexual activity
8. The concentration of PSA in a given specimen, determined with assays from different manufacturers, may not be comparable due to differences in assay methods, calibration, and reagent specificity.

Recommended Testing Intervals

- Pre-operatively (Baseline)
- 2-4 days post-operatively
- Prior to discharge from hospital
- Monthly followup if levels are high or show a rising trend

Post Surgery	Frequency of testing
1st year	Every 3 months
2nd year	Every 4 months
3rd year onwards	Every 6 months



Name : Mr. SUNIL KUMAR SINGH
Lab No. : 176120529
Ref By : DR SHALEEN SHARMA MS
Collected : 28/10/2023 9:01:00AM
A/c Status : P
Collected at : FPSC MODIPURAM
Shop No.9 Vardhman Palaza,Roorkee Road C
Pocket Pallavpuram Meert - 9411261452

Age : 56 Years
Gender : Male
Reported : 28/10/2023 2:41:10PM
Report Status : Final
Processed at : LPL-MEERUT LAB
1st Floor, Hall No. 101, 1st Floor of Shree
Ram Commercial Complex, Shradhdhapuri,
Phase 2, NH-58, Meerut, UP - 250001



Test Report

Test Name	Results	Units	Bio. Ref. Interval
-----------	---------	-------	--------------------

Clinical Use

- An aid in the early detection of Prostate cancer when used in conjunction with Digital rectal examination in males more than 50 years of age and in those with two or more affected first degree relatives.
- Followup and management of Prostate cancer patients
- Detect metastatic or persistent disease in patients following surgical or medical treatment of Prostate cancer

Increased Levels

- Prostate cancer
- Benign Prostatic Hyperplasia
- Prostatitis
- Genitourinary infections

Dr Ankit Jain
MD, Pathology
Chief of Laboratory
Dr Lal PathLabs Ltd

Dr Abhinav Sharma
MBBS,MD Pathology
Consultant Pathologist
Dr Lal PathLabs Ltd

Dr.Sandeep Yadav
MBBS,MD (Biochemistry)
Consultant Biochemist
Dr Lal PathLabs Ltd

Dr Sonal Jindal
MD, Microbiology
Consultant Microbiologist
Dr Lal PathLabs Ltd

-----End of report-----



Name : Mr. SUNIL KUMAR SINGH
Lab No. : 176120529
Ref By : DR SHALEEN SHARMA MS
Collected : 28/10/2023 9:01:00AM
A/c Status : P
Collected at : FPSC MODIPURAM
Shop No.9 Vardhman Palaza,Roorkee Road C
Pocket Pallavpuram Meert - 9411261452

Age : 56 Years
Gender : Male
Reported : 28/10/2023 2:41:10PM
Report Status : Final
Processed at : LPL-MEERUT LAB
1st Floor, Hall No. 101, 1st Floor of Shree
Ram Commercial Complex, Shraddhapuri,
Phase 2, NH-58, Meerut, UP - 250001



Test Report

Test Name	Results	Units	Bio. Ref. Interval
-----------	---------	-------	--------------------

IMPORTANT INSTRUCTIONS

•Test results released pertain to the specimen submitted. •All test results are dependent on the quality of the sample received by the Laboratory.
•Laboratory investigations are only a tool to facilitate in arriving at a diagnosis and should be clinically correlated by the Referring Physician. •Report delivery may be delayed due to unforeseen circumstances. Inconvenience is regretted. •Certain tests may require further testing at additional cost for derivation of exact value. Kindly submit request within 72 hours post reporting. •Test results may show interlaboratory variations. •The Courts/Forum at Delhi shall have exclusive jurisdiction in all disputes/claims concerning the test(s) & or results of test(s). •Test results are not valid for medico legal purposes. •This is computer generated medical diagnostic report that has been validated by Authorized Medical Practitioner/Doctor. •The report does not need physical signature.

(#) Sample drawn from outside source.

If Test results are alarming or unexpected, client is advised to contact the Customer Care immediately for possible remedial action.

Tel: +91-11-49885050, Fax: - +91-11-2788-2134, E-mail: lalpathlabs@lalpathlabs.com



GSTIN. 09AAFNCN4496B1ZC

Nutema Pharmacy Pvt . Ltd.**CASH**

ऑनलाइन दवाई मंगवाने के लिए इस न० पर पचा Whatsapp करे

7055444445

कम से कम 500 रुपये और हॉस्पिटल के 5 km के दायरे के अन्दर.

Invoice No. : 79814/23-2 Dated : 16-Nov-2023

Patient Name : SUNIL SINGH

IPD/OPD NO

Dr. Shaleen Sharma/ Dr. Sar

SNo	Particulars	HSN	Batch no	Expiry	QTY	UOM	RATE	Discount	%GST	Amount(Rs.)
1	Urimax-0.4 cap 15	3004	BA30775	Jun-2025	55	PCS	15.27	5.00	12	797.86
2	ROUND OFF				0		0.14			797.86
SUB TOTAL										797.86
SUB TOTAL										

NUTEMA PHARMACY
CASH PAID
Rs. 798.00

Items	Sub Total	Concession / छूट
2	839.85	41.99

(+/-) NET AMOUNT PAYABLE
798.00

798.00**RUPEES SEVEN HUNDRED NINETY EIGHT ONLY**

Sale @12 =712.38 , SGST=42.74 , CGST=42.74

Print Time : 3:11:21PM

Authorised Signature

बिना बिल के दवाईया वापिस नहीं होंगी

Signature

MOHIT ROY

Patient Name : MR.Sunil kumar

Age/Sex : 56/M

Reg. ID. :

Date : 27/10/2023

Referred By : ~~Self~~ Nufema Hospital

ULTRASOUND OF KUB region

RIGHT KIDNEY - is normal in size (10x4.2 cm), shape and position. It shows homogenous echotexture. Corticomedullary differentiation is maintained. It shows normal cortical/parenchymal thickness. There is no evidence of any calculus or no backpressure changes seen. No evidence of any mass seen.

LEFT KIDNEY - is normal in size (11.5x4.7 cm), shape and position. It shows homogenous echotexture. Corticomedullary differentiation is maintained. It shows normal cortical/parenchymal thickness. There are few renal concretions noted in midpole and lower pole region. Largest measuring 5.3mm in mid pole.

URINARY BLADDER-is physiologically distended. Lumen is echofree. No mural or intraluminal pathology. No intraluminal calculus is seen.

Pre-void urine- 191.8 cc, Post Void urine- 15 cc

PROSTATE: is enlarged in size, however normal in shape and echotexture (3x3.5x2.5cm) (37 cc).

No free fluid seen in peritoneal cavity.

IMPRESSION: Prostatomegaly with minimal residual post void urine.

Adv- Serum PSA

Note: (1) This report is a professional opinion based on imaging findings. NOT valid for medico-legal purpose.
(2) In case of any discrepancy due to machine error or typing error please get it rectified immediately

Please correlate clinically.

Sweta
DR. SWETA KUMARI
M.B.B.S, MD
Reg no- 105185

Shaleen
Dr. Shaleen Sharma
M.B.B.S, M.S, Mch.
Urologist and Transplant Surgeon
Nufema Hospital Garh Road, Meerut U.P.
No. UPMCI. 43051 MRT.

