



All India Institute of Medical Sciences
Rishikesh
Department of Pathology and Lab Medicine

HISTOPATHOLOGY REPORT FORM

Date of Receiving: 07.12.19

Time of Receiving: 2:20 pm

CR. Number: 20190216157

Histopathology Number: S-7502/19

Ward & Bed No. (For IP): IPD

Routine/ Frozen Section

Patient's name: Ravinder Pandey

Age: 46 years Gender: Male

Referring Department/Unit: ENT

Referring Consultant: Dr. S. Varshney

Specimen sent: Biopsy.

Clinical Diagnosis: Growth hypopharynx.

Gross:

Received two soft tissue pieces altogether measuring 0.5 x 0.2 x 0.1 cm. All embedded as A1.

Microscopy:

Sections examined show a tumor arranged in nests and sheets. They have a round to polygonal shape, hyperchromatic nucleus with moderate amount of eosinophilic cytoplasm. Atypical mitotic figures are seen. Stroma shows a desmoplastic and inflammatory response.

Diagnosis:

Biopsy growth: Moderately differentiated squamous cell carcinoma.


Dr. Michael Anthony

Senior Resident


Dr. Nilotpal Chowdhury

Additional Professor

Date of Reporting: 10.12.2019





ALL INDIA INSTITUTE OF MEDICAL SCIENCES, RISHIKESH
DEPARTMENT OF RADIO-DIAGNOSIS & IMAGING

Name of Pt./ Age /Sex:	RAVINDER/46Y/M	Cr No.:	20190216157
Ref. Deptt.:	ENT	Date:	1/11/2019

CECT NECK (64 Slice CT)

Clinical Details: Difficulty in swallowing (solids>liquids). ? Growth ? irregularity over right pyriform fossa.

Study Procedure: A plain and post contrast CT study of the Neck is performed using contiguous sections from hard palate upto the root of neck.

Imaging Findings:


- There is focal constriction seen in the cervical oesophagus at the level of C7 vertebra posteriorly- likely due to crico-pharyngeal muscle spasm.
- Tongue is normal in morphology and contrast enhancement. The intrinsic muscles of tongue appear normal.
- Soft palate appears normal.
- Floor of mouth is normal in morphology and contrast enhancement.
- Aryepiglottic folds, vocal cords, anterior commissure, subglottic air space and region of hypopharynx as well as the upper oesophagus do not show any apparent abnormality.
- The nasopharynx is normal.
- The parapharyngeal fat appears preserved.
- The prevertebral and retro-pharyngeal spaces are normal.
- The buccal pad of fat appears normal. The buccinator muscle appears normal.
- The muscles of mastication including the masseter, medial pterygoid and the temporalis appear normal.
- The nasal septum is fairly in the midline.
- Paranasal sinuses appear normal.
- The major vascular structures are normal.
- There are no significant enlarged lymphnodes.
- Both lobes of thyroid and isthmus are normal in morphology and enhancement.
- Both the parotid glands are symmetrical in size and normal in attenuation.
- Both the submandibular glands are symmetrical in size and normal in attenuation.
- Visualized orbits, middle and posterior cranial fossae are normal.
- A well sclerotic lesion measuring ~6x6mm is seen in D2 vertebra and tiny sclerotic lesion seen in C7 vertebra.

IMPRESSION:

- Possibility of crico-pharyngeal muscle spasm. Adv- Barium swallow.


Dr Anurag Modi
Junior Resident

Dr Mriganki
Senior Resident


Dr Poonam Sherwani
Associate Professor





All India Institute of Medical Sciences Rishikesh

UHID:20190216157

CONSULTING ROOM NO : 2063

CLINIC: Radiotherapy TOKEN NO: 36

DAYS: MON,TUE,WED,THU,FRI

VISIT NO : 8

LAST VISIT DATE : 17/01/2020 ✓

OUT PATIENT RECORD

EHR ID :19000258073527688

RADIATION ONCOLOGY OPD (RE-VISIT)

युनिट-1/UNIT-1

सोमवार, बुधवार, पन्ना व तीसरा शुक्रवार

MONDAY, WEDNESDAY, 1st /3rd /5th FRIDAY

Name : MR. RAVINDER PANDEY

Department : Radiotherapy

Dept No. : 2020/105/0000275

Date of Registration : 02-03-2020 11:53:01 AM

Unit : 1

Billing Type : GENERAL

Mobile No. : *****733

Address : 1157, RAM LILA TILLA MUZAFFARNAGAR PIN:251002, UTTAR PRADESH, INDIA

Fees : ₹ 0

Sex : Male

DOB : RAMADHAR PANDEY

Age : 46Y 4M 27D

Email : agochar121@gmail.com

Occupation : UNKNOWN

Patient Type : NON MLC Prepared

By : Ms.Shardha Masih

02 MAR 2020

% Ca Hypopharynx - T4b No N0.

PET CT reveals an additional Precaecal mass.

→ Pt. does not have any symptom of the precaecal mass.

→ pts - Smooth bulge over posterior rectal wall. Rectal wall mobile over mass.

Upper extent of mass not reachable.

Plan: 1) Continue with radical plan for Ca Hypopharynx.

2) PET CT review with Dept. of Nuclear Medicine to characterize lesion.

↓
Further evaluation based on discussion.

Adm,

स्तन कैंसर जागरूकता अभियान, ब्रेस्ट क्लिनिक, भूतल, बी-ब्लॉक

- Dental evaluation for radical RT.

- RTP scan date order.

Dr. Leekshmi's, thesis.

Shy (S.K.S.)



All India Institute of Medical Sciences Rishikesh

UHID:20190216157

26th

01/01/20



ULTING ROOM NO : 2063

: Radiotherapy TOKEN NO: 2

MON, TUE, WED, THU, FRI

NO : 7

VISIT DATE : 16/01/2020

OUT PATIENT RECORD

EHR ID : 19000258073527688

(RE-VISIT)

NAME : MR. RAVINDER PANDEY

Specialty : Radiotherapy

Reg No. : 2020/105/0000275

Date of Registration : 17-01-2020 09:15:43 AM

Age :

Religion : GENERAL

Mobile No. : *****733

Address : 1157, RAM LILA TILLA MUZAFFARNAGAR PIN 251002, UTTAR PRADESH, INDIA

Fees : ₹ 0

Sex : Male

S/O RAMADHAR PANDEY

Age 46Y 3M 11D

Email agochar121@gmail.com

Occupation : UNKNOWN

Patient Type : NON MLC Prepared By : Ms.Shardha Masih

18 JAN 2020

17 JAN 2020

17/1/20

c/s/b Dr Panjari DR - 1/ED

△ Carcinoma Hypopharynx
MDSCC

CTx No Mo

max
(Tuck up not done)

c/d/w Dr Gaurav SR/ED

ADU

① PET SCAN whole Body

② To r/w T report

रतन कैंसर जागरूकता अभियान, व्हेस्ट क्लिनिक, भूतल, बी-ब्लॉक

Beam office



All India Institute of Medical Sciences Rishikesh

UHID:20190216157

CONSULTING ROOM NO : 1026
CLINIC: ENT TOKEN NO: 86
DAYS: MON,THU,FRI
VISIT NO : 5
LAST VISIT DATE : 03/12/2019 ✓



OUT PATIENT RECORD

EHR ID : 19000258073527688

Name : MR. RAVINDER PANDEY

(RE-VISIT)

Department : ENT

Dept No. : 2019/075/0022652

Date of Registration : 16-01-2020 09:34:54 AM

Unit : 1

Billing Type : GENERAL

Mobile No. : *****733

Address : 1157, RAM LILA TILLA MUZAFFARNAGAR PIN:251002, UTTAR PRADESH, INDIA

Fees : ₹ 10

Sex : Male

S/O : RAMADHAR PANDEY

Age : 46Y 3M 10D

Email : agochar121@gmail.com

Occupation : UNKNOWN

Patient Type : NON MLC Prepared

By : Mr.Pankaj Rawat

डॉ. मनु मल्लोत्रा / Dr. Manu Malhotra
अपर आसि / Additional Professor
कर्ण, नासिका एवं कंठ शल्य चिकित्सा
Department of Ear, Nose & Throat
संस्था, ऋषिकेश / AIIMS, Rishikesh

FUL of ? Malignancy Hypopharynx

D/L Biopsy done on - 07/12/19.

PT. Proxy

HPE (S-7502/19) : Mod. diff. scc

✓


✓

AL

→ Radiotherapy opinion -

Pranav
SR, ENT

① M
 simple sketch
 sketch your
 in hand with
 7 (M/PA),
 for visual eye



what
 you

→ (left - M/PA to 7) (right)
 → ~~sketch~~
 → (left, left, left, left, right, right)
 → the left hand being left

M/PA
 M/PA

②



Department of Otorhinolaryngology (ENT),
All India Institute Of Medical Sciences,
Rishikesh.

DISCHARGE SUMMARY

Unit - I

Patients Name : Ravinder Pandey Age/Gender : 46/M
Address : Muzaffarnagar UHID : 20190216157
Diagnosis : Growth hypopharynx (cT1N0Mx)
Surgery : Direct laryngoscopic Biopsy under LA

Head of dept : Dr. Saurabh Varshney DOA : 03/12/19
Asst.Prof. : Dr. Amit Kumar Tyagi DOS : 06/12/19
Asst Prof. : Dr. Amit Kumar DOD : 07/12/19

Chief Complaints :

Difficulty in swallowing (solids > liquids) x 3 years
h/o bidi smoking x 1 year (2 per day)

Examination Findings

Oral cavity : Mouth opening adequate.
Ant Rhinoscopy : Septum central and airway fair
Ear : B/L TM intact
Larynx : B/L TVC mobile. A smooth growth seen in left posterior pharyngeal wall near pyriform fossa
Neck : No palpable swelling/LN



Investigations:

Haematology : 03/12/19				LFT,RFT & Sr. Electrolytes – 11/11/19			
Test	Value	Unit	Reference range	Test	Value	Unit	Reference range
Hb	: 10.17	gm/dl	M13-17,F 12 - 15	Total Bilirubin	: 0.40	mg/dl	0.3 - 1.2
RBC	: 5.283	million/mm ³	M4.5-5.5,F3.8-5.2	Direct bilirubin	: 0.26	mg/dl	<0.20
TLC	: 4160	/mm ³	4,000-11,000	S.G.P.T	: 15	U/L	M-<50,F-<35
DLC	: 51/29/13/4/3		N40-70%,L20-40%, E1-6%,M2-8%,B<2%	S.G.O.T	: 18	U/L	M-<50,F-<35
PC	: 1.76	/mm ³	1.5-4.0	ALP	: 209	U/L	30-120 U/L
PT	:			GGT	: 29.5	U/L	M-<55,F-<38
INR	: 0.91			Blood Urea	: 12.8	mg/dl	17 - 43
ESR	:		M-0-7, F-0-14	Sr. Creatinine	: 0.76	mg/dl	M0.67-1.17, F0.51-0.95
Hct	: 32.78	%	M40-50,F36-45	Sr. Total Protein	: 7.50	g/dl	6.6 – 8.3
RBS	: 126	mg/dl	upto 140	Sr. Albumin	: 4.70	g/dl	3.5-5.2
Mg	:			Sr. Na	: 135	mmol/L	136 – 146
Viral markers – 01/11/19				Sr. K	: 5.1	mmol/L	3.5 – 5.1
Anti HIV Ab	:		: NR	Ca	: 8.3		
HbSAg	:		: NR				



अखिल भारतीय आयुर्विज्ञान संस्थान, ऋषिकेश- 249203
All India Institute of Medical Sciences, Rishikesh- 249203
निश्चेतना पूर्व मेडिकल जाँच / Preoperative Assessment Chart 2019/777/15427

Registration No. :

Date. : 8/11/15

Special Remark

Patient Details:

Name: Ravinder Pandey Age/Sex: 46 (M/F)

Weight(kg): 53.7 Height(cm): BMI:

IPD/OPD No. 20190216157 Department: ENT

Diagnosis: malignancy Proposed Surgery: Endoscopic Biopsy (Left / Right)

HOPI:

Cough/Sputum

Chest Pain/ Tightness

Dyspnoea

Cyanosis

Palpitation

Pedal Oedema

Nausea/Vomiting

Abdominal pain

↑/↓ Urine output

Fever

Backache

LOC

Convulsions

Numbness

MEIS > A

Past History:

DM

CAD

HTN

Asthma

Tuberculosis

Seizures

Jaundice

Personal History:

Alcohol Consumption -

Appetite N

Immunisation History (Paediatric)

Smoking History (+)

Bowel Habits N

Tobacco chewing (+)

Sleep N

Family History: (-)

Problems with anaesthesia

Heart/ Respiratory problem

Others

Bleeding problem

Tumour

Obstetrics / Gynaecological History: (-)

LMP:

G/P/L/A:

OCP Intake,

If any:

Anaesthesia History: (-)

Previous Surgery and Anaesthesia

Any history of difficult intubation

Adverse reaction to anaesthesia

PONV

Medication History

(+) 7. Cetirizine 10mg sos

Drug Allergy if any

(-)

22/10/19

Examination:

GC & Nutritional status:

Vitals:

PR 81

BP 114/74

SPo2 100

RR

Clubbing

Pallor (+)

Icterus

Cyanosis

Oedema

Lymphadenopathy -

Temperature Afebrile

RS:

A/E BL (+)
No added sounds

CVS:

S12 (+) No murmurs

GIT

MAD

CNS:

E/V/M 4/5/6

Spine:

Any Deformity -

Any Skin Infection (+)

Plaque in BLK leg

Airway:

Mouth opening 3f

MMPS 4II

Edentulous -

Teeth Loose/Crown/Buck/Capping

Upper @ Camine

Neck Movement free

Neck Mass -

Misc.

Investigations

HB/Hct: - 8.67

Blood Grp:

TLC: - 4761

DLC: N/L/E/M/B -

54 | 31 | 2 | 10 | 1

AEC:

Platelet Count: - 214.2

BT:

PT/INR: 13.0 | 1.00

CT:

aPTT: 29.6

Bl. Sugar-R 81.2

F

RFTL: Sr. Creatinine 0.76

PP

Bld. Urea 12.8

HbA1C

Phos - 3.2, Calc - 8.3

Serum Electrolytes: Na+ 1330

K+ 5.1

Others

Cl- 90.7, U-A - 3.6

LFT: Bilirubin - Total 0.4

SGOT/AST 18.8

Direct 0.26

SGPT/ALT 15.2

Indirect 0.14

ALP 209.3

Proteins: 7.50 Albumin

Globulin

A/G

Urine R/M:

4.70

2.8

1.68

CXR

↑ Bvm

ECG ST + V3

ECHO

Viral Markers:

HbsAg (nt)

HCV (nt)

HIV (nt)

MISC

Consent for anaesthesia:

मैं अपना/अपने मरीज का आपरेशन पूर्ण बेहोशी/स्पाइनल/एपीड्यूरल एनेस्थीसिया/नस् सून्न करा के करवाने के लिए अपनी इच्छा से तैयार हूँ। इस से सम्बन्धित सभी जानकारी और खतरे मुझे समझा दिये गये हैं। और सबकी जिम्मेदारी मुझ पर है।

Name:

Relation with Patient:

Dated:

Signature: राजेश पाठेज

ASA GRADE:

Pre-operative instructions:-

- NPO after pm
- Scheduled Morning/Previous night medications:

Plan of Anaesthesia

General Regional Other

- Patient is referred to OPD No ___ for management of:
- Other Instructions:

CECT Neck (1/11/19) ²⁰⁵⁰ - Paal constrictions seen in cervical oesophagus at level of C7 vertebrae ~ orico pharyngeal muscle spasm

- Naropharynx, Aryepiglottic fold, VC, AC, hypopharynx appear NL

- Kindly get Xray neck - AP, lateral view

- Kindly get IDL to assess VC mobility

- Review Ppt

Date
02

26/11

IDL - BIL TVC mobile

(Proxy visit)

Epiglottis (2)

✓ New - Tracheal narrowing

- Patient can be facer for Sx if Hs % > 10g/ml

- Informed written consent to be taken

- NPO - Solid food - clear liquid

Signature (SR)

5/12/19

- Kindly get dermatology review if no multiple patches over chest upper and lower limbs

- Patient is provisionally fit for the procedure ↓ Hs %

- NPO - 8hrs solids

↳ 2 hrs clear fluids

- Kindly get written informed consent

- Kindly maintain oral hygiene on day of Sx

Signature (SR)

Pre-Operative Anesthesia Record:

Date of Surgery:

Names of Anesthetists/Assistants:

Surgery :

Anesthesia: GA/Spinal/Epidural/others (

)Surgeons:

Operation Theater: I/II/III/IV/V/VI

Ventilation: Spontaneous/IPPV
 Laryngoscope: Macintosh/Fiberoptic/McCoy
 Laryngoscopy Grade: I/II/III/IV; Bouggie-Y/N
 Airway type: LMA/ET tube/DLT
 Size: (mm) Balloon air volume: ml)
 ET tube fixed at mark: (cm)

Spinal needle size:
 Epidural catheter size:
 Vertebral space: Level of block
 Drug used:
 onset time: Duration

Vital Monitoring Chart

Time (min)	0	5	10	15	20	25	30	35	40	45	50	60	70	80	90	100	110	120	Remarks	
180																				
Induction 170																				
Incubation 160																				
Incision 150																				
IV fluids 140																				
IV fluids 130																				
HR() 120																				
SAP () 110																				
DAP () 100																				
MAP () 90																				
CVP(+) 80																				
SPO2 (0) 70																				
Body Temp 60																				
ET CO2 50																				
40																				
Urine Out 30																				
20																				
10																				
0																				

Anesthetic Drugs and Fluid Chart

Time (min)->	0	5	10	15	20	25	30	35	40	45	50	60	70	80	90	100	110	120	130	140	Remarks	
Propofol																						
Fentanyl																						
Relaxant																						
N Sahe																						

Post operative instructions:
 oxygen by mask:
 analgesic:
 antiemetic:
 PCA Medication:
 Body surgace warmer: Yes/No

Signature _____
 Name: _____

Post Operative Recovery:
 Consciousness:
 Muscle Movement:
 Heart rate:
 Blood Pressure:
 Oxygen Saturation:
 Body temperature:
 Pain Score:
 Nausea Vomiting:
 Critical Event:



ANAND
HOSPITAL

MULTISPECIALITY - LEADING THE WAY

A UNIT OF MARWAH HOSPITALS PVT. LTD.
CIN : U8519UP2015PTC075167

Dr. Karan Marwah

M.B.B.S.
M.S. (General Surgery)
M.Ch (Neurosurgery)
BRAIN & SPINE SPECIALIST
Reg. No. : RMEE1902080

UHID : 202308004468	OPD No. : 39	Date : 03/Aug/2023 11:58 AM
Name : Mr.RAVINDRA PANDEY	Age/Sex : 50 Yrs. /Male	Address : RAMLILATILLA MZN
Mobile : 9568820161	Degree : M.B.B.S.,M.S.,M.Ch	Dept : OPD
Consultant : Dr.Karan Marwah	Weight	B.P 110/110
	Temperature	Spo2
		Pulse

10 Manderw today

40 vomit

40 Coloma @ 10/11/23

Act

X-ray Cervical spine

Neurosurgeon

↓ ↓ Dimin root cut

7 cm L trans

7 M 40mm trans

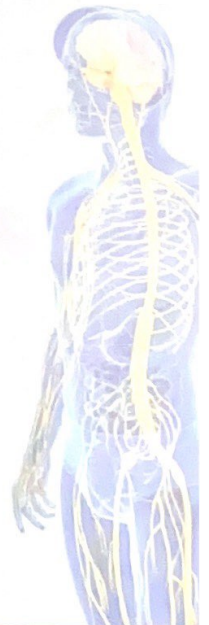7 Placed + cut

7 40mm L mm

7 40mm 1/2 mm

↓ ↓ ↓

↓



- BRAIN SURGERY
- EPILEPSY
- ORTHOPEDIC
- DENTISTRY
- SPINE SURGERY
- OBS. AND GYNECOLOGY
- TRAUMA CENTRE
- CT SCAN & PATHOLOGY
- STATE OF ART NEURO

272, BHOPA ROAD, OPP. GANDHI POLYTECHNIC, MUZAFFARNAGAR (U.P.) • E-mail : marwahhospital@gmail.com
• NOT FOR MEDICO LEGAL PURPOSE • FOR APPOINTMENT : 8057188237, 0131-2411030 • WhatsApp : 9800000000

24 x 7 Emergency & Ambulance Ph.: 8057188237 • Timing : 11 AM to 4 PM & 6 PM to 8 PM • रविवार सायं ७



ANAND HOSPITAL

MULTISPECIALITY - LEADING THE WAY

A UNIT OF MARWAH HOSPITALS PVT. LTD.
CIN : U8519UP2015PTC075167

Dr. Karan Marwah

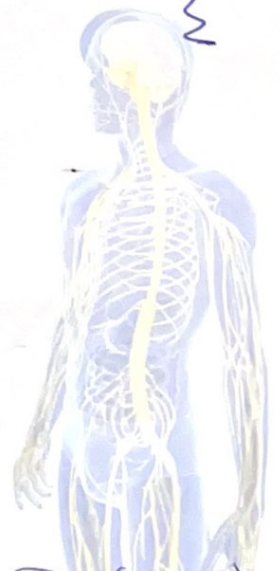M.B.B.S.
M.S. (General Surgery)
M.Ch (Neurosurgery)
BRAIN & SPINE SPECIALIST
Reg. No. : RMEE1902080

UHID : 202308004468	OPD No. : 83	Date : 10/Aug/2023 06:25 PM
Name : Mr.RAVINDRA PANDEY	Age/Sex : 50 Yrs. 7 Days /Male	Address : RAMLILATILLA MZN
Mobile : 9568820161	Degree : M.B.B.S..M.S..M.Ch	Dept : OPD
Consultant : Dr.Karan Marwah	Weight	B.P <i>110/70</i>
	Temperature	Spo2
		Pulse

*Uol madaal m doel
Uovum
Uolign @mm
and*

*dy + Dmm 500 + ca
T. ka 2 m
Tm uo xwo + m
T plares 2 m
T. kka m 2 m
T. kq y 2 m*

Torannp xioel



(5 2 m)



• BRAIN SURGERY • EPILEPSY • ORTHOPEDIC • DENTISTRY
• SPINE SURGERY • OBS. AND GYNECOLOGY • TRAUMA CENTRE • CT SCAN & PATHOLOGY • 24x7 PHARMACY
• NOT FOR MEDICO LEGAL PURPOSE • FOR APPOINTMENT : 8057188237, 0131-2411030 • WhatsApp : 9897405303
• STATE OF ART NEURO ICU

272, BHOPA ROAD, OPP. GANDHI POLYTECHNIC, MUZAFFARNAGAR (U.P.) • E-mail : marwahhospital@gmail.com

24 x 7 Emergency & Ambulance Ph.: 8057188237 • Timing : 11 AM to 4 PM & 6 PM to 8 PM • शनिवार सायं अवकाश



ANAND HOSPITAL

MULTISPECIALITY - LEADING THE WAY

A UNIT OF MARWAH HOSPITALS PVT. LTD.

CIN : U8519UP2015PTC075167

Dr. Karan Marwah

M.B.B.S.
M.S. (General Surgery)
M.Ch (Neurosurgery)
BRAIN & SPINE SPECIALIST
Reg. No. : RMEE1902080

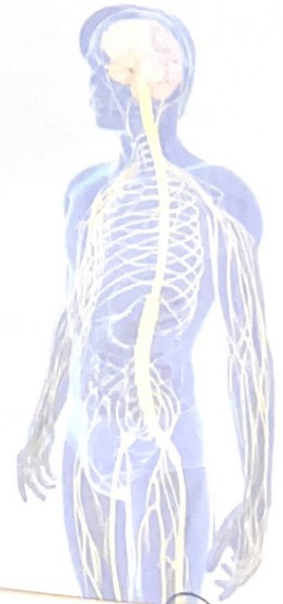UHID : 202308004468	OPD No. : 110	Date : 30/Oct/2023 06:50 PM
Name : Mr.RAVINDRA PANDEY	Age/Sex : 50 Yrs. 2 Months 27 Days /M	Address : RAMLILATILLA MZN
Mobile : 9568820161	Degree : M.B.B.S..M.S..M.Ch	Dept : OPD
Consultant : Dr.Karan Marwah	Weight	B.P
	Temperature	Spo2
		Pulse

Handwritten notes in Hindi:
 400gms c @ukar 15dy 2 + 2mm
 40 vertice
 40 madairns

Handwritten word: muel

Handwritten notes in Hindi:
 - BRINE 1 form
 - form 2 + form
 - form 2 1 mm
 - flenda + anti
 - form 2 + form

Handwritten word: Torofn x 2el



• BRAIN SURGERY • EPILEPSY • ORTHOPEDIC • DENTISTRY
 • SPINE SURGERY • OBS. AND GYNECOLOGY • TRAUMA CENTRE • CT SCAN & PATHOLOGY • 24x7 PHARMACY
 • STATE OF ART NEURONCL

272, BHOPA ROAD, OPP. GANDHI POLYTECHNIC, MUZAFFARNAGAR (U.P.) • E-mail : marwahhospital@gmail.com
 • NOT FOR MEDICO LEGAL PURPOSE • FOR APPOINTMENT : 8057188237, 0131-2411030 • WhatsApp : 9897405303

24 x 7 Emergency & Ambulance Ph.: 8057188237 • Timing : 11 AM to 4 PM & 6 PM to 8 PM • शनिवार सायं अवकाश



ANAND
HOSPITAL
MULTISPECIALITY - LEADING THE WAY

A UNIT OF MARWAH HOSPITALS PVT. LTD.
CIN : U8519UP2015PTC075167

Dr. Karan Marwah

M.B.B.S.
M.S. (General Surgery)
M.Ch (Neurosurgery)
BRAIN & SPINE SPECIALIST
Reg. No. : RMEE1902080

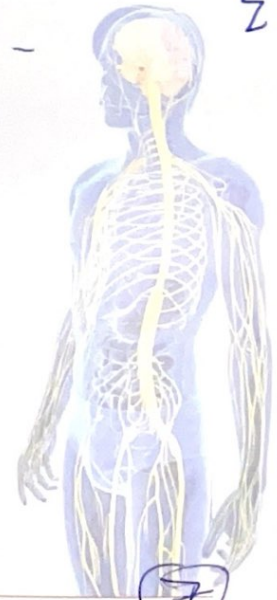UHID : 202308004468	OPD No. : 117	Date : 06/Nov/2023 06:53 PM
Name : Mr.RAVINDRA PANDEY	Age/Sex : 50 Yrs. 3 Months 3 Days /Ma	Address : RAMLILATILLA MZN
Mobile : 9568820161	Degree : M.B.B.S..M.S..M.Ch	Dept : OPD
Consultant : Dr.Karan Marwah	Weight	B.P
	Temperature	Spo2
		Pulse

Govt @ water
Govt
Govt

all Soft GI cancer

- Bcm + font
- Km + font
- 7 Cm + 1mm
- vxm + 1m
- tlaxa + cmr
- traxa @ + font

Tomy 100%



- BRAIN SURGERY • EPILEPSY
- SPINE SURGERY • OBS. AND GYNECOLOGY
- ORTHOPEDIC • TRAUMA CENTRE
- DENTISTRY • CT SCAN & PATHOLOGY
- 24x7 PHARMACY • STATE OF ART NEURO ICU

272, BHOPA ROAD, OPP. GANDHI POLYTECHNIC, MUZAFFARNAGAR (U.P.) • E-mail : marwahhospital@gmail.com
• NOT FOR MEDICO LEGAL PURPOSE • FOR APPOINTMENT : 8057188237, 0131-2411030 • WhatsApp : 9897405303

24 x 7 Emergency & Ambulance Ph.: 8057188237 • Timing : 11 AM to 4 PM & 6 PM to 8 PM • शनिवार सायं अवकाश