

79

105

बहिरंग-पत्र
कमांक-च 707284
सर सुन्दरलाल चिकित्सालय, काशी हिन्दू विश्वविद्यालय

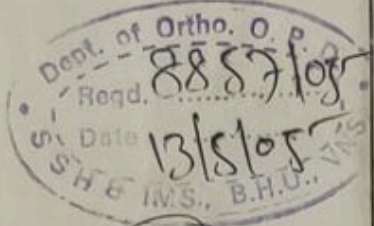
नाम अश्विनी
आयु 2 पु०/स्त्री०/बा०

दिनांक चिकित्सा

13/5/05

संक्षिप्त विवरण

X-ray Pelvis - both Hips - AP.
GML



79

Pedicle length - 4pp.

- Ext. Rotation of both lower limbs at hip
- ~~Flat~~ Plano Valgus
- genu Valgum

To. Physiotherapy (Tech)
P). evaluate the core & discum
GML

AS - Splintage for walk
- Exercises

शुक्रवार

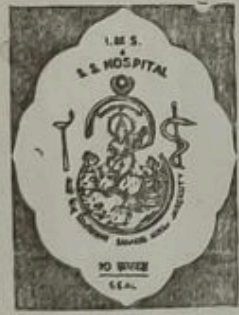NO H/O Anemia, Asphyxia, still term cesarean delivery
Hyperbilirubinosis. Photo therapy done for 9 weeks

H/O mild delayed milestones.

- can walk independently but c(4)
- operated for cleft palate hemiplegic

O/E. Cor. Lenzed (4) 4L

- voluntary control (4) 4L GM. / fair FM. / fair
- plano valgus feet
- genu valgum
- (4) hemiplegic gait -



बृहस्पतिवार

09.6.05

0522-2494082 (2.30-4.00 PM)

Dr. V. Bhatia

Professor
Department of Endocrinology
S.G.P.G.I.M.S., Lucknow

Wed/Thurs.



आरम्भवा समो जित

Sanjay Gandhi Postgraduate Institute of Medical Sciences, Lucknow
Deptt. of Endocrinology

Patient OPD Record

DOB-26/12/02

For appointments: Tel.: (0522)-2494075, 2495004

Medical Social Worker, OPD Hall No. 1

Doctor's signature for medical reimbursement to be taken within 6 months of expenditure.

Name Avni

CR No. 2013618425 - Diagnosis

Age/Sex 10¹⁰/12 yrs

24/10/13

Short stature /
Multiple dysmaturisms

- WT = 21.6 kg
- HT = 124.4 cm
- OFL = 49 cm
- Broad forehead
- Microphthalmia
- Broad nasal bridge
- Prominent columella
- ? Micrognathia

TV ~ 2-3rd, SPL (+), PH,

Plan =>

- Genetic follow up
- Chemistry
- Thyroid profile
- 6 month date shu

TTC (n)

Chem

Hb

T₄

TSH

23/7/15

12/7/12

25.7


132

GV₂₁ = 4.4 cm/yr


Prepubertal TV 3ml b/l

Al To follow for onset
of puberty.
6 month date

28/01/16

Date	Clinical Condition	Advice
<p>Short stature with narrow palpebral fissures</p>	<ul style="list-style-type: none"> - Flattened tip nose - mild retrognathia. - Everted umbilicus - mild soft fissure syndactyly. - No sweat scurfum. - Externally rotated. ears - hypoplastic, alae nasi - cardiac. 	<p>-?? Acanthosis syndrom</p> <p>Review 6 months.</p>  <p>Responsible 2317115</p>

Date	Clinical Condition	Advice
<p>28/Jan/16</p>		

Date	Clinical Condition	Advice
Short stature	ichn-narrow palpebral fissures - flattened tip of nose - mild retrognathia. - Everted umbilicus - Mild soft fissure syndactyly. - No shaft scutum. - Externally rotated. ear - hypoplastic alae nasi - cleftic..	-?? Anarkog syndrome
	Review	6 months.
		 23/7/15

28/1

बहिरंग-पत्र

क्रमांक-च 641913

सर सुन्दरलाल चिकित्सालय, काशी हिन्दू विश्वविद्यालय

नाम

Arival

आयु

Arival

पुं/स्त्री/बा०

दिनांक

चिकित्सा

5/3/05

संक्षिप्त विवरण

PLASTIC SURGERY,

Regd. No. 1329/05

16/6/05

(46)

To come in person Saturday at 8:30 AM for speech therapy

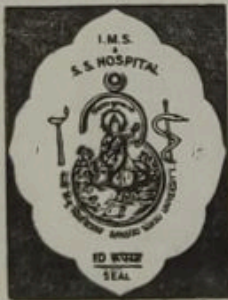
Speech therapy given
Be in regular follow up
Review after 3 months.

(28)

21/6/05

for teeth problem please contact
Dentist
& ~~visit~~ Mental Retardation. Dept.
Refer to Paed. medicine
for evaluation.

h
21/6.



डॉ० वी० महाचार्या
प्रोफेसर प्लास्टिक सर्जरी
पूर्व दिग्गजाचार्य

एम०एस०एम०एस०एम०पी०एच०डी०
एफ०आई०सि०एस०एम०एन०एम०एम०एम०
मंगलवार

PAEC-4101



अ० भा० आ० सं० अस्पताल / A.I.I.M.S. HOSPITAL

विद्युत् लेखी विभाग / Out Patient Department

General Consultation Time: 9.00 AM-1.00 PM



DeptSeq: 306

SPITAL PREMISES

P0 103946349

Dept: Endocrinology

OPR-6

Clinic No: PAEC- Clinic No.2018/PAEC/4101

Unit: Unit-I

Name: AVKIRAL RAI

Room: 1 Endo

S/O AK RAI, 16Y 7D, M

N/19

Ph: 9868940983

Days:

OMEGA GREATER NOIDA, UTTAR PRADESH, Pin:0, INDIA

App. Date:

27/08/2018

/O.P.D. Regn. No. _____

एकक/Unit _____

विभाग/Dept. _____

नाम/Name _____

पता/Address _____

Appt. ID:



2018082713239

निदान/Diagnosis

Pediatric & Adolescent Endocrinology Clinic (PAEC)
Department of Endocrinology & Metabolism, AIIMS
Every Monday, 2 to 4 pm, 2nd Floor, Main OPD Block

दिनांक/Date

उपचार/Treatment

Ht - 149.2 cm

wt - 37.2 kg

mht - 164.6 cm

fht - 169.6 cm

MPH - 173.6

HT SDS - 2.6

Wakeup - (4)

Subclinical
Hypothyroid

Significant Short stature

Short for MAH

Multiple dysmorphic features
operated for cleft palate

Bone age 13⁶/₁₂ yrs Chronage 15⁶/₁₂

? Araskog Syndrome

HT prognosis explained

Plan:

- Dental Problem - Dr Vijay Malhotra
Dental OPD, CDER
- Voice problem - ENT consultation

CLEAN AND GREEN AIIMS / एम्स का यही संकल्प, स्वच्छता से काया कल्प

अंगदान-जीवन का बहुमूल्य उपहार / ORGAN DONATION - A GIFT OF LIFE

O.R.B.O., AIIMS, 26588360, 26593444, www.orbo.org Helpline - 1060 (24 hrs service)

Rx

high protein diet

↑↑ calcium intake

Toylash Sakut - one month

F/U 3 months



DR. RAJESH KHADGAWAT

Professor

Dept. of Endocrinology & Metabolism
AIIMS, New Delhi-110029

Dr Praveen Sharma faculty cell



अ० भा० आ० सं० अस्पताल / A.I.I.M.S. HOSPITAL
बहिरंग रोगी विभाग / Out Patient Department

4

अस्पताल के अन्दर धूम्रपान मना है। / SMOKING IS PROHIBITED IN HOSPITAL PREMISES

शरीरमार्च खतु सर्वसाधनम्

New Patient

Dept. Reg. 2018/025/0008282

General / 10

OPR-6

एकक / Unit _____

Endocrinology/Unit-I

कक्ष/Room: 1 Endo

विभाग / Dept. _____

Name: AVKIRAL RAI

Days: Mon, Fri

नाम / Name _____

नाम: अवकिराल राय

16Y पुंल/♂


पं. No. _____

S/O Av RAI

Ph. 9868940983

पता / Address _____

पिता: अव रै



UHQ: 103946349

Date: 20/08/2018

निदान / Diagnosis

? Short stature.

दिनांक / Date

उपचार / Treatment

Ht = 151 cm
wt = 38 kg.

C/S/B h-4-4upta

P wt 169.0 gm / 75%
M wt 781. Kg.
- 164.0 gm

RAV

R / A in r/hydr

Thick

Plz provide file.

27/8

For. opinion. of Sir.
and registration
in PAEC Clinic

22/8/18

Please Register in
PAEC 2.00 PM OPD

Handwritten signature

DR. RAJESH KHADGAWAT