



## CARDIOLOGY

DATE : 27/08/2016  
ANGIOPLASTY NO : 29855  
NAME : Mr. Hans Nath Pandey  
AGE/SEX : 72 Yrs. / Male  
HOSPITAL NO : 7160  
WARD : CCU  
CONSULTANTS : DR. PURSHOTAM LAL  
: DR. PANKAJ RANJAN

## ANGIOPLASTY REPORT

### PRE ANGIOPLASTY DIAGNOSIS

Coronary artery (Left Main with Triple Vessel) disease  
Angina and breathlessness on exertion Grade III-IV  
Essential hypertension

**PROCEDURE** : Rotational atherectomy with PTCA with stenting to Left Main to LAD and RCA (by using drug eluting stents) and plain balloon angioplasty to LCX and PDA with intravenous glycoprotein IIb/IIIa receptor blockade therapy by using progreal catheter.

**DISCUSSION**: Mr. Hans Nath Pandey, 72 yrs. male underwent coronary angiography on 08/08/2016 which revealed left main with triple vessel disease. The patient was found high risk for CABG because of advanced age and weak lungs. Therefore, less invasive and less risky method of myocardial revascularisation by angioplasty was preferred and a plan for PTCA to Left Main to LAD, LCX, RCA and PDA was made. Thus after obtaining an informed written consent he was taken for Procedure.

### Cardiology Wing

X - 1, Sector - 12, Noida - 201301  
Tel. : +91 120 2533 491, 2444 466, 4366 666  
Fax : +91 120 2533 487

### Multispeciality Wing

L - 94, Sector - 11, Noida - 201301  
Tel. : +91 120 2522 959, 2442 666  
Fax : +91 120 2442 555

E-mail : info@metrohospitals.com, Website: www.metrohospitals.com

Regd. Office : 14, Ring Road, Lajpat Nagar IV, New Delhi - 110027  
NHI/CL/0115/Rev. No. 01

Digitally signed by AFUN  
KUMAR RAI  
Date: 2022.12.18 19:30:52 UTC  
Reason: Document Owner  
Location: District and Sessions  
Court

**REPORT:**

**Left Main to LAD:** The LCA was engaged with 7F XB 3.5 guide catheter. Left Main to LAD lesion was crossed with 0.014" Run Through wire which was then exchanged for Rota wire with the help of Microcatheter (Progreat). A 0.009" Rota wire (Boston) was used to cross the Left Main to LAD lesion. 1.5 mm Rota burr advancer was used for atherectomy. Predilatation of Left Main to LAD lesion was done with 2.0 mm x 28 mm balloon inflated at 10 atmosphere for 30 seconds. Thereafter, a 3.5 mm x 32 mm Promus Element drug eluting stent was deployed in Left Main to LAD at 16 atmosphere for 30 seconds. Final check-angiography revealed no residual stenosis with brisk antegrade flow.


**LCX:** A 0.014" Run Through wire was used to cross the lesion. The LCX lesion was dilated by using 2.0 mm x 28 mm and 1.5 mm x 08 mm balloons inflated at 8 atmosphere for 10 seconds. Final check-angiography revealed no residual stenosis with brisk antegrade flow.

**RCA and PDA:** The RCA was engaged with 6F AL 1 guide catheter. A 0.014" Run Through wire was used to cross the RCA and PDA lesions. The lesions were predilated by using 2.0 mm x 28 mm and 1.5 mm x 08 mm balloons inflated at 8 atmosphere for 10 seconds. Thereafter, a 3.5 mm x 38 mm Promus Element drug eluting stent was deployed in RCA at 20 atmosphere for 30 seconds. Final check-angiography revealed no residual stenosis with brisk antegrade flow.

Patient tolerated the entire procedure very well without any significant angina or haemodynamic disturbances. He was later shifted to CCU for observation and monitoring.

**IMPRESSION** - Successful Rotational atherectomy with PTCA with stenting to Left Main to LAD and RCA (by using drug eluting stents) and plain balloon angioplasty to LCX and PDA with intravenous glycoprotein IIb/IIIa receptor blockade therapy by using progreat catheter.

**Advice :** Check angiography to be done after six months.

  
**DR PURSHOTAM LAL MD AB FACM FACC FRCP(C) MBCIS FSCAI**  
**DIRECTOR INTERVENTIONAL CARDIOLOGY**

**DR. PANKAJ RANJAN, MD, DM**  
**CONSULTANT CARDIOLOGIST**





# METRO

HOSPITALS & HEART INSTITUTE  
(a unit of Metro Hospitals of Medical Services Pvt. Ltd.)  
REGD. OFFICE : 14, Ring Road, Lajpat Nagar IV, New Delhi - 110024  
(Branch, Noida & Gurgaon, Gurgaon, Faridkot)

## DEPARTMENT OF CARDIOLOGY DISCHARGE SUMMARY

NAME	:	Mr. Hans Nath Pandey
AGE/SEX	:	72 Yrs./Male
D-D-A	:	25/08/2016
D-D-D	:	30/08/2016
ID No.	:	7160-2016
IP No.	:	3942
PANEL	:	CASH
WARD	:	Fifth Floor
CONSULTANTS	:	Dr. P. Lal / Dr. P.T. Upasani / Dr. S. Kanwar Dr. Nilkanth C. Patil / Dr. Pankaj Ranjan / Dr. Sameer Gupta

### DIAGNOSIS :

Coronary artery (Left Main with Triple Vessel) disease  
Angina and breathlessness on exertion Grade III-IV  
Essential hypertension

### ON ADMISSION :

Physical Examination : No cyanosis, pallor, oedema  
Heart Rate : 70 bpm, regular  
BP : 140/70 mmHg  
JVP : Not raised  
CVS : S1 S2 normal  
Chest : Clear  
Abdomen : Soft, no organomegaly

**PROCEDURE** : Coronary angiography and rotational atherectomy with PTCA with stenting to Left Main to LAD and RCA (by using Drug Eluting Stents) and plain balloon angioplasty to LCX and PDA.

Mr. Hans Nath Pandey, 72 yrs. old male, hypertensive, nondiabetic, ex-smoker, k/c/o CAD was admitted with complaints of angina and breathlessness on exertion. He underwent coronary angiography on 08/08/2016 which revealed Left Main with triple vessel disease. Echocardiography showed adequate LV function (EF=55%). Consultation was sought from Pulmonologist (Dr. Deepak Talwar). PFT was done which showed mild obstructive ventilatory defect. The patient was found high risk for CABG because of advanced age and weak lungs. Therefore, less invasive and less risky method of myocardial revascularisation by angioplasty was preferred. B/L carotid Doppler, Arterial Doppler of B/L lower limbs and ultrasound whole abdomen were done (reports enclosed). His PTCA with stenting to Left Main to LAD and RCA (by using Drug Eluting Stents) and plain balloon angioplasty to LCX and PDA was done on 27/08/2016 with intravenous glycoprotein IIb/IIIa receptor blockade therapy which was used in view of thrombotic lesion. Detailed angioplasty report is enclosed. His post PTCA period was uneventful and he is being discharged in a stable condition.

### ology Wing

tor - 12, Noida - 201301  
120 2533 491, 2444 466, 4366 666  
120 2533 487

### Multispeciality Wing

L - 94, Sector - 11, Noida - 201301  
Tel. : +91 120 2522 959, 2442 666  
Fax : +91 120 2442 555

E-mail : [info@metrohospitals.com](mailto:info@metrohospitals.com), Website: [www.metrohospitals.com](http://www.metrohospitals.com)  
Regd. Office : 14, Ring Road, Lajpat Nagar IV, New Delhi - 110024

MHHI/CL/0115/Rev. No. 01

**TREATMENT :**

Low salt, low fat diet

1. Tab. Ecosprin 75 mg once daily at 9 p.m.
2. Tab. Prax (Prasugrel) 10 mg once daily at 9 a.m.
3. Tab. Nitrocontin 6.4 mg twice daily at 9 a.m. and 9 p.m.
4. Tab. Nebistar 5 mg once daily at 9 a.m.
5. Tab. Ramistar - H (2.5) once daily at 9 a.m.
6. Tab. Rosuvas 10 mg once daily at 9 p.m.
7. Cap. Pan-D once daily at 7 a.m.
8. Foracort Inhaler (200) 2 puffs twice daily with spacer

**Do not discontinue Ecosprin and Prax unless advised by the treating Cardiologist.**

**ADVICE :**


1. Rest for one week.
2. Check angiography after six months.
3. Fasting & PP Sugar, KFT, Lipid profile (fasting), CBC to be done after two weeks.

**FOLLOW-UP:** In Cardiac OPD after two weeks with prior appointment.

- For OPD appointment contact 9871124095

- For appointment contact Mr. Bhaskar - 9818754788 / Mr. Anurag - 9871369832  
(from 9 a.m. to 6 p.m.)

- For any emergency contact 9810855136 / 9958905666


  
DR. PURSHOTAM LAL,  
MD, AB(USA), FACM, FRCP(C), FACC, FSCAI (USA)  
DIRECTOR INTERVENTIONAL CARDIOLOGY

DR. SAMEER GUPTA MD, AB (USA), FACC, FSCAI  
CONSULTANT INTERVENTIONAL CARDIOLOGIST &  
ENDOVASCULAR INTERVENTIONALIST

DR. NILKANTH C. PATIL, MD, DM  
CONSULTANT CARDIOLOGIST

DR. P.T. UPASANI, MD DM FCCP FCSI  
SENIOR INTERVENTIONAL CARDIOLOGIST

DR. PANKAJ RANJAN, MD, DM  
CONSULTANT CARDIOLOGIST

  
DR. S. KANWAR, MD, PhD  
CONSULTANT CARDIOLOGIST





UHID No : 28776  
 Name : MANISH NATH PANDEY  
 Sex / Age : Male / 78 Years  
 Address : D-4

07-07-2022

DE  
 RR 97/min  
 BP 120/60 mmHg

Follow up

RIS  
 CVS  
 PA

wt 70.4 kg

RIA  
 H<sub>2</sub> inhibitor

↓  
 BIL FF - 133  
 PP - 154

21/09/22

wt 69.8 kg

OIA

PR-78/min  
 BP-120/70 mm

Follow up

RIS  
 CVS  
 BIV

RIA  
 GI tract + weak

↓  
 BIL FF  
 PP

As per doctor  
 do Routine check  
 2 months  
 complete

having dizziness & dyspnea  
 on walking

see report  
 1200. cold. 4. 30 days

dr. for  
 : 150000

R  
 Diabetic diet - SRD

① ② ③ ④ ⑤ ⑥ ⑦

75. Akerfix - Total MS

x relay

hall

Dr. Nethan R  
 CEO F...  
 37th floor  
 Gop...  
 Gidd...  
 Monday

Re Doest each 1SRD

① cap lipi care Gold 1 tab

② cap Renodag - 1000 x 1000

③ ~~cap Sinitel - 400 mg~~

④ cap Nikoran - OD 10 x 1000

⑤ cap Concor - 5 mg x 1000

⑥ cap Silodal - D8 1 tab

⑦ cap Glycomet - SR - 500 x 1000

⑧ 75 Sinitel - 400 mg MS, etc

hall







AH  
Jyoti  
ojas@sadgurustrust.org

**Dr. Alok Sen**  
Medical Superintendent  
E-Mail: aosen@rediffmail.com

**Dr. Elesh Jain**  
Administrator  
E-Mail: dr.elesh@sadgurustrust.org

**Ophthalmology**

Dr. Pooja P. Agade

**Children's Eye Care Centre**

- Dr. Pradnya Sen (HOD)
- Dr. Elesh Jain
- Dr. Anil Mohan
- Dr. Chiranjeev Shah
- Dr. Easha Rameswar

**Cornea & Refractive Surgery:**

- Dr. Gaurav Singh Parmar (HOD)
- Dr. Ashok Kumar
- Dr. Sharmada Jureja

**Glaucoma:**

- Dr. Rakesh Shukla (HOD)
- Dr. Navrat Singh Ahlawalia

**Oculoplasty:**

- Dr. Navendra Paridar (HOD)

**Retina:**

- Dr. Alok Sen (HOD)
- Dr. Shubhi Tripathi
- Dr. Sachin D. Sharma
- Dr. Pradyumn Tekwani
- Dr. Tina Agrawal
- Dr. Vanshi D. Athavale
- Dr. Gaurav Mohan Kohli
- Dr. Pratik Shetty

**Cataract IOL Clinic:**

- Dr. Rajesh Joshi (HOD)
- Dr. Ashwesh Bajaj
- Dr. Devendra K. Sharma
- Dr. Anusudha Nimbhorkar

**Centre for Community**

**Ophthalmology:**

- Dr. Elesh Jain
- Md. Subesh Kayyadyil

**Advisory Board:**

- Dr. Keki Mehta, Mumbai
- Prof. A.K. Grewal, New Delhi
- Dr. Ranjit Maniar, Mumbai
- Dr. Rajiv Ramesh, Chennai
- Dr. Ramesh B. Shah, USA
- Dr. Genshiro I. Taniya, UK

Date: 20/10/22

**Case Summary**

Hospital Registration No: P2161721

Patient Name: Mr. Hans Nam Pandey Age/Sex: M

Date of Examination: 28/11/2022

Chief complaints: Diminution of vision in left eye since 4 months.

**Ocular examination:**

	Right Eye	Left Eye
BCVA:	6/6	PL + RD
Anterior Segment:	K clear A.C. - 3 M.C. P.C.IOL	K clear Blood in chamber A.C. - 2 M.C. P.C.IOL R.I.B.
Fundus Examination:	CDR - 0.3:1 FR + colored woodpecker	V.Haze +

Investigations: B scan +

Clinical Diagnosis: left eye High grade Proliferative diabetic Retinopathy

Treatment advised: Patient can be given Anti VEGF inj.  
Needs regular BP and sugar monitoring.

Dr. Alok Sen

Medical Officer

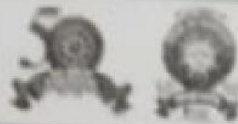(Founded by Parami Pujya Shri Rameshchodasji Maharaj)

Jankikund, Chitrakoot 210 234 Dist. Satna (M.P.) T: 7471116346, 07670 265 320, 265 600 www.sadgurustrust.org

सही तो इलाज सही







Retina Surgical Sheet

Hemant Mahesh

SO/WO Anand Ashwari

Male  Female

M.R.D. No. P2161725

Referral - Dr. Anand Chatur Anesthetist

Operating Surgeon - OT Assistant - Mr. E. Jay

Date Of Surgery - 25/11/22

No. 00 Starting Time - 01:00 pm Ending Time - 01:05 pm

Preparation - In Patient / Out Patient -

Surgery LE - my. Ravi Patel & M

Primary Break  
Cryolaser  
Scleral Buckle (240 Band)  Yes  No

End to end at (Clock Hour)

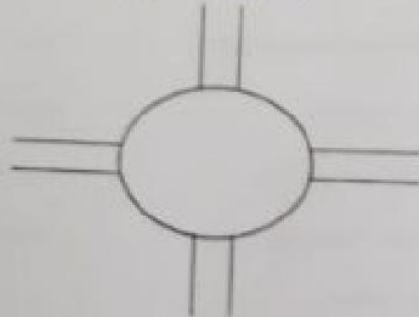
380 yrs.

Location Of the tyre (Clock Hour)

Eye Size Position

Orientation

Drainage Size Distance From Limbus



Complication RNV 13 22007

PLANA VITRECTOMY

Gauge: 20/23/27/35

P. USG: Date Finding

P. Fundus Picture: Date Finding

Surgical Steps:

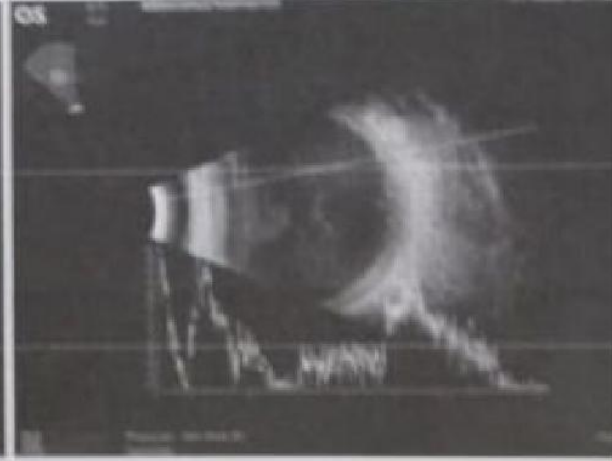
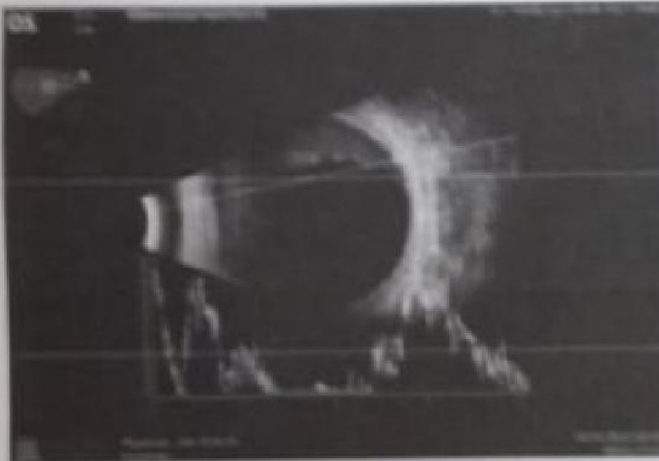
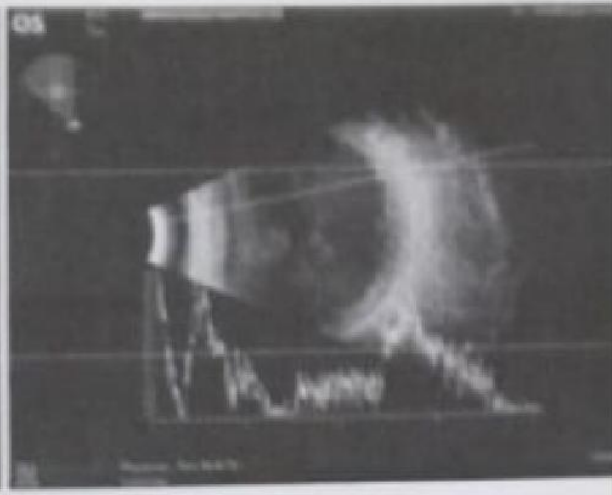
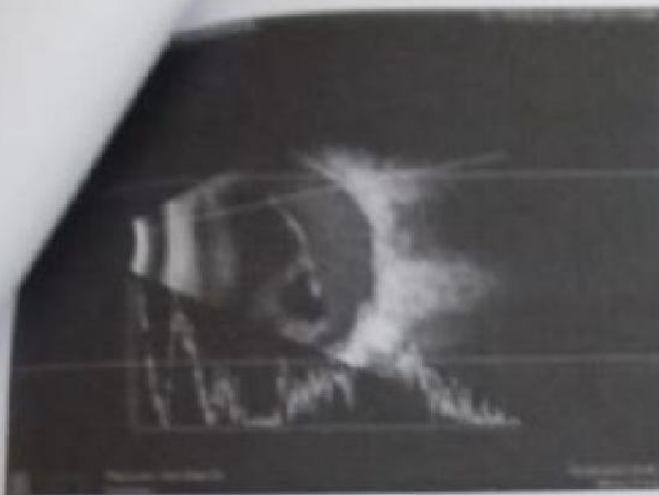
Sclerectomies:

Plana Lensectomy:

Vitreotomy:

New York, Dr.  
New York, Dr.  
New York, Dr.

Small  
Date of birth  
Gender  
Race



Comments

Empty box for comments.

Comments

Empty box for comments.



ACQUITYS-DANTIC CORPORATION

Location:

Patient Information:

Name: Test Subject

Age: 2

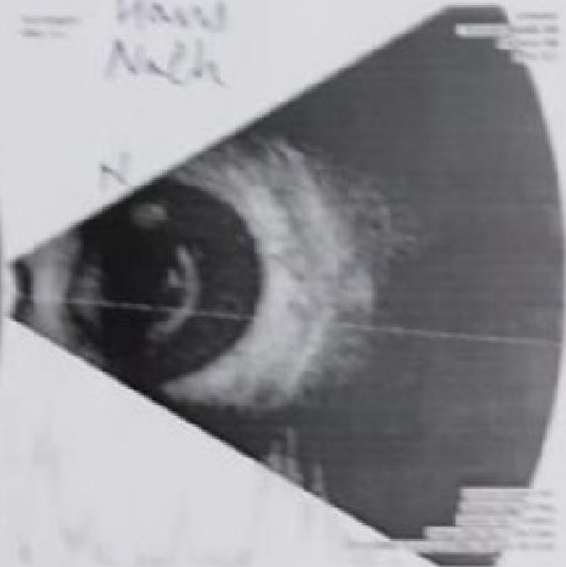
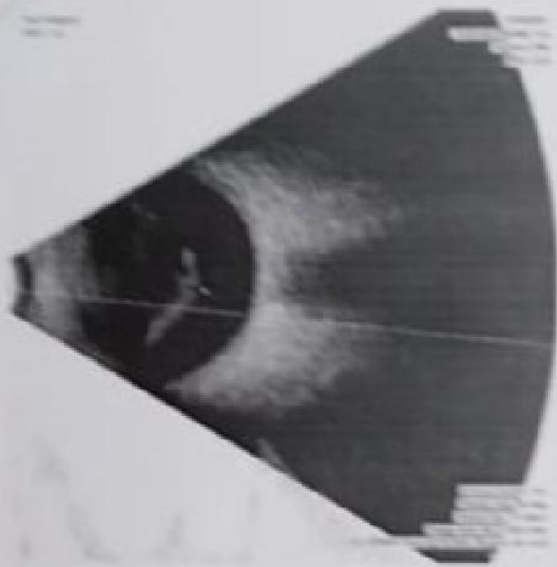
Exam Type: LD

Diagnosis:

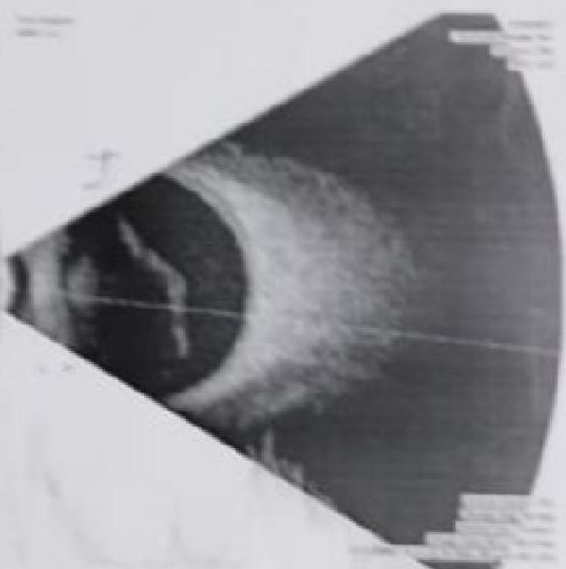
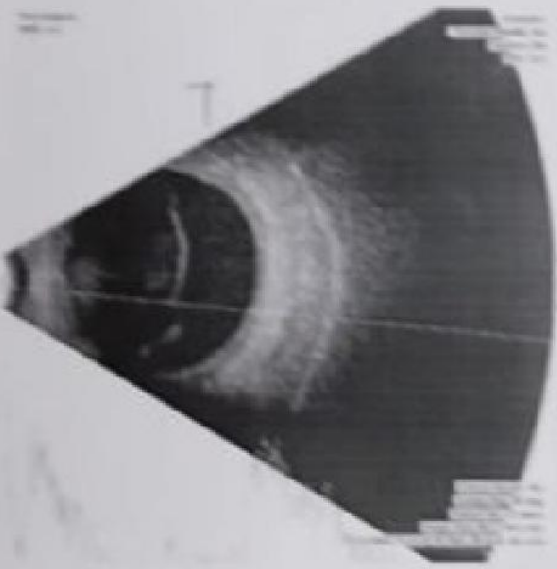
MRD 100

Number: none

02222 @ 15:57 Test Subject: 02112 0000 - Pupil, 270 degrees, Sampled @ 20 MHz, Pulse @ 12 MHz, 80 gain, 80 width, 12.8 sec



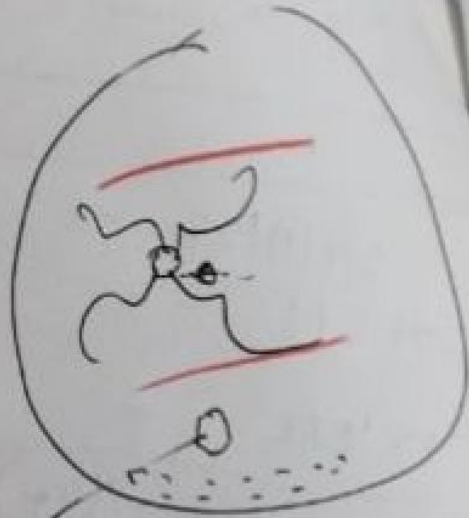Hand  
Neth



9

Minimal  
base blood  
in VC

H/V



plaque  
of dehydrated  
blood

R/B by Ashisham Sir

Head end  
Elevation

Adv

- Eld Predf. etc. etc.
- Eld Moni etc.
- Eld Hauide TDS

FP - disc. c  
Am

(D)

3 days /

- T. VYSER D RD
- T. Pan 4omp OD

HA 1 week/OD

Adv  
05301  
29/11/22

URU Sadguru  
ANGH Neta Chaitanya  
Papa Shri Ranchhodra



Adv

- q of headfelle btd
- q maxi DID } (L)
- b1 monitoring
- Plan, @ PPU
- (L) B: scan
- (L) PA → 3/ possible fluids

Adhish  
01/11/22

28/11/22

visu (L)

- CPVD (L)
- VM (L)
- NO fractures
- Retina on 02/16

Date - 28/11/22  
 Time - 12 pm  
 B.p. - 150/90 mmHg

Date - 28/11/22 at 5:30 hr

BP - 170/95 mmHg  
 RA - 72/1 min

Reflex to JAC for Dr. Deyak &  
 photo of mixed

Re 19/1/22

T CLONING /copy/  
 MONA A 67





**SADGURU SEVA SANGH** | Sadguru  
Netra Chikitsalaya  
& Pratikshala of Siddhanta  
(Founded by Pawan Prasad Singh Raxzhadhisi Maharaj)

SAC/RET/19/725

Retina Surgical Sheet

Patient Name: Hans Nath Pandey      so/w/o: Avadh Bihari pandey

Sex:  Male       Female      M.R.D. No. P2161725

Surgeon: Dr. Abhiram      Anesthetist: \_\_\_\_\_

Assisting Surgeon: Dr. Aditi Agaswani      Assistant: Dr. Ankur

Diagnosis: \_\_\_\_\_      Date Of Surgery: 28/11/22

OT No.: 08      Starting Time: 09:30 PM      Ending Time: 05:30 PM

Skin Preparation: Dr. Ankur      InPatient/Out Patient: IP      Acetamin

**RD Surgery**

Primary Break:

Position:  Cryo/Laser

Encirclage(240 Band):  Yes       No

Tide end to end at(Clock Hour):

276/280 tyre:

Position Of the tyre( Clock Hour):

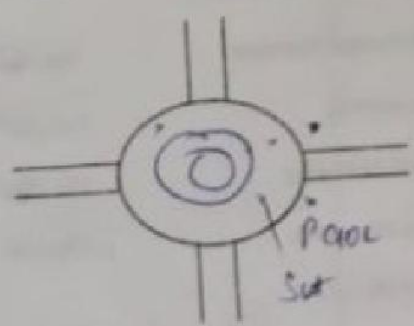
Sponge: Size: \_\_\_\_\_      Position: \_\_\_\_\_

Orientation: \_\_\_\_\_

SRF drainage: Size: \_\_\_\_\_      Distance From Limbus: \_\_\_\_\_

Any Complication

LE - PPV + EL



**PARS PLANA VITRECTOMY**

Gauge: 20/23/27/35

Pre OP. USG: Date: \_\_\_\_\_      Finding: Periphery checked

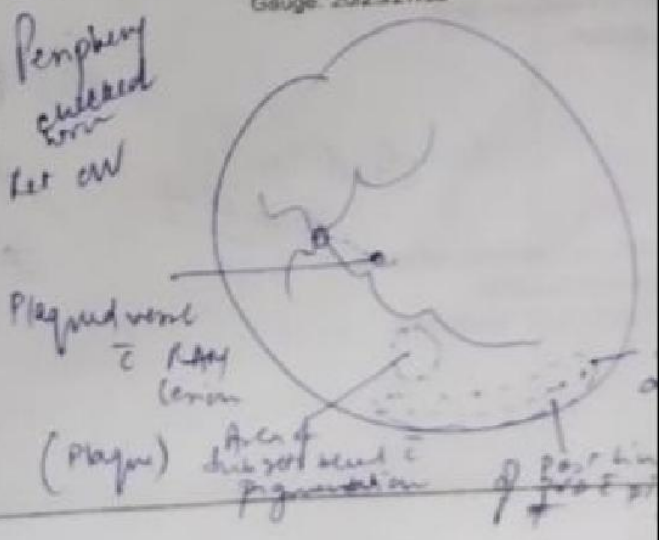
Pre OP Fundus Picture: Date: \_\_\_\_\_      Finding: Let out

Surgical Steps:

Site Of Sclerectomies:

Pars Plane Lensectomy:

Core Vitrectomy:



\* vitreous could not be dissected beyond it.

use / Notes:

stor Code: 370

This is Computer generated Discharge.

Dr. \_\_\_\_\_  
12/2022  
Signature / Code of Eye Surgeon