



INDIRA J ORTHOPAEDIC CENTER

Dr. Rajendra Singh

MBBS, M.S. (Ortho.)
Bone & Joint Surgeon

डॉ० राजेन्द्र सिंह

हड्डी एवं जोड़ रोग विशेषज्ञ

Name

M. K. Singh

Age

Sex

Date

19/8/23

3D

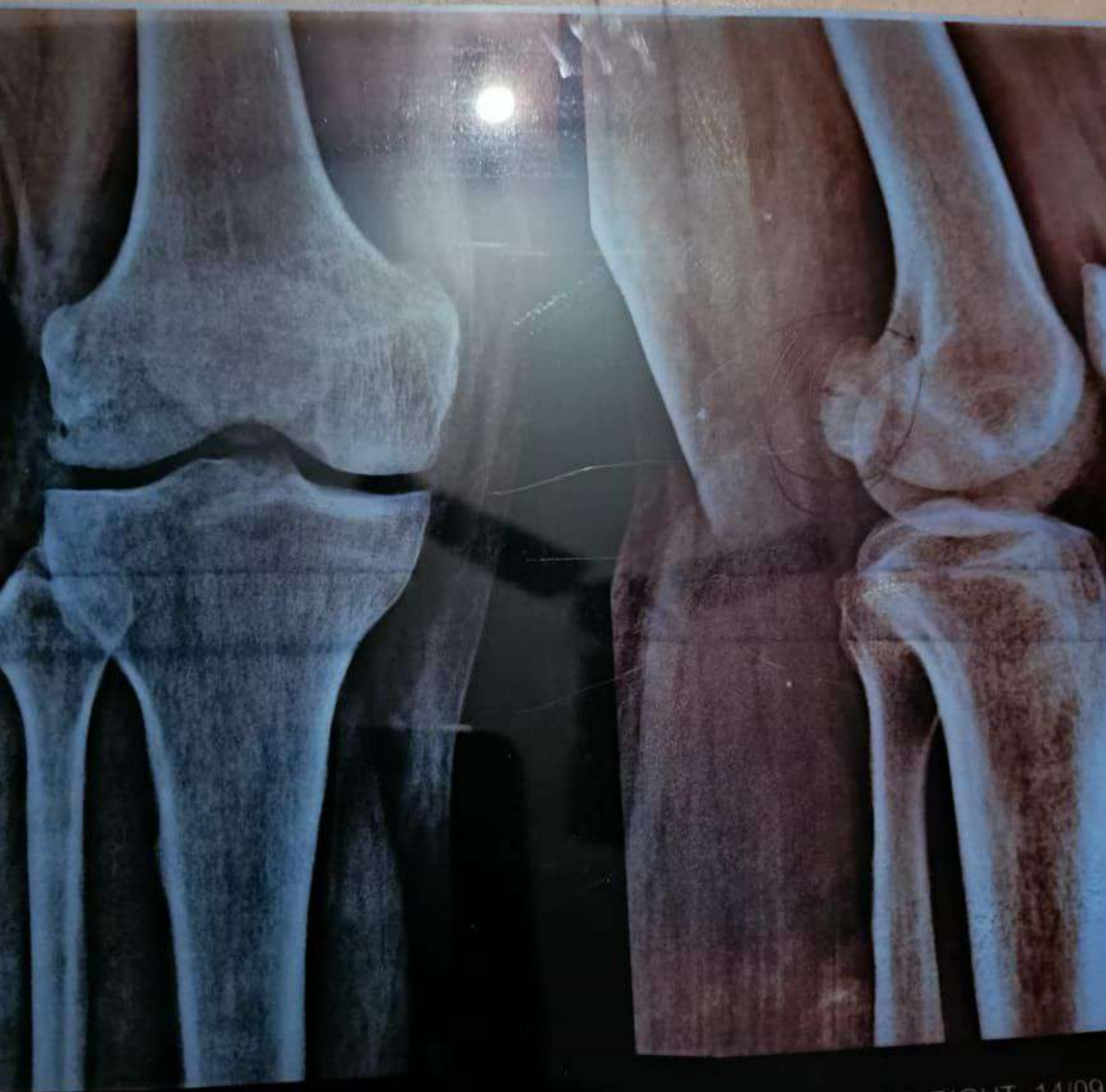3D

est.

RT

hms Jh.

[Signature]



23091465915 MR KALE SINGH 60 YEAR M KNEE AP LAT RIGHT 14/09
DR RAJENDRA SINGH INDIRAJ ORTHOPAEDIC CENTRE, JOYA ROAD AM



TMU HOSPITAL

(A Hospital of Teerthanker Mahaveer Medical College & Research Centre)
Delhi Road, Moradabad-244001 (U.P.)

Tel : 0591-2476816
: 0591-2360777
URL : www.tmu.ac.in

DEPARTMENT OF RADIOLOGY

Patient Name	MR. KALE SINGH		RIS No	1009386
UHID/IP No	310250061		Order Date	
Age/Gender	60 Yrs/Male		Ackn. Date	25/10/2023 10:39AM
Bed No/Ward	OPD		Report Date	27/10/2023 9:42AM
Referred By	Dr. GENERAL MEDICINE UNIT 3		Report Status	
Manual Lab No			Report Revised	N

RADIOLOGY - MRI

MRI OF THE RIGHT KNEE WITHOUT CONTRAST.

TECHNIQUE: Axial, coronal, and sagittal images of the right knee were obtained on a 1.5 Tesla magnet.
COMPARISON: None.

FINDINGS:

Fluid: Moderate joint effusion extending to parafemoral recess and suprapatellar recess.

MEDIAL COMPARTMENT:

- Medial meniscus: Grade-II signal in posterior horn and body of medial meniscus.
- Medial collateral ligament: Grade-I sprain.
- Medial femoral condyle: Mild marrow edema is seen. Osteophyte lipping is seen.
- Medial tibial plateau cartilage: Osteophyte lipping is seen.

LATERAL COMPARTMENT:

- Lateral meniscus: Grade-I signal in anterior horn, posterior horn and body of lateral meniscus.
- Lateral collateral ligament: Grade-II sprain at femoral attachment site.
- Lateral femoral condyle: Mildly displaced fracture of lateral femoral condyle. Osteophytes are seen.
- Lateral tibial plateau cartilage: Osteophyte lipping is seen. Mild marrow edema is seen.

POSTEROLATERAL CORNER:

- Popliteus tendon: Partial tear of popliteus tendon at femoral attachment site. Grade -I sprain of popliteus muscle.
- Popliteofibular ligament: Mild sprain.
- Mild sprain of anterolateral ligament.
- Proximal tibiofibular joint: Osteophyte lipping is seen in lateral femoral condyle and fibular head. Mild marrow edema is seen in fibular head.

ANTERIOR COMPARTMENT:

- Alignment: Normal.
- Quadriceps tendon: PDFS hyperintensity is seen at patellar attachment site - Mild tendinosis.
- Patellar tendon: PDFS hyperintensity is seen at patellar attachment site - Mild tendinosis.
- RETINACULUM: Medial - Grade -I sprain. Lateral - Normal.
- PATELLA: Small T2W hypointense linear signal is seen in anterior aspect of patella - possibility of small fracture in anterior aspect of patella.
- TROCHLEA: Normal.
- Plica: Mildly edematous infrapatellar plica. Hoffa fat pad: Mild edema is seen.

INTERCONDYLAR COMPARTMENT:

- Anterior cruciate ligament: PDFS hyperintensity is seen in anterior cruciate ligament - Grade -I sprain.
- Mild tendinosis involving biceps femoris tendon.
- Posterior cruciate ligament: Normal.
- Vessels: Normal.

TECHNOLOGIST

RESIDENT

RADIOLOGIST



Panacea Hospital & Research Center

An NABH Accredited Multi Speciality Hospital
Next to LSA (school), Amroha-Jaya Road, Amroha - 244 221
Mob: 7088 808 000, 7617 564 028 www.panaceaamroha.com, phrcamro@gmail.com



Name	MR KALE SINGH	Department of Radiology	Patient ID	14740
Accession No	190823		Age/Gender	60YR / Male
Referred By	Dr.CHITRAK BANSAL		Date	19-Aug-2023 00:00:00

NCCT KNEE 3D RT

FINDINGS:

- There is transarticular fracture of lateral femoral condyle with fracture fragments in joint space .
- Moderate joint lipoarthrosis is seen .
- Soft tissue injury with edema is seen in adjacent myofascial planes and subcutaneous plane

The upper end of tibia and fibula appears normal
No lytic or sclerotic lesion is seen.
Rest muscle and soft tissue appears normal
The patella appears normal

IMPRESSION:

- Transarticular fracture of lateral femoral condyle with fracture fragments in joint space
- Moderate joint lipoarthrosis
- Soft tissue injury with edema in adjacent myofascial planes and subcutaneous plane

Suggested clinical and MRI correlation

Dr. Bijendar Kumar , MD
Consultant Radiologist
Reg-No-RMC-029357

ANAMIKA MEDICOSINDIRAJ ORTHOPAEDIC CENTRE, JOYA
ROAD, AMROHA
9719521066

Patient Name : KALE SINGH

Patient Address :

Dr Name :

Pr Reg No.

GSTIN : 09CGUPS7723L2Z9

Licence No : UP23290000063, UP23210000063

Invoice No. : A011434 Date: 22/08/2023

BILL OF SUPPLY

SN.	PRODUCT NAME	PACK	HSN	BATCH	EXP.	QTY	MRP	RATE	SGST	CGST	AMOUNT
1	LUPIPAN-L	10'S	OTHERS	GC230258	10/24	0.7	315.10	315.10	0.00	0.00	221.27
2	NUCICAL XT	15'S	3004	LTA-33128	9/24	0.7	345.00	345.00	0.00	0.00	161.00
3	RITAFAR-SG	10'S	3004	VSG-318	7/24	0.7	198.00	198.00	0.00	0.00	138.60
4	STEFURE LZ 600	10'S	3004	KLE2205A	5/25	1.4	410.80	410.80	0.00	0.00	575.12

GST 986.39*0%=0SGST, CALZsdMETHI** GET WELL SOON **

Terms & Conditions

SUB TOTAL	1095.99
Discount 10 %	109.60
Roundoff	0.39

For ANAMIKA MEDICOS

Remark :

Rs. Nine Hundred Eighty Six Only

Authorised Signatory

GRAND TOTAL 986.00

सामुदायिक स्वास्थ्य केन्द्र अमरोहा

छोटा परिवार



सुखी परिवार

जनपद - अमरोहा

पंजीकरण सं०

117463



रोगी का नाम

Handwritten name

आयु

60

रोग

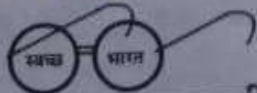वाह्य कक्ष सं०

नोट : केवल 15 दिन तक के लिए मान्य है।

दिनांक	लक्षण तथा उपचार
27/9	<p>Severe Pain (R) Knee joint</p> <p>Joint Body part</p>
Widened (R) (L) (R) (L)	
Act on (R) Knee joint	<p>Handwritten notes and diagrams</p>
Completed Bed rest for 2 wks	
joined	

Dr. Mohd. Javed
MEDICAL OFFICER
C.H.C. Amroha Dist. Amroha
Regd. No. 2300

खुले में शौच न करें। शौचालय का प्रयोग करें।



एक कदम स्वच्छता की ओर



TMU HOSPITAL

(A Hospital of Teerthanker Mahaveer Medical College & Research Centre)

Delhi Road, Moradabad-244001 (U.P.)

Tel : 0591-2476816
: 0591-2360777
URL : www.tmu.ac.in

DEPARTMENT OF RADIOLOGY



NQAS

जिला संयुक्त चिकित्सालय, अमरोहा



पंजीकरण संख्या 193046 वाह्य रोगी टिकट दिनांक 28/10
 रोगी का नाम काली देवी आयु 60 लिंग M
 पता

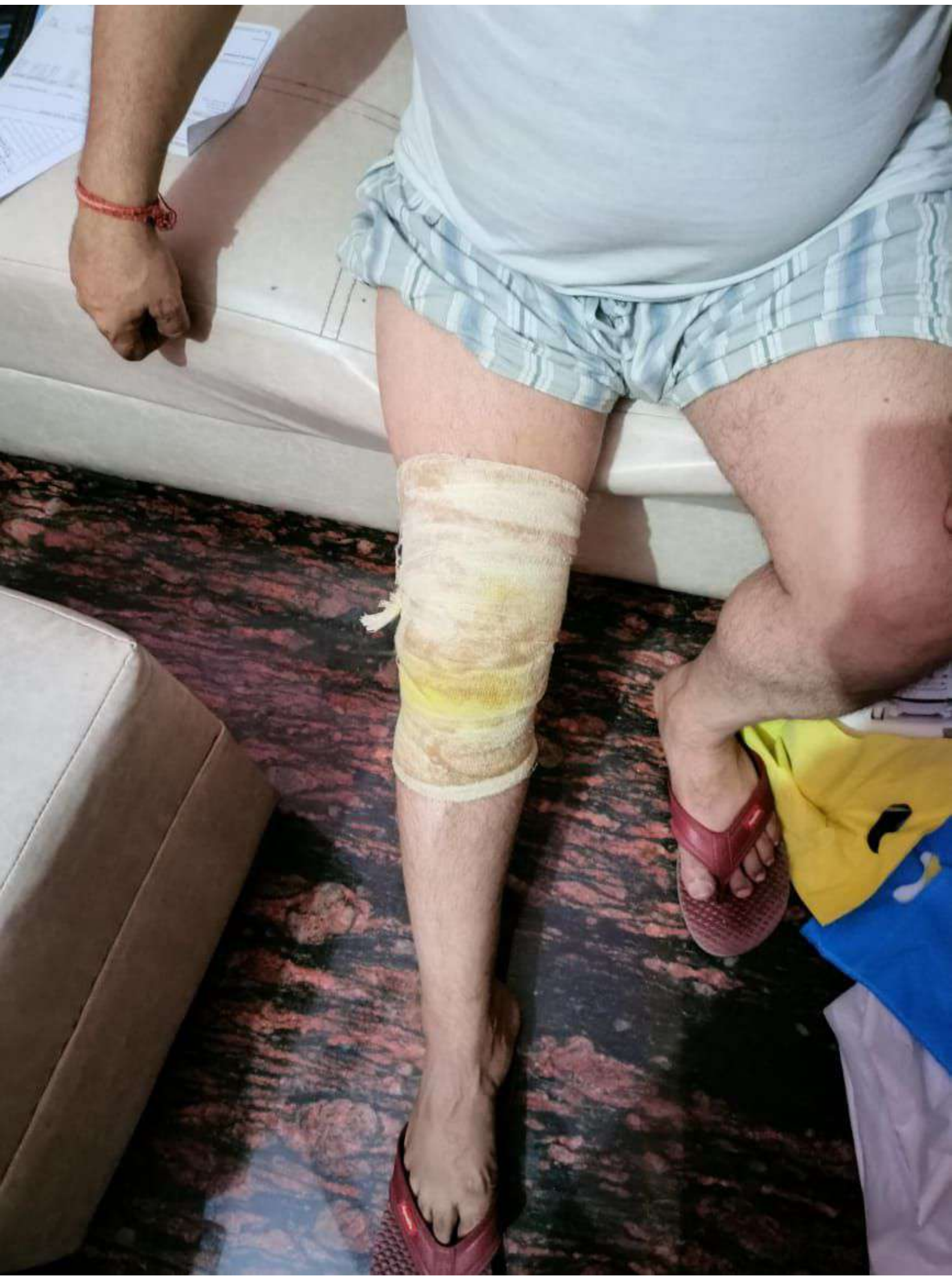दिनांक	लक्षण तथा उपचार
--------	-----------------

Handwritten notes in the table:
 1. 28/10
 2. 29/10
 3. 30/10
 4. 31/10
 5. 01/11
 6. 02/11
 7. 03/11
 8. 04/11
 9. 05/11
 10. 06/11
 11. 07/11
 12. 08/11
 13. 09/11
 14. 10/11
 15. 11/11
 16. 12/11
 17. 13/11
 18. 14/11
 19. 15/11
 20. 16/11
 21. 17/11
 22. 18/11
 23. 19/11
 24. 20/11
 25. 21/11
 26. 22/11
 27. 23/11
 28. 24/11
 29. 25/11
 30. 26/11
 31. 27/11
 32. 28/11
 33. 29/11
 34. 30/11
 35. 01/12
 36. 02/12
 37. 03/12
 38. 04/12
 39. 05/12
 40. 06/12
 41. 07/12
 42. 08/12
 43. 09/12
 44. 10/12
 45. 11/12
 46. 12/12
 47. 13/12
 48. 14/12
 49. 15/12
 50. 16/12
 51. 17/12
 52. 18/12
 53. 19/12
 54. 20/12
 55. 21/12
 56. 22/12
 57. 23/12
 58. 24/12
 59. 25/12
 60. 26/12
 61. 27/12
 62. 28/12
 63. 29/12
 64. 30/12
 65. 31/12



पर्चा शुल्क
 1/- रु०
 मान्य
 15 दिन तक

हम आपके शीघ्र स्वस्थ होने की कामना करते हैं ।





Regd. No. UP04337A

INDIRA J ORTHOPAEDIC CENTRE

Joya Road, Amroha, Ph.: 05922-252566

MEDICAL CERTIFICATE

(Not For Medico Legal Purpose)

Sr. No.: 076

Patient Name: Mr. Kala Singh Age / Sex: 60yrs / male

Address: Amroha Dist. G.P.D. 19/08/23

Diagnosis: Fracture femur Date of Injury: 19/08/23

Date of Admission: 19/08/23 Date of Discharge: 26/09/23

Adv. Rest From: 19/08/23 to: 26/09/23

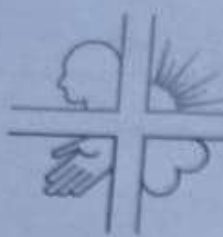
Fitness From: 27/09/2023

DR. RAJENDRA SIKCHI
M.S. (ORTHO)
INDIRA J ORTHOPAEDIC CENTRE
AMROHA

Sig. of Doctor

Sig. of Patient

(Handwritten signature)



PANACEA HOSPITAL & RESEARCH CENTER

An NABH Accredited Multi Speciality Hospital
(Run By L.S.A Society), Next to LSA School,
Amroha Jeya Road, Amroha-244221
Contacts- 70888 08000, 7617564028,
www.panaceeamroha.com,
phreamro@gmail.com

OPD INVOICE

INV NO.: 14740
DATE: 2023-08-19 11:25:51
CASH BILL



MR KALE SINGH (14740) Age & Sex : 60Y/M / UHID No:	Referred By : DR CHITRAK BANSAL Address : AMROHA , Mobile Number : 9319396563
--	--

SN	Description	Qty	Unit	Total
1	HC199 - NCCT KNEE JOINT WITH 3D SINGLE	1	NOS	3500.00
Sub Total				3500.00
Discount Amount				1000.00
Total After Discount				2500
Total				2500.00

Rupees Two Thousand Five Hundred Only

Total Items : 1

Remarks : DIS BY FARHAN SIR

1. Please inform the reception counter if there is any discrepancy in this bill.
2. All claims related to bill have to be sorted out immediately and the same will not be taken for consideration if there is any delay.

[Signature]
Authorised Sign