



Patient Name	Bharti Jha	Requested By	Dr. Anshuman Kumar
MRN	15050000108737	Procedure DateTime	2021-10-04 17:27:14
Age/Sex	37Y 9M/Female	Hospital	NH-Dharamshila

Inv. No. 2016

MRI BOTH BREASTS

Technique : MRI Both Breasts done on 1.5 Tesla.

Sequences taken : Axial T1 & T2 / coronal / sagittal / Post-contrast dynamic T1 / diffusion.

Report:

Bilateral breast composition is predominantly fatty with scattered areas of fibroglandular tissue.

Mild bilateral background enhancement pattern seen.

Few thin walled cysts are seen in bilateral breasts, mostly in retroareolar region, the largest on the right is ~2.2 cm & on the left is ~1.0 cm.

A 4 mm focal enhancement is seen in the right upper outer quadrant, without diffusion restriction and a type I enhancement curve.

Skin and nipple areolar complex is normal.

No ductal dilatation is seen.

No significant axillary lymphadenopathy seen.

Impression: Bilateral cystic lesions

Small enhancing focus right upper outer quadrant

BIRADS III.

MRI BIRADS Category :

0. Need Additional Imaging Evaluation or Prior Mammograms for comparison.
1. Negative - There is nothing to comment on.
2. Benign finding.
3. **Probably benign finding (<2% malignant). Initial Short Interval Follow Up Suggested.**
4. **Suspicious Abnormality (2 - 95 % malignant). Biopsy Should Be Considered.**





5. Highly Suggestive of Malignancy (> 95 % malignant). Appropriate Action Should be taken.

6. Known Biopsy-proven malignancy.

Anjana

Dr. ANJANA CHANDRA
MBBS MD (Radiodiagnosis)
SR. CONSULTANT RADIOLOGIST





DEPARTMENT OF RADIO-DIAGNOSIS

Jawaharlal Nehru Medical College & Hospital

Aligarh Muslim University, Aligarh

IMAGING REPORT

Patient Name: BHARTI JHA
ID: MAS

AGE/SEX: 38(Y)/F
DATE-29.09.2021

General Information:

- * Sensitivity of mammography goes down if the breasts have dense parenchyma.
- * Screening mammography is advisable for all women above the age of 40 yrs.

Clinical profile : C/O bloody nipple discharge from right breast

MAMMOGRAPHY

Mammography of B/L breast in Cranio-caudal and Medio-lateral oblique view.

Shows generalized fatty density of B/L breast with increase in density in B/L axillary tail (upper outer quadrant) ,however no evidence of any calcification noted. Underlying pectoralis muscle appears normal. Coopers ligament appears normal. Skin and nipple appears normal.

Shows no significant lymphadenopathy.

(Due to bulky breast tissue suboptimal mammography)

ON USG SCREENING

Most of the B/L breasts appears fatty with mildly prominent fibro-glandular tissue located near B/L axillary tail region with few simple cysts within the tissue on B/L side (largest size of simple cyst~12x18mm in right breast at 7-8 'o clock position slightly towards right axillary tail) with few adjacent focally dilated terminal ductules appears to be opening into the cysts.

There is no evidence of any internal septations, debris ,fluid level or internal echoes within the cysts to suggest complexity.

Overlying skin and subcutaneous tissue appear normal. Underlying pectoralis muscle appears normal. No evidence of focal or diffuse mass lesion seen.

No significant lymphadenopathy noted in B/L axillae.

IMPRESSION: Findings are suggestive of few simple cysts with adjacent focally dilated terminal ductules in B/L breast (R>>L) as described.

....BIRADS III lesion
Adv : short term follow up (~3month)


Dr. SAYEMA
(SR,RADIODIAGNOSIS)

MITTAL

COLOUR DOPPLER ULTRASOUND, MAMMOGRAPHY
ECHOCARDIOGRAPHY, O.P.G., DIGITAL X-RAY SCAN CENTRE

Dr. Sunil K. Mittal

D. Ortho, M.D. (Radio-Diagnosis)

Radiologist & Ultrasonologist

A-12, PAWAN PALACE, NEAR TIKARAM MANDIR, SAMAD ROAD, ALIGARH - 202 001

Phones : Clinic - 2508989 • Resi. -2508585 27/9/21

Mrs. Bharti Jha 37yrs

Female

(Sono-mammography)

USG Findings-

No mass lesion is seen.

No architextural distortion is seen.

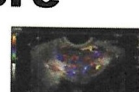
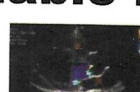
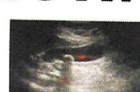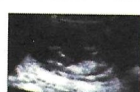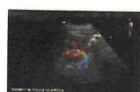
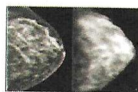No calcification is seen.

No lymphadenopathy is seen.

Rt breast shows two 16x13mm, 14x7mm size cysts in lower outer quadrant.

Adv-Ductography.

CT & MRI Facility Are Available Here



• COLOUR DOPPLER

• 4'D ULTRASOUND

• ULTRASOUND

• MAMMOGRAPHY

• ECHO CARDIOGRAPHY

• X-RAY

THIS IS A PROFESSIONAL OPINION NOT A DIAGNOSIS. IT NEEDS CLINICAL CORRELATION. REPORT IS NOT VALID FOR MEDICO-LEGAL PURPOSE.



Dharamshila Narayana
Superspeciality Hospital

Toll Free

1800-309-0309



A Unit of Dharamshila Cancer Foundation and Research Centre

KINDLY FIX UP APPOINTMENT

OPD BOOK

(TO BE RETAINED BY THE PATIENT)

TPA.....CORP PVT

MRN 15050000108737
(MRN is a very important identification for Hospital Records. Kindly remember.)

Name Mrs. Bharti Jha Age 37 Sex F

Father/Husband/Guardian's Name Mohesh Chandra Nandi Jha

Address Word no-28, Bilas Town, Deoghar,
Jharkhand, 814112

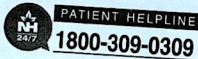Mobile No. 8318612829 Alternative No. 7355325763

Residence

Consultant's Name Dr. Anshuman Kumar Date of Registration 04/10/21

Diagnosis

Please Bring This Book with You
अस्पताल आते समय इस किताब को साथ लाएं।



Dharamshila Narayana Superspeciality Hospital

A Unit of Dharamshila Cancer Foundation and Research Centre

Dharamshila Marg, Vasundhara Enclave, Near New Ashok Nagar Metro Station, Delhi 110 096

India's First NABH Accredited Cancer Hospital | Laboratory Services Accredited by NABL

F/FO/01-37 Rev :11

Date :	Patient Name :	Age / Sex :
CR. No.:		Weight : (Kg)
Investigations	Diagnosis :	
	Treatment :	
<u>04/11/21</u>	<u>S/S of Asthma</u> <u>100ml</u>	
	Hx (L): Nipple discharge Slight episode	
	(O/E): ? duct ectasia fibrosytic discal	
	Adv	
	- (R/L) Breast MRI c contrast	
	- review c report	
	[Signature]	

