

**Dr. Anita Gupta**

Associate Director- Obstetrics & Gynecology  
 MBBS, MD (Obstetrics & Gynecology)  
 DMC No.: 4442  
 Contact:- 9811096139  
 Email to:- ashokanita@gmail.com  
 anita.gupta@fortislafemme.in

**Fortis La femme**

S-549, Greater Kailash Part 2, New Delhi-110048  
 Tel: 011-40579400, Fax No.: 011-41436103  
 Emergency: 011-41436385, Ambulance: 105010  
 Email: contactus.ff@fortislafemme.in  
 Website: www.fortishealthcare.com

(3)

Name : Taru Priya Jaiswal BP : 112/76 Pulse : \_\_\_\_\_  
 Age : 31 years Sex : female Weight : 75 kg Temperature : \_\_\_\_\_  
 UHID : 127 91604 Date : 21/12/23 Allergies : \_\_\_\_\_

**Presenting Complaints:-**

Hc<sup>+</sup> Endometrioma + multiple fibroids  
 + (R) sided Hydro salpinx. @ Hb

**Menstrual History:-**

LMP: 12/11/23

U/S. 19/12/23.

**EDD:**

**Cycles:**

**Obstetric History:-**

GPAL

POAO

**Family History:-**

**Personal History:-**

**Examination:-**

P/S

P/V

uterus enlarged. @ multiple  
 fibroids  
 50 x 49 x 50 mm  
 32 x 25 mm  
 25 x 24 mm  
 27 x 27 mm  
 (R) Or. 2 complex  
 cysts < 26 x 25 mm  
 26 x 21 mm  
 (C) Or. 31 x 31 mm complex  
 cyst.  
 (R) sided. 54 x 20 mm  
 Hydro salpinx.

P/A v. slight tenderness in

(R) iliac fossa.

18/12/23  
 CA 19.9 ↓ 1ug  
 CA -125 83.3 ↓ 1ug  
 Hb 110.  
 8.7.8mg ↑ 1ug

**Follow up date:-**

Regular Follow up every 7-10 days x 2 months

**Investigations:-**

(I) Salpingectomy

↓  
 on vilanno. B3  
 since 12/11/23

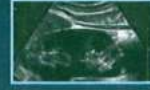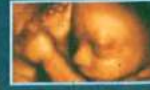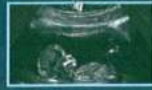**Advice:-**

- (I) Continue VISANNE 2mg twice daily x 2 months
- (II) Continue SHELCEL-HD twice daily x 2 months
- (III) Continue WRILE-D3 60 once in 15 days x 2 months
- (IV) Continue OROFER-100 x 2 months

Dr. Anita Gupta  
 Associate Director  
 Obstetrics & Gynaecology  
 Fortis LaFemme Hospital  
 S-549, GK-II, New Delhi  
 DMC Regn. No.-4442

**Consultant Signature and stamp**

Anita Gupta



DATE ----- 19.12.23  
NAME----- TANUPRIYA.  
AGE/SEX----- F  
REFD.BY----- DR.ANITA GUPTA.  
INVESTIGATION----- PELVIC SCAN..TVS/ TAS

Uterus is AV – Enlarged in size. Wall asymmetry present .  
Contour is irregular and myometrial echoes are heterogenous.  
Multiple intramural fibroids present ..FIGO 3, 4 and 5 in classification.  
Fibromyoma causing mild anterior displacement of endometrial echo.  
Various sizes are ..56x49x50mm..vol..70cc, 32x25mm,25x24mm and 27x27mm in posterior , anterior and left lateral walls.  
Cervix and cervical canal --- appear normal in texture.  
Endometrial echoes are seen and the cavity is empty. ET is 8mms.

Rt.ovary has two complex cysts..26x25mms and 26x24mms ...with lowlevel internal echoes .  
Lt.ovary has a 31x31mm complex cystic mass with ground glass appearance  
Rt.sided dilated tubular lesion is noted in rt.adnexa favouring dilated fallopian tube..54x20mms  
.....Hydrosalpinx.  
Sliding sign Absent .. Deep Infiltrating Endometriosis.  
Color score is 1 ..no internal vascularity.  
Cul-de-sac has no free fluid.  
Urinary Bladder has smooth wall of normal thickness and does not show any space occupying lesion or a calculus .

**IMPRESSION:: -**  
**MULTIPLE FIBROMYOMAS UTERUS.**  
**DEEP INFILTRATING ENDOMETRIOSIS.**  
**COMPLEX CYSTIC MASSES BOTH ADNEXAE WITH GROUND GLASS APPEARANCE AND NO**  
**VASCULARITY – S/O ENDOMETRIOSIS BOTH OVARIES AND RT. FALLOPIAN TUBES.**

**Note :** This is a routine obstetrical ultrasound, mainly done for estimation of gestational age, amount of liquor, placental position and general well being of the fetus & not for the evaluation of all congenital anomalies. Moreover, the anomalies in relation to fetal heart and limbs are extremely difficult due to constantly changing position of the fetus & overlapping of its various parts. The Detection of Fetal Anomalies is Dependent on Fetal Position, Amount of Liquor, Gestational age of Fetus & the Maternal Abdominal Wall Thickness, Hence a Normal Scan Does not necessarily mean a congenitally Normal Fetus.

**THIS IS A PROFESSIONAL OPINION NOT THE FINAL DIAGNOSIS. THIS SHOULD BE INTERPRETED IN THE LIGHT OF CLINICAL BACKGROUND.**







**Dr. Anita Gupta**

Associate Director- Obstetrics & Gynecology  
 MBBS, MD (Obstetrics & Gynecology)  
 DMC No.:- 4442  
 Contact:- 9811096139 ✓  
 Email to:- ashokanita@gmail.com  
 anita.gupta@fortislafemme.in

**Fortis La femme**

S-549, Greater Kailash Part 2, New Delhi-110048  
 Tel: 011-40579400, Fax No.: 011-41436103  
 Emergency: 011-41436385, Ambulance: 105010  
 Email: contactus.fff@fortislafemme.in  
 Website: www.fortishealthcare.com

Name: Tanupriya Jaiswal BP: 125/78 Pulse: \_\_\_\_\_  
 Age: 31yo Sex: Female Weight: 74.4 kg Temperature: \_\_\_\_\_  
 UHID: 12791624 Date: 18/12/23 Allergies: \_\_\_\_\_

**Presenting Complaints:-**

Mc Endometriosis + Adenomyoma + Multiple fibroids  
 On VISANNE for last 36 days. 40 Irregular spotting Plv still (2mg) BD (+)  
 40. Pain in knees weakness.

**Menstrual History:-**

LMP: 12/11/23.  
 EDD: X 15 day / taken -20. Tranexa.  
 Cycles: started Visanne BD.

Pain abdomen ↓

**Obstetric History:-**

G P A L

Po Ao .

**Family History:-**

**Personal History:-**

**Examination:-**

P/S  
 P/V

**Follow up date:-**

Renew with reports

**Investigations:-**

July '23 Hb reduced post surgery.  
 CA 19.9 128. Trend  
 CA 125 182. Trend  
 Advice:- Hb 7-9 g/dl.

- ① US Pelvis CTUS
- ② CA-125 S. VD.
- CA 19.9 S. Calcium.
- ESR
- CBC

*Anita Gupta*

**Dr. Anita Gupta**  
 Associate Director  
 Obstetrics & Gynaecology  
 Fortis LaFemme Hospital  
 S-549, GK-II, New Delhi  
 DMC Regn. No.-4442

Consultant Signature and stamp



**Dr. Anita Gupta**

Associate Director- Obstetrics & Gynaecology  
MBBS, MS (Obstetrics & Gynaecology)  
DMC No.: 4442  
Contact:- 9811096139, 9560488202  
Email to:- anitagupta.gynae@gmail.com  
anita.gupta@fortislafemme.in

PAGE - 1

**Fortis La femme**

S-549, Greater Kailash Part 2, New Delhi-110048  
Tel: 011-40579400, Fax No.: 011-41436103  
Emergency: 011-41436385, Ambulance: 105010  
Email: contactus.flf@fortislafemme.in  
Website: www.fortishealthcare.com

Name: Tanu Priya Jaiswal BP: 115/74 Pulse: \_\_\_\_\_  
Age: 31 years Sex: female Weight: 73.3 kg Temperature: \_\_\_\_\_  
UHID: 12791604 Date: 28/10/23 Allergies: \_\_\_\_\_

**Presenting Complaints:-**

40. lower abdomen, ↑ during menses  
lower backache.

H/O. Laparoscopy for Endometriosis, Adenomyosis  
& Hydrocolpion  
① Salpingectomy done.

**Menstrual History:-**

LMP: 16/10/23  
EDD:  
Cycles: 3-4  
30 days reg, ↑ flow pain.

in utero 2021.

**Obstetric History:-**

GPAL  
POAO. → IVF Tried twice.

MRI  
16/8/23

uterus 11.6x 7.4x 9.2  
cm.

**Personal History:-**

**Family History:-**

Present day

7 4 mths

**Investigations:-**

① Tab UPRISE-D3-60 Once in 15 days  
② Tab SHELICAL-HD twice daily  
after food

6.2x5.

B/L con

From 1st day of menses.

largest. ② adeno

① Tab TRANEXA-MF  
twice daily x 5 days  
after food.

① leni 2x2-14.

② Tab VISANNE (or) ENDOREG  
(2mg) twice daily. x 3 mths.

**Dr. Anita Gupta**  
Associate Director  
Obstetrics & Gynaecology  
Fortis La Femme Hospital  
S-549, Greater Kailash Part 2, New Delhi  
DMC Reg. No. 4442

③ Renew after 2 mths  
1 mths

Self Attested  
Anita Gupta  
22/12/23

**Follow up date:-**

Consultant Signature and stamp



**BILL OF SUPPLY**

Original Invoice

Ill No. :	GHOPBL/25657698	Bill Date :	24/08/2023 16:17
atient ID :	MM02606705	OPD No. :	20438894/1
ender / Age :	Female / 31Y 1M 30D	Visit Date :	24/08/2023 16:17
atient Name :	Tanu Priya Jaiswal	Consulting Doctor :	Dr Dimple K Ahluwalia
atient Address :		Patient Phone :	917007208080
linic :	Gyn & Gyn Onc	Bing Group / Corporate :	CASH PAYMENT
AC CODE :	9993	Patient DOB :	25/06/1992
mployer :			

	HSN/SAC Code	Qty	Total
<b>Minimum Charges</b>			
onsult Visit Charges			
JVC000086-First Consultation Charges	999312	1.00	1200.00
<b>Total</b>			1200.00
<b>Net Payable</b>			1200.00
<b>Receipt</b>			1200.00
GHOPRC/24177796/24/08/2023 16:17(By Cash)			1200.00
<b>Bill Outstanding</b>			0.00

BILL AMOUNT:

NR One Thousand Two Hundred And Paise Zero Only

PREPARED BY

Esha Parwar

Medanta-The Medicity

Disclaimer: Electronic mode of payment options are prominently displayed &amp; offered to the customer against this invoice.

*Self Attested @ 22/12/23*

Accredited by



Certificate No. CN-3528/21

Certificate No. H-2011-0075

For Emergency &amp; Ambulance: Dial @ 1068

 Medanta - Gurugram  
 3/2023 16:18  
 Sector - 26, Gurugram  
 1220024

Medanta - Medicity, Delhi

 E-Block, Sector - 15, Delhi  
 110028

Medanta - Medicity Cybercity

 110 Floor, Building 10C, DLF Cybercity, Gurugram  
 1220024

Medanta - Medicity Sulajh Chauri

 743P Sector - 39, Near Subhash Chandra Gurugram  
 1220024

[info@medanta.org](mailto:info@medanta.org)
[www.medanta.org](http://www.medanta.org)

Corporate Identity Number - LB5110DL2004\* 128319

Medanta Network: Gurugram | Delhi | Lucknow | Patna | Indore | Ranchi | Noida



Initial Assessment

<b>Patient ID</b>	: MM02606705	<b>Patient Name</b>	: Tanu Priya Jaiswal
<b>Gender</b>	: Female	<b>Age</b>	: 31Y
<b>Encounter ID</b>	: 204388940001	<b>Encounter Type</b>	: Outpatient
<b>Visit Date</b>	: 24/08/2023 16:17	<b>Location</b>	: Gynaecology & Gynaec Oncology
<b>Specialty</b>	: Gynaecology & Gynaec Oncology	<b>Attending Practitioner</b>	: Dr Dimple K Ahluwalia

<b>Note Type</b>	: OP Initial Assessment_Adult	<b>Med/Anc Service</b>	: Gyn & Gyn Onc
<b>Date / Time</b>	: 24/08/2023 16:21	<b>Performed By</b>	: Munduina Ruangmei

**OP Initial Assessment Adult**

Height	:	161 cm
Weight	:	73.5 kgs
BMI	:	28.4 Kg/m <sup>2</sup>
<b>Vitals Signs</b>		
Pulse	:	85 /min
Respiratory Rate	:	22 /min
Systolic BP	:	113 mm/Hg
Diastolic BP	:	68 mm/Hg
<b>Pain Assessment</b>		
Pain Scale	:	No Hurt (Score - 0)
Pain Score	:	0

For FLACC or Wong Baker: If pain scale score is  $\geq 4$  inform doctor & fill pain details below

**FALL RISK SCREENING: (IF ANY OF THIS IS YES, PATIENT IS AT HIGH RISK FOR FALL)**

**Reason-**

History of fall in last year	:	No
Unsteady or slow gait	:	No
Ambulatory aid	:	No
Abnormal mental status	:	No
Elderly (>65 Years)	:	No
Impaired sight	:	Yes
Loss of balance	:	No
Polypharmacy (>5 drugs)	:	No

*Self Attended @ 22/12/23*

Patient has high risk for fall, educated the patient & family on fall prevention interventions as follows:

Always escort the patient (If patient alone, wheelchair assistance provided)	:	Yes
Do not place the patient on examination table without 1:1 attendance	:	Yes
Assist patient in getting on/down from examination table	:	Yes
Toilet the patient regularly, especially before a procedure	:	Yes
Instruct the patient to use emergency call bell in restrooms, if needed	:	Yes
Safety belt to be applied when using wheel chair	:	Yes



<b>Patient ID</b>	: MM02606705	<b>Patient Name</b>	: Tanu Priya Jaiswal
<b>Gender</b>	: Female	<b>Age</b>	: 31Y
<b>Encounter ID</b>	: 204388940001	<b>Encounter Type</b>	: Outpatient
<b>Visit Date</b>	: 24/08/2023 16:17	<b>Location</b>	: Gynaecology & Gynaec Oncology
<b>Specialty</b>	: Gynaecology & Gynaec Oncology	<b>Attending Practitioner</b>	: Dr Dimple K Ahluwalia

Avoid sitting on chairs with wheels : Yes  
 Be careful of your environment to avoid tripping on furniture : Yes  
**NUTRITIONAL SCREENING**  
 Weight change >3 kg in past 3 months: : No  
 Acute illness with very less food intake for >5 days: : No  
 Diagnosed : None,  
**Social History**  
 Tobacco : No  
 Alcohol : No  
 Drug Use : No  
 Spiritual/ Cultural need : No  
**Psychological Assessment**  
 Psychological Assessment :  
**Functional Assessment**  
 Functional Assessment : Normal  
 Completed by Staff Nurse: : Independent  
 Date and Time : munduina  
 : 24/08/2023 16:23


*Self Attended*  
*[Signature]*  
 22/12/23







2 12월 4일 412



[The main body of the page contains extremely dense, illegible text, likely a scan of a document with very small font or significant noise. The text is arranged in multiple columns and is not readable.]



<b>Patient Name:</b> Tanu Priya Jaiswal	<b>Location:</b> MAX SUPER SPECIALITY HOSPITAL - PATPARGANJ
<b>Age/Sex:</b> 31/F	<b>IP No.:</b> <b>Admission Type:</b> OutPatient
<b>Max ID:</b> SKCT.0378925	<b>Order Date:</b> 16-AUG-2023
<b>Ref. Doctor:</b> Vivek Marwah	<b>Report Date:</b> 16-AUG-2023 05:04 PM

**MRI Peivis/Lower Abdomen (C ) of 16-AUG-2023:**

**Results:** *Multipolar MR images of the lower abdomen were obtained using T1, T2 weighted TSE SPIR sequences. T1 sequences were repeated after intravenous contrast administration.*

Urinary bladder is normal in size and shape.

Uterus is enlarged in size ~11.6 (CC) x 7.4 (AP) x 9.0cm (Width) with normal outline. There are multiple well defined T2 hypointense lesions suggesting fibroids, largest measuring ~3.0 x 2.7cm in size in the left lateral wall. There is diffuse thickening of the junctional zone in posterior myometrium with ill defined hypointense lesion with moderate enhancement measuring approximately 6.2x5.1 cm in size showing multiple small cystic foci (hyperintense on T1 / T2W images) in the posterior myometrium. Findings are suggestive of multiple uterine fibroids with adenomyoma /adenomyosis involving the posterior wall of uterus. The lesion causing mild compression and anterior displacement of the endometrial cavity.

There is grossly dilated tortuous tubular structure is seen in the right adnexal region suggesting right sided hydrosalpinx.

There are complex cystic lesions in bilateral adnexal region appearing hyperintense on T1W images and showing dependant T2 shading, angular margins and few thin septations suggestive of hemorrhagic cysts / chocolate cysts. The larger right adnexal lesion measures approximately 6.0 x 3.5 cm and small left adnexal lesion measures approximately 3.0 x 2.1 cm.

*Small amount of loculated fluid is seen at places in pelvis with possibility of adhesions*

*There is also focal effacement of fat planes between the sigmoid colon/rectosigmoid and the right adnexal lesion in the lower abdomen with minimal thickening of the inferior peritoneal reflection.*

The visualized bowel loops are otherwise normal.

No significant pelvic / inguinal lymphadenopathy is seen.

**IMPRESSION:** Findings are suggestive of bilateral endometriomas with right sided hydrosalpinx with multiple uterine fibroids and possibility of uterine adenomyosis/ adenomyoma as described.

*Clinical correlation is suggested.*



**Dr. Bhuvnesh Guglani**  
Principal Consultant

*Self Attested*  
*@*  
*22/12/23*

Report Approved / Verified Date & Time: 16-AUG-2023 05:04 PM





**MAX**

Institute of Laparoscopic,  
Endoscopic & Bariatric Surgery

SRU-57814

**Dr. Vivek Marwah**  
MS (Obstetrics & Gynaecology)  
Dip Op. Pelv., K. Op. Lap (Germany)  
Senior Director - Division of Minimally Invasive  
Gynaecology Surgery  
DMC Reg. No.: 15355  
Appointments: 9958 631 112, 9811 164497, 8860 444 888  
Emergency: 011-4055 4055  
Email: vivek.marwah@maxhealthcare.com

PAGE - 7

Mrs. Tanya  
30yr  
for L. L. MC / G

29/07/2023

W. ART. Gub 12/2022  
5/2022

M. Mrs 45 / 28-30  
Mrs 45 / 28-20  
Mrs 2/2

116 - 719 pld  
765 - 800

4/12 Mrs 45 / 28-30

for L. G. MC / G  
Mrs 45 / 28-30  
Mrs 45 / 28-20  
Mrs 2/2  
12/12/2023

3/A - 128  
CA - 199 - 182  
CA - 145 - 182

W. ART. Gub  
Mrs 45 / 28-30  
Mrs 45 / 28-20  
Mrs 2/2

21, 16, 12  
Mrs 45 / 28-30  
Mrs 45 / 28-20  
Mrs 2/2

Self Attested  
22/12/23







20/04/23

313 शारदा नगर  
Mrs. Tanupriya Jaiswal, 30y / F

elo

multicystic endometrial  
cyst 4<sup>th</sup> grade

and multiple  
myomas.

Achv

- Lt Sigmoidoscopy done.

- TB Gold IGR.

- Rt Hydrocoele /  
Hematocele

- Mantoux test.

Dec 2022

CA 125 - 103

7/04/23

CA 125 - 173

Comp - 14/04/23

6 - Plan for stretch

- CS9

- Tab S.M.R.P.V. x daily

00 ——— 00  
9:00

Self Attested

@  
22/12/23

SARITA TIWARI  
B.A.M.S.  
123308





PAGE - 9

DATE ----- 17.4.23  
NAME ----- TANUPRIYA.  
AGE/SEX ----- F  
REFD.BY ----- DR.SARITA TEWARI.  
INVESTIGATION ----- PELVIC SCAN..TVS/ TAS

Uterus is AV - Enlarged in size. Wall asymmetry present due to multiple fibroids in posterior wall. Contour is irregular and myometrial echoes are heterogenous. Multiple intramural fibroids present .. FIGO 4 and 5 in classification. Fibromyoma is not indenting the endometrial echo. Various sizes are ..63x51x56mm..vol..100cc, 24x22mm, 21mm, 16mm, 17mm and 13mm mostly in posterior and left lateral walls. Cervix and cervical canal - appear normal in texture, except for a 5x4mm similar lesion. Endometrial echoes are seen and the cavity is empty. ET is 6mms.

Rt.ovary could not be visualized separate from a conglomerate cystic mass along with rt.fallopian tube. Lt.ovary has a 35x32x34mmmm..vol...20.6cc complex cystic mass with ground glass appearance. Rt.sided dilated tubular lesion is noted in rt.adnexa favouring dilated fallopian tubes. Rt.sided hydrosalpinx has lowlevel internal echoes s/o haematosalpinx ....Rt Fallopian tube Endometriosis. Sliding sign Absent .. Deep Infiltrating Endometriosis. Color score is 1 ..no internal vascularity. Cul-de-sac has no free fluid. Urinary Bladder has smooth wall of normal thickness and does not show any space occupying lesion or a calculus .

**IMPRESSION:-**  
**MULTIPLE FIBROMYOMAS UTERUS.**  
**DEEP INFILTRATING ENDOMETRIOSIS.**  
**COMPLEX CYSTIC MASSES BOTH ADNEXAE WITH GROUND GLASS APPEARANCE AND NO VASCULARITY - S/O ENDOMETRIOSIS BOTH OVARIES AND RT. FALLOPIAN TUBES.**

*Self Attested*  
*@*  
*22/12/23*

**Note :** This is a routine obstetrical ultrasound, mainly done for estimation of gestational age, amount of liquor, placental position and general well being of the fetus & not for the evaluation of all congenital anomalies. Moreover, the anomalies in relation to fetus heart and limbs are extremely difficult due to constantly changing position of the fetus & overlapping of its parts. The detection of Fetal Anomalies is Dependent on Fetal Position, Amount of Liquor, Gestational age of Fetus & the Wall Thickness. Hence a Normal Scan Does not Exclude the Possibility of Congenital Anomalies.













# TUSHTI AYURVEDA

♀ Gaur City-2, Casa WoodStock, B301, Greater Noida West  
☎ 7011134469, 7838212169

## Dr. Sarita Tiwari

Gynecologist | Obstetrician  
Infertility Specialist  
(Ayurveda & Panchkarma)

ॐ अस्मिन्नादि नमः

24/02/23

Mrs. Tanupriya, 34/F

PAGE - 11

clo

- heavy flow during period.
- pain (+)
- Kclo menorrhagia
- Endometrotic cyst.

Lmp - 22/02/23

Ob

G.C. - fair  
pulse - 10k  
B.P. - 105/82

wt - 72kg

SpO<sub>2</sub> - 97%

Ab

Syp Sutgulutiratan Kashyam x 1 month

20ml \_\_\_\_\_ 20ml = 20ml of leuc  
warmed.

Syp Sulekhandam Kashyam x 1 month

10ml \_\_\_\_\_ 10ml = 10ml of leuc  
warmed.

Tab Kanchnaar Chyawanprash x 1 month

00 \_\_\_\_\_ 00 a/m

Tab K<sub>2</sub>-G. x 1 month

00 \_\_\_\_\_ 00 a/m

Self Attended  
@  
22/2/23

**IVF** is not the last option.

**CHOOSE AYURVEDA CONCEIVE NATURALLY**

100% Herbal & Hormone-Free, Root Cause Cure for Infertility in Women:  
PCOD/PCOS | Recurrent Abortion | Fallopian Tubal Blockage |  
Low AMH | Endometriosis | Ovarian Cysts | Unexplained Infertility.





Culmarol Res x 1 month  
o ————— o Alm

- Tab S.M.R.P.V. x 1 month  
o ————— o Alm

- Tab J.G.R.P.V. x 1 month  
oo ————— oo Alm

- Dashmoolhantari lehm x 1 month  
Hsf ————— Hsf 2 cow's milk  
Alm

- phala ghrita daily  
Hsf Empty stomach

गर्भ की 3 मास

Adv  
CA120  
USG GVS  
D3 / D4

Self Attested  
@  
22/12/23

Dr. SARITA TIWARI  
B.A.M.S.  
Reg No. 193308

Filoviral size ?  
Calometroric cyst ?  
Mycosporium / Hematosporium ?

350  
41  
74  
Juni  
Porena  
il n





# पतंजलि आयुर्वेद चिकित्सालय PATANJALI AYURVEDA HOSPITAL



Token 24 PIN NO: 6711834233

Reg. No. AH-2017-0025

## बहिरंग चिकित्सा विभाग O.P.D.

PAGE - 12

समय : प्रतिदिन प्रातः 9 बजे से सायं 5 बजे तक Timing : 9.00 am to 5.00 pm Daily

क्लीनिक एवं सेंटर नं. Clinic & Centre No. ..... पहचान प्रमाण ID Proof : DL / AC / VIP / PC / PP .....

पंजीकरण संख्या Reg. No. ....107538-2022 चिकित्सक Vd. Dr. Neha Verma दिनांक Date 16/12/2022

विभाग Dept. Prescription No. PRI and PRASUTI वार्षिक संख्या Annual No. ST-4921-2022 कक्ष संख्या Room No. 6

रोगी : श्री/श्रीमती Patient : Mr./Mrs. TANU PRIYA JAISWAL आयु Age 30 Year लिंग Sex Female

पता Address MODEL TOWN Ghaziabad Uttar Pradesh, India Ph : 9450844930

फोन Landline No. : ..... मा. Mobile No. : ..... ईमेल E-mail : .....

**Patient Complaint:**  
C/O- Pain In Lower Abdomen ,Pain During Cycle , Clots During Cycle  
MI - 6 Yrs S/ H/O- B/L Endometriotic Cystectomy  
Adhesiolysis Done , Left Salpingectomy Done,  
Kc/O-Multiple Fibroid Uterus ( Largest One Is 6.4 \*5.4 Cm), Right Hydrosalpinx?Hemosalpinx .B/L Ovarian Cyst . Mh - 3Days/25-26 Days H/O- 2 Time Ivf Failure

**Diagnosis:**  
रक्तचाप B.P  
नार्डिफाइब्रॉइड्स / Ovarian Cysts  
तापमान Temperature  
रक्त शर्करा Blood Sugar  
अन्य Other

Planned for  
Matra Shodhan  
Basti x 5days  
P. v. s  
A. v. s

1. **जुनवादि कण्ठ** - 40g

KANCHNAR GHANVATI	60	GM
VRIDDHIVAADHIKA VATI	40	GM
CHANDRAPRABHA VAT	40	GM
CYSTOGRIT DIAMOND	60	GM

Follow-up Date: 16/01/2023  
Take 1 tab of medicine After meal with water ml.  
1k For 30 Days

*तीन बार खाने के बाद*

2. DASHMOOL KWATH 100 GM  
MAHARASNADI KWATH 100 GM  
NIRGUNDI KWATH 100 GM

Take 1 tsp of medicine and boil it in 4 cups of water. Boil till reduces to 1 cup. Strain and take it twice a day an hour before meal for 30 Days.

3. **खटुला** Iron  
**खटुला** Omega  
**खटुला** Vitamin  
**खटुला** Calcium

Pranayam / Asanas: BHASTRIKA, KAPALBHATI, ANULOM-VILOMI, BAHYA, BHRAMRI, UDGITH, UJJAI  
HSA- 46 MILION/ML  
MOTILITY 63% , 3% MORPHOLOGY NORMAL  
AMH - 0.99 NG/ML  
THYROID PROFILE - WNL  
PROLACTIN-NORMAL  
CA- 19.9- WNL  
CA- 125-106

Dr. Neha Verma  
Assistant Professor  
M.S. (AYU) - GYNAE & OB  
Reg. No - 1067  
OPD days: Friday, Saturday

Self Attested  
22/12/23

Neha  
16/12/2022





Patanjali Yogpeeth Nyas (PWC001)

Haridwar, Uttarakhand, India -

Phone : 8954666111, Email : patanjaliyogpeeth@patanjaliwellness.com

Note : Not for medico legal purpose

Booking No: IPD2223000170271

Patient: Mrs. Tanu Priya (9450844930), F, 30 yrs

Doctor Name: Dr Rakesh Dehari

Room No: 7313

Consultation Date: 24-12-2022

MR No: 22121809475443

DOA: 24-12-2022

DOD: 29-12-2022

PAGE-13

Main Complaints :

- C/O- Pain In Lower Abdomen.
- Fullness Of Abdomen.
- K/C/O- Bulky Uterus.
- Large Submucosal Fibroid In Posterior Mid Corpus Region Of Size 94.8 Gms, Smaller Lt. Cornual And Anterior Wall Intramural Fibroids .
- Chronic Cervicitis.
- B/L Endometriotic Cyst .
- HB-8.8 G/DL.
- Uric Acid -6.95 Mg/DL.

Diagnosis :

GARBHASHAYA GRANTHI / UTERINE FIBROIDS

Hematosalpinx in Rt. tube

Handwritten notes in Hindi

Handwritten notes: prosepny in 2021

Medicine

Name	Qty	MOA
(1) DIVYA DASHMOOL KWATH 100 GM	1	Take And Boil 2 Teaspoon Of Kwath Drug Into 400 MI Of Water, When It Reduce To 100 MI Then Strain It And Take Empty Stomach In The Morning And Evening.
(2) DIVYA LIVOGRIT TABLET 60 N 33 GM	1	Take 1 Tablet- 1 Capsule Of Medicine, 30 Minutes Before Breakfast- Lunch- Dinner With Lukewarm Water.
DIVYA CYSTOGRIT 60	1	
(3) DIVYA KANCHNAR GHANVATI 60 N 35 GM	1	Take 1 Tablet- 1 Capsule Of Medicine, 30 Minutes After Breakfast- Lunch- Dinner With Lukewarm Water.
DIVYA VRIDDHIVADHIKA VATI 20 GM	1	ATS
SEA BUCKTHORN CAP 30N	1	
PUNARNAVADI MANDOOR 60 TAB	1	

Handwritten notes: चन्द्रपत्रावली खलफिद

Handwritten notes: गोशु 20 ml, देवीदेवी 20 ml, जलपिनिमोकोस 10 ml

Handwritten notes: अनुलेमफिलोन (1-1000), अलकानी (1-1000)

Kesh Kank Hair Export oil For Hairs

Handwritten notes in a circle: 24, 16809, S

Handwritten signature: Rakesh Dehari 22/12/23

Handwritten notes: केशकंक



1. Introduction

2. Theoretical background

3. Methodology

4. Results and Discussion

5. Conclusion

6. References

7. Appendix

8. Bibliography

9. Glossary

10. Index

11. Summary

12. Acknowledgements

13. Contact Information

14. Disclaimer

15. Copyright

16. Privacy Policy

17. Terms and Conditions

18. About Us

19. FAQ

20. Sitemap

21. Feedback

22. Help

23. Support



Booking No: IPD22230001702271  
Patient: Mrs. Tanu Priya (9450844930), F, 30 yrs  
Doctor Name: Dr. Rakesh Dehari, Dr. Priyanka Upadhyaya  
Room No: 7313

Consultation Date: 24-12-2022  
MR No: 22121809475443  
DOA: 24-12-2022  
DOD: 29-12-2022

Note : Not for medico legal purpose

Diagnosis :  
GARBHASHAYA GRANTHI / UTERINE FIBROIDS

Main Complaints :  
C/O - Pain In Lower Abdomen,  
- Fullness Of Abdomen,  
K/C/O - Bulky Uterus.  
- Large Submucosal Fibroid In Posterior Mid Corpus Region Of Size 94.8 Gms, Smaller Lt. Cornual  
And Anterior Wall Intrauterine Fibroids.  
- Chronic Cervicitis,  
B/L Endometriotic Cyst.  
HB-8.8 G/DL  
Uric Acid - 6.95 Mg/DL.

*Sy Attested*  
*24/12/23*

Vital Data

Date	BP (mmHg)	Pulse Rate (bpm)	Respiration (bpm)	Temperature (°F)	Height (cms.)	Weight (kg.)	FBS (mg/dl)	PPBS (mg/dl)	RBS (mg/dl)	BMI (kg/m <sup>2</sup> )
24-12-2022 17:57	100/70					72				

Treatment

Date	Time	Treatment
25-12-2022	04:00AM-05:00AM (Shaktikarma)	EN, JALNETI, RUBBER NETI, EYE WASH, MC+EP
26-12-2022	07:30AM-08:00AM and 01:30PM-02:00PM	EN, JALNETI, RUBBER NETI, EYE WASH, MC+EP
27-12-2022	08:30AM-12:30PM	EN, JALNETI, RUBBER NETI, EYE WASH, MC+EP
28-12-2022	01:30PM-05:30PM	JN, EV
29-12-2022		JN, EV

Treatment Note : MB-Kayakalp Oil 50 ML, (NB-Kayakalp + Sarvakalp Kwath + Kanchnaraghan Vati 10 + Vridhivadika Vati 10)

*+ 200mg 2x 2x*

*20/12/23*

*MC*

*PARI-KW, MB, APT, ACU*

*HCHB WITH EPSOM SALT, CFM+TP, ATP*

Date	Time	Diet
25-12-2022	04:30AM-05:00AM 07:30AM-08:00AM 08:00AM-09:00AM 11:00AM-01:00PM 02:00PM-02:30PM 05:00PM-06:00PM 07:30PM-08:30PM 08:30PM-09:00PM	AS F2 C3 D2 WT 2, SP BV, AD ROTI-2, SP ACP, Apple BV, ACP
26-12-2022		AS F2 C3 D2 WT 2, SP BV, AD ROTI-2, SP ACP, Apple BV, ACP
27-12-2022		AS F2 C3 D2 WT 2, SP BV, AD ROTI-2, SP ACP, Apple BV, ACP
28-12-2022		AS F2 C3 D2 WT 2, SP BV, AD ROTI-2, SP ACP, Apple BV, ACP
29-12-2022		AS F2 C3 D2 WT 2, SP BV, AD ROTI-2, SP ACP, Apple BV, ACP

Date	Time	Diet
25-12-2022	04:30AM-05:00AM 07:30AM-08:00AM 08:00AM-09:00AM 11:00AM-01:00PM 02:00PM-02:30PM 05:00PM-06:00PM 07:30PM-08:30PM 08:30PM-09:00PM	AS F2 C3 D2 WT 2, SP BV, AD ROTI-2, SP ACP, Apple BV, ACP
26-12-2022		AS F2 C3 D2 WT 2, SP BV, AD ROTI-2, SP ACP, Apple BV, ACP
27-12-2022		AS F2 C3 D2 WT 2, SP BV, AD ROTI-2, SP ACP, Apple BV, ACP
28-12-2022		AS F2 C3 D2 WT 2, SP BV, AD ROTI-2, SP ACP, Apple BV, ACP
29-12-2022		AS F2 C3 D2 WT 2, SP BV, AD ROTI-2, SP ACP, Apple BV, ACP

*Flavise of powder*

*Salem*

*Antigae*





# TUSHTI AYURVEDA

Gaur City-2, Casa WoodStock, B301, Greater Noida West  
7011134469, 7838212169

## Dr. Sarita Tiwari

Gynecologist | Obstetrician  
Infertility Specialist  
(Ayurveda & Panchkarma)

Dr. Sarita Tiwari

09/12/22

PAGE - 15

Mrs. Tanvriya, 30y/f

Clb  
lelelo 3lc Endometriotic  
cyst

o/e  
G.C. - fair  
pulse - 74/wr.  
spo<sub>2</sub> - 97%  
wt - 72.6 kg  
B.P. - 101/58  
mmHg

Comp 03/12/22

R

Gulgulitiktam Kashyam x 1 month.

20ml \_\_\_\_\_ 20ml \_\_\_\_\_ 20ml of  
Alm \_\_\_\_\_ Leuke water

duduranam Kashyam x 1 month.

15ml \_\_\_\_\_ 15ml \_\_\_\_\_ 15ml of  
Alm \_\_\_\_\_ Leuke water

A Surasana leham x 1 month

1 + sf \_\_\_\_\_ Leuke water  
or  
Leuke water

Self Attested  
@  
22/12/23

IVF<sup>®</sup> is not the last option.

CHOOSE AYURVEDA CONCEIVE NATURALLY

100% Herbal & Hormone-Free, Root Cause Cure for Infertility in Women:  
PCOD/PCOS | Recurrent Abortion | Fallopian Tubal Blockage |  
Low AMH | Endometriosis | Ovarian Cysts | Unexplained Infertility.



✓ Gomutra Ras | Aardhanand | Sarjeerani Ras

25ml ————— ~~20ml~~ X  
= Half glass of  
Empty Stomach <sup>lene war</sup> water.

Tab mensokot X 1 month  
| ————— | 9/00

✓ Phala Sapi X daily

————— 1st X lene  
war  
water.

Early morning

Sarita

Dr. SARITA TIWARI  
B.A.M.S.  
Reg No 193308

Suf Husted  
@  
24/12/23



# Dr. (Mrs.) Chitra Setya

MD (Obst. & Gyne)  
Sr. Consultant Obstetrician & Gynaecologist  
and Laparoscopic Surgeon  
Reg. No. MCI 1491

# Dr. Sushmita Prakash

MD (Obst. & Gyne)  
Associate Consultant  
Reg. No. DMC 47642

Clinic :

PAGE - 16

Clinic : C-6, Sector-20, Noida, Ph.: (0120) 4121741, 2521648, 2522136, 8287716995

E-mail : setyas@gmail.com

Mon., Wed. & Fri. 12 Noon to 1.30 pm and 6.00 pm to 8.00 pm.

Tue., Thur. & Sat. 12 noon to 2.00 pm

(Sunday Closed)

Apollo Hospital, E-2, Sector-26, Noida. Ph. (0120) 4012000

ONE OF THE TEAM MEMBERS WILL ATTEND TO YOU IN ANY EMERGENCY

### Patient Details:

TANU PRIYA JAISWAL  
Age: 30 years (F)  
Contact No: 9953779565

Patient UHID: 22-23-00946

Department: Gynecology

Consulting Doctor: Dr. Chitra Setya

Visit Date: 21-11-2022

### History/Presenting Complaints: MF 5.5yrs.

P0+0 Failed 2 IVFs

Diagnosed as B/L endometriosis with adenomyosis with fibroids in 2020. Rx at AIIMS. started on Dienogest off & on. refd out due to Covid.

Consulted dr. V. Marwah at Max saket

Laparoscopic release of sigmoid / ureter with Lt salpingectomy with cystectomy for endometriotic cysts ranging from 15 x 5cm to 12x10cm. July 21

8/7/22: USG: Ut enlarged in size. Multiple fibroids post wall 6.2 x 6.5 x 5.1cm, 2.4x2.2cm, 2.3x2.4cm, 2.3x2.4cm & 2.2 x 2.1cm. mostly Lt lat & post walls. ET 5.7mm.

Rt ovary : 2 cystic masses 24x20x21mm, 19x14x14mm. Lt ovary 10x10x92mm, Rt tube hematosalpinx

MRI: Jan 22: Uterus AV,RF. ET 6.7mm. Multiple fibroids +. B/L endometrial cysts

Acute pain abdomen continuous.

LMP: 9/11/22

Has an embryo stored at SGRH

Clinical Finding: PV: Uterus about 8-10 wks size, incorporated in a mass in Lt Fx about 10x10cm . Acute tenderness+

Provisional Diagnosis: Endometriosis

### Rx:

- |    |   |                   |            |
|----|---|-------------------|------------|
| 1) | ENZOFLAM                                  | 3 times every day | x 5 days   |
| 2) | INJ LUPRIDE DEPOT 3.75 MG I/M EVERY MONTH | every month       | x 1 months |

Tests: USG pelvis (TVS)

Review after result



Dr. Chitra Setya

UPMC: 81518, MCI: 1491, DMC: 5838

Self Attested  
@  
22/12/23

In case of emergency please reach Apollo Hospital Noida and contact the labour room  
Emergency Helpline : 9717480374

One of the doctors in the unit will attend to your case



**Patient Details:**

TANU PRIYA JAISWAL  
Age: 30 years (F)  
Contact No: 9953779565

Patient UHID: 22-23-00946  
Department: Gynecology  
Consulting Doctor: Dr. Chitra Setya

Visit Date: 21-11-2022

**History/Presenting Complaints:** MF 5.5yrs.

P0+0 Failed 2 IVFs  
Diagnosed as B/L endometriosis with adenomyosis with fibroids in 2020. Rx at AIIMS. started on Dienogest off & on.  
refd out due to Covid.  
Consulted Dr. V. Marwah at Max saket  
Laparoscopic release of sigmoid / ureter with Lt salpingectomy with cystectomy for endometriotic cysts ranging from  
15 x 5cm to 12x10cm. July 21  
8/7/22: USG: Ut enlarged in size. Multiple fibroids post wall 6.2 x 6.5 x 5.1cm, 2.4x2.2cm, 2.3x2.4cm, 2.3x2.4cm & 2.2 x  
2.1cm. mostly Lt lat & post walls. ET 5.7mm.  
Rt ovary : 2 cystic masses 24x20x21mm, 19x14x14mm. Lt ovary 10x10x92mm, Rt tube hematosalpinx  
MRI: Jan 22: Uterus AV,RF. ET 6.7mm. Multiple fibroids +. B/L endometrial cysts  
Acute pain abdomen continuous.

LMP: 9/11/22

Has an embryo stored at SGRH

USG 21/11/22: Uterus RV bulky with a well defined fibroid in post midsection 6.4 x 5.8 x 4.8cm extending S/mucosally.  
Lt cornual S/S & small I/M midcorpus ant wall seen ET 1.03cm. Both ovaries not seen separately from B/L  
multiloculated thick, regular walled cystic lesions with low intensity contents 4.8 x 3.7 x 2.0cm & 2.7x2.8cm & Lt  
composite 4.5 x 4.5 x 3.7cm . No free fluid seen.

Clinical Finding: P/V: Uterus about 8-10 wks size, incorporated in a mass in Lt Fx about 10x10cm . Acute tenderness+

Provisional Diagnosis: Endometriosis

Rx:

- |  |                   |            |
|--|-------------------|------------|
| 1) ENZOFLAM                                  | 3 times every day | x 5 days   |
| 2) INJ LUPRIDE DEPOT 3.75 MG I/M EVERY MONTH | every month       | x 1 months |

Review with Dr. Abha regarding surrogacy in view of fibroid projecting S/M

*Abha*  
AMH

*Chitra Setya*  
Dr. Chitra Setya

UPMC: 81518, MCI: 1491, DMC: 5838

*By Atul [Signature]*  
@  
2/12/23



Puneet Bedi MD

Obstetrician, Gynaecologist & Specialist in Fetal Medicine

D 49, Hauz Khas New Delhi 110016 Phone 26513682, 26568203, 9810170717  
Registration No MCI 2255 Email drpuneetbedi@gmail.com

PAGE -17

Tanupriya Jaiswal 30 Abhishek Jaiswal 9953779565 P0A0 BI Gr B Neg Husband B Positive LMP 23 8 22  
Never Tried for conception being for Abdominal pain Surgery for ? Endometriosis 2021 2 cycles IVF Failed

September 10, 2022 Complains of NO complaints Except Trying to Conceive

**Past Medical History** Any History of

**GIS** Liver Disease Nil Gall Stones Nil Jaundice Nil

**CVS** H/O Rheumatic Fever / RHD Nil Congenital Heart Disease Nil Hypertension Nil

**Chest Diseases** Nil Asthma Nil Tuberculosis Nil COPD NIL

**Endocrinal System** Diabetes Nil Thyroid disease nil PCO NIL

**Neurological** Problems Nil Epilepsy Nil Migraines Nil Sleep Disorders Nil

**Mental Health** Problems Nil Anxiety Nil Depression Nil Mental Illness Nil Any Medication taken NIL

**GUS** Renal Disease Nil Recurrent UTI Nil PID Nil STDs Nil

**Blood Disorders** Thalassemia Nil Sickle cell NIL Thrombosis / Varicose veins NIL

**Musculoskeletal** Long term Spine / Neck / Back Problems Nil Limbs Nil

**Infections** Rubella Nil Chicken Pox Nil Measles Nil TB Nil HIV Nil

**Gynecological** Problems Fibroids Nil ? endometriosis Ovarian Mass / cysts Nil PCOS Nil

**History of Blood Transfusion** Nil

**History of Infertility** Any treatment for Infertility taken Yes 2 failed IVF Attempts

**History of Long Term Medication** For TB DIABETS THYROID Tranquilizers Other Drugs / Hormones Nil

**Allergies** Drugs Nil Food Nil Dust Nil Others Nil

**Others** Any Other Long term illness Nil Any Hospitalization Nil

**History of any Surgeries / General Anesthesia** STOP Nil **Laparoscopy done in 2021 one tube removed on**

**tuboplasty done** Appendix Nil Tonsils Nil Anesthetic Problems Nil GA Nil LA Nil Intubations Nil Gall bladder Nil

Laparoscopy Nil Piles / Fissures Nil Tumors Nil Breast Disease Fibroadenoma Lumps Nil Orthopedic Surgery / I

Injury Nil Cosmetic Surgery Nil

**Family History Genetic Disorders** Thalassemia Nil Sickle cell Trait Hemophilia Nil Other Bleeding disorders N

Fibrosis Nil Muscular Dystrophies Nil Mental Retardation Nil Others Nil / Syndromes Nil CP Nil Special Nee

children in the extended Family

Diabetes Hypertension Heart disease Tuberculosis Epilepsy Asthma  
Father Had DM No HT No HD No TB Nil Nil  
Mother no DM no HT No HD No TB Nil Nil  
Siblings Nil Of Significance

**Past Obstetric History** P0L0A0

HO Recurrent Miscarriages Nil Preterm Birth Nil Previous PIH / HELLP Nil

Surgery on the Uterus LSCS / Hysterotomy Nil Myomectomy Nil

Surgery on the Cervix Manchester Repair Nil Cervical Cautery Nil Cervical Circlage Nil

**Menstrual History** Menarche at 12 years Cycle 4/30 Reg Painful Periods No PMS No Pain Killers Very high do

Heavy Now

**Personal History** Work Housewife House Work Yes Smoking Nil Alcohol Never Recreational Drugs Nil

Vegetarian Exercise Walk Seat Belts Yes Contraception OCPs for painful period in 2014

**PRESENTING COMPLAINTS** Planning to Conceive

**On Examination** Pallor Nil Edema Nil Breast BL WNL Galactorrhoea nil Thyroid appears to be normal

Pulse Per minute BP 120 / 80 mm Hg Chest NAD CVS NAD Weight 72 Height 5'4"

Per Abdomen Uterus NO Mass / Tenderness Liver and Spleen are not palpable

**Per Speculum Examination NOT DONE** Per Vaginum Uterus NS Adenexa NAD NO Mass Tenderness

Serum Progesterone Day 22 ~~10~~ 12/13 Sept 2022

CBC  
Urine RE AND ME ✓

ADVISED

ZENTEL one tablet only just now ONE TABLET ONLY JUST NOW  
Autrin® one daily after breakfast

During Periods  
Voveran® SR 50 mg with Breakfast (For excessive Pain) during periods  
+ Crocin 500 SOS

Self Attested  
@  
22/12/23

(75512)



**NORMAL ACTIVITY**

**EXERCISE** Walks jogging, Dance, Aerobics Yoga skipping Swimming ARE GOOD  
NO MACHINES, NO WEIGHTS, NO PUSH UPS, PULL UPS, ROWING  
No Muscle building exercises

**Diet**

50 G of animal proteins (a small daily helping of Paneer (not processed Cheese) OR White meat from fish or po meat or three eggs)  
Milk Products Curds and Paneer -not processed Cheese are better than Milk as Milk  
5 fresh fruits (all seasonal Fruits in moderation including Papaya and Pineapple are good, Banana and Coconut probably the best fruits available all year round but all seasonal fruits are good)  
Vegetables both cooked and uncooked All Vegetables are good and you should mix them up  
A bowl of lentils every day preferably 2 bowls  
A handful of nuts (with chilka which has most of the nutrition soaked or fresh not fried)  
2-3 Dates every day and 2-3 dried Figs (Anjeer) fresh or soaked (good for Iron and keeps the motion soft , avoic constipation a common problem in pregnancy)  
No high calorie meals, avoid raw fats and sugars (all forms of ghee, panjeeri, laddo to be avoided totally as it o your weight and have 0 nutrition value)

**Menstrual Charting 6 months**

Dates Pads per day Clots +/- Medication Other symptoms

Puneet Bedi MD

*Handwritten signature*  
11/9/2022

# Husband's Semen Analysis  
Apollo IVF 6th floor

*Handwritten signature*  
10/9/2022

Self Attestd  
@  
22/12/23





डॉ. सारिता तिवारी

PAGE - 18

27/08/22

Ms. Pooja Jaiswal, 30y / F

clo

lelelo

Endometriotic cyst

± BCL

hematocapnia

- Pain in lower abdomen
- specially in lower abdomen.

Investigation

Hb% - 8.8

Vit D25OH - 48.3

UPG -

SHO9 - 22.2

SH29 - 20.2

lipid  
Painfull  
Average

Alkaline phosphatase - 108

left -

uric acid - 6.95

creatinine - 0.64

lipid profile

cholesterol - 153

triglycerides - 179

USG whole abdomen

3L

Reva conversion

Comp - 23/08/22

on 4.5 days

28. 30 days

plant on oepills - 10y slow

- Endoreg
- Berrabel

Flm Hypertension - mother, AB in family

S/for Laparoscopy for myomectomy + cystectomy

Dist No Allergy - to any medicines

self Attested  
24/12/22

6

Yanarshan 5 days

1/4 th of Honey or Juice warm water  
or empty stomach



Neer KPG x daily (2 month.)  
 10ml — 10ml = 10ml of leucocytosis

Syp Lotranone. x 2 month,  
 15ml — 15ml — 15ml E low of leucocytosis

Gob Puranahadi mandoor  
 00 — 00 Alon

*[Signature]*  
 DR. SARTI TIWARI  
 B.A.M.S.  
 Reg No. 193308

Anoid

25g Gm  
 100 of 100  
 100  
 100

100g  
 100g, 100g

100g  
 fermented - Bone  
 100g, 100g

Junk, preservative  
Packed food

100g  
 refined oil

Suf Atishy  
 @  
 24/12/23





Ms. Pampraja, 30y/f

R

- Varnadi Rasayam x 2 months (X)

2ml \_\_\_\_\_ 2ml 2 bowl of lime juice wali  
A/m

Tab Rama Brandadi Kwallu x 2 months (X)  
o \_\_\_\_\_ o A/m

- Saptasari Kwallu tab x 2 months ✓  
oo \_\_\_\_\_ oo A/m

- Kanchuran Juggul x 2 months ✓  
oo \_\_\_\_\_ oo A/m

- Tab Ke.h. x 2 months x  
oo \_\_\_\_\_ oo A/m

Self Attested  
@  
22/12/23

- Tab S.M.R.P.V. x 2 months ✓  
oo \_\_\_\_\_ oo A/m

SARITA TIWARI  
B.A.M.S.  
Reg No. 193308



# Yogasana

# अनु रोज

# Diet

Brisk walk 30-40 min

~~सुनि~~ योगासन → शुद्ध अनामस  
लोक विलोक  
शामना  
अभ्यास  
अपानासनादि - 20 min

चितली आसन  
 पश्चिमोत्तार  
 ललाटी आसन  
 गोशुल्क आसन  
 Planas  
 pashups  
 concha

9.12 PM  
 12-1  
 फल अथवा  
 vegetables

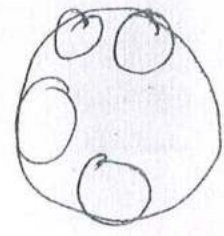
8:30 AM - 9 AM

काले चने  
~~...~~  
 फेदा / 300g -  
 oats / 100g  
 शुद्ध मसुरा  
 vermicelli  
 शिरीश मसुरा

↓  
 11 o'clock  
 fruit / salad /  
 sprouts

12:30 PM - 1 PM

अनामस  
 गुजर  
 पियार  
 लाली  
 अनामस  
 हरीशर्करा



4:30  
 Green tea  
 Roasted मकाने  
 Roasted चने  
 अने 2 पिठोरा

विरान - 80g  
 50 - 100  
 200 - 300  
 500 - 500

Boil  
 ↓  
 1-2 - 2 मल्टीग्रान्स  
 शिरीश  
 अनामस हरे  
 अनामस की चने

4:30  
 Green  
 ↓  
 Fruit Pump

Self Attested  
 @  
 22/12/23

7:30 8 PM





ॐ ह्येनमि मे

PAGE - 20

06/08/22

100ml. Pottu prajya, 25y / f

- maza basti c sahcharasli kalam c 30 ml

feeding tube

Syringe - 50ml  
100ml

50ml

Tab Yograj guggul.

800  
c lene wear  
cable

Self Attested  
@  
22/12/23

*(Signature)*

DR. SARITA TIWARI  
B.A.M.S.  
Reg No. 193308



Aroid → उड़द गीम  
 एते बीजम  
fermented →

अणु  
 अणु  
 अणु

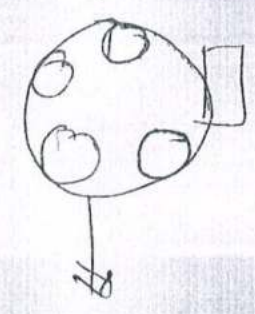
June, poryevahi  
 purreal

अणु  
 अणु  
 refined oil  
 अणु

diel  
 8:30 AM - फाले चणे  
 लो विया  
 - oats (अणु)  
 - पोटा (अणु)  
 - क्रीक पिना  
 - venicelli  
 - रोटी साठवा

↓  
 11:0' close  
 fruits / sprouts  
 Sabud

12:30 pm to 4 pm



4:30 - 5  
 Green tea  
 Roasted sprouts  
 Roasted चणे  
 आदि विरजण -  
 गुळ

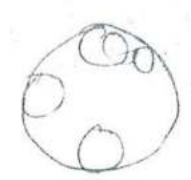
6  
 15ml ————— 15ml  
 kankasava

2 15ml of  
 pure war  
 water

अणु

- ditophaladi cheam  
 अणु

Sy Atish  
 @  
 22/12/23



7:30 - 8:30





अभिनेत्री नामः

PAGE-21

4/08/22

मा. पामु प्रिया, 29/11

cb

14/10

Adenocarcinoma

Endometrial module  
BL ovary.

Endometrioma

Seven abdominal  
pain

8/1/22

USG IVS / N/A

multiple

fibromyomas etc.

Deep infiltrating Endometriosis; 1/10/22  
Complex cystic mass both  
Adenocarc. 2 grand glass  
Appearance and NO vascularity.

19/08/21

19.9

CA125 - 71.9

8/1/22

AMH - 1.20

CA125 - 24.6

PGT - 22 ng / dl

LAG - (N)

KFA - (M)

Lipid profile - NR

Triglyceride - 158 ng / dl

Vit D25OH - 20.5

HIV I & II - NR

HbA1c - NR

HCV - NR

Hb% - 5.7

HbA1c - 5.67

VDRL - Negative

S/O - Endometriosis both ovary and

RT Fallopian tube.

last day leuprolide 3.7 mg.

Comp - 25/07/22

m/n

4-5 days

Regular

periods

28-30 days

heavy

self attested

22/12/23

Plan for - No.

Plan - Hypothyroidism - 9 months

S/O - laparoscopy surgery 2021 for sub ovarian mass



Dhw - No allergy to any medicine.

Q

Advice Maths basti with Lehcharoli tailer.  
2 goul oil

Castor oil  
1 tsp 2 mlt

Advice ice patte always

- G. Chandraprabha ras 7 2 months.  
0 — 0 — 0 1/m

Q  
G.C. - fever  
pulse - 88/min  
B.P. - 116/73  
wt - 72.7 kg  
SpO2 - 97%  
←

- G. hokhushali. guggul. 7 2 months  
0 — 0 — 0 1/m

Self Attested  
@  
24/12/23

Dr. Sarita  
DR. SARITA TIWARI  
B.A.M.S.  
Reg No. 193308



**Dr. Chandela**  
Specialized Homoeopathy Clinic

Dr. Jeetandra Chandela  
Dr. Bhavesh Chandela  
Dr. Swanti Singh Chandela



Successful Years  
Personalized Cure & Care



doctorchandela@gmail.com  
www.doctorchandela.com

Near Bhagat Singh Chowk, Haridwar (Uttarakhand), India

PAGE-22

**Dr. Chandela**  
Specialized Homoeopathy Clinic

Dr. Jeetandra Chandela  
Dr. Bhavesh Chandela  
Dr. Swanti Singh Chandela

**Consultation Timings**

Summer  
Morn : 10 am to 1.30 pm  
Even : 05 pm to 8.30 pm

Winter  
Morn : 10 am to 2:00 pm  
Even : 04 pm to 7.30 pm  
Sunday : 10 am to 5.00 pm

**Saturday Holiday**

**Registration Card**

Ref. 24873  
Name Mrs. Tanupriya  
Date 19.07.20

\* Appointment Requested For Consultation \*

Plz Call Us For Appointment : 01334 22 77 33 , 97 192 85 0 77 Fax 22 53 33

Self Attested  
@  
22/12/23







B. Ve

M - Tanu Kaje Sad

2.3 1/2

PAGE-24

19/6/2022

L. L. PL

Ref. Ref. in

Page 11/23-20  
 Page 25/23-20  
 Date - 1/6

1/2  
 1/2 AT / sp / M  
 1/2 1/2 1/2 / 1/2 / 1/2  
 1/2 1/2 1/2  
 1/2 1/2 1/2

31st May  
 Corrigendum

17/6/2022

Max Super Sp  
 (A Unit of Devki Devi Foundation)  
 2, Preet Enclave Road, Saket,  
 New Delhi-110 017  
 Phone: +91-11-26510050 / 66115000

Max Super Speciality Hospital, Saket  
 (East Block) - A Unit of Devki Devi Foundation  
 Devki Devi Foundation registered under the Societies Registration Act XXI of 1860  
 2, Preet Enclave Road, Saket, New Delhi, India

Self Attested  
 @  
 22/12/23





429 (CAT-28)

Endo. for  
TBS cure  
Expert  
Adenomyoma along  
Endo. Removal.

Severe Pain

Max Super Speciality Hospital - East Block  
(A Unit of Dewji Datta Foundation)  
2, Press Enclave Road, Connaught Place,  
New Delhi-110 008  
Ph: 91-11-2651 5959, Fax: 91-11-2651 5529 / 2651 5660

30/6/21	S. CA - 125	-	164.8
	S. Amn	-	3.32
	CA 19.9	-	471.2
	LDN	-	340 (240 - 480)

Self Attested  
@  
22/12/23

844  
100/70 mmHg  
64/18/163L  
98%