



Neev Medicare

CONSULTANT OBSTETRICIAN & GYNAECOLOGIST

Clinic :- Anika Market (Near Aura Chimera) 2 Floor, Raj Nagar Extn., Gzb.
Mob. : 9310726790, Website : drshwetagoyal.com

Dr. Shweta Goyal

M.B.B.S., M.S. (Obstetrics & Gynaecology)
(Gold Medalist)
Regd. No. : 9376

PAGE - 26

Timing
Mon to Sat : 8.30 a.m. to 1.00 p.m.
4.30 p.m. to 8.00 p.m.
Sun : 10.00 a.m. to 1.00 p.m.

8/4/22

Mrs. Tanupriya

Age 32y2m

BP (mm Hg) 103/74 mmHg
Pulse 93/1st
Wt. 71.1 kg
Pallor
Icterus

pt 40th infertile for last
1 year

trk IVF cycle - ~~July~~ ^{September} 2021

underwent myomectomy, endometrial
ablation, EMB for UPE in ~~July~~
July 2021.

LMP = 6/3/2022

pt on T. Mirena (for last 3 months)

pt has come for
2nd opinion.

ADV -

• Continue IVF
cycle.

Self Attested
@
22/12/23

Shweta

Follow us on :

Facebook :

Instagram :
Neevmedicare

Dr. Tanya Buckshee Rohatgi

MBBS MD DNB MNAMS FRCOG (London) DFFP (London) MSc - (UK), FICOG, DMC: 12733

Principal Consultant Reproductive Medicine & Assisted Reproductive Techniques (IVF) & Onco Fertility

Contact: 9910003731 e-mail: mybaby@maxhealthcare.com

Fellow Royal College, London, UK

MSc Reproduction & IVF-Distinction Awardee University of Bristol UK

Advanced ART & IVF Training in Reproductive Medicine Chelsea and Westminster Hospital, Imperial College London

Royal College Fellow in IVF & Onco-Fertility in Cancer Patients, KKIVF Women's and Children Hospital, Singapore

Diploma in Family Planning and Sexual Health, London

Fellowship in Laparoscopy and Reproductive Surgery, All India Institute of Medical Sciences (AIIMS)

Consultant Training - Obstetrics and Gynecology, Leeds University and Yorkshire Deanery (UK)

30/3/22

Mrs Tanya Jaiswal
29yr - 30yr Sep 2022

MF x 5 years

6th March

↓

bleeding on Drengeon

↑ Dose 2mg - 2mg
twice a day

has some pain ⊕

very uncomfortable

Issues

① failed IVF - No eggs

② Bev may

③ b/l infection
blowds / Adamp / reved

Stage IV Endometriosis

③ Abon tubes

④ Salpingectomy
(Kendall ⊕) (R) ? ? ?
(?) ? ? ?

④ failed IVF - No eggs

Oct 2022

Self Attestation
22/12/23

Dr. Tanya Buckshee Rohatgi

MBBS MD DNB MNAMS FRCOG (London) DFFP (London) MSc - (UK), FICOG, DMC: 12733

Principal Consultant Reproductive Medicine & Assisted Reproductive Techniques (IVF) & Onco Fertility

Contact: 9910003731 e-mail: mybaby@maxhealthcare.com

Fellow Royal College, London, UK

MSc Reproduction & IVF-Distinction Awardee University of Bristol UK

Advanced ART & IVF Training in Reproductive Medicine Chelsea and Westminster Hospital, Imperial College London

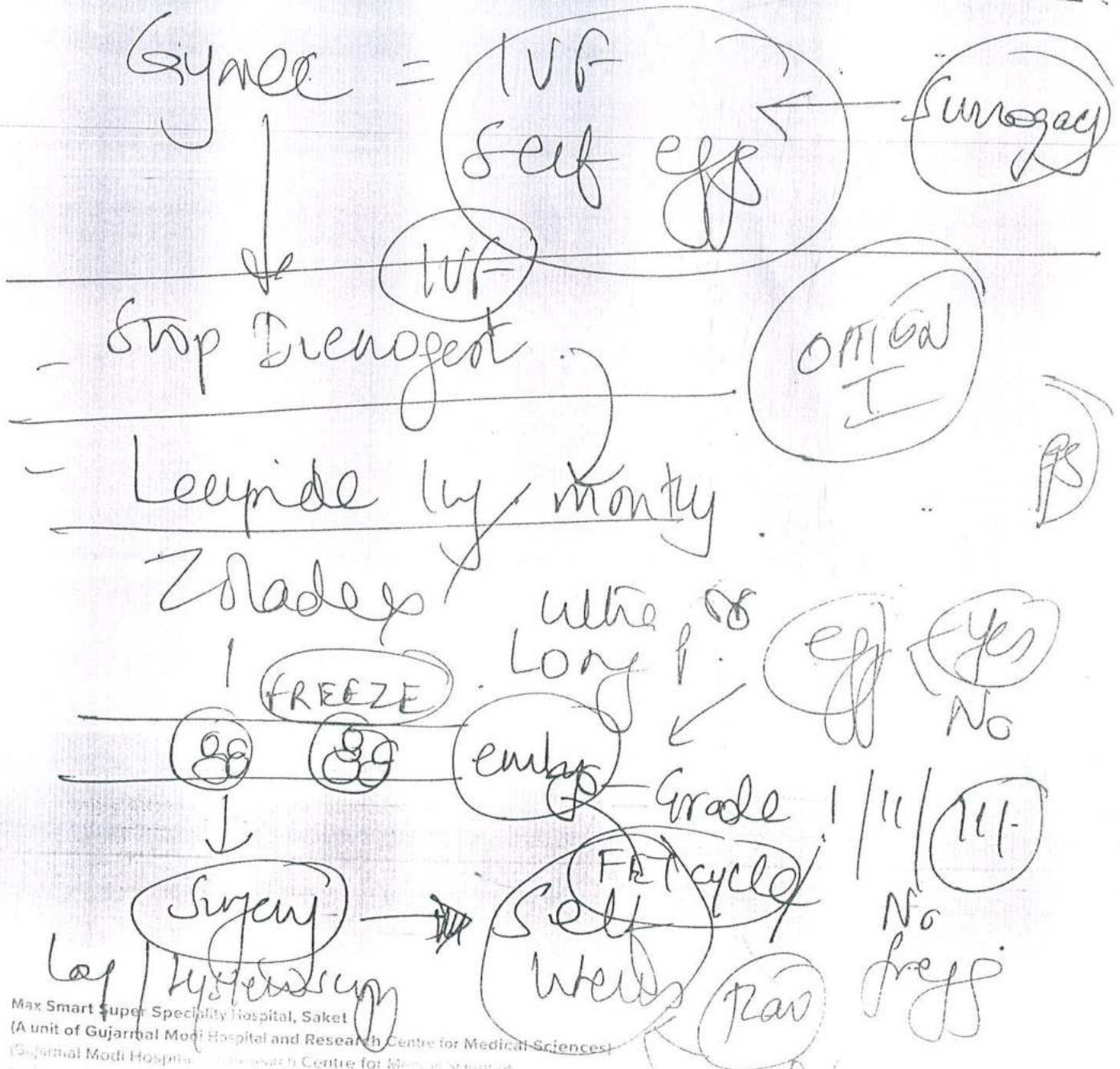
Royal College Fellow in IVF & Onco-Fertility in Cancer Patients, KKIVF Women's and Children Hospital, Singapore

Diploma in Family Planning and Sexual Health, London

Fellowship in Laparoscopy and Reproductive Surgery, All India Institute of Medical Sciences (AIIMS)

Consultant Training - Obstetrics and Gynecology, Leeds University and Yorkshire Deanery (UK)

Controlled



Max Smart Super Speciality Hospital, Saket
(A unit of Gujarmal Modi Hospital and Research Centre for Medical Sciences)
(Gujarmal Modi Hospital and Research Centre for Medical Sciences)

For Appointment Contact: +91 9990034444

Prenatal selection is illegal and banned in India. Punishable by law.

self Attested @ 22/12/23

Dr. Tanya Buckshee Rohatgi

MBBS MD DNB MNAMS FRCOG (London) DFFP (London) MSc - (UK), FICOG, DMC: 12733

Principal Consultant Reproductive Medicine & Assisted Reproductive Techniques (IVF) & Onco Fertility

Contact: 9910003731 e-mail: mybaby@maxhealthcare.com

Fellow Royal College, London, UK

MSc Reproduction & IVF-Distinction Awardee University of Bristol UK

Advanced ART & IVF Training in Reproductive Medicine Chelsea and Westminster Hospital, Imperial College London

Royal College Fellow in IVF & Onco-Fertility in Cancer Patients, KKIVF Women's and Children Hospital, Singapore

Diploma in Family Planning and Sexual Health, London

Fellowship in Laparoscopy and Reproductive Surgery, All India Institute of Medical Sciences (AIIMS)

Consultant Training - Obstetrics and Gynecology, Leeds University and Yorkshire Deanery (UK)

Contd

- Surgery July 2021
 - Lupide x (2) Aug / Sep 2021
 - IVF (Oct 2021) Antay op

(F) from (S)
 My tumour Ht 375 (mm)
 My cells (↑ 450 IU)
 Tiger HUCOG 10, 010/m
 On
 Drenogen Large
 22nd Jan '22

11 days (+) No Eggs

Jan / MRI 2022

fibroids (+)
 Lapa 2.5 x 2.3 cm
 Adenomyosis
 of Ovaria
 Peritoneum
 (L) - 3.8 x 3.6
 (R) 2 x 2.1

Feb 2022 Bully / Adenomyosis

? Hydrosalpinx (R) 34 x 32 mm with submucosal elevation

self attest
 @
 22/12/23

2) Cont 7. Diclogeest / viscane 2mg - daily for 3 months.

3) Avoid constipation

Take SYR MOVICOL - 2 tsp in water at night if feeling constipated.

4) PRIMROSA 500 - twice daily for 2 months. 0/0

5) CAP EVION LC - once daily for 2 months. - 0

6) Blood for - vit B12
- vit D3

7) ARACHNITOL ~~DIANO~~ 60k - once weekly for 8 weeks.

8) RIA 3 months

Plan: Frozen ET

↓ ↓
Self donor

To discuss with DR TANIA BAUSHI

Signature
Dr Jayaram
Sundar.

DR. JAYARAM SUNDAR
Department of Obstetrics & Gynaecology
DMC Reg. No.: 20150

36.64/100

Self Attested
@
22/10/23



Visit No. : 022203240097
Patient Name : **Ms. TANU PRIYA JAISWAL**
Age/Sex : **30 YRS / Female**
Referred By : Dr. VIVEK MARWAH

UID No. : 1405089
Reg. Date : 24/Mar/2022 02:26 PM
Report Date : 24/Mar/2022 04:39PM
Print Date : 24/Mar/2022 04:39 PM

PAGE - 31

ULTRASOUND PELVIS (TVS)

Ultrasound was done using a transvaginal probe with special 2D enhancement features including compound and speckle reduction imaging (SRI).

Clinical profile: Patient is a follow-up case of endometriosis.

Urinary Bladder: is adequately distended and reveals normal walls. No calculus is seen.
Pre-void bladder volume measures 206.6cc.
Post-void residual urine measures 11cc (insignificant).

Uterus: is anteverted, retroflexed and the uterine corpus measures 7.7x7.2x7.3cm in size. It reveals a globular contour with moderate heterogeneity of the myometrium and a poorly defined endomyometrial interface. Mild discordant thickening of the posterior myometrium (3.95 cm) is noted as compared to the anterior myometrium (2.0cm). Multiple well-defined hypoechoic focal lesions suggestive of myomas are noted measuring approximately 2.1 x 1.1cm, 1.4 x 1.0cm are seen in the anterior myometrium and 1.7 x 1.6cm in the left lateral wall. A heteroechoic focal lesion is seen in the left posterior myometrium measuring approximately 5.1 x 4.6 cm showing few cystic foci within it, largest measuring approximately 1.0cm and 0.8cm.

Pushty mty

The endometrial echo appears displaced anteriorly and measures 4.9mm.

The cervix appears normal in size and measures 2.9 x 2.0cm. It shows a nabothian cyst with internal echoes in the posterior cervical pillar measuring approximately 9x8mm.

Both ovaries: appear adherent to the posterior uterine walls.
Right ovary is bulky and measures 5.5 x 3.7 x 2.0cm, volume being 22.3cc. There are two well-defined thin walled smoothly marginated cystic lesions measuring approx. 2.2 x 1.8 x 1.3cm, (volume 2.9cc) and 1.9 x 1.8 x 1.5cm volume 2.8cc. These cysts show homogeneous low amplitude internal echoes. No obvious septations / solid component / vascularity is seen. These are suggestive of small endometriotic cysts. Two follicles are seen in the right ovary measuring approximately 9.9mm, 8.0mm.

Left ovary measures 3.3 x 2.7 x 1.4cm, volume being 6.9cc. There are three well-defined thin walled smoothly marginated cystic lesions measuring approx. 1.1 x 1.1 x 1.0cm volume 0.7cc, 1.3 x 1.2 x 0.9cm volume 0.8cc and 1.2 x 1.1 x 0.7 cm volume 0.5cc. These cysts show homogeneous low amplitude internal echoes. No obvious septations / solid component / vascularity is seen. These are suggestive of small endometriotic cysts. Three follicles are seen in the left ovary measuring approximately 5.8mm, 4.2mm and 4.1mm.

Self Attested

*@
22/12/23*



Mr. Tanu Prasad Jaiswal

28 1/2

PAGE-33 31/01/2023

Emp - 31/11. Visceral Adh. Acte 1 month
12/01 -> 25

APT 25/11/2022
31/10/2022

Dr. ERDOGAN / V. SARMA
24g
x 3

Acte 1 month

- L.F.T.
- U.S.G - PELVIS (T.V.S)

Dr. MEHTA L
Gy. PARIK

Self Attested
@
22/12/23





Name- **MRS. Tarnu Priya** Reg. No. - **200211492** Age/Sex- **30y/F** Issue Date- **25/1/22**
 Category **Priya** Patient Mob.- **9595564544** Pay Mode- **PAGE - 35**

Dr. (Prof.) Alka Kriplani
M.D, FRCOG, FAMS, FICOG, FIMSA, FICMCH, FCLS
 Director & HOD – Obstetrics, Gynecology & ART
Padma Shri, Dr. B.C Roy National Awardee
 Ex – Professor & Head, Deptt. of Obst. & Gynae.
 All India Institute of Medical Sciences, New Delhi, India

For Appointment, Please Contact
 Tel: - 0124-4585555
(OPD Mon to Fri - 9:00 am to 4:00 pm)
(OPD Saturday - 9:00 am to 3:00 pm)
 For any Enquiry (9:00 am to 5:00 pm)
MS. KULJEET KAUR - 9319292564

Dr. Seema Sharma
Sr. Consultant – MS, FMAS
 Mob.-9810439709

Dr. Namita Jain
Consultant
 MS, DNB, MRCOG (UK), IVF
 Mob. - 9899142849

Dr. Manpreet Sodhi
Consultant
 DNB, Fellowship in clinical ART
 Mob. - 9810434251

<p>Menstrual History</p> <p><u>LMP -> 12/1/2022</u></p>	<p>Presenting Complaints</p> <p><u>Yo severe pain abdomen</u></p>
<p>Obstetric History</p>	<p>Examination Findings</p> <p>BP: Weight: Height:</p> <p>Breast</p> <p>P/A:</p>
<p>Medical History</p>	<p>P/S:</p> <p><i>self Attested</i> <i>[Signature]</i> <u>22/12/23</u></p>
<p>Surgical History</p>	<p>P/V:</p>
<p>Family History</p>	



Diagnosis

Date

Investigation

Dr. Sonia Malik

Dr. Natini Mafajan

Kaveri Banerjee

Cloud 9 → Dr. Shweta

Management Plan

Ovi + IUI next cycle.

In a cycle to be tried to

Advice

look for follicles.

Options discussed
✓ ovi + IUI
✓ surgery vs.

✓ Medical Rx

✓ planning pregnancy

patient yet to decide

1. Visanne drug on daily
x 3 months

Rx aft. 3 months.

1. folic acid daily x 3 months.

H

For husband

1. Carnitine x 1 mg
daily x 3 months

Sofy Atisher

22/12/23

Diagnosis

Malignant of Endometrium
+ HbA1c, for Myomectomy
Endometrium + Pan

Date

8/1/2022

AMH → 1.20

24/10/2021
CA-125 → 23.1

YSH - 1.09

PM - 9.9

Investigation

CA-19.9-67.6

Management Plan

HSA

Advice

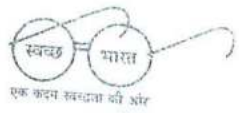Y v i reperi

Yodo

→ MRI pelvis + kidneys

Sib Alister

22/12/23



अस्पताल के अन्दर धूम्रपान मना है / SMOKING IS PROHIBITED IN HOSPITAL PREMISES

शरीरमाद्यं खलु धर्मसाधनम्

एकक/Unit _____
 वेभाग/Dept. _____

OPR-6
 PAGE-37

नाम/Name	पिता/पुत्र/पत्नी/पुत्री F/S/W/D of	लिंग Sex	आयु Age	पता/Address
Tanu Priya Jaiswal		F	28yr	

ब०रो०वि० पंजीकृत सं०/O.P.D. Regn. No. _____

दान/Diagnosis

दिनांक/Date

उपचार/Treatment

2/09/21

Inc of Ad IV Endometriosis (DIE)
 & Fibroid adenomyosis
 ↓
 Laparoscopic clearing on 5/7/21
 ↓
 Removal of R/L Endometriomas
 (cystectomy) & Lt Hematosalpinx
 & ~~excision~~ excision of
 RU nodules & removal of sigmoid
 + adenomyoma (all hpc confirmed)
 ↓
 Recd. Ling of Lupride
 (17th July & 21st Aug 21)

Hysteroscopy
 also done
 - Normal

AFC < 7-8 / outside

PLAN : COS & OPV free all embryos

DR FET

Self Attested
 @

22/12/23



MAX

Institute of Laparoscopic,
Endoscopic & Bariatric Surgery

Mrs. Sannkya
Taisevel

Dr. Vivek Marwah
M.S. (Obstetrics & Gynaecology)
Dip. Op. Pelv., K. Op. Lap (General)
Director - Division of Minimally Invasive Gynaecology
Max Institute of Laparoscopic, Endoscopic
and Bariatric Surgery
Appointments: 9958 631 112, 9811 164 112
E: vivek.marwah@maxhealthcare.com
For free Home Delivery of Medicine: 8744 888

PAGE - 39 12/7/20

Pre case of lap management of
Endometriosis & Lap. myomectomy
on 5th July 2021
ready to enter hall.

Adv.

- Inj. Betadine 3-4 times a day

- Tab. crocin 650mg 3-5 } 7 pm
- Lap. Band. 1505 }

Tab - Cremlan 2 tabs 505 } 7
- Colmapa

Tab. Allegra 120mg 10/5. 05-7

Biopsy - W.M.

T.

Max Super Speciality Hospital - East Block
(A Unit of Devki Devi Foundation)
2, Press Enclave Road, Saket,
New Delhi-110 017
Tel: 4961 3050, Fax: +91-11-4961 3050

Self Attested
@
22/12/23

Division of Minimally Invasive Gynecology Surgery

Name		Discharge Summary		
TANU PRIYA, JAISWAL		SSN No.	Sex	Date of Birth
Admitted	JUL 4, 2021 @ 11:58:25	210-37-8925	FEMALE	JUL 25, 1992
Ward	SKTE-5THFLR-MAS	Room-Bed	EB-EC-2533	
Provider	MARWAH, VIVEK	Specialty	MIN INV GYN SUR DIVN	
DOD	07/07/2021			

****Diagnosis****

Bilateral Multiple Ovarian Endometriomas with Left Haematosalpinx with Left Tubo-Ovarian Mass with Severe Deep Infiltrating Rectovaginal Endometriosis with Adenomyosis Uteri with Myoma Uterus

****History****

Complaints of pain lower abdomen with increased frequency of urination 2 yrs.
Past cycles- 3-5/28-30 days
Present cycles - 3-5days/ 28-30 days cycle
LMP- 1/6/21
Married life 4 yrs
Nulligravidae
Inj covishield 31/5/21

****Examination****

Patient is of normal build.
No tenderness present.

****Operation Details****

Laparoscopic Management of Endometriosis with Removal of Bilateral Endometriomas with Left Salpingectomy with Excision of Endometriotic Nodule with Diagnostic Hysteroscopy with Adhesiolysis was performed on 05th July 2021.

****For emergency or doctor assistance (Fever/Vomiting/Excessive Bleeding)****

Please contact Dr. Vivek Marwah : 9958631112
Dr. Surbhi : 9818152807/ Dr. Kanika : 8007591226
or report to the casualty at Max Health Care, Saket
Tel no. (011-26515050).

****For Homecare services****

(Sample Collection, Physiotherapy, Medicine Delivery, Nursing, Medical Equipment, Doctor Visit)


Contact at 011-47326969, +91-9999777754. — for Lab reports

Page - 1

Self Attested
@
22/12/23

Max Super Speciality Hospital - East Block
(A Unit of Devki Devi Foundation)
2, Press Enclave Road, Saket,
New Delhi-110 017
Ph: +91-11-2651 5050, Fax: +91-11-26510250/11-11-1103

Max Super Speciality Hospital, Saket
(First Block) - A Unit of Devki Devi Foundation
(Devki Devi Foundation registered under the Societies Registration Act XXI of 1860)
Regd Office 2, Press Enclave Road, Saket, New Delhi 110 017
For medical service queries or appointments, call +91 11 2651 5050
Fax: +91 11 2651 0050
www.maxhealthcare.in

Max 



Name	SSN No.	Sex	Date of Birth
TANU PRIYA ,JAISWAL	210-37-8925	FEMALE	JUL 25,1992


****Operative Findings****

P/S : Cervix and vagina healthy.
 P/V : Pelvic mass 28 weeks size ,UCL-9 cm
 D&C done-endometrium sent for histopathology.
 On Hysteroscopy :
 External os , internal os and endocervical canal normal
 Uterine cavity - stretched
 No indentation / submucous myoma/ septum present
 Bilateral ostia visualised with right ostia pulled backwards
 On Laparoscopy :
 Upper abdomen normal.
 Uterus 8-10 weeks size. Adenomyotic.
 Three intramural myomas present largest fundal 4x5 cms with two seedling myomas present - total 5 myomas removed.
 Fundoposterior 2x2 cm adenomyoma present - removed.
 Left tubal haematosalpinx 15x5 cm present coiled around the ovary forming tubo-ovarian mass 15x 18 cm adherent to ovarian fossae,posterior surface of uterus and rectosigmoid entrapping left ureter-released and left salpingectomy done .
 Multiple left ovarian endometriomas present ranging from 8x9 cm to 2x1 cm invaginating into the pararectal space and perivesical space - released , drained and cyst wall removed.
 Multiple large right ovarian endometriomas present largest measuring 12x10 cm cms (ranging from 12 - 1 cm) present adherent to rectosigmoid and appendix and invaginating into the pararectal space and POD - released , drained and cyst wall removed .
 Right tube oedematous and patent.
 Chromopertubation test - right side free spill present ..
 Bilateral ureters entrapped in adhesions - released.
 Bladder and UV fold normal.
 Rectosigmoid advanced and adherent to left lateral pelvic wall, left tubo-ovarian mass , right ovarian endometriomas and posterior surface of uterus with dense adhesions - released and integrity checked .
 Scarring and fibrosis of bilateral uterosacral ligaments forming endometriotic nodule with rectosigmoid - excised .
 Rectovaginal endometriosis present and pod completely obliterated with adhesions - cleared myoma sent for frozen section - benign .
 Myoma sent for frozen section - benign .
 Endometrium for TB gene expert .
 Endometrium , myoma , adenomyoma , left ovarian cyst , right ovarian cyst and Endometriotic nodule sent for histopathology.

****course in hospital**** 2 units of B negative LDPRBC and one unit of FFP.

Self Attested
@
22/12/23

Max Super Speciality Hospital
 (A Unit of Devki Devi Foundation)
 2, Press Enclave Road, Saket, New Delhi-110 017
 Ph: +91-11-2651 5050, Fax: +91-11-2651 5050





Laboratory Investigation Report

Patient Name	: Ms. Tanu Priya Jaiswal	Centre	: 1103 - Max Hospital Saket (East Block)
Age/Gender	: 28 Y 11 M 11 D / F	OP/IP No	: IP/414892/2533E
Max ID/Mobile	: SKCT.378925/9595564544	Collection Date/Time	: 05/Jul/2021 04:35PM
Lab ID	: 0832072105339	Receiving Date	: 05/Jul/2021
Ref Doctor	: Vivek Marwah	Reporting Date	: 08/Jul/2021

Histopathology

PAGE - 43

Histo Biopsy Fallopian Tube

Histopathology Number:
S-9850/21 (FS - 742/21)

Specimen Type:

- 1) Myoma (FS)
- 2) Endometrium
- 3) Left ovarian cyst wall
- 4) Right ovarian cyst wall
- 5) Endometriotic nodule
- 6) Adenomyoma
- 7) Myoma
- 8) Left fallopian tube

Clinical Data / Impression:

Not submitted

Gross Description:

- 1) Myoma (FS) - Specimen measuring 1 x 0.6 x 0.4 cm. (A - ETP)
- 2) Endometrium - Single grey white soft tissue bit measuring 1.5 x 0.7 x 0.5 cm. (B - ETP)
- 3) Left ovarian cyst wall - Multiple cystic tissue pieces altogether measuring 6 x 5 x 2 cm. (C to D - RBP)
- 4) Right ovarian cyst wall - Multiple cystic tissue pieces altogether measuring 8 x 6 x 5 cm. (E to F - RBP)
- 5) Endometriotic nodule - Two grey white soft tissue bits together measuring 2 x 1.5 x 1 cm. (G - ETP)
- 6) Adenomyoma - Single grey white soft tissue bit measuring 2.5 x 1.2 x 0.7 cm. (H - ETP)
- 7) Myoma - Multiple morcellated soft tissue bits altogether measuring 9 x 5 x 4.5 cm. (I, J - RBP)
- 8) Left fallopian tube - Single tubular tissue piece measuring 8 x 4 x 2 cm. (K to L - RBP)

Frozen Section Report:

Myoma - Spindle cell lesion, likely leiomyoma.

Microscopic Examination:

- 1) Endometrium:
 - Proliferative Endometrium.
 - Negative for endometritis, granuloma or malignancy.

Self Attested
@
22/12/23



SIN No:ms0616724, Test Performed at :910 - Max Hospital - Saket M S S H, Press Enclave Road, Mandir Marg, Saket, New Delhi, Delhi 110017
 Booking Centre :1103 - Max Hospital Saket (East Block), 1, 2, Press Enclave Marg, Saket Institutional Area, Saket, New Delhi





Laboratory Investigation Report

Patient Name	: Ms. Tanu Priya Jaiswal	Centre	1103 - Max Hospital Saket(East Block)
Age/Gender	: 28 Y 11 M 11 D /F	OP/IP No	IP/414892/2533E
Max ID/Mobile	: SKCT.378925/9595564544	Collection Date/Time	05/Jul/2021 04:35PM
Lab ID	: 0832072105339	Receiving Date	05/Jul/2021
Ref Doctor	: Vivek Marwah	Reporting Date	08/Jul/2021

Histopathology


PAGE - 44

- 2) Left ovarian cyst wall:
 - Endometriotic ovarian cyst with hemosiderophages.
 - Negative for neoplasia.
- 3) Right ovarian cyst wall:
 - Chronic hemosiderotic cyst – consistent with endometriotic ovarian cyst.
- 4) Endometriotic nodule:
 - Fibrocollagenous tissue with occasional gland with stroma.
 - Endometriotic deposit.
- 5) Adenomyoma – Sections show composed of fascicles of spindle shaped cells with oval to spindle shaped nuclei with minimal pleomorphism. No evidence of coagulative necrosis or increased mitotic activity is noted.
 - Leiomyoma.
- 6) Myoma– Sections show composed of fascicles of spindle shaped cells with oval to spindle shaped nuclei with minimal pleomorphism.
 - No evidence of coagulative necrosis or increased mitotic activity is noted.
 - Leiomyoma.
- 7) Left fallopian tube: Tube with hemosiderophages in the plicae and marked congestion.
 - Negative for neoplasia.
 - Consistent with Hematosalpinx

** Slides & blocks for second opinion will be issued to the patient / attendant after 48 hours of submitting a formal request (Time - between 3 pm to 5 pm) (slides are chargeable)

Kindly correlate with clinical findings

*** End Of Report ***

self Attested

 22/12/23

Page 2 of 3

SIN No:ms0616724, Test Performed at :910 - Max Hospital - Saket M S S H, Press Enclave Road, Mandir Marg, Saket, New Delhi, Delhi 110017
 Booking Centre : 1103 - Max Hospital Saket(East Block), 1, 2, Press Enclave Marg, Saket Institutional Area, Saket, New Delhi



Referral slip
26/11/20

डिस्चार्ज/ रेफरल/ लामा/ मृत्यु फॉर्म (जो लागू हो उस पर सही (✓) का निशान लगाये)

स्वास्थ्य केंद्र का नाम:	DWH Ayodhya	जिला:	Ayodhya
ब्लॉक:		फोन न.:	
सेवा प्रदाता का नाम तथा हस्ताक्षर:	<i>[Signature]</i> चिकित्सक/धिकारी	PAGE - 46	

नाम:	Tanupriya	जिला पंडित चिकित्सालय माली व बेटों:	Abhishek Jaiswal	उम्र (साल):	28	एमसीटीएस न.:	9229
------	-----------	--	------------------	-------------	----	--------------	------

भर्ती की तारीख:	26/11/20	भर्ती का समय:	3:11 PM	डिस्चार्ज/रेफरल की तारीख:	26/11/20	डिस्चार्ज/रेफरल का समय:	4 PM
प्रसव की तारीख:		प्रसव का समय:		प्रसव का परिणाम:	जीवित जन्म <input type="checkbox"/>	गर्भपात <input type="checkbox"/>	एक/सिंगल <input type="checkbox"/>
				ताजा स्टिल बर्थ <input type="checkbox"/>	मैसेरेटेड स्टिल बर्थ <input type="checkbox"/>	जुड़वा/मल्टिपल <input type="checkbox"/>	

अंतिम परिणाम: डिस्चार्ज/ बाहर रेफर हुआ/ लामा/ मृत्यु/ गर्भपात
(जो लागू हो उस पर सही (✓) का निशान लगाये)

डिस्चार्ज का संक्षिप्त विवरण:	रेफरल का संक्षिप्त विवरण:
माँ की स्थिति	रेफरल का कारण <i>Po to 1° infertility & Severe anaemia & moderate fibroid uterus</i>
एफपी चुनाव (यदि दिया गया)	स्वास्थ्य सुविधा केंद्र का नाम (जहाँ रेफर हुआ) <i>CPH - VE</i>
बच्चे की स्थिति	इलाज दिया गया <i>Referred to SMH/Higher center for further management</i>
बच्चे का लिंग M <input type="checkbox"/> F <input type="checkbox"/> जन्म के समय वजन (कि.ग्रा.)	
प्री-टर्म: हाँ <input type="checkbox"/> नहीं <input type="checkbox"/> इंजेक्शन विटामिन K1: हाँ <input type="checkbox"/> नहीं <input type="checkbox"/>	
टीकाकरण: बीसीजी <input type="checkbox"/> ओपीवी <input type="checkbox"/> हेपाटाइटिस बी <input type="checkbox"/>	
डिस्चार्ज के समय सलाह:	
<input type="checkbox"/> माँ और बच्चे में खतरे के लक्षण के बारे में काउन्सिलिंग हुई	
<input type="checkbox"/> आराम, पोषण और अधिक मात्रा में तरल पदार्थ	
<input type="checkbox"/> आयरन की गोली <input type="checkbox"/> कैल्शियम की गोली.....	
इलाज दिया गया	

डिस्चार्ज/ रेफरल/ मृत्यु के नोट्स

Saf Attested
@
22/12/23

Hb 8.1 gm %
B - ve
HIV
HBSAg
HCV
VDRL } NR

Mr. Tanu Arora

28/11

1/11/2020

of Per L Low P12
 E Low manual PAGE-47

1/11/2020 - 1st 20-35
 2nd 20-35
 3rd 21/11

Per L L AM
 3rd manual

0/11/2020 m2 = 3 1/2
 m 1/2 AM / 4 1/2
 m 1/2 AM / 4 1/2
 m 1/2 AM / 4 1/2

1/11/2020 - Vase P12 (AM)
 4-6 x 4-1 x 2-8 cm AM
 4-0 x 3-5 cm Intely
 4-5 cm Intely
 4-8 x 3-1 - 2-9 cm
 5-2 x 6-6 x 6-2 cm
 1/2 Over Intely
 2 AM By Dr. Marwah

Q. T. Marwah + 1/11/2020
 19/11/2020
 Self Attested
 @
 22/11/23



DIVISION OF MINIMALLY INVASIVE GYNAECOLOGY
INSTITUTE OF MINIMAL ACCESS, METABOLIC & BARIATRIC SURGERY
MAX HEALTH CARE, SAKET, INDIA
Investigations advised

<input checked="" type="checkbox"/> • CBC	<input checked="" type="checkbox"/> • Ultrasound Pelvis (T.A / T.V.S)
<input checked="" type="checkbox"/> • Blood Sugar - Fasting / Post Prandial (R)	<input checked="" type="checkbox"/> • Ultrasound (K.U.B) - Pre void / Post void
<input type="checkbox"/> • BUN / Creatinine	<input checked="" type="checkbox"/> • MRI Pelvis (Sagittal Section Preferred)
<input type="checkbox"/> • HbA1c (R T-PLA-COVID)	<input type="checkbox"/> • Ultrasound Whole Abdomen
<input type="checkbox"/> • Serum Bilirubin	<input type="checkbox"/> • MRI Whole Abdomen
<input type="checkbox"/> • TSH	<input checked="" type="checkbox"/> • X Ray Chest (PA)
<input checked="" type="checkbox"/> • HBsAg	<input checked="" type="checkbox"/> • ECG
<input checked="" type="checkbox"/> • HCV	<input type="checkbox"/> • Venous Doppler
<input checked="" type="checkbox"/> • HIV	<input type="checkbox"/> • Stress Echo (TM / Dobutamine)
<input checked="" type="checkbox"/> • PT / INR, APTT	<input type="checkbox"/> • 2 D echo
<input checked="" type="checkbox"/> • L.F.T	<input type="checkbox"/> • LDH
<input checked="" type="checkbox"/> • K.F.T	<input checked="" type="checkbox"/> • S. AMH
<input checked="" type="checkbox"/> • Urine Routine	<input type="checkbox"/> • CA - 125
<input checked="" type="checkbox"/> • Blood Group / Rh Factor	<input type="checkbox"/> • FSH
	<input checked="" type="checkbox"/> • HE4
	<input checked="" type="checkbox"/> • CA19.9
	<input type="checkbox"/> • LH
	<input type="checkbox"/> • INHIBIN B
	<input type="checkbox"/> • AFP
	<input type="checkbox"/> • CEA

INVESTIGATIONS	CLEARANCE
Yes	<input type="checkbox"/> • Physician
No	<input type="checkbox"/> • Cardiology
	<input type="checkbox"/> • Neurology
	<input type="checkbox"/> • Nephrology
	<input type="checkbox"/> • Orthopedic

Pre Anesthetic Checkup

- Review
- Cleared

Self Attested @ 22/12/23

For insurance contact TPA Desk (Tel No. 011-40632586)
 For admission booking kindly contact (Shradha / Nancy)
 (Mon to Fri between (10am - 6pm) and Sat between (10am - 4pm)
 Mob No. +91 - 9999668700, 9999668200 / 011 - 40632588 , 40632594
 For contacting Dr. Vivek Marwah call (between 7pm - 8pm)

Max Super Speciality Hospital, Saket
 (East Block) - A Unit of Devki Devi Foundation
 (Devki Devi Foundation registered under the Societies Registration Act XXI of 1860)
 Regd. Office: 2, Press Enclave Road, Saket, New Delhi-110 017
 For medical service queries or appointments, call: +91-11 2651 5050
 Fax: +91-11-2651 0050

Dr. Sunami
 9818152802



VIRTUAL CONSULTATION PRESCRIPTION

PAGE - 49

Dr Vivek Marwah

MBBS, MS (Gynae), Course in IVF-ET, Dip. in Operative Pelviscopy

Address: Max Hospital

Mobile: 8860444888

Email: info@maxhealthcare.com

Consult Date/Time: 23/11/2020 11.20 AM

Patient Name: TANU PRIYA JAISWAL

Age: 28 / **Sex:** Female

Address: J-81 GOVINDPURAM

COMPLAINTS AND BRIEF HISTORY:

Myoma uteri with ovarian endometriosis

MEDICINES & TESTS ADVISED:

Rx

Advised Laparoscopic management of endometriosis with Myomectomy

For investigations and dates can contact Dr Surabhi at Max Hospital Saket East block 5th floor at 09818152807.

For estimate kindly contact TPA desk at Max Hospital Saket East block 5th floor at 01140632586.

This prescription generated is provided basis the virtual consultation done between the patient and doctor, relying on patient declaration during the consultation, patient notes & documents provided prior to the consultation.

This is an electronically authorized prescription, hence does not require a signature.

Reference Number: MH131448

*Self Attested
@
22/12/23*

Dr. Priyanka Khare

M.B.B.S., M.S.
OBSTETRICS & GYNAECOLOGY
Reg. No. No-55229/M.B.B.S.
3645 / M.S.

डा. प्रियंका खरे
एम.बी.वी.एस., एम.एस. (सर्जन)
प्रसूति एवं स्त्री रोग विशेषज्ञ
रजि. नं. No-55229/M.B.B.S.
3645 / M.S.

PAGE - 50

Name

Tanu priya

Date... 13/11/20

Age.....Wt.....

R

6 off for 1m 10
x 1m

24/10/20

↓
6/11/20

du

to Crinos NSCR 1m x 2day
8pm

to MCR 1m x 3d

to Dolamin plus (4)

↓

to Flugs 10mg - (Friday)

↓
(Monday)

↓
(Thurs)

to Flugs 15mg - (Monday)

↓
(Thurs)

x 4 weeks

(AMN) - Prep

(Prep)

Self Attested

@
22/12/23

लोक प्रिया हॉस्पिटल

निकट सेल्स टैक्स ऑफिस, नैखर कालोनी, मोदह चौराहा, सिविल लाइन्स, फौजाबाद-अयोध्या 224001

मरीज देखने का समय: :: प्रातः 10 बजे से दोपहर 02 बजे तक :: सायं 06 बजे से रात्रि 08 बजे तक

माह का प्रत्येक शनिवार पूर्ण अवकाश
इमरजेन्सी सेवार्थे डाक्टर के रहने पर ही होगी।

मो0 नं0 - 7084177500



27/73 A, Church Road, Civil Lines, Agra 282002

Dr. Mukesh Chandra
डॉ. मुकेश चन्द्रा

PROFESSOR & Head Of Dept
OBSTETRICS & GYNAECOLOGY
FH Medical College Tundla

PROFESSOR(Retd.)
DEPARTMENT OF OBSTETRICS & GYNAECOLOGY
S.N. MEDICAL COLLEGE & HOSPITAL, AGRA - 282002

M.S. (Ob/Gyn), Ph.D. Sch (Obstetrics & Gynaecology),
M.A.M.S., F.I.C.O.G., F.I.C.M.C.H., F.I.C.M.U.
DIPLOMA LAPAROSCOPIC SURGERY (Germany)
CERT. DIAGNOSTIC ULTRASONOGRAPHY (NEW ZEALAND)

HONORARY MEDICAL ADVISOR / CONSULTANT - ARMED FORCES
MEMBER, NATIONAL ACADEMY OF MEDICAL SCIENCES
FORMERLY
* LECTURER, Dept. Of Obstetrics & Gynaecology, S M S MEDICAL COLLEGE, JAIPUR
* LECTURER, Dept. Of Obstetrics & Gynaecology, M.L.B. MEDICAL COLLEGE, JHANSI
ETHICON FELLOW:
* Visiting FELLOW, Gynaecological Cancer Unit, TATA MEMORIAL HOSPITAL, BOMBAY
* Visiting FELLOW, Dept. Of Obstetrics & Gynaecology, All India Institute Of Medical Sciences, New Delh
* Visiting FELLOW, Indian Institute for research in Reproduction (ICMR), BOMBAY
* Fellow, INDIAN COLLEGE OF OBSTETRICIAN & GYNAECOLOGISTS
* FOUNDER FELLOW, INDIAN COLLEGE OF MEDICAL ULTRASOUND
* FELLOW, INDIAN COLLEGE OF MATERNAL & CHILD HEALTH
* INSTRUCTOR, Laparoscopy Training Ministry of Health & Family Welfare, Govt. of UTTAR PRADESH
* MASTER TRAINER, SIFPSA & RCH - II
* MEMBER, International Federation of Obstetrics & Gynaecology
* MEMBER, Asian Federation of Obstetrics & Gynaecology
* MEMBER, Indian Academy of Human Reproduction
* MEMBER, Indian Academy of Juvenile & Adolescent Gynaecology & Obstetrics
* MEMBER, Indian Federation of Ultrasound in Medicine and Biology
* MEMBER, Indian Association of Gynaecological Oncology
* MEMBER, National Association of Voluntary Sterilization of INDIA
* MEMBER, Indian Association of Fertility & Sterility
* MEMBER, Indian Association of Gynaecological Endoscopy
* MEMBER, Indian Association of Human Reproduction
* MEMBER, India Medical Association
* President, Agra Obstetrics & Gynaecological Society
Registration No. 21215 / UP

PAGE - 51

Phone: 0562-2520022, 2523000

EMAIL : mukesh.chandra@hotmail.com | Website & Online Appointment : www.chandraclinic.com

Name TC-C1
(RI) Mrs. TANUPRIYA
FAIZABAD

Age 28 yrs
DATE 13-Sep-20



G O P O A O
LMP 31-Aug-20

Cycle Flow Dysmen Clots
28 2/Av days +ve +ve
ABO Rh Hb Urine B sugar ESR
- - - - - 94

P/V UT :- AV 18W
Cx :- NAD
Fx :- Thickened and Tender

P/A Tsh 2.37

- Notes
- 1 PRL 81.85
 - 2 USG ELSE 05AUG20 MULTIFIB B/L TOM R-93 L-83MM
 - 3 AMH 1.66
 - 4 FSH 10.98V LH 2.83

- Rx
- 1 Tab ADOVA 1 mg - Once Daily - After Breakfast X 1 Month
 - 2 Tab Visanne 2 mg - Once Daily - After Breakfast X 1 Month
 - 3 Tab DEXIBU FORTE - Twice daily - After Lunch & Dinner X 1 Month
 - 4 Cap DANOGEN 100 mg - Once Daily - At Bedtime X 1 Month
 - 5 Cap ENDOGEST SR 300 mg - Once Daily - At Bedtime X 1 Month
 - 6 Tab SICRIPTINE 1.25 mcg - Once Daily - At Bedtime X 1 Month

- Complaints :
- 1 NO ISSUE
 - 2 MD 2017
 - 3 PAIN IN BOTH ILIAC FOSSA

- Investigation
- 1 COLOR DOPPLER 13-Sep-20
 - 2 SERUM PROLACTIN 13-Sep-20
 - 3 CA125 13-Sep-20
 - 4. Quantiferon Gold

Procedures
1

Precaution
1

Self Attended @ 22/12/23

Clinical Impression **Primary Sterility**

Next Appointment Date **13 - Oct - 20**

Please reconfirm your appointment by 08-Oct-2020



अ० भा० आ० सं० अस्पताल / A.I.I.M.S. HOSPITAL
 वहिरंग रोगी विभाग / Out Patient Department
 अस्पताल के अन्दर धूम्रपान मना है / SMOKING IS PROHIBITED IN HOSPITAL PREMISES

एकक / Unit
 विभाग / Dept.

OPR-6

PAGE - 52

न० रोगी/पंजीकृत सं० / O.P.D. Regn. No.

नाम / Name	पिता, पुत्र/पत्नी/पुत्री F/S/W/D of	लिंग Sex	वय Age	पता / Address
Tanu Kiyra	Abhishek	F	27 yrs	Fairabad.

निदान / Diagnosis

Pym c/o. Dysmenorrhea. x three months.

दिनांक / Date

उपचार / Treatment

02/01/23

M/W: Regular, 2-3d, avg flow, severe dysmenorrhea
 28-30d
 2pac/d (+)

LMP: → 3/7/2020

QW: → MFX 3yrs

not sitting together. (Analysing)
 on & off trying.

QW: → It currently on homeopathic off x 3 months
 is had mild relly.

H/O: 7 OCP mistake on & off x few years

H/O 2nd dysparea mistake x March & June.

no mo tb/ dm / any other / 2/65
 (none) for dysmenorrhea

QW: NAD

Self Attested
 @

21/12/23

CLEAN AND GREEN AIIMS / एम्स का यही संकल्प, स्वच्छता से काया कल्प

अंगदान-जीवन का बहुमूल्य उपहार / ORGAN DONATION - A GIFT OF LIFE

O.R.B.O., AIIMS, 26588360, 26593444, www.orbo.org Helpline - 1060 (24 hrs service)

4/07/20

Rt. is a case of severe endometriosis (Ad IV) as per u/s

Issue - infertility
chr. pelvic pain

Bodulini reserves - B/c endometrioma

Option given earlier
menstr. Sp → IVF

however, poor prognosis of IVF in v/o adenomyosis

A/c endometrioma

Currently Pandemic situation - NO O:T (elective Sp) available

Option for pain relief
1. DINOGEST 2mg once a day

Hb%:

Neema

To follow after 3 months

01/07/2021

Reviewed MRI - s/o DIE & B/c endometrioma 3x30mm

Plan: Fibroid clearing prior to IVF

Endometrioma - cystectomy

Adenomyoma - adenomyectomy

Contra - 2 x 2 shot when IVF "Neg"

USG (10/5/2020)

Un bulky Mv

PAGE - 53

multiple fibroids

ant - 18 x 14 mm.

Post - 48 x 31 mm.

ET - 6 mm

B/c endometriosis

⊙ - 28 x 24 mm
⊙ - 30 x 26 mm
⊙ - 35 x 30 mm

⊙ - 40 x 26 mm
⊙ - 51 x 33 mm

S. AMN → 1.66 (13/5/2020)

USG (24/5/2020)

Un E fibroids

ant wall - 20 x 16 mm

post wall - 46 x 36 mm

ET - 7.9 mm

B/c endometriosis

⊙ - 50 x 44 mm
⊙ - 31 x 35 mm
⊙ - 42 x 41 mm

⊙ - 33 x 27 mm

Self Attested
@
22/12/20



M KRISHNA MEDICAL CENTRE

(ISO 9001 : 2008 Certified)

1, Rana Pratap Marg, Lucknow, Phones : 2616064, 2628823

शुक्रादि
Ecoent Hnee

pg. 15 (2020)

Dr Chandravati

DGO, MS, DFPA (Eng) FICS, FICMCH
Professor Emeritus &
Head of the Department (Retd.)
Department of Obstetrics & Gynaecology,
King George's Medical University, Lucknow

o/w large Endometriosis
Tanu priya

Date: 10/5/20
27/5
und 10/5
10/6

PAGE-54

2A 12/5
z Tet vac

z : Emanon → 100 / mg 100
: Aciloc 1800
z . Dinogal 2mg amp
fave 0.2g

24/5 z Cabg din 1.5 mg weekly p 20/16

Self Attested
@
22/12/23

OBSTETRICS & GYNAECOLOGY
PEDIATRICS
00 MA X-RAY

ASSISTED REPRODUCTION (IVF)
 ENT SURGERY
 ULTRASOUND

NEUROSURGERY
 PATHOLOGY
 MAMMOGRAPHY

GENERAL SURGERY
 ENDOSCOPIC SURGERY
 BONE DENSITOMETRY

CONSULTATION :: MORNING : 11 AM TO 1:00 PM EVENING : 5:00 PM TO 8:00 PM - SUNDAY : 10:00 AM TO 1:00 PM
SATURDAY EMERGENCY ONLY

male 3 yr
Poto

unp $\frac{D2}{3\text{-day req?}}$
fix (20-30 days)
pys#
D74
fly | MES
M

$\frac{yo}{want}$ $\frac{we}{lower}$
pain in
abd:
:

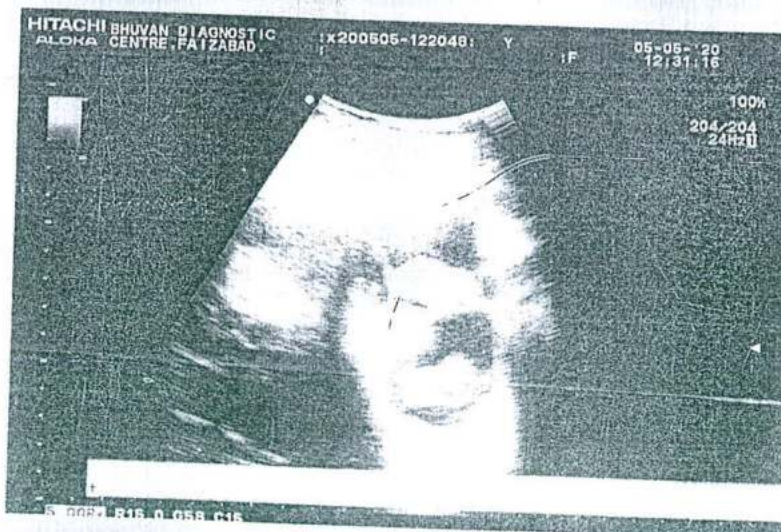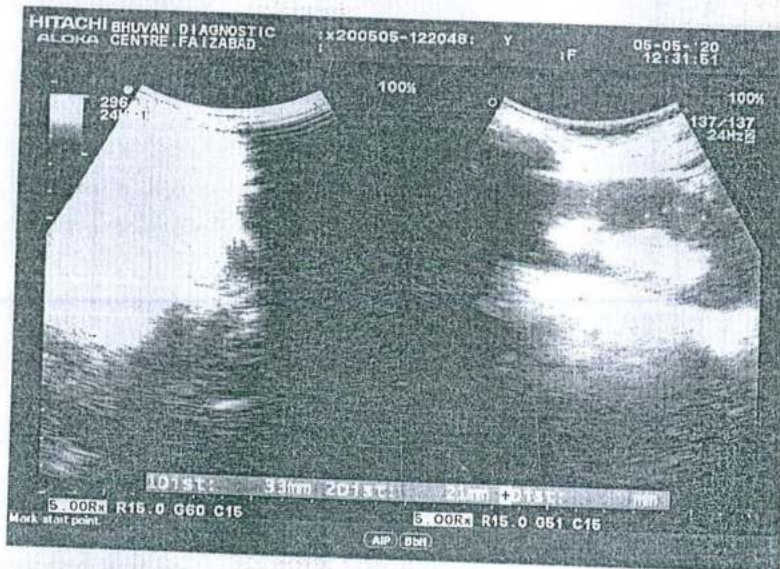
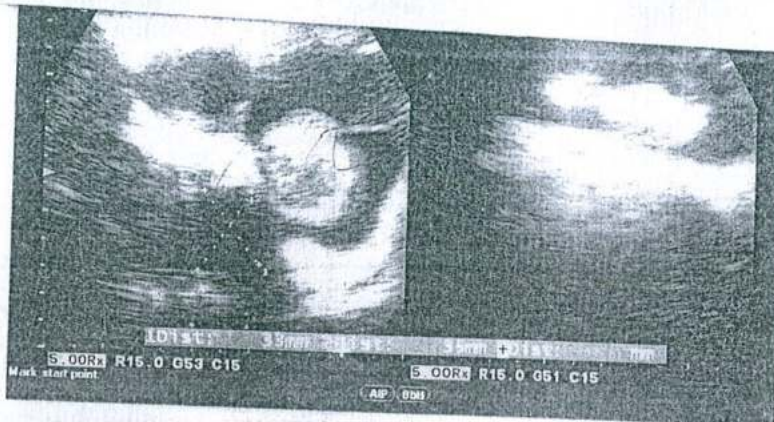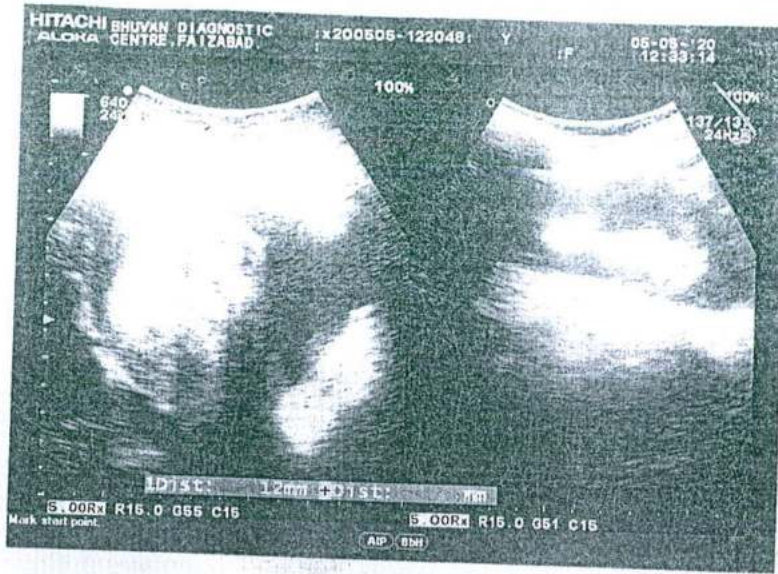
testament rights
+ Am
unad male
CA: 125
D2
8 progeet 2ax.

Lapra hyster 08-09
Cytology 2009 intravey
D567

cannot be caused
done due to cause

Semen Analy - 3002
TVS

Self Attested
@
22/12/23



DIAGNOSTIC

AN ROAD, REKABG

le Body CT Scan With
Ultrasonography & Digit

PAGE - 56

Date

Age & Sex.

the lower abdomen done in

shape and thickness of wal
en in lumen of urinary blac

m x 39mm).
size shape without any mas
Myometrial is normal.
ed.

L maximum size 65 x 82 r
mm x 22 mm seen in righ

maximum size 37 mm x 4
x 33 mm & 33 mm x 35 n
ent in cyst no 2nd & 3rd.

seen in pouch of douglas.

BOTH OVARIES.

Self Attested
@
22/12/20
Senior
MBBS.

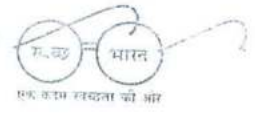may not be picked up always o
tion with clinical findings and other
purpose.

abilities and it is only opinion, not fi

of various shadows produced by bo



श्री ०- शमशेर जी
AIIMS HOSPITAL
 बहिरंग रागी विभाग / Out Patient Department



शरीरभाघं खलु धर्मसाधनम्

अस्प

New Patient

MISES

Dept Reg. 2020/010/0006062

General/र 10

Obs and Gynae/Obs. and Gynae/Unit-III

कमरा/Room: 4 obs

OPR-6

नाम: टनु प्रिया जैसवाल

Days : Wed, Sat (बुध, शनि)

Name: Mrs TANU PRIYA JAISWAL

Queue No : N14

legn. No.

पति : अभिशेक जैसवाल

27Y महिला/F

पता/Address

W/O ABHISHEK JAISWAL

Ph. 9595564544



UHID : 105114001

Date: 26/02/2020

PAGE - 57

निदान/Diagnosis

दिनांक/Date
26/8/20

उपचार/Treatment

C/O- severe dysmenorrhoea
 Since menarche.
 - decreased flow during menses
 - Blood stained discharge x 2-3 yrs
 (Post coital also)

M/H :- LMP - 8/2/20
 Prev. cycles regular, 2-3d, Pain ⊕, clots
 28-30d
 decreased flow (1-2 pads/d)

O/H :- MFX 3 yrs
 Not trying for conception

P/U
 -
 F/U - NS

Self Attended
 @
 22/12/23

CLEAN AND GREEN AIIMS / एम्स का यही संकल्प, स्वच्छता से काय कल्प

अंगदान-जीवन का बहुमूल्य उपहार / ORGAN DONATION - A GIFT OF LIFE

AIIMS, 26586360, 26593444, www.orbo.org Helpline - 1060 (24 hrs service)



meraaspatal.aiims.gov.in

Rubella IgG.
 Serum { FSH }
 { LH }

MONDAY →
 10.00 - 11.00 AM

* Semen analysis
 (IVF Lab)

w/s Pelvis in IVF K. ~~see~~ access
 PAGE-58
 (g drains, Pfc
 adenomyosis @ 40 g cavity)

✓ Cap A to Z 1000 -
 ✓ Cap BQ - 300mg once/day }

• AMH (post.
 6we
 1.1 ng/ml)

≈ Maxora - L. sachet once daily (for husband)

Reps for
 IVF
 Neer

Neer

Plan:- Against cycle
 @ AMH - 375
 after semen q/s

Adv

3/9/2021
 FSH - 7.15
 LH - 0.3 mIU/ml
 Rubella IgG < 0.02.

- inj. Rubivac Lamp stat.
 or MMR Lamp stat
- semen q/s
- ✓ - USA after 3-5 days
 of abstinence (IVF Lab)
- ✓ - HIV, HBsAg, HCV, VDRL
 for husband
- ✓ - VDRL (CP)

• Id consent
 (Ms Mary)

② - ⑤
 2300202
 09/09/21

self attested

@
 22/12/23

Anshu
 CA

Reg. Date/Time: 20/02/2020 15:27:44



Patient ID : 101947003
Patient Name : Mrs. TANUPRIYA
Age / Sex : 27 Yrs Female
Ref. By : SELF

Sample Received On :
Reported On : 20/02/2020 16:29:43
Sample Type :

USG TVS

PAGE - 59

Uterus is anteverted, normal in size and shows normal echotexture.

Posterior myometrium shows heterogeneous echotexture with multiple cysts s/o adenomyosis.

The endometrium measures 14 mm.

Multiple chocolate cysts are seen in left ovary, largest ones measuring approx. 26 x 26 mm, 28 x 15 mm, 23 x 16 mm, 53 x 30 mm & 56 x 42 mm.

Multiple chocolate cysts are seen in right ovary, largest ones measuring approx. 82 x 55 mm, 56 x 50 mm, 35 x 34 mm & 24 x 20 mm.

Right ovary measures 102 x 84 x 90 mm (Volume 407 cc).

Left ovary measures 74 x 61 x 57 mm (Volume 138.7 cc).

No free fluid is seen in Pouch of Douglas.

Please correlate clinically.

Sch: MRI Pelvis

Self Attested
@
22/12/23

*** End of Report ***

DR. VINEET SETHIA
MD. Radiology
Sr. Consultant Radiologist

DR. MADHU AGARWAL
MD Radiology
Consultant Radiologist

DR. DIVYA GOEL
MBBS, MD (Radiodiagnosis)
Consultant Radiologist

DR. MADHU

Page No. 1 of 1

34, 36, Mall Road GTB Nagar, Near GTB Nagar Metro Gate No. 3, Delhi-110009

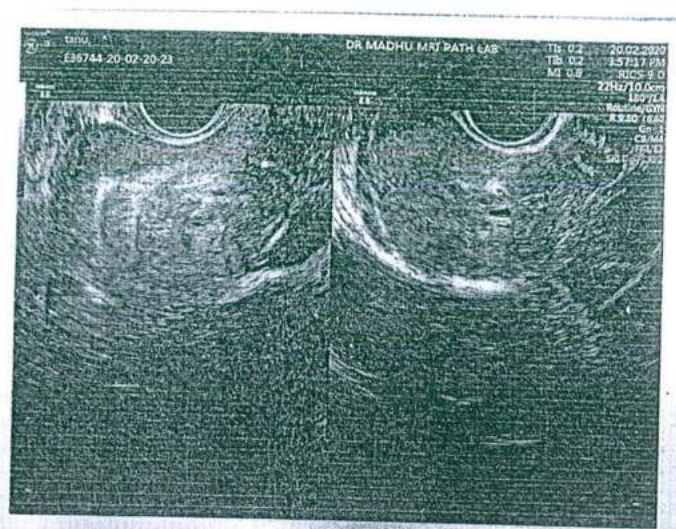
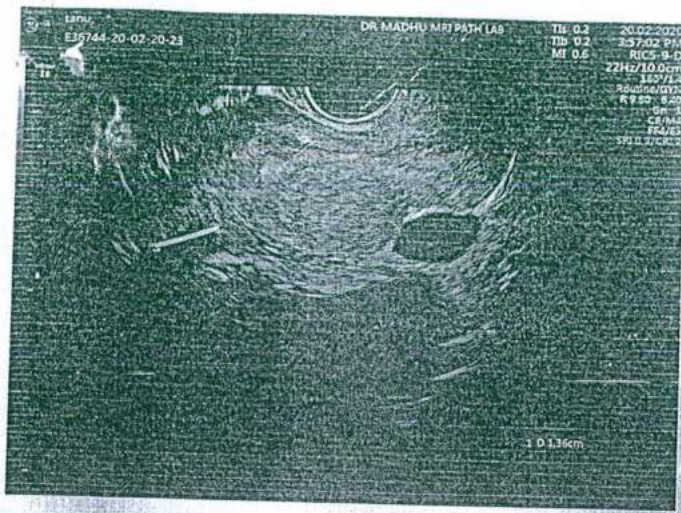MRI PATH LAB.

F19-A, Vijay Nagar, Near GTB Nagar Metro Gate No.4, Opp. Tata Power, Delhi-110009

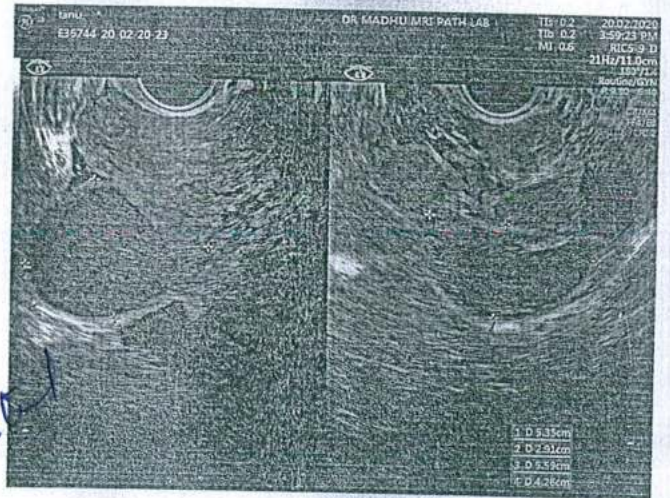
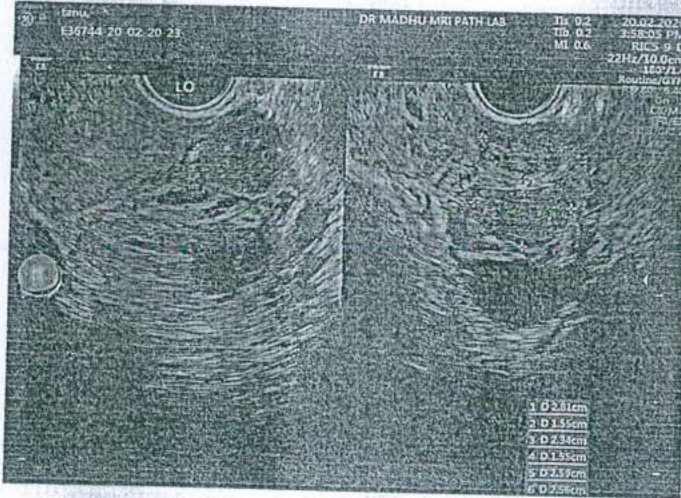
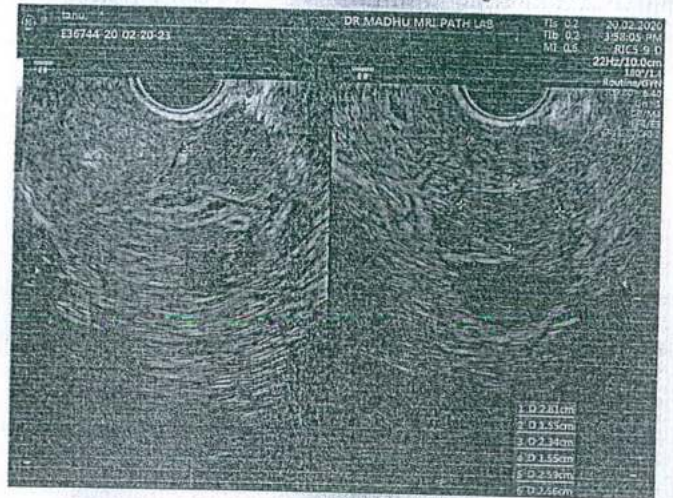
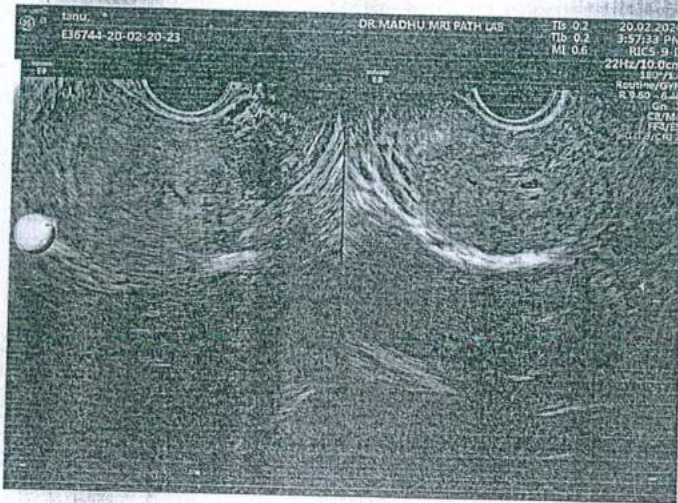
9415268438

Note: This Report is subject to the terms and conditions mentioned overleaf
PARTIAL REPRODUCTION OF THIS REPORT IS NOT PERMITTED

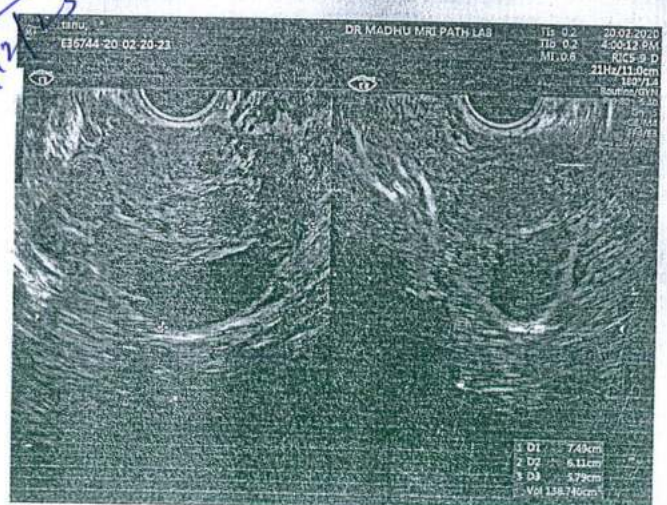
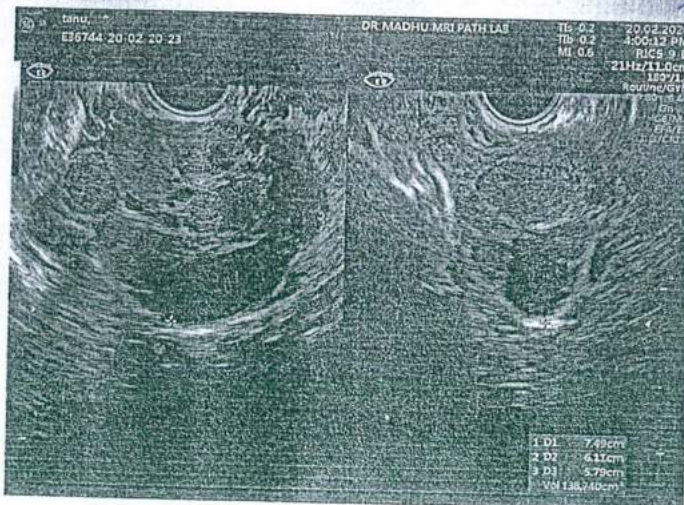




PAGE - 60



Sub Attended
@
22/12/23



Reg. Date/Time : 07/06/2018 / 09:40:44

Patient ID :	10189672	Husband/ Fathers Name :	
Patient Name :	Mrs. TANUPRIYA	Sample Received On :	
Age / Sex :	25 Yrs	Female	
Ref. By :	SELF	Reported On :	07/06/2018 11:23:00
Patient Address :			



USG TVS

PAGE - 61

Uterus is anteverted normal in size and shows normal echotexture.

Endometrial Thickness: 17.4 mm.

Posterior myometrium shows heterogeneous echotexture suggestive of adenomyosis.

Five - six chocolate cysts are seen in right ovary, measuring approx. 3.6 x 3.2cm, 2.7 x 1.7cm, 2.4 x 1.7cm, 1.6 x 1.5cm and 1.7 x 1.5cm in size.

Six - Seven chocolate cysts are seen in left ovary, measuring approx. 5.0 x 3.2cm, 3.0 x 2.2cm, 2.4 x 1.2cm, 5.6 x 3.5cm, 4.3 x 3.5cm, 2.5cm and 1.9cm.

No free fluid is seen in Pouch of Douglas.

Please correlate clinically

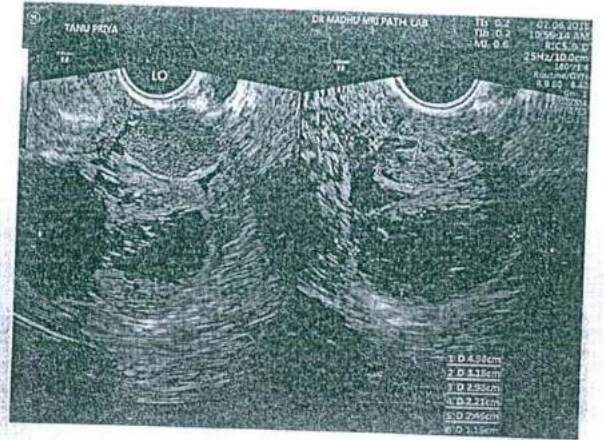
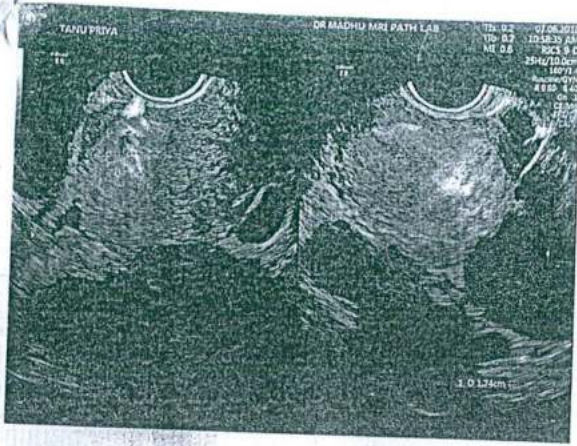
Self Attested
@
22/12/23

*** End of Report ***

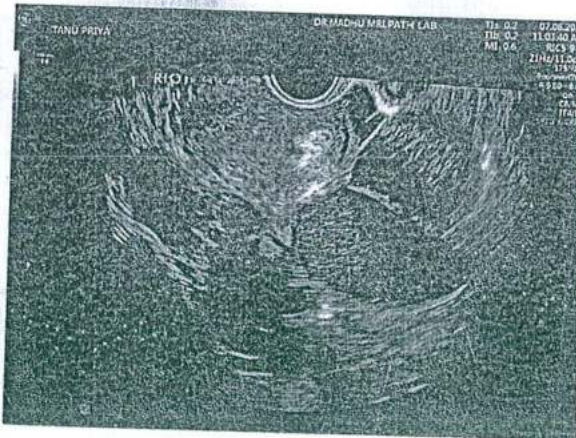

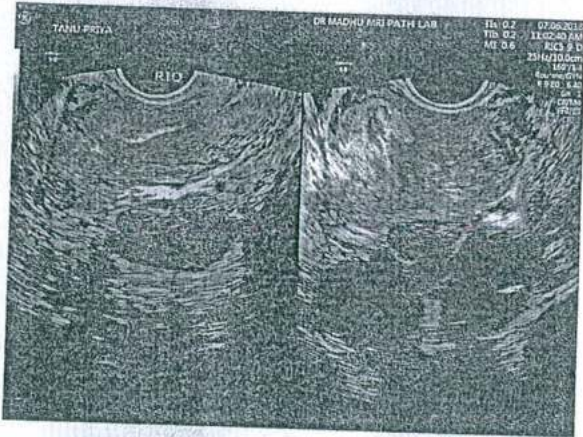
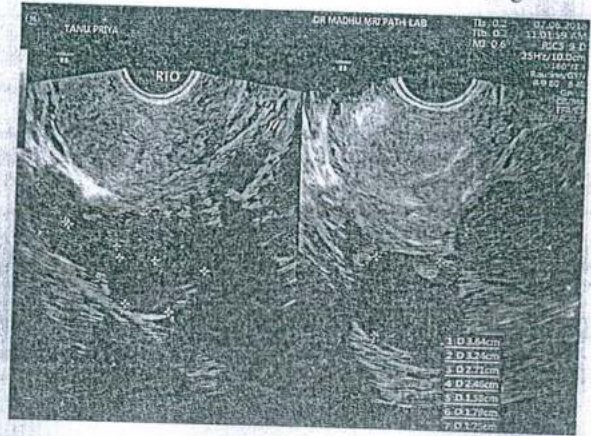
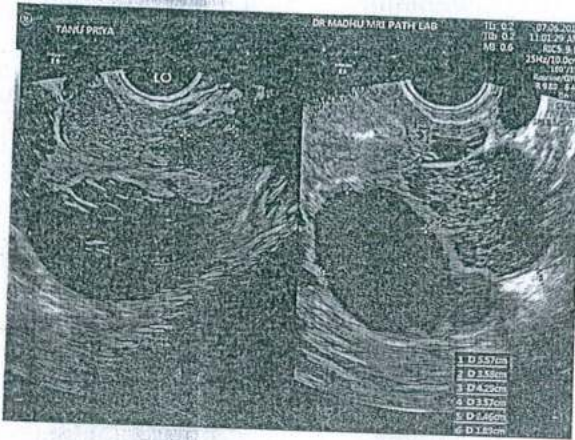
DR. PRIYANKA GHURE
MD, RADIOLOGY
CONSULTANT RADIOLOGIST

DR. MADHU AGARWAL
MD Radiology
Consultant Radiologist

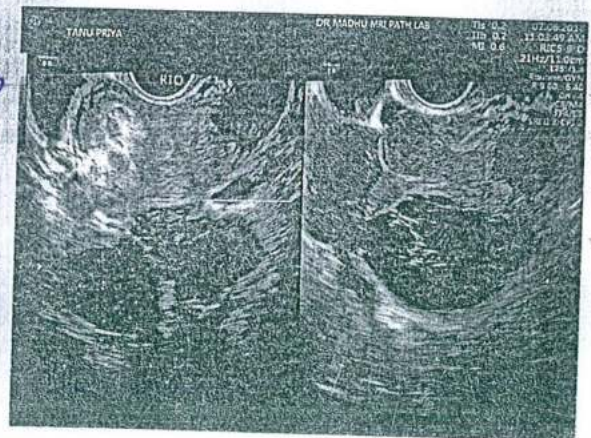
Dr. Awnish Kumar
Consultant Radiology(MD)



PAGE - 62



self Attended @ 22/12/23



gap period - [2 yrs]

Patients Name	Mrs. Tanu Priya	Date : 07-01-18
Age/Sex	25Y/Female	
Referred By	Hindu Rao Hospital	

PAGE-63

U/S UPPER ABDOMEN

Liver is normal in size and normal echotexture. Hepatic vasculature and intrahepatic biliary radicles are normal.

Gall bladder is normal in size and with normal wall thickness. No evidence of any calculus or space occupying lesion seen. No pericholecystic collection seen.

Common Bile Duct and Portal Vein are normal.
 Pancreas is normal in size and echotexture.
 Paraaortic region is normal.

Right kidney is normal in size, shape, outline and parenchymal echotexture.
 Pelvicalyceal system appears normal. No calculus or space occupying lesion seen in right kidney.

Left kidney is normal in size, shape, outline and parenchymal echotexture.
 Pelvicalyceal system appears normal. No calculus or space occupying lesion seen in left kidney.

Splenic echotexture and size are normal.
 No free fluid seen in abdomen.

IMPRESSION : NORMAL STUDY.

self Attested
 @
 22/12/23

Dr. Madhu Agarwal,
 MD, Radiology,
 Consultant Radiologist.

Thanks for your visit



Patients Name	Mrs. Tanu Priya	Date : 07-01-18
Age/Sex	25Y/Female	
Referred By	Hindu Rao Hospital	

PAGE-64

U/S LOWER ABDOMEN

Uterus is anteverted normal in size and echotexture.
Endometrial Thickness : 10 mm.

Posterior myometrium shows heterogeneous echotexture s/o adenomyosis.

Five-six chocolate cysts seen in right ovary measuring 3.5 x 2.8 cm, 2.0 x 1.5 cm, 2.0 x 1.7 cm, 1.5 cm and 1 cm in size.

Six-seven chocolate cysts seen in left ovary measuring 5.0 x 4.0 cm, 2.6 x 2.2 cm, 1.8 x 1.7 cm, 2.0 x 1.5 cm, 2.2 x 1.5 cm and 2 cm in size.

Right ovary measures : 6.4 x 3.8 x 5.5 cm.

Volume : 72.5 cc.

Left ovary measures : 7.7 x 5.1 x 7.4 cm.

Volume : 155 cc.

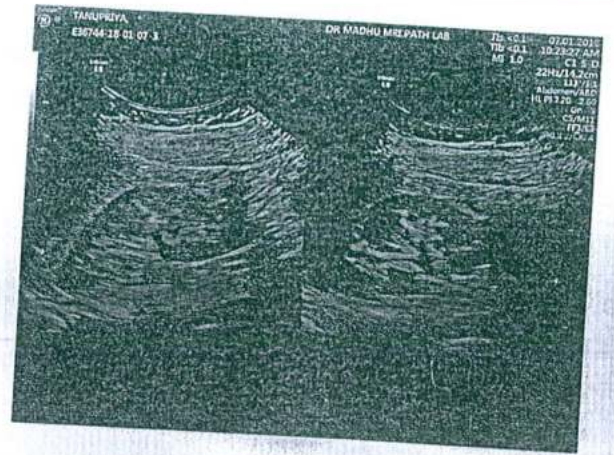
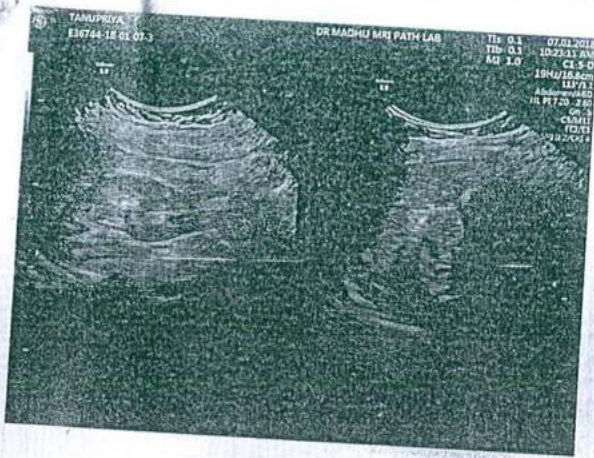No free fluid seen in pouch of douglas.

Urinary bladder is normal in outline, shape and volume.

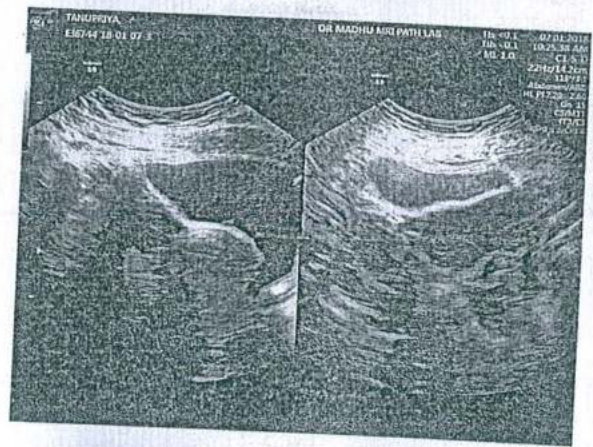
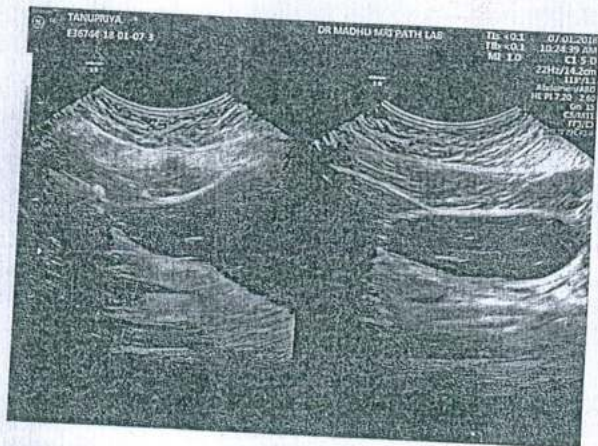
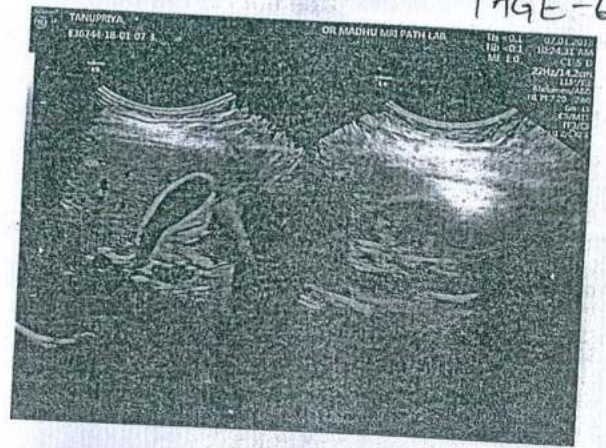
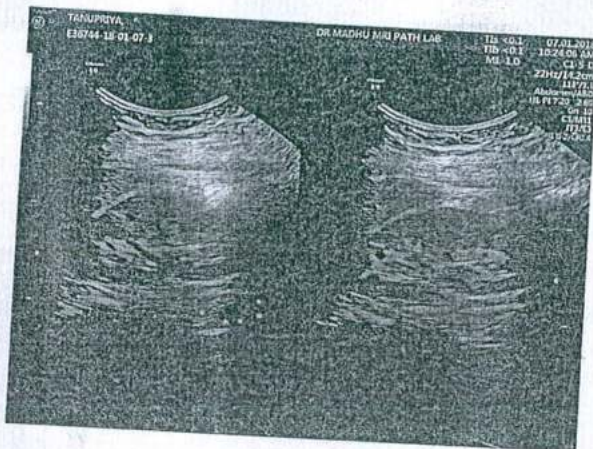
Self Attested
@
22/12/23

Thanks for your visit

[Signature]
Dr. Madhu Agarwal,
MD, Radiology,
Consultant Radiologist.



PAGE-65



Copy Here @ 24/1/18

