

VARDHMAN TRAUMA & LAPAROSCOPY CENTRE PVT. LTD.

Dr. NUTAN JAIN
 M.B.B.S., M.S., F.I.C.O.G., F.I.C.M.C.H.
ADVANCE LAPAROSCOPIC SURGEON
 INTERNATIONAL MEMBERSHIPS :

- * Elected Board Member of International Society of Gynaecological Endoscopy (ISGE)
- * Nominated for Board of Trustee for (AAGL)
- * American Society For Reproductive Medicine (ASRM)
- * All American Gynae Laproscopist (AAGL)
- * International Society For Gynaecological Endoscopy (ISGE)
- * World Association of Laparoscopic Surgeons - (WALS)
- * Author of World Renowned Text Books of Laparoscopic Surgeries

Dr. VANDANA JAIN
 M.B.B.S., M.S.
INFERTILITY AND IVF SPECIALIST

NATIONAL MEMBERSHIP :

- * Indian Association of Gynaecological Endoscopist (IAGE)
- * Indian Society For Assisted Reproduction (ISAR)
- * Indian Academy of Human Reproduction (IAHR)
- * National Association for Reproductive and Child Health of India (NARCHI)
- * Indian Federation of Ultrasound in Medicine & Biology (IFUMB)
- * Indian Fertility Society (IFS)
- * Society of Endoscopic & Laparoscopic Surgeons of India (SELSI)
- * Masters Award for Excellence in Laparoscopic Surgery

Date & Time : 27/12/22 Aadhar No. :

Name : Shweta Nain UHID : 44729 City : Local Husband : Job SRE

D.O.B. : 27/10/94

Age : 28yrs

ML : 1yr

Parity : POAOLs

LMP : 18/12/22

Day : D/10

Chief Complaints
Wants Conception

Rt has been Equip + working w-Job in SRE

Took AKTX 6mths
 (Lungs TB)
 @ 16-17yrs of age

(H/O Pul TB in child hood)

MH - Reg - 5/26-27
Flow - (N) days
Dysm (+) Dysu (-)
Dysp (+) Dysch (+)

HSG (30/11/22)
B/L No spillage

USG (TV) - 23/11/22
 ? small Rt. ov. chocolate cyst (25X18)mm
 ? Adherent both ovaries to uterus

USG (w. Abd) TVS - 22/8/22
 • Lt. ova. cyst (67X55)mm
 • ? Rt. ov. chocolate cyst (25X15mm)
 • ? Adherent B/L ovaries to uterus

Took T. Gabolin X3 mths.

To come on 9th - 1us/a

Investigation :

Past History : No
 DM / HTN / IHD / STROKE

Allergy : No

Previous Surgery : No

Vitals : PR - 99
 BP - 110/70
 Wt. - 44kg
 Ht. - 5.6

① Rx T. FOLVITE 1-1
T. EBEXID 1-1
 ② Bring old record of Treatment.

③ (No Negative. (Tus))

To come on 29th

TUS / NP / HSG / HSD
Investigations for Adv

ME, ECG, ABORH
HIV, HCV, HBsAg
VDRL, URE
TSH, PRL

P/A Soft
 P/w Cyst RU
 P/s Cramps @ thick white disch (+)
 Pain Scale Score : (Score 0 : No Pain, 1-3 Mild Pain, 4-7 Moderate Pain, 8-10 Severe Pain)

Nutritional Advise : Normal Diet, Low Salt, Low Fat Diet, High Calorie Diet

for post visit Loop: 11/1/23. 29/12

Follow up date : KFT - (N)
LFT - (N)

Website : www.vardhmanhospital.com Local Auth. Regst. No. : RMEE2108327 Mb - 11.8

TEL. : (0131) 2623084, 2623085, 7830803084, 7830803085 • E-MAIL : jainnutan@gmail.com

Reg. Office : C-209, Defence Colony, New Delhi-110024 • CIN : U85110DL1996PTC079982

I.V.F. Helpline : +91-9720675029 • Laproscopy Helpline : 8449579000, 8979162397

3rd Km., Jansath Road, Muzaffarnagar - 251001 (U.P.)

VARDHMAN TRAUMA & LAPAROSCOPY CENTRE PVT. LTD.

Dr. NUTAN JAIN

Dr. VANDANA JAIN

13/28/1/2023
9:15

Name: Mrs. Bhawla Nain

Age: 28 yrs ML: 1 yr

Status: POTO

Weight: 44kg

Height: 5"6 LMP: 11.1.23

Place: (Local)

ICG used: 1600 camera system

Diagnosis: Grade IV endometriosis

Treatment: VLH done on 17.1.23

- Both sides Endo cyst noted
- POD obliterated, DIE
- B/L Adhesed tubes
- (N) Uterine cavity.

Op: Placecortone 1 amp 100 00 x (10)

Op: mikacin 2 vial 1ml iv (500) 00 x 7 day

Operative Findings:

- on inserting the scope at Jain point
- Uterus is densely RV, fixed in POD. POD obliterated.
- B/L tubes and ovaries densely adherent to ovarian fossa UTS ligament, back surface of uterus and Rectosigmoid.
- Both sides endometriotic cyst noted. DIE noted
- Rectum adherent. Very careful ad adhesiolysis done.
- ICG used in both ureters.
- complete rectal mobilization done.
- RV space fully cleared. RV nodules excised & removed.
- B/L Ureter dissection done.
- Both endometriotic cyst drained and excised.
- B/L tubes, ovaries totally freed and spiced noted.
- hysteroscopy? - shows (N) size uterine cavity.
- B/L ostia loose (N)

T. Zocaf (250) 1 - |

T. SN 15 1 - |

T. Paraloip (40) 1 - |

T. Phenergan (10) - 1HS

T. Reviry (10) 1 - | x 11 days (start from 27.1.23)

Inform sas

To come on 28th Janu

(FORS SLR)
17. 1. 23

A. Nutan Jain
M.B.B.S., M.S., F.I.C.O.G., F.I.C.M.C.H.
ADVANCE LAPAROSCOPIC SURGEON

45
13.2.23

D/28 - Repeat
L-
D/2

Indana Jain
M.B.B.S., M.S., PGDS
IVF / INFERTILITY SPECIALIST
ADVANCED LAPAROSCOPIC SURGEON

Name : Mrs. S. Sweta

Husband :

D.O.B. :

Uterus done on 17/12/23

Age : 28 yrs

R

ML : 1 eps

Grade IV Endometriosis
Bilateral Endometriosis
Bilateral patent tubes
① uterine cavity

Parity : P0 + 0

HPE consist with Endometriosis

LMP : 12/12/23
no flow

D/2

Day : msh: 4-5 days / 28-28 day cycle

TAB PSLVITE
|

Chief Complaints : Dysmen +

Supp. med

TAB EBEXID
|

Su B. tb positive (N)
Dysmen (N)
Pain (N)

PH (N) thyroid

TAB DUSPirin 75

Investigation : HSD 29/12/22

TVS
ND
this cycle
planned

BP: 100/60
wt: 45kg
hgt: 56"

Gonorrhea
test results
LH

X 2.EP

~~Tab Progestin~~

USG :


① In Lupricle (3.75mg)
① Today

To come on D/2 of period.
or Repeat TVS

/ ① March.

Dr. Nutan Jain

M.B.B.S., M.S., F.I.C.O.G., F.I.C.M.C.H.
ADVANCE LAPAROSCOPIC SURGEON



vardhman hospital

44729 ²⁸
3.3.23
Dr. Vandana Jain

M.B.B.S., M.S., PGDS
IVF / INFERTILITY SPECIALIST
ADVANCED LAPAROSCOPIC SURGEON

Name : Mrs. Sparshita New City : hared Husband : guy

D.O.B. :

Age : 28 yrs

ML : 14/3

Parity : PO-0, 12/123
(mblw 4-5 d-4)

LMP : 2/3/23
↓ scanty blood (pale w)

Day : NH

Chief Complaints : Brast 14/3/23
HSA 29/12/22
9 VS
3rd
Thymel
TAB. FOLVITE
TAB. EBEXO
TAB. DISPIRIN 1/2

Bp : 103/54
wt : 45 kg
Gonoclen
40 mg tablet
115

Investigation :

14/3/23
Free
10/2

USG :

TAB PROGNONA 2000
↓ 1 → 2 days
6 niari ml et

3/3/23

TAB DEKRY (10mg) → 1 → 2 days
↓ 18 niari ml et

1/2 done

Dr. Nutan Jain

M.B.B.S., M.S., F.I.C.O.G., F.I.C.M.C.H.
ADVANCE LAPAROSCOPIC SURGEON



vardhman hospital

Dr. Vandana Jain

M.B.B.S., M.S., PGDS
IVF / INFERTILITY SPECIALIST
ADVANCED LAPAROSCOPIC SURGEON

Name: Mrs. Shweta Nain

City: local

Husband:

9:1

D.O.B.:

Age: 28 yrs

ML: 1yr

Parity: P0+0

LMP: 31/3/23

Day: D/2

Chief Complaints:

Wants
conception

TNS-NP

Investigation:

HSA (29/12/22)

C - 60 m/m

M - 40%

USG:

p/s: C₀ / mild redness

PCT 13^u

10/04/23

CT - - -

To come on - - -

- R VLM done on 17/1/23
- G IV endometriosis
 - DIE noted
 - B/L endocyst noted
 - POD obliterated
 - B/L tubes spill noted
 - (N) uterine cavity

- 1) T. FOLVITE 1-1
- 2) T. EBEXID 1-1
- 3) T. DISPRIN 1/2 daily

TAB Letrozole (2.5mg) 1 - 1 x 5 days
start on Today

To come on. 10/4/23

1
1/4/23

10/4/23

10/05/23

Dr. Nutan Jain

M.B.B.S., M.S., F.I.C.O.G., F.I.C.M.C.H.
ADVANCE LAPAROSCOPIC SURGEON



vardhman hospital

City: Local

Dr. Vandana Jain

M.B.B.S., M.S., PGDS
IVF / INFERTILITY SPECIALIST
ADVANCED LAPAROSCOPIC SURGEON

Name: Shweta Nain

D.O.B.: 27/10/94

Age: 28 yrs

ML: 1yr

Parity: PoAo

LMP: 31/3/23

Day: D/19

Chief Complaints:

Wants
conception

Lmp
28/4/23

TVS free

Investigation:

HSA (29/12/22)
C - 60 m/ml
M - 40% (III)

USG:

101

TAB.
PROBUPROSA
(2mg)
1 - 1 x 2 days.

(4) - vs free hmg.

sphere 1-1 x 5 days

18/4/23

Rx

VLH done on 17/1/23

- G_{IV} endometriosis
- DIE noted
- B/L Endocyst noted
- POD obliterated
- B/L tubes spill noted
- (N) uterine cavity

- T. FOLVITE 1-1
- T. EBEXID 1-1
- T. DISPRIN 1/2 daily

18/4/23

TAB utreva (400mg) to be
continue x 11 days.

In^o HCG (SK) ilm. stat
5 days over due HCG Card Test
to come on D₁₂ of period

TVSNIP

Gharan
1100 km

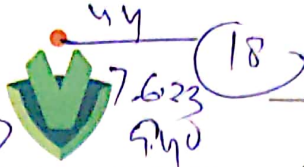
29/12/22
Mx - ve
PRL - 12.46
T₄ - 1.64
TSH - 2.120

21/8/22
T₃ - 1.03
T₄ - 8.23
TSH - 2.120
Hb - 11.8

18 (circled)
18 (circled)
45
18.4.23

Nutan Jain

M.B.B.S., M.S., F.I.C.O.G., F.I.C.M.C.H.
ADVANCE LAPAROSCOPIC SURGEON



Vardhman hospital

Dr. Vandana Jain

M.B.B.S., M.S., PGDS
IVF / INFERTILITY SPECIALIST
ADVANCED LAPAROSCOPIC SURGEON

Name: Shweta Nain

City: Ghazipur

Husband:

D.O.B.: 27/10/94

Age: 28yrs

ML: 1 1/2 yr

Parity: PoAo

LMP: 28/5/23

Day: D/10

TNS-NP

Chief Complaints:

- Wants conception
- Pain in Abd. (Lts side) since 2-3 months

- R** VLH done on 17/1/23
- GIV endometriosis
 - DIE noted
 - B/L endometriotic cysts
 - POD obliterated
 - B/L tubes spill noted
 - (N) uterine cavity

IUI done on 9/5/23

- Took Letroz 0-1 X 5 days from D/2
- Taking T. Progynova 2-2 X 7 days from 3/6/23

Took AKTX 6 months @ the age of 16-17yrs (pulmonary TB)

29/12/22

Mx - ve

PRL - 12.46

T4 - 1.64

TSH - 2.120

21/8/22

Hb - 11.8

Investigation:

HSA (29/12/22)
C - 60 m/m
M - 40% (III)

✓ Try. Luprele (1mg) 1/m stab
? 8/10/22
✓ ✓ ✓
C ? daily

USG: USG (Pelvis) 29/5/23

- Minimal hypoechoic spiculations extending from Rt. lat. wall of uterus adjacent parametrium ? adhesin
- Minimal thickening of adjacent rectum/sigmoid colon ? due to deep pelvic endometriosis

TAB. Sees ter (oomy)

~~12/13/23~~
come on 12/13/23

Nutan Jain
 M.B.B.S., M.S., F.I.C.O.G., F.I.C.M.C.H.
 ADVANCE LAPAROSCOPIC SURGEON

40
 10-5

vardhman hospital

18
 8-5-23
Dr. Vandana Jain
 M.B.B.S., M.S., PGDS
 IVF / INFERTILITY SPECIALIST
 ADVANCED LAPAROSCOPIC SURGEON

Name: Shweta Nain

City: Ghazipur

Husband:

D.O.B.: 27/10/94

Age: 28 years

ML: 1 year

Parity: P0 A0

LMP: 28/4/23

Day: D11

Chief Complaints: LMP
 Wants conception on follicular monitoring. 28/5/23

Investigation:

USG:

Rx VLH done on 17/1/23 A+ve
 - grade IV endometriosis
 - BIL tubes spill noted
 - (N) uterine cavity

Rx:
 T. FOLVITE 1-1
 T. EBEXID 1-1
 tubal spray 2 tub daily

USG
 4/5/23 -
 - AFC =
 R. side = 10
 L. side = 12

INJ - HCG (10K) IM STAT
 TO COME ON 9/5/23

8/5/23

10/5/23

at night
 TAB - AZEE (1gm) →
 TAB - FORCAN (150mg) → } H/W single dose

Actu -
 CBC, ABO, RH
 HIV, HCU, HBsAg,
 VDRL, U-R -ME
 BS-F -PP, TSH

P-70

Dr. Nutan Jain

M.B.B.S., M.S., F.I.C.O.G., F.I.C.M.C.H.
ADVANCE LAPAROSCOPIC SURGEON

Dr. Vandana Jain

M.B.B.S., M.S.
ADVANCE LAPAROSCOPIC SURGEON

1700 Shweta Nain Chhazipur

-36
28/10/2023
18

55
18-10-23
10.56



Vardhman
Trauma & Laparoscopy Centre (P) Ltd.

Atue

Age - 29y

191: 240

Potd

Wet done on 17/1/23

End IV endometriosis

1312 tube sprid noted
Normal uterine cavity

4/9/23

Hb1c 5.8

TS11 10960

Hb1-11.8
CBC N

LFT - N
KFT - N

Lmp: 20/8/23

13P: 90160

wt: 45.9 kg

INJ. ITCN 5000 TWICE WEEKLY ← Tuesday
Friday.

INJ. PROLUTIN DEPOT 250 / weekly

TAB. FOLVITE 1 →

TAB. EBELID 1 →

TAB. DUPHASTONE 1 →

TAB. LYOPOGON - 1 -

TAB. DEX 5 mg ALT

TAB. DISPREN 1/2 DAILY

Day
Hb1 FSH
13 blood sugar FPP
1+IV 1+ASNG 000L
1+EV, Hb1c
Hb1 Electrophoresis

Day sonography box beofal gynecols
and well being casdrae

PH / NOLING
PIT

L usn - 4/10/23

Gwke oclau

Ccaadrae -

pt wath

wait x/wedy
adv: evanation

TVS/MP

→ No growth

→ Next Scan form only

Local Auth. Reg. No. : RMEE2108327

VARDHMAN TRAUMA & LAPAROSCOPY CENTRE PVT. LTD.

3rd Km., Jansath Road,
Muzaffarnagar-251001 (U.P.) India

+91-0131-2623084, 2623085

drvandanaivf3@gmail.com
jainnutan@gmail.com

Reg. Office : C-209, Defence Colony, New Delhi-110024

www.vardhmanhospital.com

✓ Spj. Gestā (30) amp indiv

Anembryonic Pregnancy.

→ 1/2 dose


→ Hydno: → (D)

Postnatal outline of
Syp. 2002

28/12/23
BP: 110/70
wt. 4.5 kg
Temp 38

Wai...
pains as below

Dx of me { hCG
RPLN
TSH
palecetes
Chromosomal analysis (Karyo.)



T. Celestrol 1 — 1
(250)

T. Paracet 1 — 1
(40)

X { T. Folvite 1 — dose
Derive
T. Ebeacid 1 —
T. Dispersin 1/2 — daily

T. Methergin 1 — 1 x 3 days

T. Polybion 1 —

✓ T. Progynon 1 — 1 x 21 days
(2mg)
(start from 27.10.23)

✓ T. Deviry 1 — 1 x 14 days
(10)
(start from 8.11.23)

Inform sas
To come on next day
of pd.

23.10.23

CAP. Roxamycin 1 — 10zcdy,
15-dy

1 — 10zcdy

TAB PoluicE ACTIVE
1 —

TAB Ekeon 1 —

TAB Eesperin (1mg)



09/05/23

IUI SUMMARY

Registration No. : 18

Name : Mrs. Shweta Nain

Husband Name : Mr. Anant

IUI - Cycle : 1st

Prewash 50/50 III

Post wash 50/90 IV

Self/TID self
10/5
70/60/III
80/90/IV
[Handwritten signature]

PROCEDURE NOTES :

- o Easy/Difficult
- o Sim / Cusco
- o Erosion
- o Patient Cooperative / Non Cooperative

Result



7/6/23

IUI SUMMARY

Registration No. : 18

Name : MVS SHWETA NALIN

Husband Name : MR. ANANT KUMAR

IUI - Cycle : ^{IInd -} $\frac{FM - 7/6/23}{60/40}$ | $\frac{IInd 8/6/23}{40/80}$ ^{Self/TID} ✓

Prewash

Post wash

PROCEDURE NOTES :

- o Easy/Difficult
- o Sim / Cusco
- o Erosion
- o Patient Cooperative / Non Cooperative

Result

20/8/ 9/1/2023

Uterus Rlv Globular

Endo - 8mm

mild Adenomyosis

Rterary

Uterary

B/L ovaries Adherent

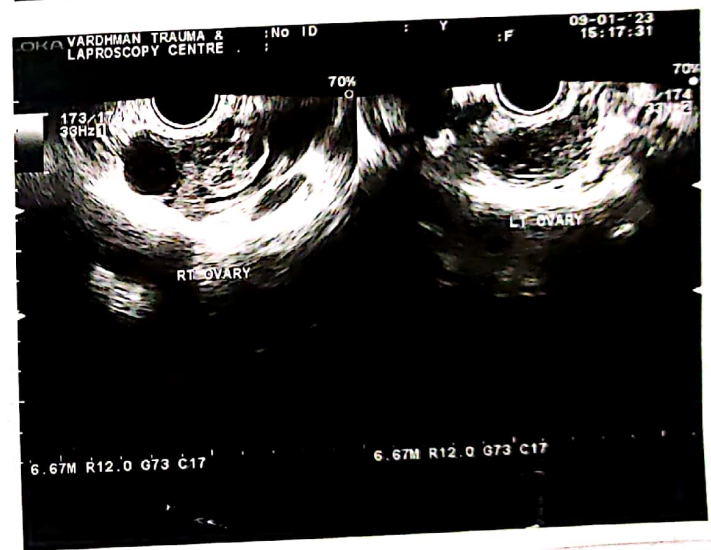
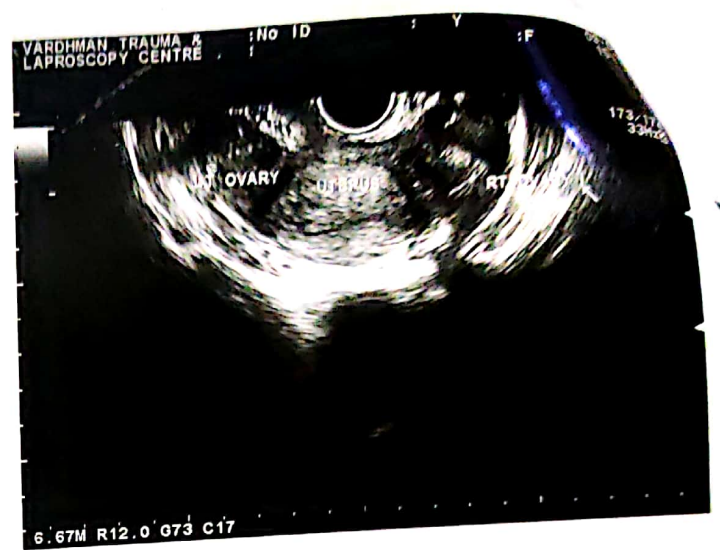Endocyst

mild-pouch

(26x22)
(14x12)

Endometrios

(Scary tender +)



0/12

NP 29/12/2022

9-50Am

Uterus

0/12

Q shaped

Uterus Rlv Globular

Uterus size - (66x37)

Endo - 8mm = line

mild Adenomyosis

Rterary

Uterary

B/L ovaries

Adherent

(os . 55x30)

(os - 41x29)

Endocyst - { 26x22
16x12 }

(Cyst - 27x20)

Cyst - 33x22mm

(Scary tender +)

Endometrios

FOLLICULAR SONOGRAPHY

DR. NUTAN JAIN M.S.

DR. VANDANA JAIN M.S.

Lap Date : _____

HSA _____

Count : _____

Moti : _____

Name/Age : Stweta Nain / 28 yrs Station : Local

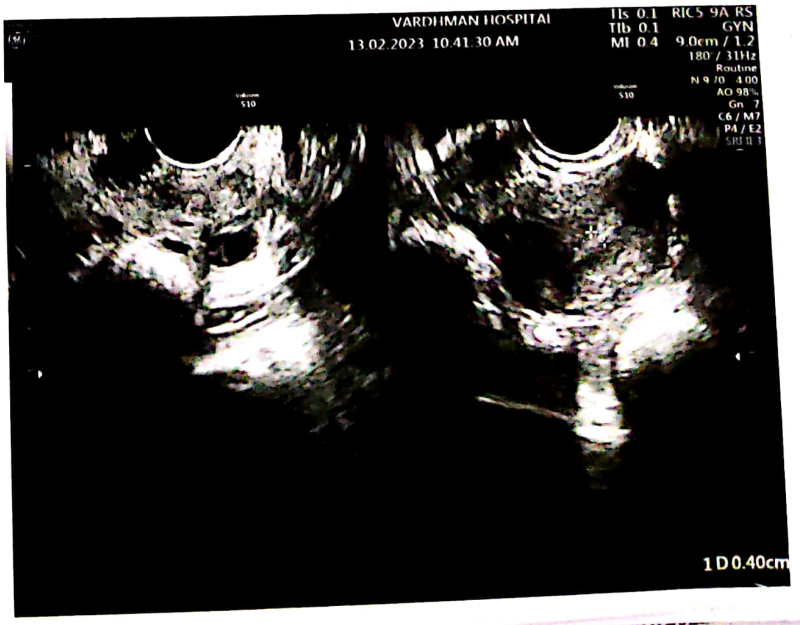
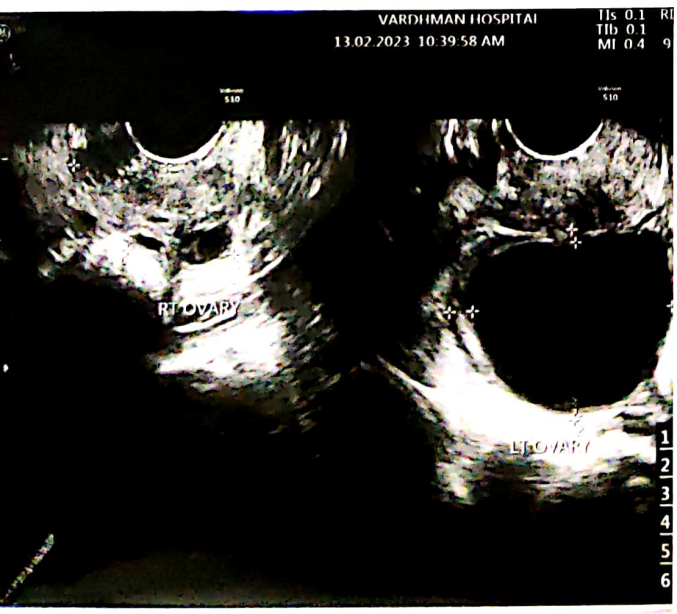
Parity : Poto ML : lyes

Cause of Anovulation : _____ Ovulogen : _____ MH : _____

After lap OSCU.

L.M.P. 12/2/23

Scan	Rt. Ovary	L. Ovary	Endometrium	PCT	Cx Mucus
<u>NP</u> <u>13/2/23</u> <u>2/2</u>	<u>(B/L ovaries Seen closed)</u> <u>(OS - 46x22)</u>	<u>Seen closed</u> <u>(OS - 58x46)</u>	<u>ut R/v Globular</u> <u>Endo - 4mm</u>		<u>(A Stape)</u>
	<u>(5-6 follicle)</u>	<u>cystic follicle</u> <u>(49x41)</u>			
<u>Re-assess on Day 28</u>					
<u>if present 2nd. supside</u>					
<u>D/2 - see for cystic</u>					



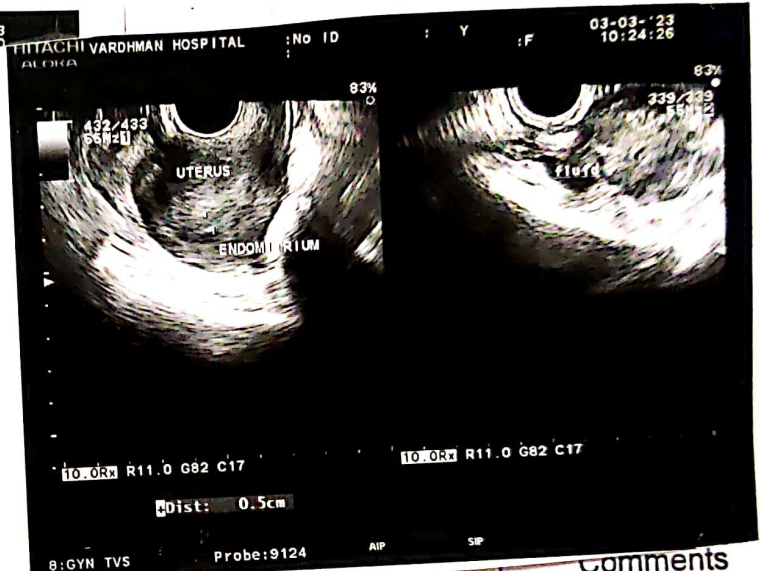
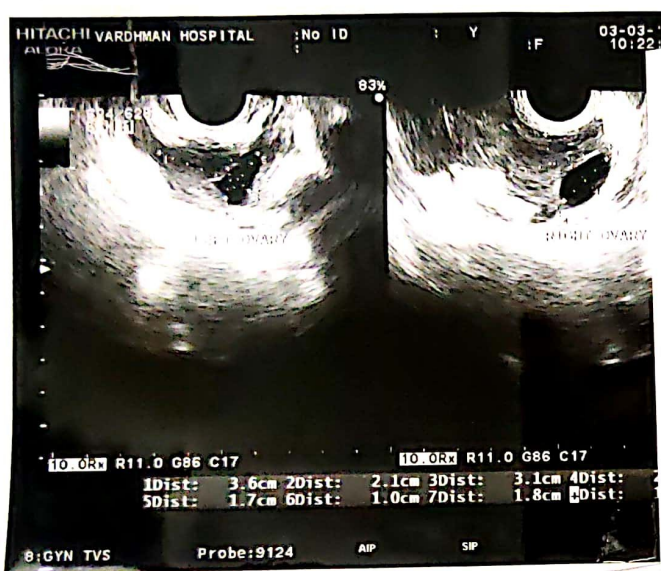
LMP 2/3/23

NUTA

Cycle Drug :

L.M.P.

Scan	Rt. Ovary	L. Ovary	Endometrium	Comments
3/3/23	B/L ovaries	Seen close	Uterus R/v	lobular
0/2	f1 - 18x11 COS - 31x25	COS - 36x21 (Cystic Collapsed) 17x10 (Mild fluid)	Endo → 5mm	(@ Skape)



Scan	Rt. Ovary	L. Ovary	Endometrium	Comments
1.				
2.				
3.				
4.				

FOLLICULAR SONOGRAPHY

DR. NUTAN JAIN M.S.

DR. VANDANA JAIN M.S.

Lap Date : grade IV
endometriosis
17/1/23 DIE

HSA
 Count :
 Moti. :

Name/Age : Shweeta

Station : local

Parity : P0+0

ML : 148

Cause of Anovulation :

Ovulogen :

MH :

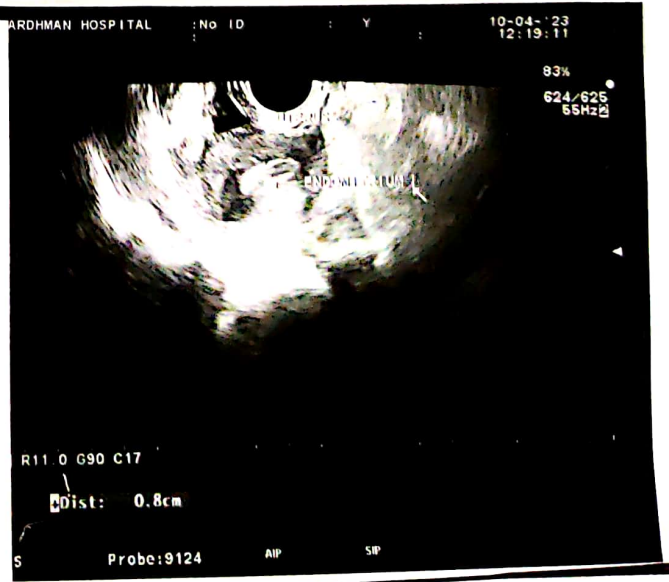
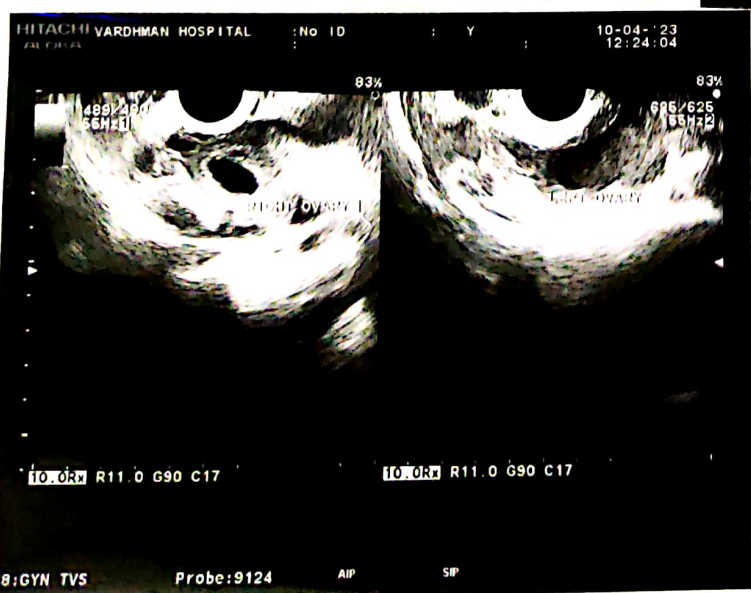
1+1-1 cycle ①

1 Cycle

Drug :

L.M.P. 31/3/23

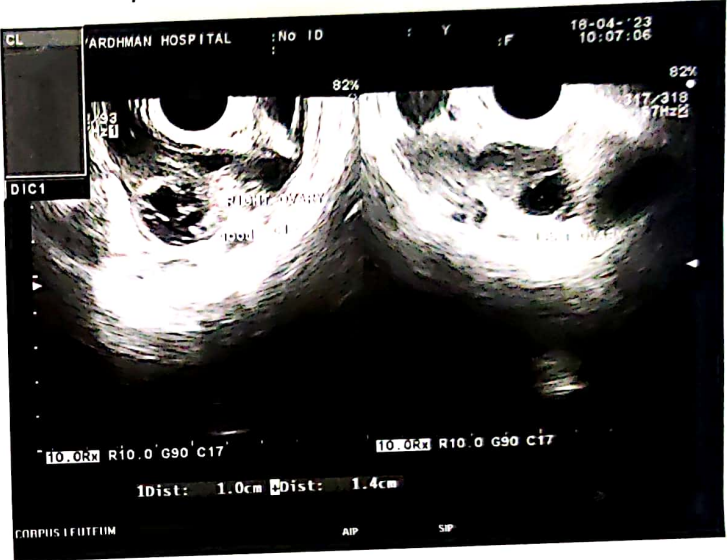
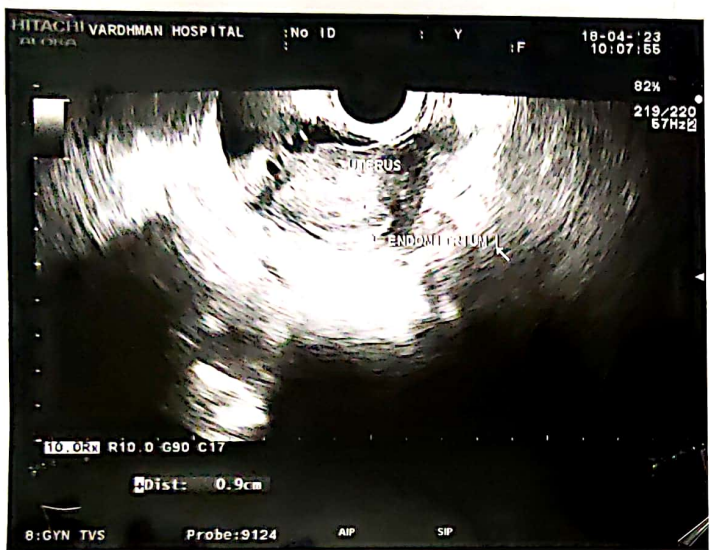Scan	Rt. Ovary	L. Ovary	Endometrium	<input type="checkbox"/> PCT	Cx Mucus
1. <u>MP</u> <u>11/4/23</u> <u>0/2</u>	B/L ovaries seen close (OS-31x15)	Seen close (OS-29x21)	Uterus. R/L Endo-5mm.		lobular. @ shaped.
2.	4-5 follicle Reg. CL seen.	5-6 follicle.			
3. <u>10/4/23</u> <u>OHQ</u>	B/L ovaries seen F1-17x11=13	Small F1-11x7	Uterus R/L Endo-8mm		lobular (@ shaped)
4. <u>16/1/23</u> <u>OHQ</u>					



II Cycle Drug :

L.M.P.

Scan	Rt. Ovary	L. Ovary	Endometrium	Comments
1. 18/4/23 D114	BL ovaries seen		uterus	R/v bilobular (O shaped)
2.	FL- 23x16	FL- 17x8	Endo- 8mm	
3.			PLS- mild tenderness @	
4.			clear mucus. many mitotic spores	



Scan	Rt. Ovary	L. Ovary	Endometrium	Comments
1. 18/4/23 D119	BL ovaries seen		uterus R/v	bilobular (O shaped)
2.	good CL seen	FL- 14x10	Endo - 9mm	
3.				
4.				

FOLLICULAR SONOGRAPHY

DR. NUTAN JAIN M.S.

Lap Date :

Name/Age : *shweta Nain* Station : *Local*

Parity : *PO+0 / 2840* ML : *1yr*

Cause of Anovulation : Ovulogen : MH :

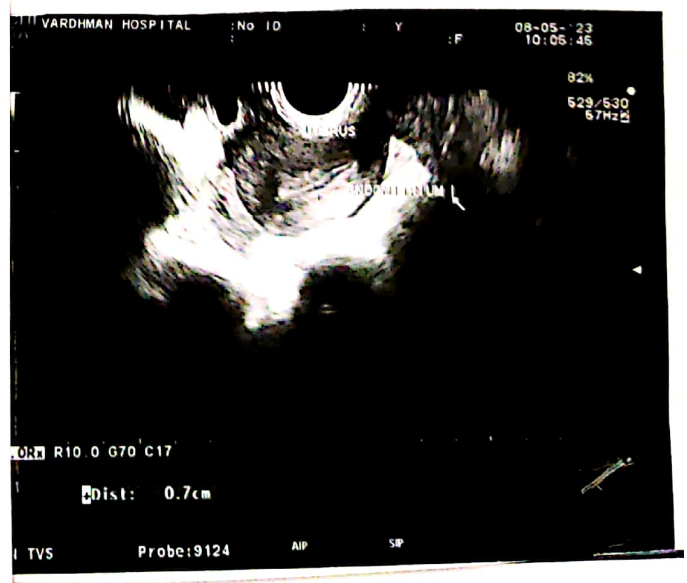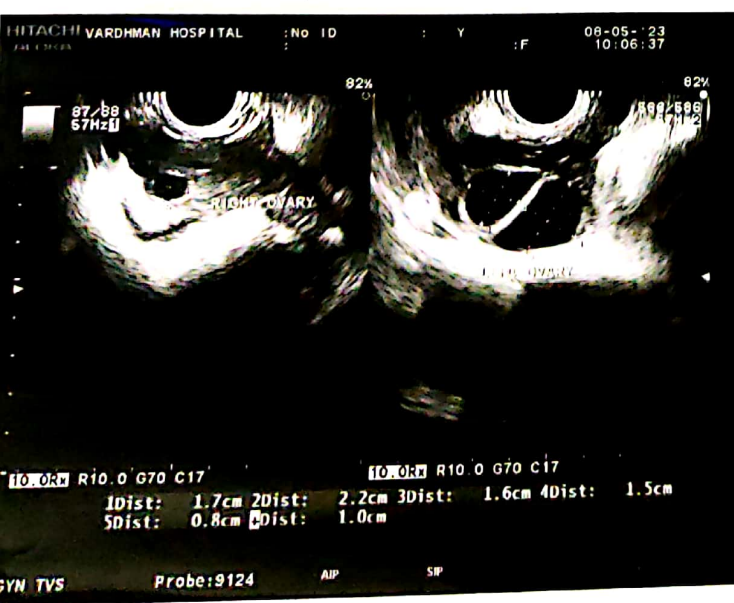
HSA ..

Count :

Moti. :

1 Cycle Drug : *CCYOO + HMO₁* L.M.P. *28/4/23*

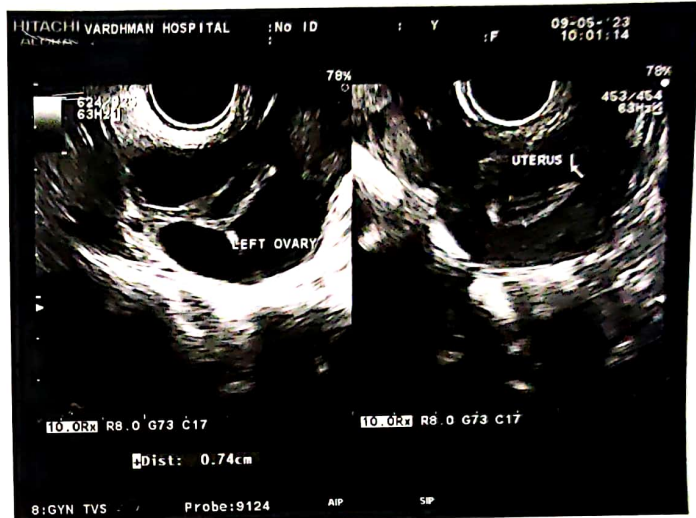
Scan	Rt. Ovary	L. Ovary	Endometrium	<input type="checkbox"/> PCT Cx Mucus
<i>1. NP 29/4/23 D/2</i>	<i>B/L ovaries seen. (OS-37x18)</i>	<i>(OS-30x27)</i>	<i>uterus R/v Endo-5-6mm</i>	<i>lobular o shaped.</i>
<i>2.</i>	<i>B/L 4-5 follicle.</i>			
<i>3. 8/5/23 D/11</i>	<i>F1- 10x8</i>	<i>F1- 22x17 F2- 16x16 F3- 18x14 F4- 22x11</i>	<i>uterus R/v Endo-7mm = 1Pr.</i>	<i>lobular o shape</i>
<i>4.</i>				



Cycle Drug :

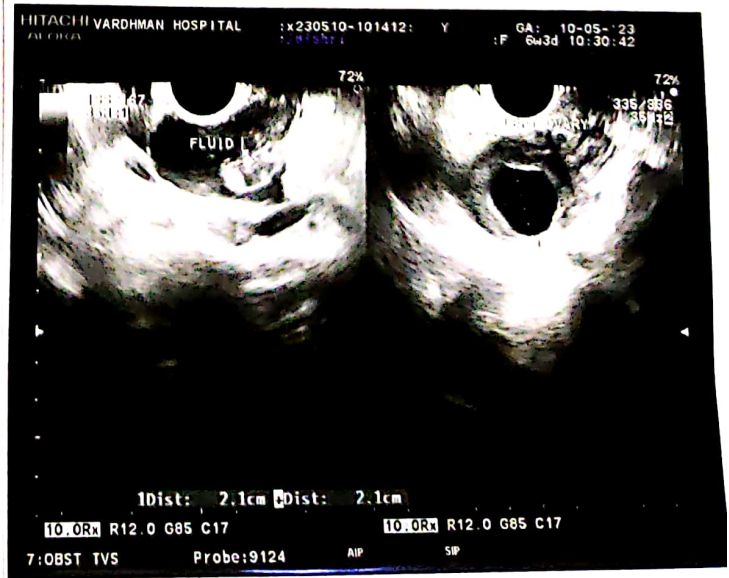
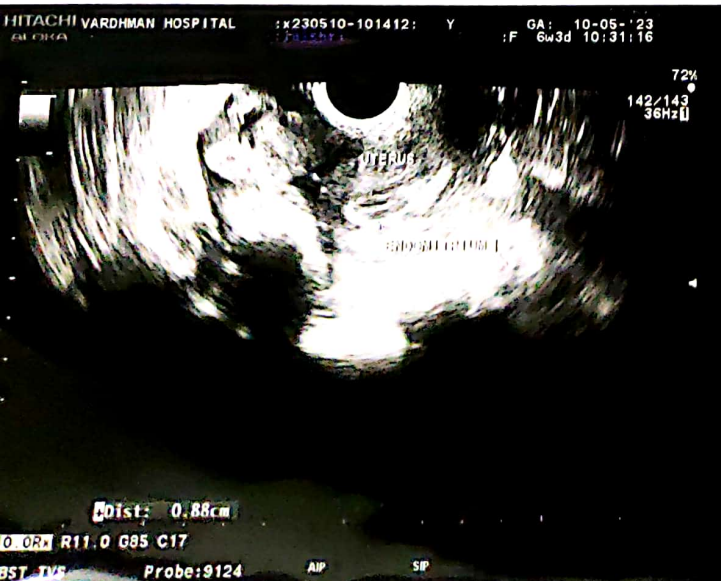L.M.P.

Scan	Rt. Ovary	L. Ovary	Endometrium	Comments
1.	B/L ovaries seen		uterus R/V lobular	IF
2.		F1-10x9	F1-25x23 F2-22x21 F3-20x19 F4-24x13	
3.				10/14R
4.				



III's Cycle Drug :

Scan	Rt. Ovary	L. Ovary	Endometrium	Comments
1.	B/L Ovaries seen		uterus	R/V globular
2.		F1 12x8	C3 collapsed F1-21x21	Endo - 8.8mm
3.				





FOLLICULAR SONOGRAPHY

DR. NUTAN JAIN M.S.

DR. VANDANA JAIN M.S.

Lap Date :

Name/Age : *Sneha Nain*

Station : *Ghaziabad*

Parity : *P0+0*

ML : *1/244*

Cause of Anovulation :

Ovulogen :

MH :

Lt 0-1 cycle ③

HSA

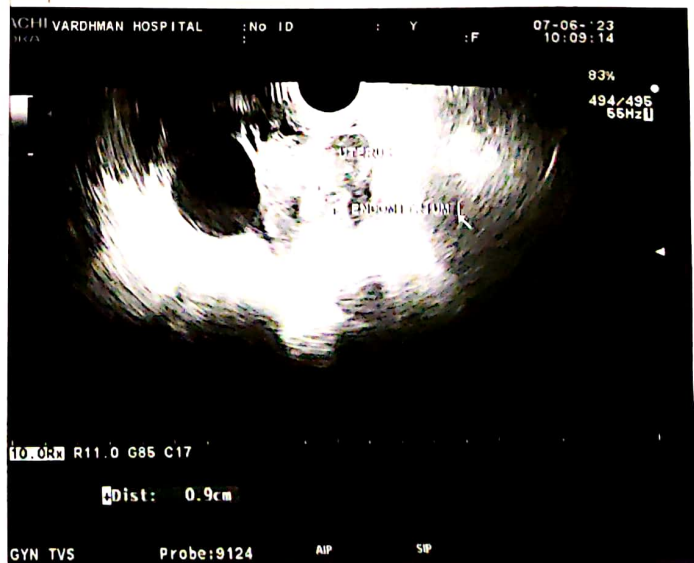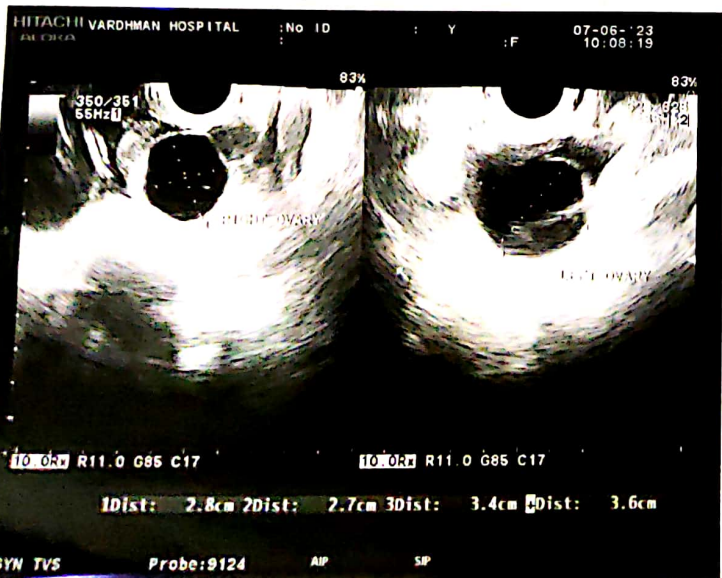
Count :

Moti :

1 Cycle Drug :

L.M.P. *20/5/23*

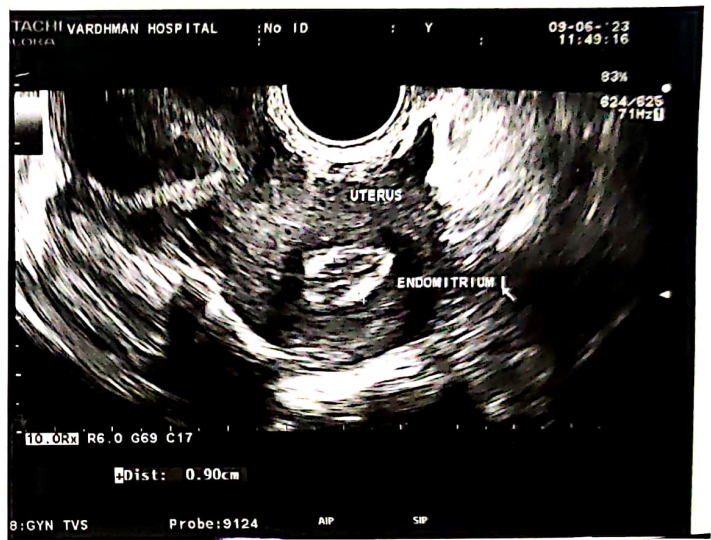
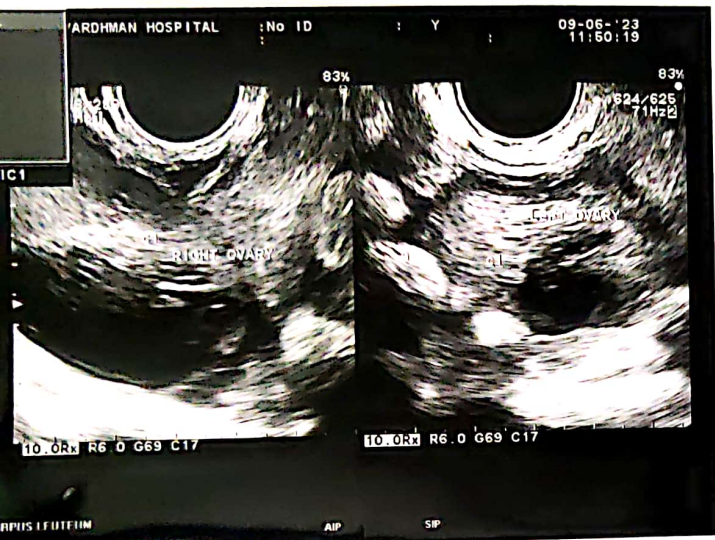
Scan	Rt. Ovary	L. Ovary	Endometrium	PCT Cx Mucus
<i>MP 6/6/23 D/10</i>	<i>Blk ovaries seen (OS-37x20)</i>	<i>Seen (OS-40x44)</i>	<i>Uterus R/V Endo-8mm</i>	<i>Globular & shaped.</i>
<i>2.</i>	<i>F1-24x24</i>	<i>F1-36x26</i>	<i>≡ lines</i>	<i>NO CT- -</i>
<i>3. 7/6/23 D/11</i>	<i>Blk ovaries seen F1-27x27</i>	<i>F1-36x34</i>	<i>Uterus R/V Endo-9mm</i>	<i>Globular & shaped <u>1.0/4R</u></i>
<i>4.</i>				



II Cycle Drug :

L.M.P.

Scan	Rt. Ovary	L. Ovary	Endometrium	Comments
1. 8/6/23 2/12	BIB ovaries seen		uterus	Rlv lobulated ashaped
2.	F1- 33x33	F1- 46x32	Endo-9mm	
3.			pls - clear	10/14R ?
4.				1 mucus seal Remnants 23



Scan	Rt. Ovary	L. Ovary	Endometrium	Comments
1. 9/6/23 2/13	BIB ovaries seen		uterus	Rlv lobulated ashaped
	(blood cl seen)	(blood cl seen)	Endo-9mm	

VARDHMAN TRAUMA & LAPAROSCOPY CENTRE PVT. LTD.
 3rd Km. Jansath Road, Muzaffarnagar (UP)



FOLLICULAR SONOGRAPHY

DR. NUTAN JAIN M.S.

DR. VANDANA JAIN M.S.

Lap Date: 17/11/23.
 Cx Endometrosis
 B/c tubes small
 HSA
 Count :
 Moti. :

Name/Age: Mm. Sheefa Nam Station: C2B

Parity: 0000 29yrs ML: 2yrs

Cause of Anovulation: Ovulogen: MH:

1 Cycle	Drug :	L.M.P. 20/8/2023		
Scan	Rt. Ovary	L. Ovary	Endometrium	PCT Cx Mucus
1. NP 18/10/2023	B/L Cystic CL (23x23)	Adenexa scan	Uterus R/L Cx - 8 weeks 3 days	
2.		Coel - 36mm	Ces - 26mm yollesae - 6mm	
3.				
4.		A single intra uterine pregnancy of 6 weeks 5 days by scan and 8 weeks 3 days by log		
5.				

18/10/2023

Date : Cx OS

Spinbarkett

Cx Mucus

Sperms

Folliculo-Endo-Cx Synchronization

Motile/Nonmotile

Date :
 Time :

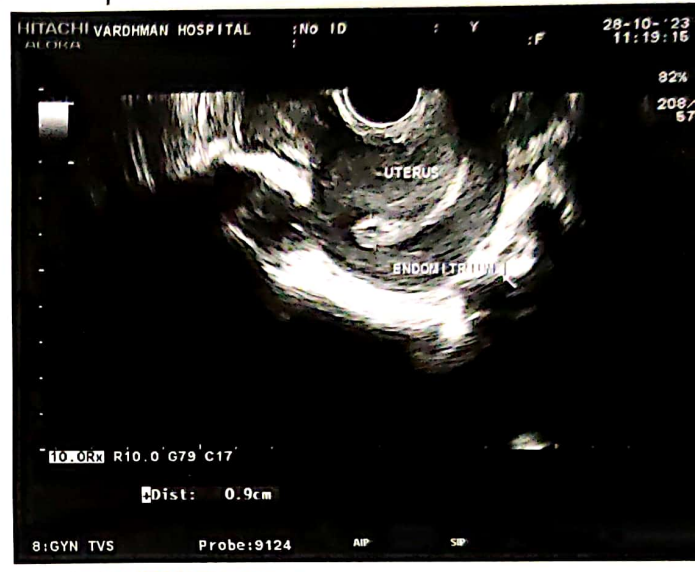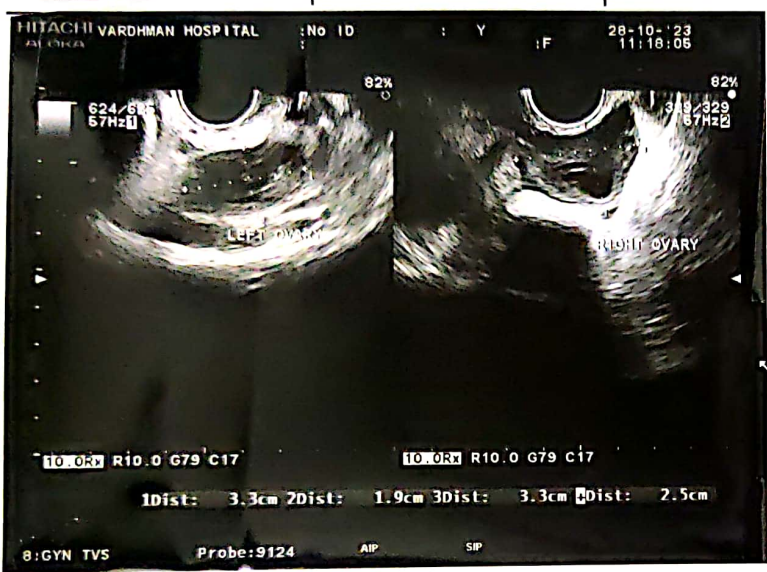
Consultant Name & Signature

P.T.C
 VTLC/Gynae/Form/FS/2023/Ver.1.

II Cycle Drug :

L.M.P.

Scan	Rt. Ovary	L. Ovary	Endometrium	Comments
1. <u>28/10/23</u>	BIL ovaries seen		ut Rly	multilocular (ashabe)
2.	(OS-33x25)	(OS-33x22)	Endo-9mm	(thick end)
3. <u>28/10/23</u>				
4. <u>28/10/23</u>				



III Cycle Drug :

L.M.P.

Scan	Rt. Ovary	L. Ovary	Endometrium	Comments
<u>28/10/23</u>				