

Cardiac Catheterization and Intervention Report

Patient Name : Mr. Yadavendra Singh
Reg. No. : 11923644
Age/Gender : 52 yrs 19 days /M
Address : J-34 NYAY NILYAM KALA AAM CHAURAHA
BULANDSHERA
Proc. Date : 08/08/2022
Procedure No. : 71499
IPD No. : 131277/22/1201
Performed By : DR. VINEY JETLEY
Assisted By : .

PROCEDURES DONE : Coronary Intervention

INDICATIONS : Angina

DIAGNOSIS

Intervention : 1. Successful Intervention of OM2 - Ostial (Drug Eluting stent)

Coronary Anatomy :

APPROACH : R Femoral Artery

COMPLICATIONS : No Complications during the Procedure



INTERVENTION

1 OM2 Ostial Stenosis: 80 - 90% Residual Stenosis: 0% Occurrence: Denovo Result : Successful

Procedures:

ICS

Catheter : Guide catheter / XB 6F / 3.5 F
Guidewire : BMW / 190 cm / 0.014"
Pre-Dilatation : Balloon - 2 mm x 12 mm inflated @ 10 atm
Stent : Xience Alpine - 2.5 mm x 28 mm inflated @ 10 atm
Post-Dilatation : Balloon - 2.75 mm x 12 mm inflated @ 14 atm

Adj. Pharmacology

: Heparin


DR. VINAY JETLEY

DIRECTOR INTERVENTIONAL
CARDIOLOGY

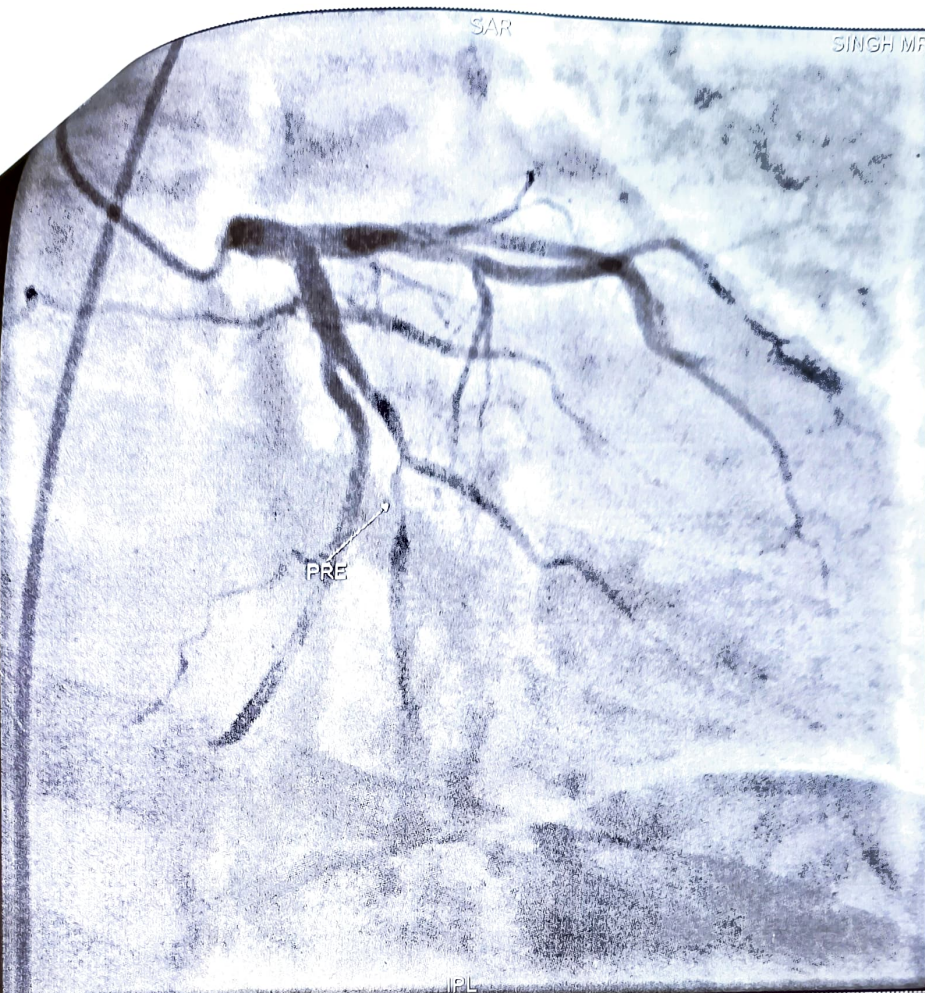


SAR

SINGH MR YADAVENDRA 52/M
214732
M

Aug 08 2022
14:34:22

R
P



L
A

(Filt. 5)

FOV: 15x15 cm
RAO: 20.0 deg
CAU: 19.2 deg
L: -0.1 deg
Tilt: 0 deg
Mag = 1.00
FL: ROT:
WW: 256 WL: 152
XA 512x512

Seq: 3
FRAME = 23 / 88

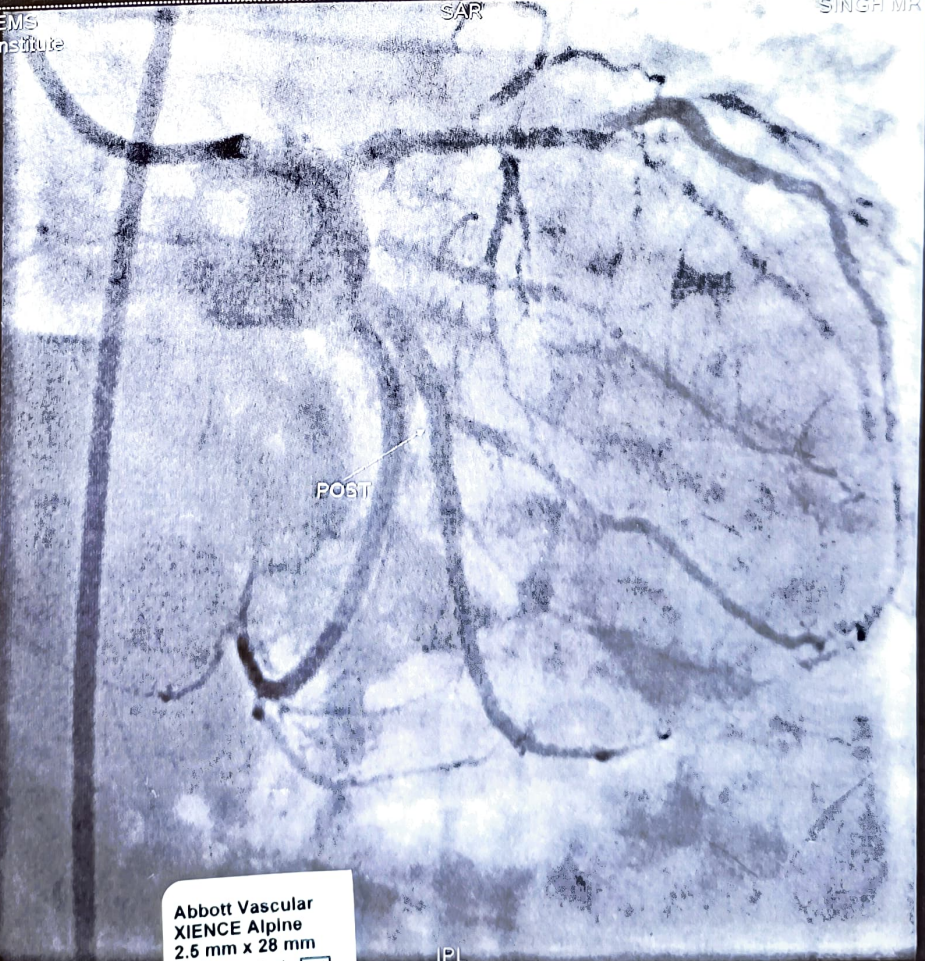
GE MEDICAL SYSTEMS
Fortis Escorts Heart Institute

IPL
SAR

SINGH MR YADAVENDRA 52/M
71499
M

Aug 08 2022
15:26:44

R
P



L
A

(Filt. 5)

FOV: 15x15 cm
RAO: 18.6 deg
CAU: 29.2 deg
L: 0.0 deg
Tilt: 0 deg
Mag = 1.00
FL: ROT:
WW: 256 WL: 152
XA 512x512

Seq: 33
FRAME = 32 / 53

Abbott Vascular
XIENCE Alpine
2.5 mm x 28 mm

LOT 2033041 RX
REF 1120250-28

IPL