



डा० भीमराव अम्बेडकर संयुक्त चिकित्सालय (पुरुष) इटावा  
DR. BHIMRAO AMBEDKAR COMBINED HOSPITAL (MALE) ETAWAH



Date: 12 FEB 2024 Department ..... OPD No: 5011  
Patient Name: Adv. शैलेन्द्र निगम S.D. W/o ..... Age 52 Sex: M/F/Trans  
Address: J-3 सिविल लाइन इटावा

Presenting Complaints ..... Pain, Abdomen & cholelithiasis  
Past & Family History ..... B.L. Renal stones  
Know drug Allergy .....

(A) General physical examination

Ht                      Wt                      Temp  
Pulse                  RR                      BP  
Pallor                  Icterus  
Oedema                Cyanosis  
Dehydration Mild/ Mod/Sev

Prov. diagnosis

Treatment plan:

Rx T. Diclo 50mg 2000  
T Dicyclomine 2000  
T Ranitae 2000  
Cap Bifilae 2000  
Complete Bed rest for 15 days

(B) Systemic examination

CNS:

CVS:

Resp:

(C) Local examination

Abdominal:

Chest:

Extremities:

(D) Investigations:

Handwritten notes in a box:  
H/W  
O/S  
L/L  
R/S  
R/S  
H/W  
H/W  
Cap profly

डा० शैलेन्द्र निगम  
चिकित्सियन  
सुबाल, इटावा

डा० शैलेन्द्र निगम  
चिकित्सियन  
जिला अस्पताल, इटावा  
25/02/2024  
Doctor's Name & Signature

Follow - up

Date

26/2/24

Treatment plan:

Rx

Cll

Post operative case of cholelithiasis  
EBL kidney stones & L.B.A.

Rx

T. Tramadol 3000

T. S&PD 3000

T. Cefixime 2000 3000

T. RANTAC 3000

T. ~~Do~~ MCH →

Dibs get →

x 15 days

Admni

Complete bed rest for 15 days

डा० शशिकु निगम  
मिनीशियन  
जिला अस्पताल, इटावा  
206001/24  
26/2/24

डा०भीमराव अम्बेडकर संयुक्त चिकित्सालय (पुरुष) इटावा

दिनांक-

चिकित्सा प्रमाण-पत्र

प्रमाणित किया जाता है कि श्री/श्रीमती/कु०..... शैलेन्द्र निगम उम्र लगभग 52 वर्ष पिता/ पति श्री.....

शैलेन्द्र निगम पता ग-३ सिविल लाइन इटावा विभाग आय विभाग  
संयुक्त चिकित्सालय (पु०) इटावा में वाहय रोगी पर्चा सं० 5011 के द्वारा

चिकित्सालय में मेरे समक्ष अपने उपचार हेतु दिनांक-12/21/24 को उपस्थित हुए। जाँचोपरान्त श्री/श्रीमती/कु०.....  
शैलेन्द्र निगम को Rain Akhmen & BIL Renal stones & cholelithiasis रोग से पीड़ित पाया गया।

मेरी राय में श्री/श्रीमती/कु०..... शैलेन्द्र निगम को पूर्ण स्वास्थ्य लाभ हेतु नियमित उपचार एवं  
30 दिन/सप्ताह/माह तक पूर्ण विश्राम करने की सलाह दी जाती है। जोकि दिनांक 12/21/24  
से प्रभावी होगा।

श्री/श्रीमती/कु०..... शैलेन्द्र निगम के हस्ताक्षर मेरे द्वारा नीचे प्रमाणित किये जाते हैं।

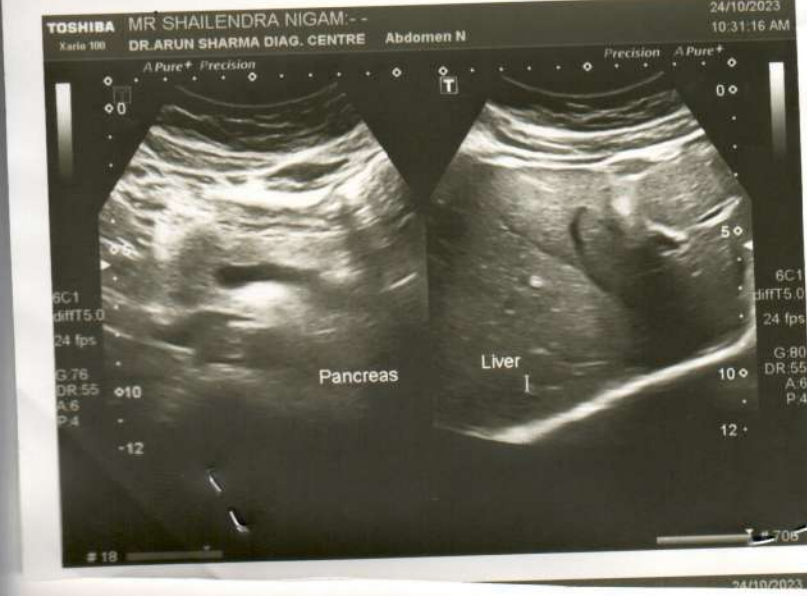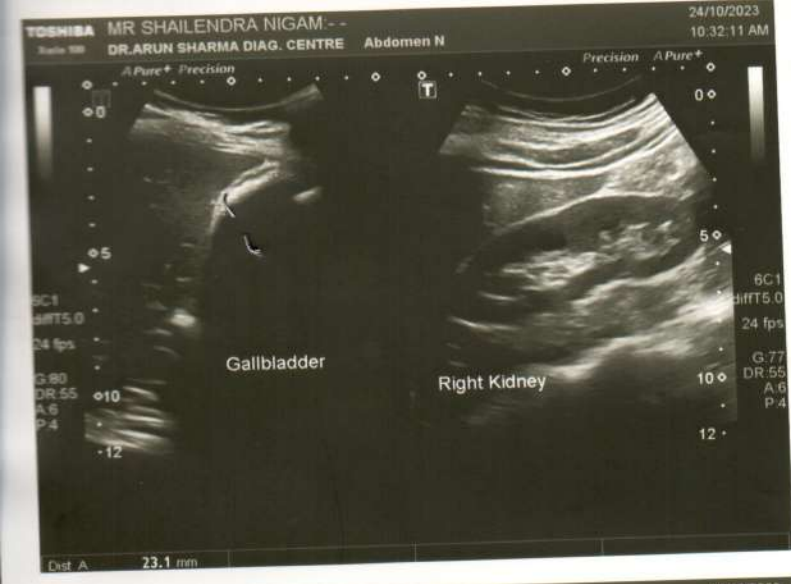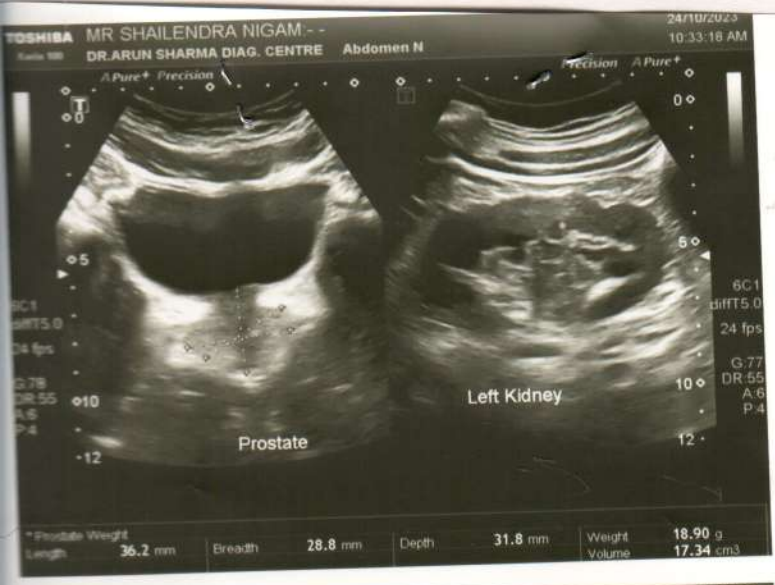Shaleendra nigam

हस्ताक्षर प्रमाणित इच्छु  
डा० शैलेन्द्र निगम  
चिकित्साधिकारी  
संयुक्त चिकित्सालय, इटावा

डा०भीमराव अम्बेडकर संयुक्त चिकित्सालय,  
(पु०) इटावा

डा० शैलेन्द्र निगम  
चिकित्साधिकारी  
डा०भीमराव अम्बेडकर संयुक्त चिकित्सालय,  
(पु०) इटावा

Chief Medical Superintendent  
डा०भीमराव अम्बेडकर संयुक्त चिकित्सालय  
(पुरुष) इटावा।



# ARUN SHARMA DIAGNOSTIC CENTRE

Whole Body 3D Colour Doppler Ultrasound (Nemio Premium Compact Toshiba, Japan)  
4D Colour Doppler 2-D Echocardiography ♦ Digital X-Ray (Konika) ♦ Pathology

37/52, Gilish Bazar, Kotwali Chauraha, Shivala Road, (Opp. Bhalla Medical Store) Kanpur Ph.: 9415474552, 9838983373

**PATIENT'S NAME:-SHAIENDRA NIGAM**

**REF. BY.DR:-SELF**

**DATE:-24.10.23**

## **ULTRASOUND OF WHOLE ABDOMEN**

**LIVER** IS NORMAL IN SIZE, SHAPE AND POSITION. LIVER PARENCHYMAL ECHOPATTERN IS NORMAL. INTRAHEPATIC BILIARY & VASCULAR RADILCES ARE NORMAL. PORTAHEPATIS REVEALS NO ABNORMALITY.PORTA VEIN IS NORMAL. DOMES OF DIAPHRAGM ARE NORMAL. NO FOCAL MASS / DEFECT SEEN.

**GALL BLADDER IS CONTRACTED WITH THICKNED WALLS WITH CALCULUS = 23 MM.**

**C.B.D IS MEASURING ABOUT 7 MM IN DIAMETER.** NO CALCULUS OR MASS.

**PANCREAS** IS NORMAL IN SIZE, SHAPE AND POSITION WITH NORMAL ECHOES PATTERN AND CLEARLY VISUALIZED ALL MARGINS OF PANCREAS. NO PANCREATIC CALCIFICATION.

**BOTH KIDNEYS** ARE NORMAL IN SIZE, SHAPE AND POSITION WITH NORMAL CORTICAL PARENCHYMAL ECHOGENECITY AND THICKENS. NO CALCULUS OR MASS. PELVI-CALYCES SYSTEM ARE NORMAL. RENAL SINUSES ARE NORMAL. CORTICO-MEDUALLAY RATIO IS NORMAL EXCURSION WITH RESPIRATION ARE NORMAL.

**SPLEEN** IS NORMAL IN SIZE, SHAPE AND POSITION WITH HOMOGENOUS ECHO PATTERN.

**BOTH URETERS** ARE NORMAL IN COURSE AND CALIBRE.

**URINARY BLADDER** SHOWS NORMAL FILLING WITH THICKENEED WALLS NO CALCULUS AND MASS SEEN IN BLADDER LUMEN.RESIDUAL URINE MEASURING ABOUT 8 ML.

**PROSTATE** IS MEASURING ABOUT 36X28X21 MM. WITH NORMAL ECHO PATTERN WITH INTACT CAPSULE. NO PROSTATIC CALCIFICATION SEEN.PROSTATIC WEIGHT NEAR ABOUT 19 GMS.

NO EVIDENCE OF ASCITES/LYMPH NODES.

**IMPRESSION:-CHRONIC CHOLECYSTITIS WITH CHOLELITHIASIS.**



**Dr. ARUN SHARMA**  
M.D. RADIOLOGIST  
M.R.I. & CT SCAN SPECIALIST

### **Kindly Note :**

The science of Radiological diagnosis is based on the interpretation of various shadows produced by both the normal and abnormal tissues and are not always conclusive. Further biochemical and radiological investigation & clinically correlation is required to enable the clinician to reach the final diagnosis, **The report and films are not valid for medico-legal purpose. Kindly inform any typing mistake immediately for the correction**

**For any indicripeny between report & clinical findings please inform immediately for further assessment.**

**Dr. B. R. AMBEDKAR COMBINED HOSPITAL (MALE)**

**ETAWAH**  
DEPARTMENT OF PATHOLOGY  
"AN ISO 9001:2015 CERTIFIED LABORATORY"

Date : 22-Sep-2023 Reg/Ref: DMH-56 / 305522  
Name : MR. SHAILENDRA NIGAM Age/Sex : 52 Yrs./Male  
Ref.By : Dr. SELF Phone : Ward : OPD  
Receipt : NA  
Requested Test : cbc, KFT, LFT, LIPID P., amylase, LIPASE, RBS, CRP, t3 t4 tsh, vb12, VITAMIN D, HBA1C  
Coll Time : 22-Sep-2023 09:33 AM Validate : 22-Sep-2023 01:22 PM Prn. Time : 22-Sep-2023 01:24 PM

Investigation	Observed Values	Biological Ref. Interval
---------------	-----------------	--------------------------

**HAEMATOLOGY**

**Complete Blood Count**

Haemoglobin	15.6 g/dL	13 - 17
Total Leucocyte Count ( TLC )	8400 cells/mm <sup>3</sup>	4000- 11000
<b>Differential % Leucocyte Counts:</b>		
Neutrophils	62 %	40 - 80
Lymphocytes	30 %	20 - 40
Eosinophils	06 %	1 - 6
Monocyte	02 %	
Basophil	00 %	
Platelet Count	1.58 Lac cells/mm <sup>3</sup>	1.5 - 4.5
LPCR	27.4	
MPV	9.8 fl.	
PDW	12.8	
PCT	0.15	
Total RBCs	5.03 Million cells/ $\mu$ L	3.8 - 4.8
MCV (Mean Cell Volume)	89.1 fl.	80 - 100
MCH (Mean Corpus. Haemoglobin)	30.9 pg	27 - 32
MCHC (Mean Corpus. Hb Conc.)	34.7 g/dl	32 - 35
HCT ( hematocrit )	44.9 %	36 - 46
RDWA	58.3	
RDW	13.8 %	11.5 - 14.5
<b>Absolute Leucocyte Counts:</b>		
Abs. Neutrophils	5.1	
Abs. Lymphocytes	2.6	
Abs. Eosinophils	0.7	

*Neetu*

Page 1 of 3

Dr. Neetu Dwivedi  
MD (Pathology)

Checked By :-  
Lab Technician  
Pathologist

# Dr. B. R. AMBEDKAR COMBINED HOSPITAL (MALE)

## ETAWAH DEPARTMENT OF PATHOLOGY "AN ISO 9001:2015 CERTIFIED LABORATORY"

Date : 22-Sep-2023      Reg/Ref: DMH-56 / 305522  
 Name : MR. SHAILENDRA NIGAM      Age/Sex : 52 Yrs./Male  
 Ref.By : Dr. SELF      Phone :      Ward : OPD  
 Receipt : NA  
 Requested Test : cbc, KFT, LFT, LIPID P., amylase, LIPASE, RBS, CRP, t3 t4 tsh, vb12, VITAMIN D, HBA1C  
 Coll Time : 22-Sep-2023 09:33 AM      Validate : 22-Sep-2023 01:22 PM      Prn. Time : 22-Sep-2023 01:24 PM

Investigation	Observed Values	Biological Ref. Interval
<b>HBA1C</b>		4.0 - 7.0
Glycosylated Haemoglobin	6.8 %	

Interpretation:

HBA1C	Degree of glucose control
> 8	Action suggested due to high risk of developing long term complications like Retinopathy, Nephropathy, Cardiopathy and Neuropathy
< 7	Goal
< 6	Non Diabetic Level

### HORMONE & IMMUNOLOGY ASSAY

<b>THYROID PROFILE</b>		
Serum T3	1.12 ng/mL	0.35 - 1.93
Serum T4	8.86 ug/dl	4.87-11.72
Serum TSH	3.6647 uIU/ml	0.35 - 4.94
<b>VITAMIN B 12</b>		25.1 - 165
Serum Vitamin B12	23.6 pmol/L	
<b>VITAMIN D</b>		3.4 - 155.9
VITAMIN D	21.7 ng/ml	

*Neetu*

Dr. Neetu Dwivedi  
MD (Pathology)

Page 3 of 3

Reprinted Report

"श्रीम स्वस्थ लाभ की कामना"

----- End of report -----

Reported By - RAJKUSHWAHA (COLLECTION-PC), SOMVIRYADAV (COLLECTION-PC),  
 Checked By -

Lab Pathologist

# Dr. B. R. AMBEDKAR COMBINED HOSPITAL (MALE)

## ETAWAH

DEPARTMENT OF PATHOLOGY

"AN ISO 9001:2015 CERTIFIED LABORATORY"

Date : 22-Sep-2023      Reg/Ref: DMH-56 / 305522  
Name : MR. SHAILENDRA NIGAM      Age/Sex : 52 Yrs./Male  
Ref.By : Dr. SELF      Phone :      Ward : OPD  
Receipt : NA  
Requested Test : cbc, KFT, LFT, LIPID P., amylase, LIPASE, RBS, CRP, t3 t4 tsh, vb12, VITAMIN D, HBA1C  
Coll Time : 22-Sep-2023 09:33 AM      Validate : 22-Sep-2023 01:22 PM      Prn. Time : 22-Sep-2023 01:24 PM

Investigation	Observed Values	Biological Ref. Interval
---------------	-----------------	--------------------------

### BIOCHEMISTRY

#### KIDNEY PANEL;KFT

Serum Urea	33.2 mg/dL.	10-45
Serum Creatinine	1.38 mg/dL.	0.5-1.5
Serum Uric Acid	<u>7.80 mg/dL.</u>	3.4 - 7.0
Serum Calcium, Total	8.36 mg/dl.	8.2 - 10.2

#### LIVER FUNCTION TEST

Serum Bilirubin, Total	0.66 mg/dl.	0.3-1.2
Serum Bilirubin, Direct	0.25 mg/dl.	0- 0.4
Serum Bilirubin, Indirect	0.41 mg/dl.	0.2-0.7
SGOT	26.7 IU/L	0-40
SGPT	39.8 IU/L	0-40
Serum Proteins	6.32 gm/dL.	6.0 - 7.8
Serum Albumin	4.21 gm/dL.	3.5 - 5.0
Serum Alkaline Phosphatase	175 IU/L	50-270

#### LIPID PROFILE

Serum Cholesterol	232 mg/dL.	130 - 200
Serum Triglycerides	181 mg/dL.	30 - 200
HDL Cholesterol	52 mg/dL	40- 65
LDL Cholesterol	144 mg/dL.	UP TO 150
VLDL Cholesterol	36 mg/dL.	12 - 30
CHOL/HDL	4.46	
LDL/HDL	2.77	

Serum Amylase	111.10 IU/L	<90
---------------	-------------	-----

<u>Serum Lipase</u>	<u>37.72 IU/l</u>	<u>&lt;38</u>
Plasma Glucose Random	95.4 mg/dL	70 - 140

#### C- REACTIVE PROTIEEN

CRP	1.9 mg/L	
-----	----------	--

*Neetu* 3

Page 2 of 3

Dr. Neetu Dwivedi  
MD (Pathology)

Checked By :-  
Lab Technician  
Pathologist



11-10-2014 08:40:43 AM

ID: 0000003320 Name: Y  
Gender: Unknown  
Race: Unknown  
Room: Technician  
<Minnesota Codes>  
6-5-0  
4-2-0 (aVF)  
9-4-1 (V3)

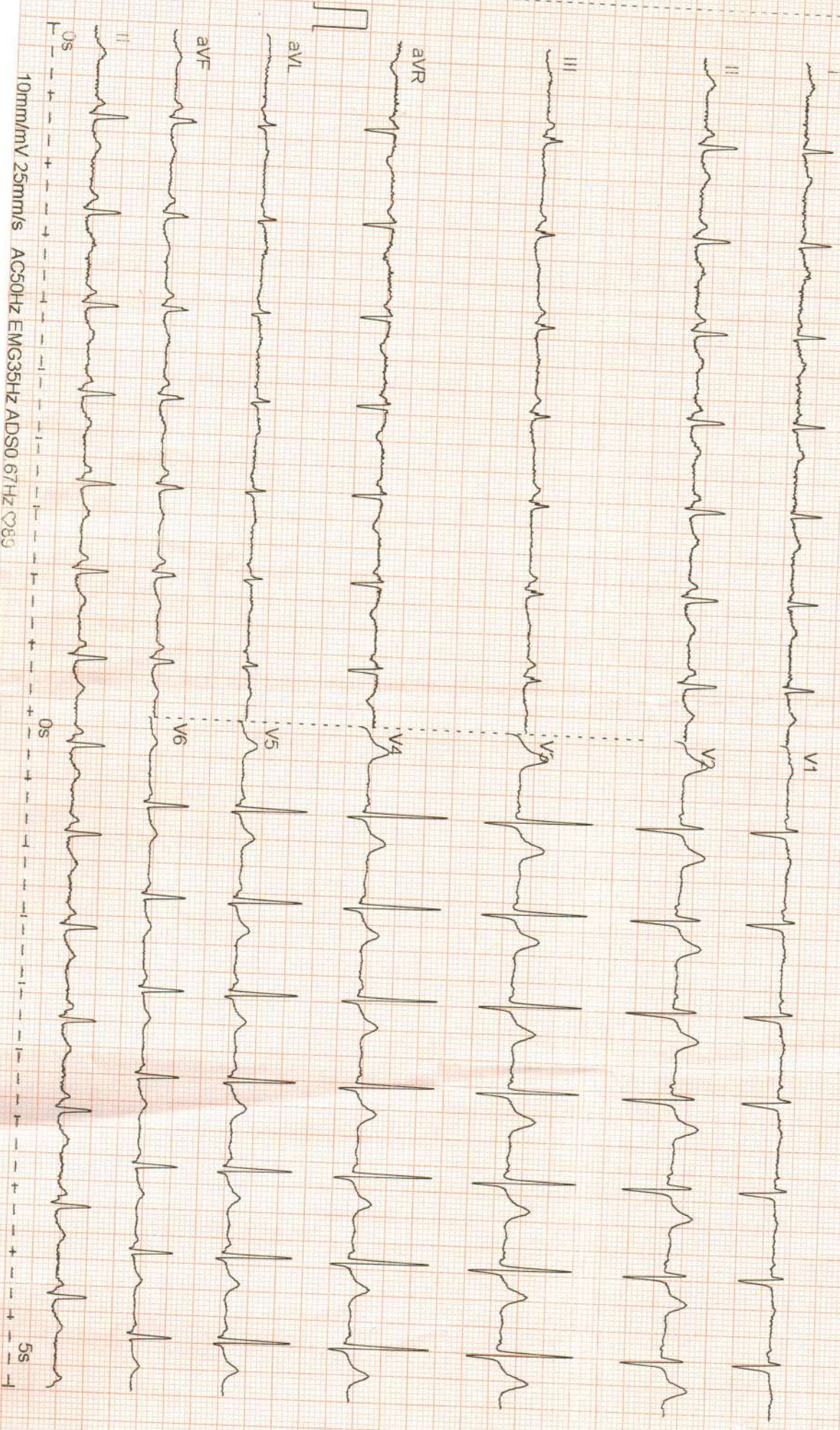
cm kg / mmHg  
Drugs:  
Bed No:

Shalinder Nigam 525 22/9/2014

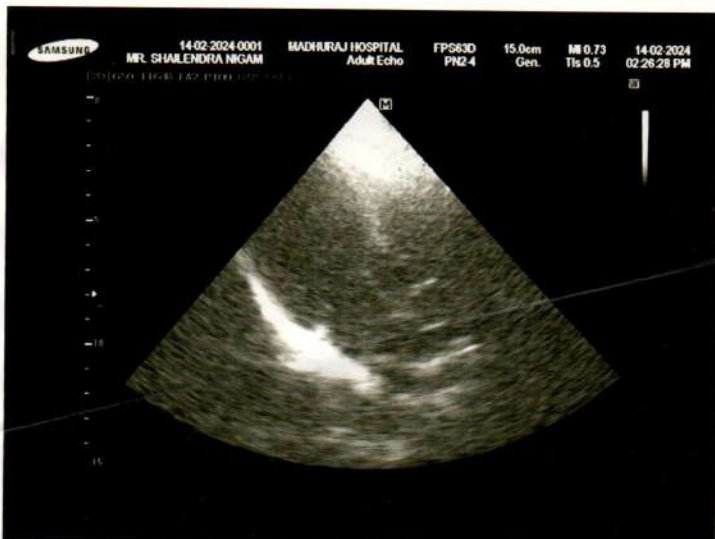
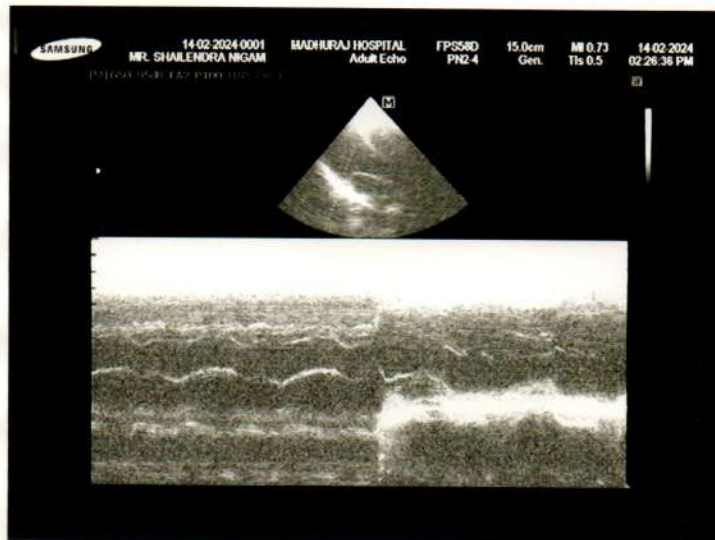
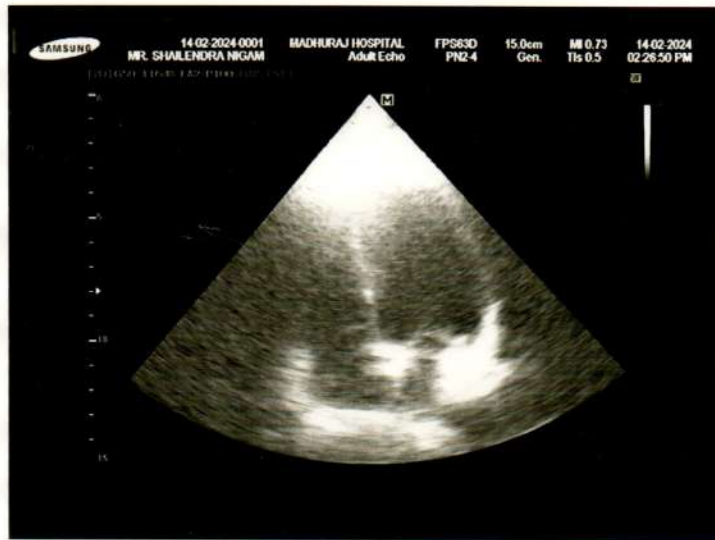
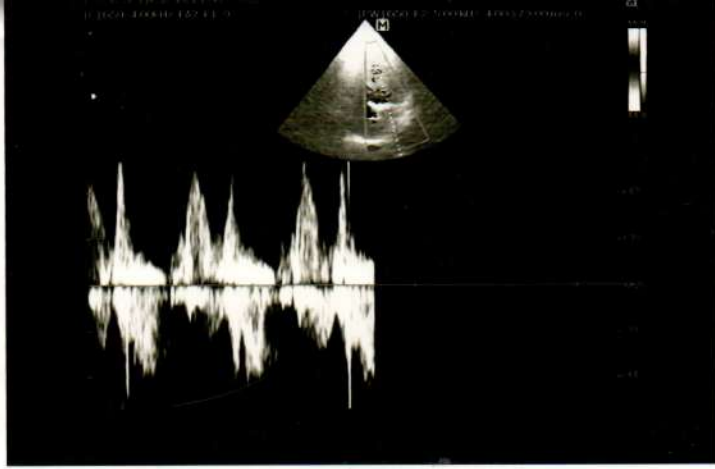
HR	P	PR	QRS	QT/QTc	RV5/SV1	RV5+SV1	RV6/SV2
89	88	109	96	332 / 406	76 / 147 / 122	1.288 / 0.704	1.992
	Dur	Int	Dur	Int	Axis	Amp	Amp
	89	109	96	332 / 406	76 / 147 / 122	1.288 / 0.704	1.992
							0.781 / 0.879

bpm <ECG Analysis Result>  
ms 800 Normal Sinus Rhythm  
ms 401 Short P-R Interval  
ms 632 Mild ST-T  
Abnormality (aVF)

Report Confirmed by:



10mm/mV 25mm/s AC50Hz EMG35Hz ADS0.67Hz Q83





**ECHOCARDIOGRAPHY AND COLOUR DOPPLER REPORT**

**NAME:** - MR. SHAILENDRA

**AGE/SEX:** 52YEARS /MALE

**DATE:** 14/02/2024

**REF. BY:** DR. DEEPAK AGARWAL

**INDICATION:-** Plan for Cholecystectomy.

**ECG:-** NSR,WNL.

**OBSERVATION:**

- Normal Chamber Dimension with Normal LV Systolic Function.  
LVEF- 60%.
- Grade I LV Diastolic Dysfunction.
- No Regional Wall Motion Abnormality at Rest.
- Normal Aortic Valve, No AR/ No AS.
- Normal Mitral Valve, No MR/ No MS.
- Normal Tricuspid Valve, No TR, No PAH.
- Normal: RA, RV, PA & IVC with Good RV function.
- Intact IAS/ Intact IVS.
- Normal Aortic Arch and Vessels.
- No Intra-cardiac clot/ No vegetation /No PE.
- IVC 1.2 cm with Normal Respiratory variation.

**FINAL IMPRESSION – Normal Chamber/Grade I LVDD/LVEF- 60 %.**



# MADHURAJ HOSPITAL (P) LTD.




CIN-U85110UP1984PTC006462  
Regd. add : 113/121-A, Swaroop Nagar,  
Kanpur-208002 (U.P.) INDIA  
Tel.: 0512-2556712-15-16-17-19, 2541404  
Our Toll Free No. 1800 1208700  
E-mail : madhurajhospital@gmail.com  
Website : www.madhurajhospital.org

DIMENSIONS :	PATIENT VALUES	NORMAL RANGE
LVID (Diastolic)	46	36- 56 mm
LVID (Systolic)	24	24 - 42 mm
IVS (Diastolic)	09	7 - 15 mm
IVS (Systolic )	14	7 - 15 mm
LVPW (Diastolic)	09	7 - 15 mm
LVPW (Systolic)	14	7 - 15 mm
AORTIC ROOT	22	22 - 37 mm
LEFT ATRIUM	24	19 - 24 mm

## DOPPLER FINDINGS:

VALVE	STENOSIS	REGURGITATION	AREA
MITRAL	NIL	Nil	
AORTIC	NIL	Nil	
TRICUSPID	NIL	Nil	
PULMONARY	NIL	Nil	

  
**DR. SHRIPAD KHAIRNAR**  
MD (MED), DM (CARD)  
CONSULTANT CARDIOLOGIST

Name: Mr shailendra -  
Patient ID: 110620

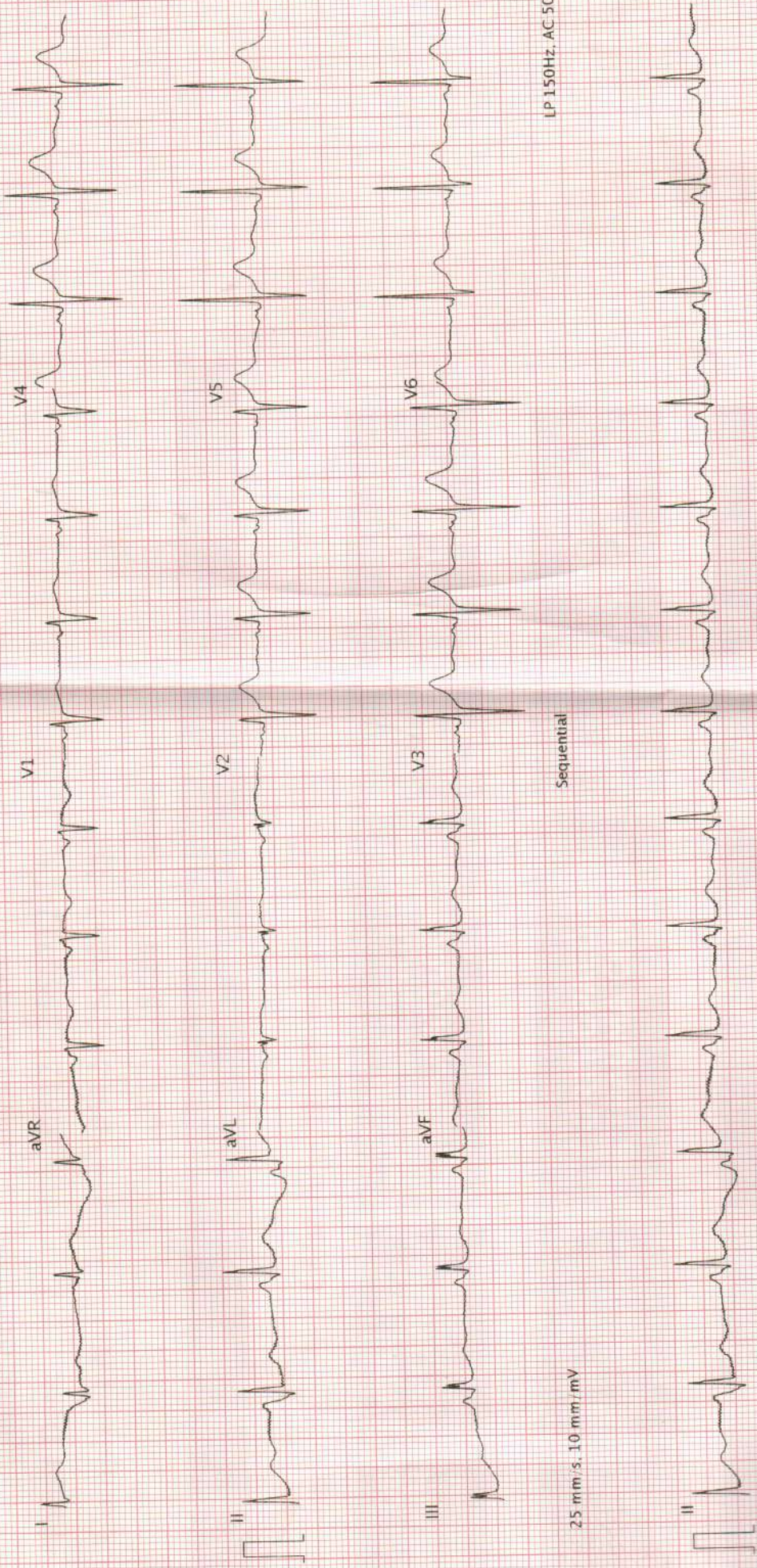
Date of birth: [Blank]  
Gender: Male  
Height: [Blank]  
Weight: [Blank]  
Ethnicity: Undefined  
Pacemaker: Unknown  
Indication: [Blank]  
Remark: [Blank]

HR: 82 bpm  
P: [Blank]  
PR: [Blank]  
QRS: 84°  
QT: 61°  
QTcB: 46°

728 ms  
91 ms  
114 ms  
76 ms  
353 ms  
414 ms

Sinus rhythm  
Normal electrical axis  
Normal ECG  
Unconfirmed report

Normal



LP 150Hz, AC 50Hz

Sequential

25 mm/s, 10 mm/mV

LP 150Hz, AC 50Hz

25 mm/s, 10 mm/mV  
AT 102 C... 2.0 (1080.009530)

Printed on 14.02.2024 13:43:44



# MADHURAJ HOSPITAL (P) LTD.



MH110620

CIN-U8511OUP1984PTC006462  
Regd. add : 113/121-A, Swaroop Nagar,  
Kanpur-208002 (U.P.) INDIA  
Tel.: 0512-2556712-15-16-17-19, 2541404  
Our Toll Free No. 1800 1208700  
E-mail : madhurahospital@gmail.com  
Website : www.madhurahospital.org

SNo. :	Reg No :	OPD95745	Patient Name :	Mr. shailendra nigam
TokenNo :	11	Reg Date :	14/Feb/2024	Age : 53 YRS / M Mobile No. : 9838113090
Address :	KANPUR		Guardian Name:	
Doctor Name :	Dr. DEEPAK AGARWAL (GENERAL SURGEON)			Doctor RegNo :
MBBS, MS				

Department : GENERAL SURGERY

BP :

Pulse :

Plan for choleystomy

SBY/M

no hwt/ hwt crop

no cardiac complaints

no. good JJ capacity

018

gc bur

P 5/10 min.

bn h/w/sg

ws 5/10

w clear

Uter: - NTR. w.m.

20h: - w/h cont.

w/w m/a.

cont. 2 w/m.

- PEPID = 0

- Plan h. mben dr se = low cont. RAC

SHAILRNDRA NIGAM, DR.DEEPAK AGARWAL \* MADHURAJ HOSPITAL (P) LTD. VS8002736 24 02 14 11 14.02.2024 12:17:20

TIs <0.1  
Tlb <0.1  
MI 0.9

Cl 5 RS  
ABD  
16.8cm / 1.2  
60° / 20Hz  
Abdomen H.R.  
HM PI 7.70 2.10  
AO 95%  
Gn -4  
C6 / M4  
FF3 / E2  
SRI II 2 / CRI 2

PROSTATE

1 D	3.73cm
2 D	2.62cm
3 D1	2.78cm
D2	3.65cm
Vol	19.392cm <sup>3</sup>

SHAILRNDRA NIGAM, DR.DEEPAK AGARWAL \* MADHURAJ HOSPITAL (P) LTD. VS8002736 24 02 14 11 14.02.2024 12:14:52

TIs <0.1  
Tlb <0.1  
MI 0.9

Cl 5 RS  
ABD  
16.8cm / 1.2  
60° / 20Hz  
Abdomen H.R.  
HM PI 7.70 2.10  
AO 95%  
Gn 5  
C6 / M4  
FF3 / E2  
SRI II 2 / CRI 2

PANCREAS

SHAILRNDRA NIGAM, DR.DEEPAK AGARWAL \* MADHURAJ HOSPITAL (P) LTD. VS8002736 24 02 14 11 14.02.2024 12:16:41

TIs <0.1  
Tlb <0.1  
MI 0.9

Cl 5 RS  
ABD  
16.8cm / 1.2  
60° / 20Hz  
Abdomen H.R.  
HM PI 7.70 2.10  
AO 95%  
Gn -4  
C6 / M4  
FF3 / E2  
SRI II 2 / CRI 2

LEFT KIDNEY

1 D	8.76cm
2 D	5.01cm

SHAILRNDRA NIGAM, DR.DEEPAK AGARWAL \* MADHURAJ HOSPITAL (P) LTD. VS8002736 24 02 14 11 14.02.2024 12:14:29

TIs <0.1  
Tlb <0.1  
MI 0.9

Cl 5 RS  
ABD  
16.8cm / 1.2  
60° / 20Hz  
Abdomen H.R.  
HM PI 7.70 2.10  
AO 95%  
Gn 2  
C6 / M4  
FF3 / E2  
SRI II 2 / CRI 2

LIVER

SHAILRNDRA NIGAM, DR.DEEPAK AGARWAL \* MADHURAJ HOSPITAL (P) LTD. VS8002736 24 02 14 11 14.02.2024 12:15:07

TIs <0.1  
Tlb <0.1  
MI 0.9

Cl 5 RS  
ABD  
16.8cm / 1.2  
60° / 20Hz  
Abdomen H.R.  
HM PI 7.70 2.10  
AO 95%  
Gn 5  
C6 / M4  
FF3 / E2  
SRI II 2 / CRI 2

RIGHT KIDNEY

1 D	8.88cm
2 D	3.83cm

SHAILRNDRA NIGAM, DR.DEEPAK AGARWAL \* MADHURAJ HOSPITAL (P) LTD. VS8002736 24 02 14 11 14.02.2024 12:14:01

TIs <0.1  
Tlb <0.1  
MI 0.9

Cl 5 RS  
ABD  
16.8cm / 1.2  
60° / 20Hz  
Abdomen H.R.  
HM PI 7.70 2.10  
AO 95%  
Gn 2  
C6 / M4  
FF3 / E2  
SRI II 2 / CRI 2

STONE GALL BLADDER



MADHURAJ HOSPITAL (P) LTD.



CIN-U8511OUP1984PTC006462  
Regd. add : 113/121-A, Swaroop Nagar,  
Kanpur-208002 (U.P.) INDIA  
Tel.: 0512-2556712-15-16-17-19, 2541404  
Our Toll Free No. 1800 1208700  
E-mail : madhurajhospital@gmail.com  
Website : www.madhurajhospital.org


Shailendra Nirgam -

17/2/2014

△ Cholelithiasis

40  
Urani to have gall stones  
No Urani. Comorbidity

AM  
Lap cholelithectomy



20  
- r/s white dot  
- Cardiac opinion.

21  
Contracted, gall bladder.  
Slurry stone.

- Admit on 19/2/2014.  
- opiate at 10pm.  
- cut  
- Pt. poplite  
- nit only.  
- 2ur. ~~sin~~ as as let.  
- X-ray igu / at 9 AM.  
- of Auler

22





# MADHURAJ HOSPITAL (P) LTD.



CIN-U8511OUP1984PTC006462  
 Regd. add : 113/121-A, Swaroop Nagar,  
 Kanpur-208002 (U.P.) INDIA  
 Tel.: 0512-2556712-15-16-17-19, 2541404  
 Our Toll Free No. 1800 1208700  
 E-mail : madhurajhospital@gmail.com  
 Website : www.madhurajhospital.org

## DISCHARGE SUMARRY

Registartion No. :	I240219003 / MADHURAJ	UHID NO.	MH110620
Patient Name :	Mr. SHAIENDRA NIGAM (PARAMOUNT)	Age / Gender :	53 YRS / M
Guardian Name :	LT. DR O.P. NIGAM	Contact No. :	9838113090
Bed No. :	202	Height / Weight :	68kg / 172cm
Address :	39/16 MESTON ROAD KANPUR		
Date of Admjsion :	19/Feb/2024 07:46 AM	Date of Discharge :	20/Feb/2024 11:36 AM

### PATIENT'S COMPLAINS DURING ADMISSION

PAIN IN RIGHT UPPER ABDOMEN , BELCHING PRESENT

### FINAL DIAGNOSIS

CHRONIC CALCULUS CHOLECYSTITIS

### CLINICIAN INCHARGE

Dr. DEEPAK AGARWAL (GENERAL SURGEON)-----MBBS, MSRegistration No:32775

### OPERATIVE NOTES

LAPAROSCOPIC CHOLECYSTECTOMY DONE UNDER GA ON 19/2/2024

### TREATMENT GIVEN DURING ADMISSION

INJ. XONE  
 INJ. ACILOC  
 IV FLUIDS  
 OTHER SUPPORTIVE TREATMENT

### HOSPITALIZATION SUMMARY

PATIENT PRESENTED HERE WITH THE COMPLAINTS OF PAIN IN RIGHT UPPER ABDOMEN , BELCHING PRESENT. DIAGNOSED AS A CASE OF CHRONIC CALCULUS CHOLECYSTITIS CHRONIC CALCULUS CHOLECYSTITIS . PATIENT WAS MANAGED SURGICALLY LAPAROSCOPIC CHOLECYSTECTOMY DONE UNDER GA ON 19/2/2024. SURGERY WAS UNEVENTFULL. PATIENT RESPONDED WELL TO THE TREATMENT AND IS BEING DISCHARGE IN A STABLE CONDITION. PATIENT ADVISED TO CONTINUE WITH MEDICAL MANAGEMENT AND FOLLOW UP AS ADVISED WITH A PRIOR APPOINTMENT.

### INVESTIGATIONS :

ATTACHED

Obs Value	Invest Date
-----------	-------------

Px	Dose	Amount	Time	Route	Remark
----	------	--------	------	-------	--------

### ADVISE ON DISCHARGE : Rx

TAB. CEFTUM 500 MG 1 TAB TWICE A DAY  
 TAB. SIGNOFLAM 1 TAB TWICE A DAY  
 CAP. PAN- D 1 CAP ONCE A DAY (E/S)

FOR 5 DAYS