

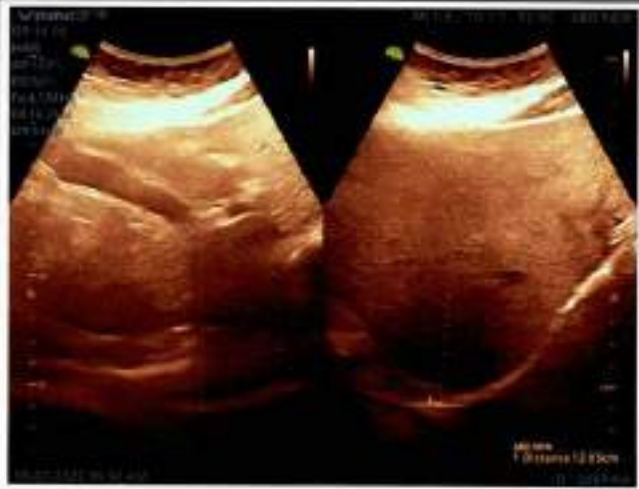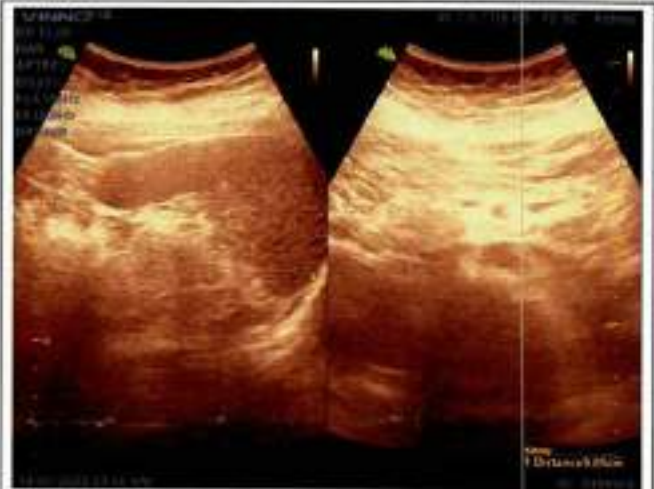
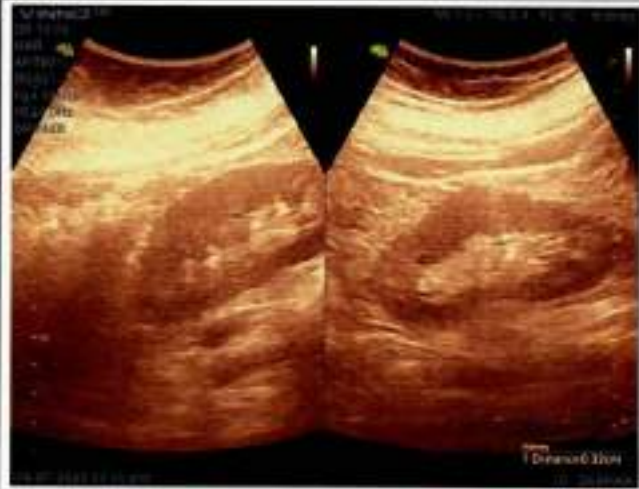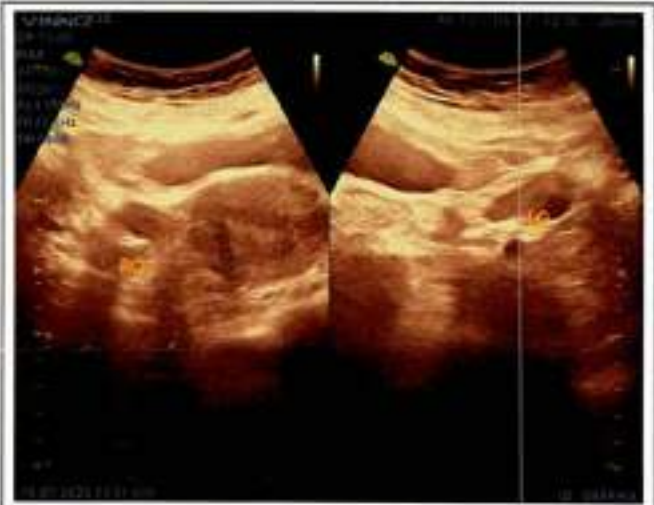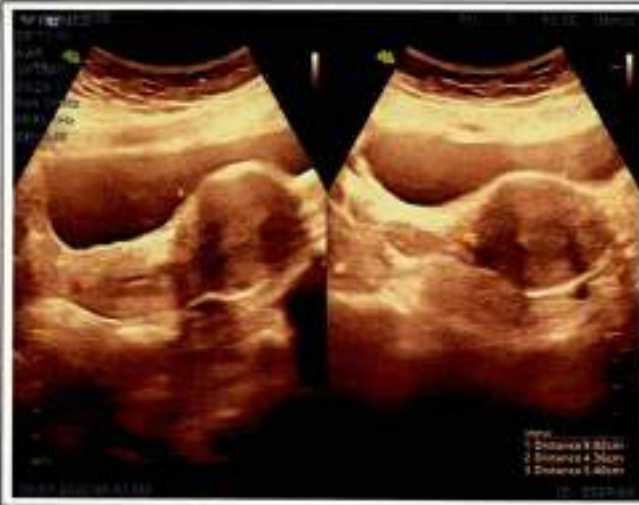SAHARA ULTRASOUND CENTER

Name or ID: DEEPIKA

Exam Date: 19-07-2022

Ref.Physician:

Operator:





Regd. SWT/USG/TEM/15/2020

Ph. : 9792244643, 8115691750

SAHARA ULTRASOUND CENTER

Sahara Hospital, Near- Tehsil, Bhinga-Shrawasti

Email Id. saharaultrasound5019@gmail.com



PATIENTS NAME: MRS. DEEPIKA KANSAL

AGE/SEX: 40YRS/FEMALE

REF. BY: SELF

DATE: 02/11/2022

USG WHOLE ABDOMEN FEMALE

LIVER: Liver is normal in shape and size 127mm with hypochoic echotexture. I.H.B.R. is not dilated. There is no space occupying lesion. Portal vein is normal.

G. BLADDER: Gall bladder is normal and well distended. No echogenic focus/mass is seen. **Wall appease are thickened 6.3mm.** Common bile duct is normal.

PANCREAS: Pancreas is normal in shape and size. No focal lesion is seen.

SPLEEN: Spleen is normal in shape and size(76mm) . No focal lesion is seen.

KIDNEYS: Both kidneys are normal in shape and size. Right kidney measure 93x45mm and left kidney measure 102x39mm. **Single echogenic calculus (3.2mm) are seen in middle calyx of left-kidney.** Differentiations are normal. No backpressure changes are seen.

U. BLADDER: Urinary bladder is normal and well distended. No echogenic focus/mass is seen. Wall is regular and smooth.

UTERUS: Uterus is antverted and enlarge in shape and size (92x42x33mm). Myometrium is homogeneous. Endometrial echoes are distinct. No mass/gestation is seen. Cervix appears normal.

ADNEXAE: No cyst/mass is seen in both adnexae. No follicular cyst is seen.

OTHERS: No ascites is seen. Lymph nodes are not enlarged. **Gassy bowel loops are seen free fluid seen P.O.D.collection.**

IMPRESSION: Findings are suggestive of → Cholecystitis.

- Left renal small calculus.
- Bulky uterus with P.I.D.
- Bowel loops gas.

Consultant

OUR FACILITIES

Premium Colour Doppler from Siemens, Carotid Doppler, Vascular Doppler, Fetal Doppler, Echocardiography, Ultrasound, TVS, TIFFA, High Resolution Ultrasound of Small Parts.

TIMING : 9:00 A.M. to 6:00 P.M.

(THIS REPORT IS NOT VALID FOR MEDICO LEGAL PURPOSE)

भ्रूण लिंग की जाँच करवाना एक कानूनी अपराध है। यह कार्य हमारे यहाँ नहीं होता है।

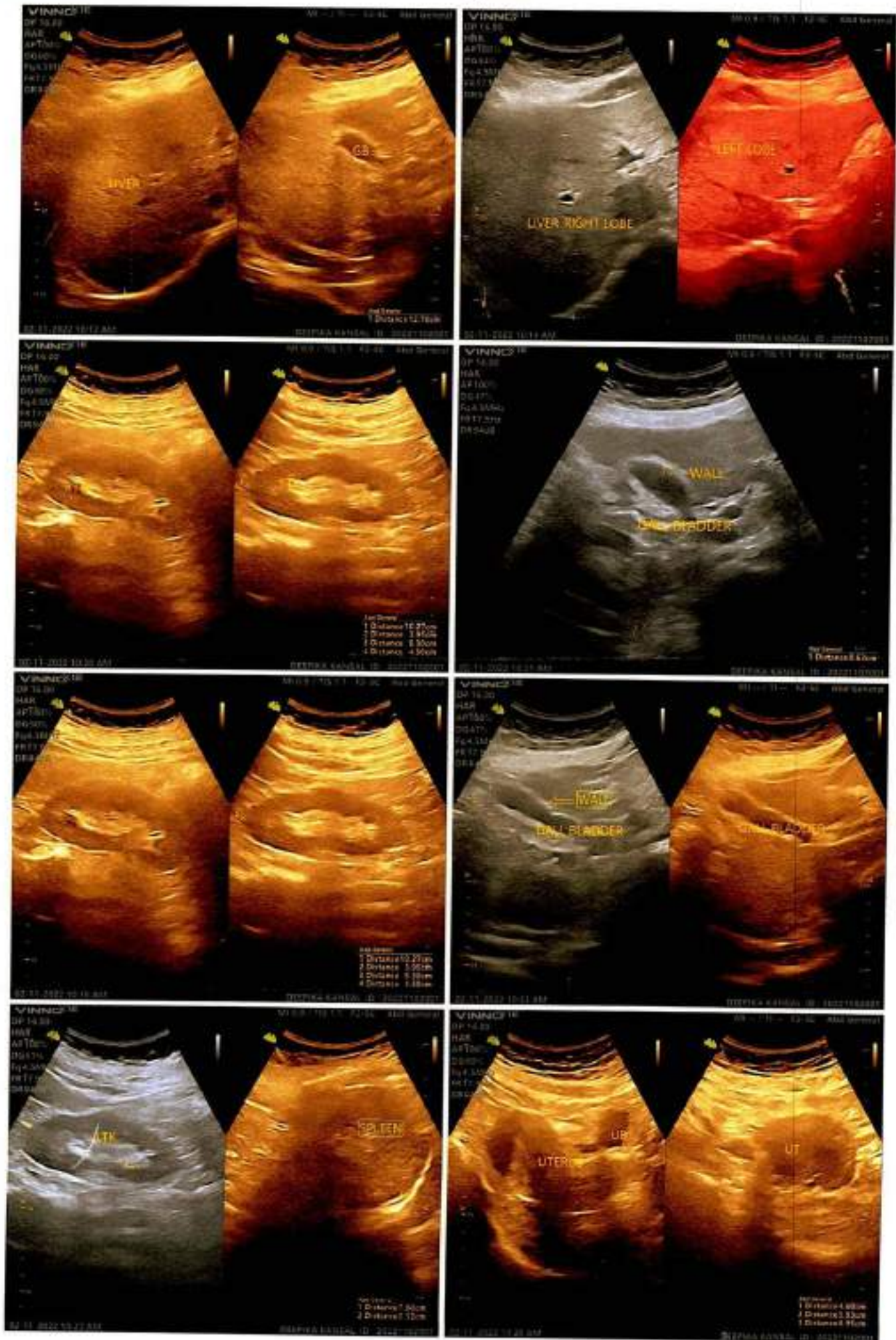
SAHARA ULTRASOUND CENTER

Name of ID: DEEPIKA KANSAL

Exam Date: 02-11-2022

Ref. Physician:

Operator:



OPD Prescription

Reg. No 200778048
Name Mrs. DEEPIKA KANSAL
Doctor/Unit Dr. ALKA KRIPLANI
Category TARIFF VERSION 11.0
Room No
Doctor Mob.
Day & Time MON-SAT-09:00AM-05:00PM

Issue Date May 15 2023 10:53AM
Age/Sex 44 Yrs/Female
Department Obstetrics & Gynaecology
Pay Mode Cash / 1400.00
Queue No.
Patient Mob. 8840838047

Note : Kindly take Prior Appointment for Consultation and diagnostic.

BP:	Height:	Weight:	BMI:	Pulse:	Temperature:	Respiration:
-----	---------	---------	------	--------	--------------	--------------

Allergies:

~~Multiple allergies~~ FUC of
AUB-A, L

History and complaints:

LMP - 30/4/23

40- burning micturition
pain lower abdomen
spotting on & off.

Examination:

Hystero, GA, polypertomy, Mirena insertion
(9/5/23).

Provisional/Final Diagnosis:

APE - Proliferative
endometrium.

Drug orders:

Adv (Dr Alka Kriplani)

Nutritional Screening:

LBC - NLLM

• keep menstrual record

• Fosfomicin sachet with
one glass of water - Hfs
(after submitting cerin report)

Advice:
(Lifestyle / Rehab / Diet)

to do:
UKR
DPS

Follow up:

Investigations:

• P. Pyridium 1tab thrice daily
- 3 days

Date: _____

Reception-0124-4585555 Ambulance-0124-4585666

• P. Emmanu - D 1 tab three
daily - 7 days

Review with reports.

7 days

Deepika Kansal
44 years.

8/3/23

Ch pain lower abdomen
Dysmenorrhoea X 1.5 months.
Heavy flow.

N/H:- LMP - 30/4/23, 7d/30d/Heavy flow

O/H:- Nulliparous.

P/H:- N/S.

O/E:-

P/E - Nulliparous OS
No lesions / no prolapse.

P/V - ut - RU bulky,
mobility restricted
Ext. cervix free.

Actv:-

- DOA - 9/5/23
- DOS - 10/5/23
- PAc (1st floor)
- COVID RT-PCR

Plucker

Plan:- Hyster + EA + microneedle
insertion.
+ Polypectomy

OB1186 + OB1165 +
OB1190



Reception-0124-4585555 Ambulance-0124-4585666

Registered Address: Paros Health - C-1, Sushant Lok, Phase-1, Sector-43, Gurugram (Haryana)

 @ParosHealth

8/5/23

USG

Ut - (N) size, ET - 6.6mm
Intraluminal fibroid 0.6x0.6cm
in (2) ant. wall (FIGO-4)

B/L ovaries (N).

- Diffuse Adenomyosis.



DEPARTMENT OF RADIOLOGY

NAME	DEEPIKA KANSAL	STUDY DATE	08-05-2023 13:34:29
AGE/GENDER	44Y 8M 17D / F	REG NO.	200778048
ACC NO	10251127	MODALITY	US
REFERRED BY	Dr. ALKA	REPORT DATE	08-05-2023 14:27:12

ULTRASOUND WHOLE ABDOMEN WITH TVS**Findings:**

Liver : is normal in size. Parenchymal echotexture is normal and no focal area of altered echogenicity is seen. IHBR not dilated. Portal vein radicles are normal. CBD and MPV are normal in diameter.

GB : is distended. Lumen is echofree and walls are normal.

Pancreas : shows normal size and parenchymal echotexture.

Spleen : is normal in size (10.3 cm) and echotexture .

Right Kidney : is normal in position size and morphology. CMD is maintained. No evidence of any calculus detected. Pelvicalyceal system is normal.

RK : 8.7 x 3.7 cm

Left Kidney : is normal in position size and morphology. CMD is maintained. A calculus measuring 4.5 mm is seen at lower pole. Pelvicalyceal system is normal.

LK : 9.0 x 4.2 cm

Urinary Bladder : shows normal lumen and walls.

Uterus : is normal in size (8.3 x 3.9 x 4.3 cm) with diffusely heterogeneous echotexture. Endometrial echo is central (6.6 mm) with ill-defined endomyometrial junction . An intramural fibroid of size 0.6 x 0.6 cm in right anterior wall (FIGO type 4). Cervix shows few nabothian cysts.

Both ovaries are well visualized and are normal.

Registered Address: Paras Health - C-1, Sushant Lok, Phase-1, Sector-43, Gurugram (Haryana)
Right Ovary : 2.9 x 2.1 x 1.7 cm, volume = 5.8 cc.

Left Ovary : 2.5 x 2.0 x 1.9 cm, volume = 5.2 cc.

 @ParasHealth

P/S read the instructions on the reverse side of this report before approaching the hospital authority.

DEPARTMENT OF RADIOLOGY

NAME	DEEPIKA KANSAL	STUDY DATE	08-05-2023 13:34:29
AGE/GENDER	44Y 8M 17D / F	REG NO.	200778048
ACC NO	10251127	MODALITY	US
REFERRED BY	Dr. ALKA	REPORT DATE	08-05-2023 14:27:12

No peritoneal collection or free fluid identified.

IMPRESSION:

- Left renal calculus
- Normal sized uterus with diffusely heterogeneous uterine echotexture likely diffuse Adenomyosis.
- Small Intramural uterine fibroid (FIGO type 4).
- Cervix show few nabothian cyst.

Please correlate clinically



● Dr. Kavita Kapoor, MD
● Sr. Consultant
● MNC Reg No.-011960

Registered Address: Paras Health - C-1, Sushant Lok, Phase-1, Sector-43, Gurugram (Haryana)
Tel: 0124-4585555 Fax: 0124-4585572 **Emergency: 0124-4585666** Email: contact.gurugram@parashospitals.com

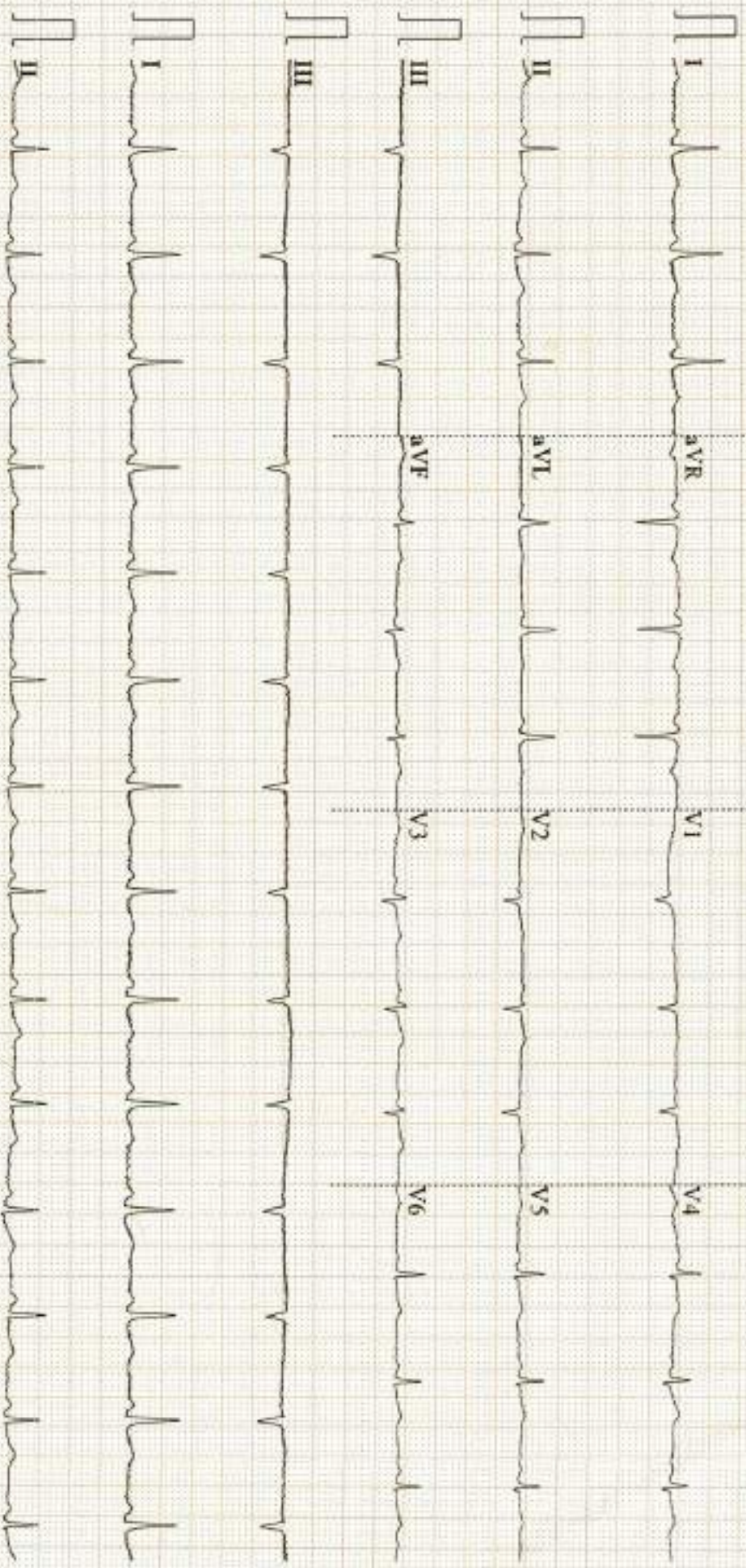
 @ParasHealth

P/S read the instructions on the reverse side of this report before approaching the hospital authority.

HR	84	bpm
P	94	ms
PR	127	ms
QRS	77	ms
QT/QTc	338/402	ms
P/QRS/T	30/136	°
RV5/SV1	0.399/0.267	mV

Diagnosis: Inferior wall
 Sinus Rhythm
 Suspect Anteroseptal Myocardial Infarction?(V1,V2)
 Low Voltage(Chest Leads)

Report Confirmed by:



11/05/2023 8:55:43
FARMS HOSTAL
SUSPENSE LOK SELC-40
SURGAMIN

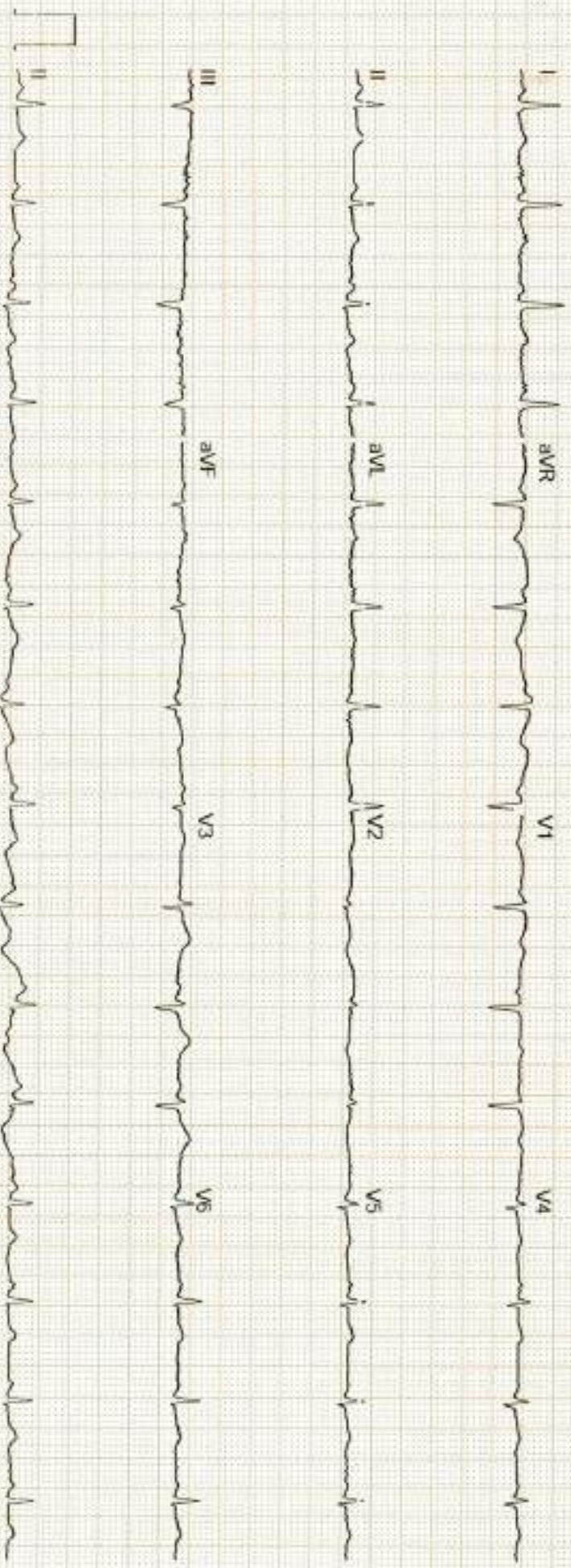
Viewport
Epoxy
Order Number
Installation
Medication 1
Medication 2
Medication 3

Technician
Ordering P/N
Refering P/N
Assembling P/N

QRS : 60 ms
QT / QTdiaz : 390 / 428 ms
PR : 114 ms
P : 74 ms
RR / PP : 868 / 666 ms
P / QRS / T : 38 / 4 / 0 degrees

Normal sinus rhythm
Low voltage QRS
Borderline ECG

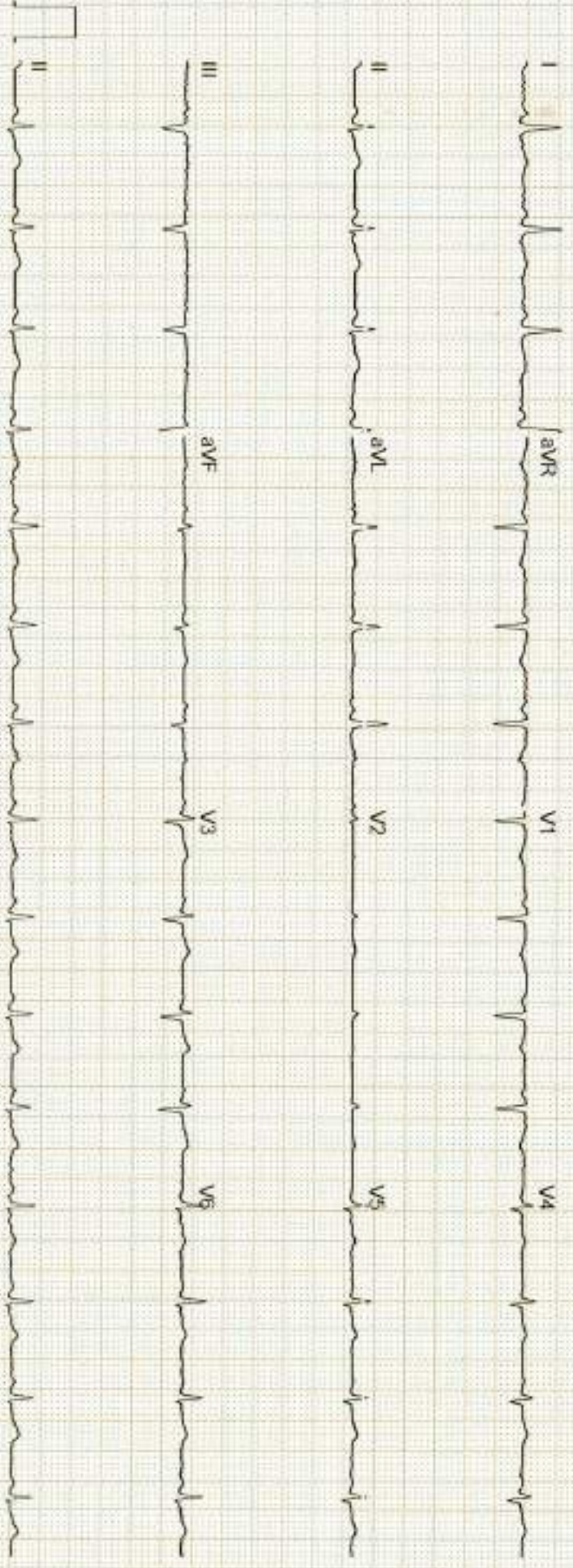
90 bpm
--- mmHg



QRS 64 ms
QT / QTcBaz 350 / 432 ms
PR 116 ms
P 85 ms
RR / PP 654 / 652 ms
P / QRS / T 31 / -2 / 31 degrees

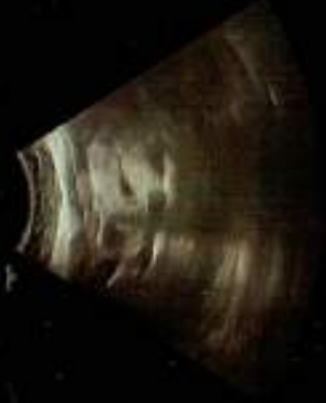Normal sinus rhythm
Low voltage QRS
Borderline ECG

Technician
Ordering Ph
Referring Ph
Attending Ph




PARAS HOSPITAL

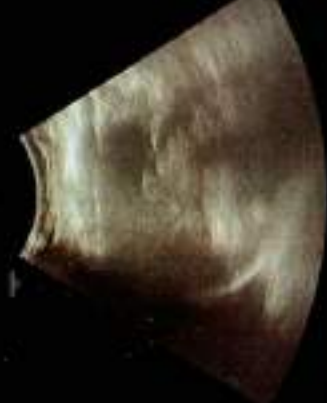
MR. JAYANTH
P. JAYANTH
MURUGAN
20070804 21:00:11:17
30070804 21:00:11:17
30070804 21:00:11:17



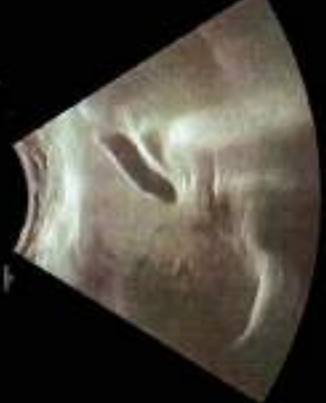MR. JAYANTH
P. JAYANTH
MURUGAN
20070804 21:00:11:17
30070804 21:00:11:17
30070804 21:00:11:17



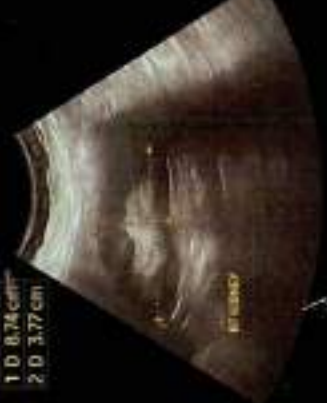MR. JAYANTH
P. JAYANTH
MURUGAN
20070804 21:00:11:17
30070804 21:00:11:17
30070804 21:00:11:17



MR. JAYANTH
P. JAYANTH
MURUGAN
20070804 21:00:11:17
30070804 21:00:11:17
30070804 21:00:11:17



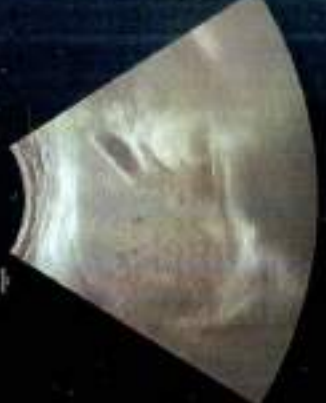MR. JAYANTH
P. JAYANTH
MURUGAN
20070804 21:00:11:17
30070804 21:00:11:17
30070804 21:00:11:17



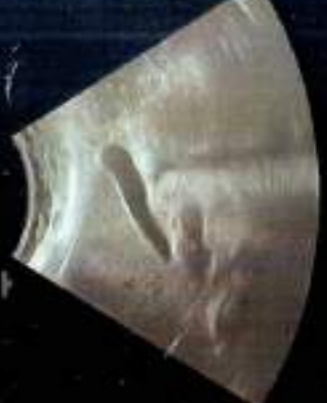MR. JAYANTH
P. JAYANTH
MURUGAN
20070804 21:00:11:17
30070804 21:00:11:17
30070804 21:00:11:17



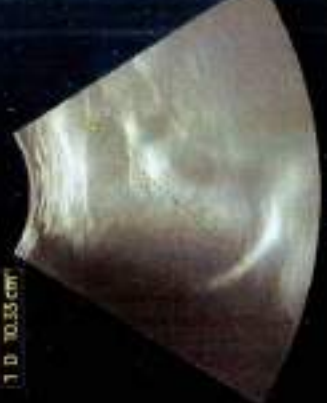
MR. JAYANTH
P. JAYANTH
MURUGAN
20070804 21:00:11:17
30070804 21:00:11:17
30070804 21:00:11:17



MR. JAYANTH
P. JAYANTH
MURUGAN
20070804 21:00:11:17
30070804 21:00:11:17
30070804 21:00:11:17




MR. JAYANTH
P. JAYANTH
MURUGAN
20070804 21:00:11:17
30070804 21:00:11:17
30070804 21:00:11:17



MR. JAYANTH
P. JAYANTH
MURUGAN
20070804 21:00:11:17
30070804 21:00:11:17
30070804 21:00:11:17



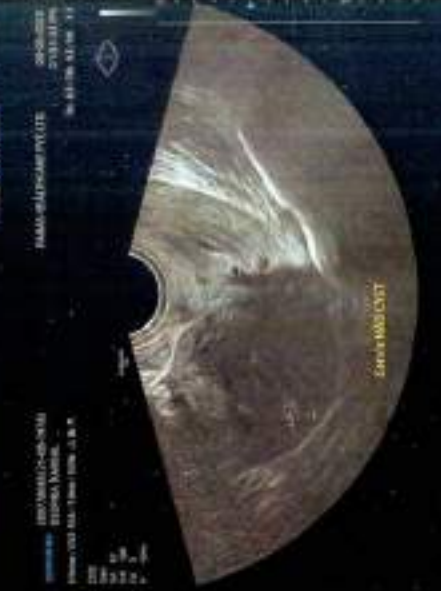
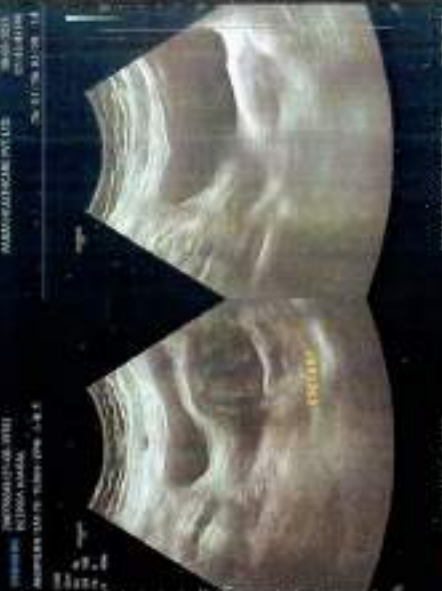
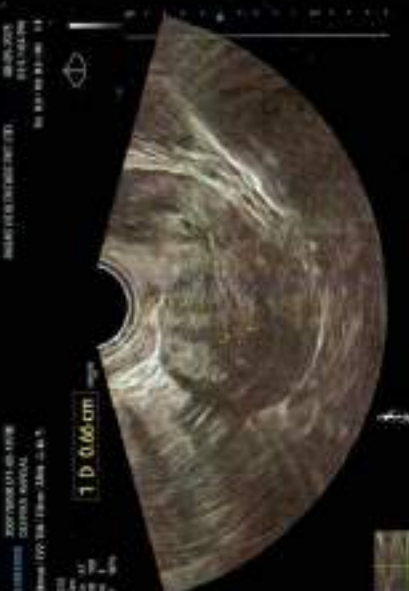
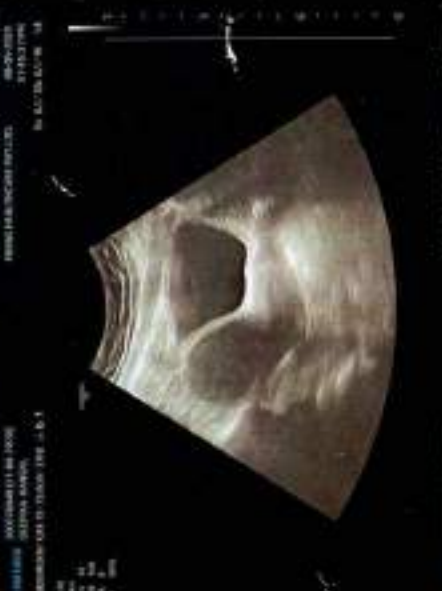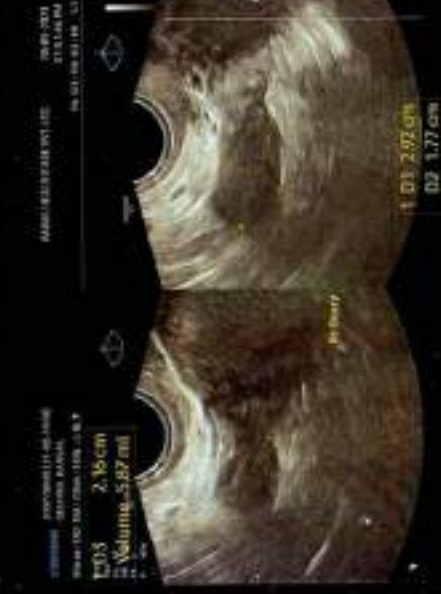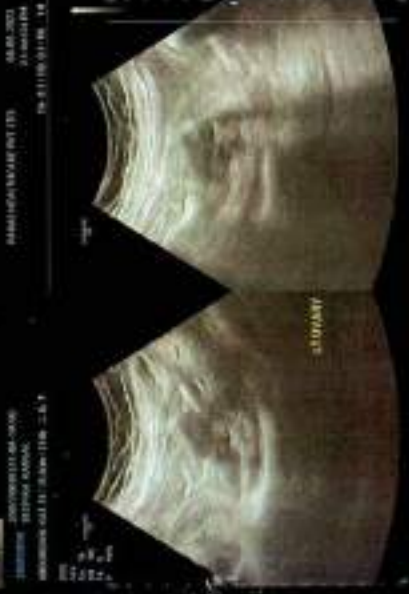
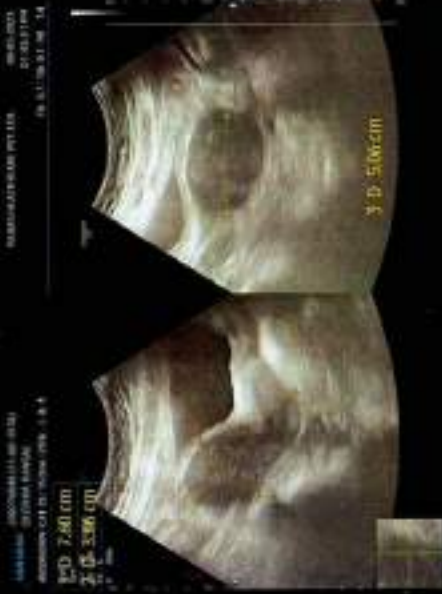MR. JAYANTH
P. JAYANTH
MURUGAN
20070804 21:00:11:17
30070804 21:00:11:17
30070804 21:00:11:17



MR. JAYANTH
P. JAYANTH
MURUGAN
20070804 21:00:11:17
30070804 21:00:11:17
30070804 21:00:11:17



PARAS HOSPITAL



ART BY NALLA TR



बद्री प्रसाद शुक्ला मेमोरियल हॉस्पिटल प्रा० लि०

पुलिस लाइन रोड, बहराइच, Mob.: 9792110002



डा० एस० के० शुक्ला

एम.बी.बी.एस., एम.एस. (सर्जन)

समय : प्रातः 09 से 1.30 बजे तक कार्य आपरेशन के बाद ओ०पी०डी० रविवार बन्द रहेगी।

डा० संगीता मेहता (D.G.O.) (पतिता एवं प्रसूति रोग विशेषज्ञ) सोमवार से शनिवार प्रातः 9:30 से 12 बजे तक	मरीज का नाम <u>Deepika Kumbhar</u>
डा० बी०के० सिंह एम.डी. (नवजात शिशु एवं बाल रोग विशेषज्ञ) समय : सोमवार से शनिवार	पता _____
डा० नवनीत त्रिपाठी एम.एस., एम.सी.एच., इन्फोर्मेशन सर्जन घायराइड एवं नेस्ट कैरर सर्जन प्रत्येक माह के दूसरे शनिवार	उम्र <u>37</u> लिंग <u>Female</u> दिनांक <u>31/11/2022</u>
डा० अभिवेक गुप्ता एम.एस., एम.सी.एच. (न्यूरो सर्जन) प्रत्येक माह के दूसरे व चौथे शनिवार	<u>37-11-20</u>
डा० पीयूष पी० सिंह एम.एस., एम.सी.एच., यूरो सर्जन (युवक, पथरी, प्रोस्टेट सर्जरी एवं यूरल रोग) प्रत्येक माह के प्रथम रविवार	<u>Dr. P. K. Mishra</u>
डा० मंजुश कुमार श्रीवास्तव एम.डी. जनरल एवं लेप्रोटोमिक सर्जन प्रत्येक माह के दूसरे व चौथे रविवार	<u>Dr. Manjush Kumar</u>
डा० अमिताभ मिश्रा सी.डी.एच. मुख एवं कौल रोग विशेषज्ञ सोमवार, बुधवार, शुक्रवार, शनिवार	<u>Dr. Amitabh Mishra</u>
डा० दिव्येश बरनवाल एम.डी. मानसिक, नख मुक्ति, निर्णय एवं सेलर रोग विशेषज्ञ सोमवार से शनिवार प्रातः 10 से 7 बजे तक	<u>Dr. Divyesh Baranwal</u>
डा० सोमित सिंह एम.डी.नेटवर्क पुर्वा रोग विशेषज्ञ (फ्लोराइड नेफ्रोलॉजिस्ट) प्रत्येक माह के तीसरे रविवार	<u>Dr. Somit Singh</u>
डा० जयनिल अनिल वागबडे एम.एस., डी.एन.बी. (यूरोलॉजिस्ट) युवक एवं बाल रोग विशेषज्ञ, प्रत्येक माह के तीसरे रविवार	<u>Dr. Jaynil Anil Waghade</u>
डा० सुदीप गर्ग एम.एस., एम.सी.एच., कैरर सर्जन प्रत्येक माह के पहले शनिवार	<u>Dr. Sudip Garg</u>
डा० रिचा श्रीवास्तव एम.एस., एम.सी.एच., प्लास्टिक सर्जन प्रत्येक माह के पहले शनिवार	<u>Dr. Richa Shrivastava</u>
डा० श्यामेन्द्र शर्मा एम.एस., एम.सी.एच., पीडियेट्रिक सर्जन प्रत्येक माह के दूसरे रविवार	<u>Dr. Shyamendra Sharma</u>
डा० फिरोज खान एम.एस., एम.सी.एच., यूरो सर्जन प्रत्येक माह के पहले व तीसरे बुधवार	<u>Dr. Feroz Khan</u>

गर्ल्स हॉस्टल की सुविधा उपलब्ध **एस.के.एस. ग्रुप ऑफ इन्स्टीट्यूशन** Mob: 7800009791 7800009792

उपलब्ध कोर्स- बी.एस.सी. नर्सिंग, जी०एन०एम०, ए०एन०एम०, बी० फार्मा, डी० फार्मा, डिप्लोमा इन ओरिंटीड टेक्नीशियन, डिप्लोमा इन इमरजेंसी एम्बुलेंस ड्राइवर टेक्नीशियन, डिप्लोमा इन ऑप्टोमेट्री, डिप्लोमा इन फिलियथेरेपी, डिप्लोमा इन मिओनेटोलॉजी टेक्नीशियन, डिप्लोमा इन डायलेसिस टेक्नीशियन

नोट * यह पत्राचार मंडिको लीगल केस के लिए मान्य नहीं है। * आज के दिन से जोड़ कर यह पत्राचार दिनों के लिए मान्य होगा। * दूरबीन बिधि द्वारा फिल के फेस की पथरी, अपेंडिसिस, शर्मिका, यूरल की पथरी एवं प्रोस्टेट आदि का आपरेशन होता है।



Branch of

BITANA & CHANDRAWATI HOSPITAL LLP

VIII - Naraunli P.O. Katrabahadurganj, Mallhipur Road, Bahraich

Previous Name

VERMA ULTRASOUND CENTER

Hospital Chowk, Bahraich

Dr. Ramesh Verma

M.B.B.S., M.D., Radiodiagnosis

K.G.M.C.(Lko.)

Reg.No. 039583

NAME :- DEEPIKA KANSAL AGE/SEX:- 40Y/F

REF. BY:- DR. S.K.SHUKLA (M.S.)

P ID:-

(U/S STUDY OF WHOLE ABDOMEN)

LIVER :- Liver is normal in size & echogenicity is increase . There is no focal lesion seen.

Intrahepatic portal radicles are not dilated . Portal vein is normal in size .

BILIARY SYSTEM :- Intra-hepatic bile ducts are not dilated .

C.B.D. is normal in size & lumen is echofree .

Gall bladder is normal in size. Lumen is echofree . Wall is 2mm in thickness. There is no abnormal collection or growth seen in G.B.fossa.

PANCREAS:- Pancreas is normal in size & echotexture . Pancreatic duct is not dilated .

There is no focal lesion seen in parenchyma .

AORTA & PARA AORTIC AREA :- Aorta & I.V.C. is normal in size .Para-aortic area is clear .

SPLEEN :-Spleen is normal in size & have normal echotexture . There is no focal lesion seen .

KIDNEY:- Both kidney are normal in size . Cortical echogenicity is normal.

Cortico-medullary differentiation is normal . Collecting system is not

dilated . There is 6mm calculus seen in lower middle calyx of LT kidney .

(RK104/43MM & LK98/36MM)

BOWEL LOOPS :- There is no abnormally dilated or thickened bowel loop seen .

URETER:- Upper part of both ureters are not dilated .

URINARY BLADDER:- It is partially filled (patient can not hold more than this) . Wall is smooth & regular . Lumen is echofree .

UTERUS :- Uterus is normal in size (89/45MM) .

Myometrium have normal echotexture .

Endometrium is normal in thickness & mid line.

OVARY & ADENEXA:- Both ovary are normal in size & echotexture . Both adenexal region are clear .

CUL-DE SAC:-Clear.

IMPRESSION:- GRADE I FATTY CHANGE IN LIVER

6MM LT RENAL CALCULUS

ADV:- Clinical correlation & further investigation

Thursday, November 03, 2022

RADIOLOGIST

(DR. RAMESH VERMA)
M.D. (R.D.)

Note :

(1) This report is not valid for medico-legal purpose. यह रिपोर्ट मेडिको-लीगल केस के लिए मान्य नहीं है।

(2) If the concern physician is not satisfied with this report, re-examination done free of cost or charges will be refund to the patient on recommendation of Doctor. अगर सम्बन्धित चिकित्सक इस रिपोर्ट से संतुष्ट नहीं है तो रोग का परीक्षण पुनः मुफ्त किया जाएगा, या चिकित्सक द्वारा सिखे जाने पर खर्च वापस की जायेगी।

सुषमा हास्पिटल

(A Unit of R.S. Mishra Medicare Pvt. Ltd.)

सुखदेव राज पेट्रोल पम्प के सामने, डिगिहा, गोण्डा रोड, बहराइच

डा० (श्रीमती) सुषमा मिश्रा

एम.बी.बी.एस., डी.बी.ओ.

एक्स पी.एम.एच.एस.

वरिष्ठ स्त्री एवं प्रसूति रोग विशेषज्ञ

डा० आर. एस. मिश्रा

एम.बी.बी.एस., डी.ए.

पूर्व सी.एम.ओ., इगोरपुर

वरिष्ठ एनेस्थेसिस्ट एवं फिजीशियन

संख्या :

श्रीमती.....

आयु.....

दिनांक.....

यजन

पल्स

रक्तचाप

जांच :-

120/83

9415061052
9415453764
Rx 1st 1/2yr w/Allopurinol
CP Ameliorin 1
Nifedipine 10mg
w/ 1st 1/2yr w/Allopurinol
1st 1/2yr w/Allopurinol

ATUTORY WARNING : The Diagnosis and Prognosis of disease and risks of investigations and treatment are beyond control. Under existing socioeconomic conditions and limited medical resources, professional advice can be rendered in facts and circumstances of the case. Once medicare has been started, means that there is implied consent. For better medicare it is always advised to visit other better medicare providers.

लने का समय -

1: 10:30 बजे से सायं 5:00 बजे तक

पर्चा सिर्फ 7 दिन तक ही मान्य है।

- इमरजेन्सी मरीज 24 घंटे देखे जाते हैं।

1 में बीड़ी, सिगरेट पीना तथा पान गुटका खाना नमा है।

1. जो भी शुल्क लिया जाता है वह चिकित्सा सेवा को सुचारु रूप से चलाने के लिये लिया जाता है किसी जरूरती के लिए नहीं।
2. दर्द में कमी न होने पर सूजन एवं बुखार होने पर तुरन्त सम्पर्क करें।
3. गर्भवती महिलाओं का पेट में बच्चा न चलने पर अथवा, रक्तस्राव होने पर तुरन्त सम्पर्क करें।

मेडिकल स्टोर : 7905928738

पैयालोजी एवं जन्म प्रमाण-पत्र : 7905770542

इमरजेन्सी : 8874450460

घात: 10 बजे से

सायं 7 बजे तक



R/o Sravasti

1st Visit

Dr. Neelam Vinay

MRCOG, FRCOG, (UK), FACOG (US)
Member British Fertility Society
Director - Medanta Institute of Obstetrics & Gynecology
Gynaecology & Fetal Medicine
neelam.vinay@medanta.org
Mobile : +919415313929, 9415413929
Regd. No. UPMC 85738

Dr. Ruby Yadav

MBBS, DNB
Associate Consultant
Regd. No. UPMC 81750

Dr. Aditi Agarwal

MBBS, MD, DNB
Fellowship in Foetal Medicine
(MFC, Bengaluru)
Associate Consultant
Regd. No. UPMC 87152

Dr. Monica Narayan

MBBS, DGO, DNB, FNAS
Associate Consultant
Regd. No. UPMC 75549

For Appointments - 0522-4505050

Patient Name: **Mrs. Deepika Kansal**
MMO1694787 Sex : F Age : 43Y
Location : Obs & Gynae
Practitioner : Dr Neelam Vinay

Date: 19/08/2022

W/o Anil Kumar

LMP: 12/8/22

G P L A

ET: Continued till 29/7/22
? 2-3/E

BP: 110/68 mmHg → 106/68.

EDD:

Weight: 77.5 kg

Qo Heavy menstrual bleeding
= sev. dysmenorrhoea x 1 1/2 years
Prolonged duration

Uterus (Taking T. Stenchi MD TDS)
Pain from Loin to Groin - Rt-sided
Medical/H - K/C/O HTn - 1 1/2 yrs.

Taking T. Amlodipine 5 +
Metoprolol 50

T. Clonazepam 0.5 mg
1/2 BD

Taking T. Dienogest 2mg for 5-6 mths

T. Atervastatin 20 mg

Surgical/H - NAD

Allergy - Not known

Contractive/H - Nothing

Family/H - Father - HTn
Mother - DM + HTn

Personal/H [Housewife
Husband service

Menstrual History
cycles - 30 days
Duration - 10 days
flow - heavy
Dysmenorrhoea - ++

● O/H - 1 1/2 yrs NVD.

Refd to Cardiologist
for T.B.P.

3/8/22

TUS

- Adenomyosis
- small subserous fibroid in R lateral uterine wall (20x15mm)

Ps-cervix-(N) P/U- uterus APV bulky Non tender

LBC J- Talem
HPV J-

14/7/22

USG(WA) Shrawasti
Rt Renal microlithiasis (32mm)
Bulky uterus
Excess bowel gas.

Both Medical

Surgical

options discussed

Pr declines surgical options

Pr is already taking
Diagnosis by us since Gyna

Ch. Dr. Vinay MD since
3/8/22 as

advised by Dr. in Behraik
advised to couple 21 day
of delay till 23/8/22

View as 2 1 1/3 periods
as sus 1

Today

- LBC
- HPV-DNA

- CBC
- TSH, T3, T4
- ~~FT3~~ ~~FT4~~
- Ser R12
- 25 OHVitD

G of A D J Sharma



समाधान हॉस्पिटल

जेल रोड, बहराइच - 271801

Ph : (05252) 235321, Mob : 9453299962, 9838394595

डा. बी.पी. सिंह

M.B.B.S., M.D. (SKIN & VD)

चर्म रोग, सौन्दर्य कुष्ठ व जुपा रोग विशेषज्ञ



डा. (श्रीमती) राजुल सिंह

M.B.B.S., M.S. (Obs & Gynae)

स्त्री रोग एवं प्रसूति रोग विशेषज्ञ
(निर्झपन विशेषज्ञ)

अल्ट्रासाउंड एवं IUI की सुविधा उपलब्ध

Name Miss Deepika Age 4y Sex F Date 3/8/2021

स्त्री रोग विभाग

- गर्भावस्था में जांच
- पथ्येयानी की रसौली व अन्य औपरोहन
- कृत्रिम गर्भापान (IUI)
- बौद्धिक का इलाज
- परिवार नियोजन
- सिनेरिपन जापरोहन
- गर्भगत व नसबन्दी रज्जोनिवृत्ति क्लीनिक
- कैन्सर की जांच
- गर्भाशय के मुख के पाच का सिक्काई द्वारा इलाज
- सुरक्षित गर्भापान

चर्म रोग व सौन्दर्य

- लेजर द्वारा अनचाहे बाल हटाना
- लफ्फन एवं टाटू हटाना
- झड़ते बालों का इलाज
- तिल एवं मसूस हटाना
- सेमिकल पीलिंग
- त्वचा की चमक एवं झुर्रियों का इलाज
- मौजो येरेपों
- त्वचा के निशान का इलाज
- स्ट्रेच मार्क्स (निचाव के निशान) का इलाज
- सफेद दाग का इलाज सर्जरी द्वारा

Case of Chronic Hypertension }
 BP = 120/80
 Pt. July 11 from Bhungs Hospital }
 From Dinagpur }
 Zinobulopas P x 50 }
 Denry Long x 25gs }
 Mogab }
 Can Swella 1 tab }
 by week x 1m }
 Wedy }
 Referred to cardiology 1st 11/8/21 }
 Referred to 11/8/21 }
 2/8 }
 TSK }
 ? Early Morning }
 Small cubes }

कृपया फोन पर सम्पर्क के द्वारा दवा न लिखावाये आवश्यकता पड़ने पर OPD में ही सम्पर्क करें।

पर्या केवल 6 दिनों के लिए मान्य

STATUTORY WARNING: The diagnosis and prognosis of disease and risks of investigation and treatment are beyond control. Under existing social, economic conditions and limited medical resources a professional advice can be rendered in facts and circumstances of the case. Once medicine has been started, it means that there is implied consent. For better medicine it is always advised to visit other better medicine providers and advanced medical centers.

डा. बी.पी. सिंह समय : प्रातः ~~10:00 AM to 12:00 PM~~ 12:00 PM to 4:00 PM
 डा. राजुल सिंह समय : प्रातः ~~10:00 AM to 12:00 PM~~ 12:00 PM to 4:00 PM
 निवेदन - हॉस्पिटल में ब्लड बैंक की सुविधा नहीं है, आवश्यकता पड़ने पर मरीज को स्वयं खून की व्यवस्था करनी पड़ेगी।
 रविवार पूर्ण अवकाश
 Medical Superintendent
 80 मरीजों के 4 कोर 2



Reg. No. : BRH/US/43

DR. AMIT DIAGNOSTIC CENTRE

Dr. Amit Mishra

MBBS, MD Radiodiagnosis
Formerly at Sherda Hospital & Medical College, G.Noida
Ex-Asst. Professor, Hind Institute of Medical Sciences, Lucknow

Dr. Garima Sharma

MBBS, DNB Radiodiagnosis
Formerly at Fortis Hospital, Noida
Ganga Hospital, Coimbatore

Patient Name :-Mrs. DEEPIKA

Date:- 03/08/2022

Age :- 40 yr

Gender:- Female

Referred by :- Dr. RAJUL SINGH M.B.B.S., M.S.(OBS & GYNAE)

TRANSVAGINAL ULTRASOUND PELVIS

UTERUS:

- It is anteverted and bulky in size measuring ~ 8.4 x 5.5 x 4.6 cm.
- Myometrium appears coarse heteroechoic - ? early adenomyosis changes.
- There is well defined small subserosal fibroid, measuring ~ 20.8 x 15.9 mm seen in right lateral wall.

Endometrium is central and echogenic, measuring approx 6.8 mm in thickness.

Cervix appears normal. *Pouch of Douglas: Clear.*

OVARIES AND ADNEXA:

Bilateral ovaries appear normal in size shape and morphology. No evidence of any cyst or mass seen in the ovaries.

Right ovary measures ~ 3.2 x 2.1 cm.

Left ovary measures ~ 3.1 x 1.9 cm.

IMPRESSION:

- Bulky uterus with ? early adenomyosis changes.
- Small subserosal uterine fibroid in right lateral uterine wall (~ 20 x 15 mm).


Dr. Garima Sharma

M.B.B.S., D.N.B.(Radiodiagnosis)

Suggest clinical correlation.

Note:- This report cannot be produced as an evidence for medico legal purpose.

+91 9369 78 7394

जिला अस्पताल के सामने

रविवार : प्रातः 8:00 बजे से अपराह्न 3:00 बजे तक

प्रातः 8:00 बजे से रात्रि 8:00 बजे तक

✉: dramitdiagnostics@gmail.com



Sanjay Gandhi Postgraduate Institute of Medical Sciences, Lucknow
Department of Gastroenterology

Patient OPD Record

Unit: ¹⁰⁶⁴ OPD - Tuesday/Friday
Dr. Praveen Rai
Dr. Pankaj Kumar

Diagnosis

For appointments:

4th Floor, Naveen OPD

Sanjay Gandhi Postgraduate Institute of
Medical Sciences, Lucknow-226014

Tel. : 0522-2496421/2496422

Name Deepika Kansal Age/Sex 44 CR No. 20 2338645

History & Examination

① Beckwith / Transcribed pair: large membrane
= large
with venous

② Abd bleeding

③

Investigations	Clinical Impression	Advice
	? Endometriosis / CA 20.	To send with reports, P Kansal 21/4/2022 , Tol. Neutro As 4mm , Tol. methyl spat. \leftarrow
		P Kansal 21/4/2022

Please take appointment from OPD Counter prior to coming

SANJAY GANDHI POSTGRADUATE INSTITUTE OF MEDICAL SCIENCES, LUCKNOW
DEPARTMENT OF RADIO DIAGNOSIS

CT REPORT

PATIENT'S NAME	DEEPIKA KANSAL	AGE /SEX	44Y/F
CR NO	2023338645	DATE	26/4/23

INVESTIGATION : TRIPLE PHASE CT ABDOMEN

CLINICAL DETAILS: ?SAIO; c/o endometriosis

STUDY SHOWS:

- Stomach, small bowel loops and large loops appear normal in course, caliber and enhancement pattern. Caecum and IC junction appear normal. *No obvious evidence of obstruction noted.*
- Liver is normal in size and outline. No obvious focal lesion seen. IHBR are not dilated.
- Hepatic artery, portal vein and splenoportal axis, hepatic veins and IVC are normal.
- Gall bladder is normal in outline. No obvious wall pathology or radio-opaque calculus seen. CBD is not dilated.
- Pancreas and spleen are normal.
- Both kidneys are normal in outline with normal cortical enhancement pattern. No obvious hydronephrosis/calculi/mass noted on either side.
- Bilateral adrenal glands are normal.
- No obvious abdominal / pelvic lymphadenopathy seen.
- Pelvic region reveal normal urinary bladder, and uterus. **Right adnexa show a ~35 x 34mm cystic lesion, with internal eccentric thick enhancement. Mild free fluid noted in Pouch of Douglas.**
- Abdominal aorta, bilateral iliac, CA, SMA and bilateral main renal arteries appear normal.
- *Visualized spine shows mild degenerative changes. Hemangioma noted at L2 vertebral body.*

IMPRESSION:

- Cystic lesion with internal eccentric thick enhancement in right adnexa – D/D – 1. Hemorrhagic cyst 2. Ovarian neoplasm – Adv: USG/CA-125 correlation.

DR KHALAF/DEVESH

प्रतिष्ठान अधिकारी
26/04/2024
Chief Medical Superintendent
Maharaja Subodh Dev Autonomous State Medical
College & Maharishi Balaraj
Hospital Bahujica



UHID: 20220347905

Dr Shyama prasad Mukherjee Civil Hospital
Park Road, Hazratganj, Lucknow (U.P)

CONSULTING ROOM NO : 43
CLINIC : CAUSALTY OPD- 2, TOKEN NO : 370

EHIR ID : 22000845076327470

CASUALTY

Name : Mrs. DEEPIKA KANSAL

Department : Emergency

ER.No : 2022/081/0081792

Date of Registration : 20-08-2022 09:04:42 PM

Unit : CASUALTY UNIT- 2

Age : 40Y

Billing Type : General

Mobile No : *****000

Email :

Address : judge compound , Shrawasti, UTTAR PRADESH, INDIA

Brought By : Self

Fee : 0.00

Sex : Female

W/O: shri anil kumar

Occupation : OTHER

Patient Type:NON MLC

Prepared by:Mr. Faizy Saleem

BP → 135/80 mmHg

ECG → NSR

PR = 84/min

2DE Echo → (prominent)

↓
NO RWMA LVEF = 65%

- Normal Cardiac chamber dimension

- Trace MR, Trace TR @ PASP

- @MIP

- NO I/C clot, Veg, P.E.

HTN ⊕ (Amlodipine 5 + metoprolol 50)

A.M.

[Handwritten signature]

Chief Medical Officer
20/2/2024
Superintendent
College & Mahatma
Hospital, Lucknow

[Handwritten signature]

1st visit

m KRISHNA MEDICAL CENTRE

(ISO 9001 : 2008 Certified)

1, Rana Pratap Marg, Lucknow, Phones : 2616064, 2628823

Dr Chandravati

DGO, MS, DFPA (Eng) FICS, FICMCH

Professor Emeritus &

Head of the Department (Retd.)

Department of Obstetrics & Gynaecology,

King George's Medical University, Lucknow

19/5/22

TSH - 2.04

29/7/22

S. Uric Acid - 6.23

CRP - 10.5

TSH - 3.56

TUS Adenomyoma

TUS Adenomyoma

z by Gavelawl

z Smartman 18m

z Koolcal Gold

z D Gcum

z Tryptomer

z HTM drugs to continue

Deepika

Age - 40y11f

Date: 19/08/2022

w/o Justice [HTM]

2 - 6
19/10/22 19/12/22

19/8/22

18m

38

for study
p 2 days. p 4mbs

Go to

Go to

long at 8pm

9628000815

मम चन्द्रवती

Chief Physician
20/24/2024 ent
Kanjivada Subin Das Alkondaya State Medical
College & Hospital, P. H. U.
Academy, Lucknow

- OBSTETRICS & GYNAECOLOGY
- ASSISTED REPRODUCTION (IVF)
- NEUROSURGERY
- GENERAL SURGERY
- PEDIATRICS
- ENT SURGERY
- PATHOLOGY
- ENDOSCOPIC SURGERY
- BCO MA X-RAY
- ULTRASOUND
- MAMMOGRAPHY
- BONE DENSITOMETRY

CONSULTATION :: MORNING : 11 AM TO 1:00 PM EVENING : 5:00 PM TO 8:00 PM - SUNDAY : 10:00 AM TO 1:00 PM
SATURDAY EMERGENCY ONLY