

कार्यालय संयुक्त निदेशक पर्यटन
64-ताज रोड, आगरा।

जिस किसी से सम्बन्धित।

पत्रांक 1107 /व्यय0पत्रा0/2024

दिनांक 12 . फरवरी, 2024

यह प्रमाणित किया जाता है कि श्रीमती दीप्ति वत्स पत्नी श्री सत्येन्द्र सिंह वर्मा, संयुक्त निदेशक पर्यटन कार्यालय, 64-ताज रोड, आगरा में क्षेत्रीय पर्यटक अधिकारी के पद पर कार्यरत हैं।



(अविनाश चन्द्र मिश्र)
संयुक्त निदेशक पर्यटन
आगरा एवं अलीगढ़ मण्डल
आगरा।

संयुक्त निदेशक पर्यटन
आगरा

Dr. Neha Chandra

Gynaecologist

MBBS, DNB (Obstetrics and Gynaecology)

| | | | | | |
|--------------|----------------------|-------------|---------------------------|-----------|-------------------------|
| Patient Name | : Mrs. Deepthi | Age / Sex | : Female/42 Yrs | UHID | : 81030 |
| Date | : 20/05/2023 12:46PM | Address | : GAUR GRACIOUS MORADABAD | Mobile no | : 9927857733 |
| Sponsor | : SELF PAY | Doctor Name | : Dr. Neha Chandra | DEPT. | : OBS AND GYNAECOLOGIST |

Drug Allergy :

HISTORY & CHIEF COMPLAINTS

BP : 130/70

Pulse :

Weight : 85kg

Height :

Investigation

Diet Advice

Type :

Calories :

Protein :

KIC of Hypothyroidism
 Pain on medication
 Since 12yrs
 Thyroidism - 602.15mcg
 Took ATT treatment for
 9 months (2022)

PIL
 Ref for infertility
 C.C - Rt side Breast pain with
 lumps on Bl Breast

ADVICE:

DNIE

Gc - for 8

Breasts - BL nodularity
 felt -

no lump palpable
 axilla free
 BL nipples (N)

Ades

- mammography breasts
 with WPE from
 lesion.

Chandra

- Tab Efem 100mg bid
 X 1 month

- Refer to Oncologist
 for biopsy of lesion

FOR APPOINTMENT
 Phone No.: 6396852013
 6396852220

Chandra



- Acute Cardiac Care
- Critical Care and Trauma
- Pathology
- Radiology
- Blood Bank
- Pharmacy
- Ambulance

USG BIL breasts
 प्रति हस्ताक्षरित
 4

मुख्य चिकित्सा अधिकारी
 आगरा

For Emergency Contact

639685 3330

This is an important document, please keep it safe and carry it in your hand.

सिद्ध अस्पताल में अर्थ घर हैं
 पिलोरी, खून व अन्नि जांचो
 की सुविधा। सम्पर्क करें।
 मो 0-6396852017

माचि दिनों के लिए मान्य
 Valid for Five days



Complete Accredited



International Society for Quality in Health Care

Haridwar Industrial Estate, Kanth Road, Moradabad
 +91 591 297 11 11, 297 22 22 +91 639685 2220
 info@siddhhospital.org / hr@siddhhospital.org www.siddhhospital.org

Scanned with OKEN Scanner

Scanned with OKEN Scanner

Scanned with OKEN Scanner

OPD

 **siddh**

MULTISPECIALITY HOSPITAL

Pt. Name: Mrs. Deepti

Age: 42 Years.

Sex: Female

UHID: 81030

Ref. By: Dr. Neha Chandra

Date: 20-05-2023

USG (BOTH BREAST)

RIGHT BREAST-

welldefined hypoechoic lesion of size 3.1x1.9cm at 6'o clock in right breast, lesion is wider than taller , with welldefined margins and no architectural distortion, mild internal vascularity seen with few internal echogenic foci ? Calcification. Rest Breast parenchyma have normal echotexture, no focal lesion seen.

Retromammary zone and retroareolar tissue visualized normally.

Visualized pectoralis muscle have normal echotexture.

LEFT BREAST-

Breast parenchyma have normal echotexture, no focal lesion seen.

Retromammary zone and retroareolar tissue visualized normally.

Visualized pectoralis muscle have normal echotexture.

BILATERAL AXILLA-

Visualized normally, no lymphadenopathy seen.

IMPRESSION:

- *welldefined hypoechoic lesion at 6'o clock in right breast, lesion shows mild internal vascularity with few internal echogenic foci ? Calcification-*
(BIRADS 4)

• *Adv: mammography correlation for calcification and HPE.*

Radiologist *Deepali*
DR. DEEPALI GOYAL
MBBS.MD

This report is an opinion and requires correlation with other investigations and clinical details of the patient and is not intended for any medicolegal purposes.

-----end of report-----



Complete NABH Accredited



Harthala Industrial Estate, Kanth Road, Moradabad

+91 591 297 11 11, 297 22 22 +91 639685 2220

info@siddhhospital.org / hr@siddhhospital.org @ www.siddhhospital.org

Scanned with OKEN Scanner

Scanned with OKEN Scanner

Scanned with OKEN Scanner



DR. S. S. DODA MD, FICRI
Founder, Director & Chief Radiologist



| | | | |
|-------------|------------------|-------------|---------------------|
| Name | Mrs. DEEPTI | Date | 05/Jun/2023 02:15PM |
| Age/Sex | 42 YRS/FEMALE | Reg No | 012306050174 |
| UID No | 1008806 | Reported On | 05/Jun/2023 05:03PM |
| Referred By | Dr. NEHA CHANDRA | | |

MAMMOGRAPHY

BILATERAL X-RAY MAMMOGRAPHY

CLINICAL PROFILE: Lump right breast.

STUDY PROTOCOL: Bilateral mammograms have been obtained using 2D a low radiation dose technique and compression using a 83 micron Full Field Digital (FFD) system, in the cranio-caudal and medio-lateral oblique projections. Film markers are in the lateral and axillary portions of the breasts.

FINDINGS:

Both the breasts display heterogeneous background parenchyma which may obscure small masses (category C).

RIGHT BREAST:

A well circumscribed iso to hyperdense lesion is seen in the middle 1/3rd. No architectural distortion is seen in the views taken.

Correlative ultrasound revealed a well circumscribed hypochoic lesion, parallel in orientation at 6 O' clock axis, measuring 30x15 mm. On color/power Doppler, mild vascularity was noted in and around it.

No grouped micro-calcification is present.

The skin, subcutaneous tissues and nipple are normal.

The visualized portion of the axilla shows a few nodes with intact fatty hila.

LEFT BREAST:

No mammographically demonstrable discrete mass lesion/ architectural distortion is seen in the views taken.

Correlative USG revealed display heterogeneous parenchymal echotexture without any obvious focal lesion..

No grouped micro-calcification is present.

The skin, subcutaneous tissues and nipple are normal.

The visualized portion of the axilla shows a few nodes with intact fatty hila.

IMPRESSION: PROBABLY BENIGN RIGHT BREAST LESION.

GUIDED FNAC HAS BEEN DONE FOR FURTHER EVALUATION.

BIRAD'S - III

PLEASE BRING THE FILMS ALONG WITH THE REPORT ON YOUR NEXT VISIT

BIRAD'S GRADING:

| | |
|------------|---|
| CATEGORY 0 | Incomplete. Needs additional imaging evaluation and / or prior films for comparison |
| CATEGORY 1 | Negative (Normal) |
| CATEGORY 2 | Benign |
| CATEGORY 3 | Probably benign (<2% risk of malignancy) Initial short - Internal follow-up suggested (6 monthly) |
| CATEGORY 4 | Suspicious Abnormality |
| 4 A | Finding needing intervention (low suspicious of malignancy) |
| 4 B | Close radiological & pathologic correlation (Intermediate suspicious of malignancy) |
| 4 C | Moderate concern for malignancy |
| CATEGORY 5 | Highly suggestive of malignancy > 95% |
| CATEGORY 6 | Known Biopsy - Proven malignancy. |

NOTE: Dense breast parenchyma may obscure an underlying lesion. A negative report does not entirely exclude the possibility of malignancy. 10-15% of cancers are not identified by mammography. False positive report may average 6-10%.

(Encl. 02 Films) /SA

प्रति हस्ताक्षरित

मुख्य चिकित्सा अधिकारी
रामरा

*** End Of Report ***

DR. SHALINI JAIN
DNB(Resi) RADIODIAGNOSIS
DMC Reg. No. 40493

Page 1 of 2

Disclaimer: 1. This report is a professional opinion and clinical co relation is essential for final diagnosis. This report is not valid for medico legal purposes. In case of any alarming / unexpected results or typographical error please contact immediately for necessary remedial action.
2. Any report without valid registration number, barcode or QR code shall be deemed invalid & not issued by Dr. Doda's Diagnostics & Healthcare. Dr. Doda's Diagnostics & Healthcare cannot be held responsible for invalid or forged reports.

Scanned with OKEN Scanner

Scanned with OKEN Scanner

Scanned with OKEN Scanner



DR. S. S. DODAS MD, FRCR
Director & Chief Radiologist



| | | | |
|-------------|-------------------|-----------------|---------------------|
| Name | Mrs. DEEPTI | Date | 05/Jun/2023 02:15PM |
| Age/Sex | 42 YRS/FEMALE | Collection Date | 05/Jun/2023 04:14PM |
| UID/Barcode | 1008806 /10953430 | Receive Date | 06/Jun/2023 12:32PM |
| Lab No | 012306050174 | Reported On | 06/Jun/2023 12:47PM |

CYTOLOGY

USG GUIDED - FNAC

NG/23/161

CLINICAL: Right Breast Lump.

ASPIRATE: Blood Mixed Material.

MICROSCOPY: USG guided FNAC done from right breast lump yielded blood diluted material. Smears prepared from the aspirated material are cellular & show binodal population of ductal epithelial cells and myoepithelial cells arranged in large & small cohesive clusters, aggregates, branching elongated pattern and spread singly. Few of these clusters are hyperplastic and show cribriform pattern at places. Also seen are numerous large sheets, clusters & dissociated apocrine cells having abundant granular pale cytoplasm with nuclei showing moderate anisonucleosis, nuclear overlapping, nuclear karyomegaly, inconspicuous nucleoli & focal metaplastic atypia. Few of these cells show binucleation & multinucleation with enlarged nuclei having bland nuclear chromatin and mildly irregular nuclear membrane. Background shows lipoproteineaceous material admixed with RBC's, scant inflammatory cells and bare nuclei. No necrosis / granuloma / multinucleated giant cells seen. No parasite seen.

IMPRESSION: FEATURES ARE SUGGESTIVE OF PROLIFERATIVE BREAST DISEASE WITH EXTENSIVE APOCRINE CHANGE & EPITHELIAL HYPERPLASIA WITH MILD ATYPIA- RIGHT BREAST. (IAC Yokohama System for Reporting Breast Cytopathology Category III- ATYPICAL)

Ananya
DR. ANANYA DODA, MD
FRCR, FRCR
ASSOCIATE DIRECTOR
UMC Reg No. 010405

DR. GUNPREET ANAND, MD
CONSULTANT
PATHOLOGIST
UMC Reg No. 51790

DR. SANJANA KUMARI, MD
CONSULTANT
MICROBIOLOGIST
DMC Reg. No. 8841

DR. VEENA DODA
MBBS, FRCR
LAB DIRECTOR
DMC Reg. No. 6387

प्रति हस्ताक्षरित

मुख्य चिकित्सा अधिकारी

Disclaimer: 1. This report is a professional opinion and clinical correlation is essential for final diagnosis. This report is not valid for medico-legal purposes. In case of any discrepancy / unexpected results or typographical error please contact immediately for necessary remedial action.
2. Any report without valid registration number, barcode or QR code shall be deemed invalid & not issued by Dr. Doda's Diagnostics & Healthcare.

Mrs. Deepthi 42yrs / F R/o Agra

13/6/23

Lump in (RL) breast X months

USG Breast - 3.1 x 1.9 cm at 6 o'clock in RL breast
20/5/23 well defined margins.

Mammography - BI RADS III, well circumscribed into
5/6/23 hyperdense lesion seen in middle 1/3 rd

O/E G. good / Power mild / hydratic fat

NOSE F FNAC - mild atypia

RL breast - Nodular feel
with circumscribed firm to hard
growth in smooth m.

RL axilla
no nodes

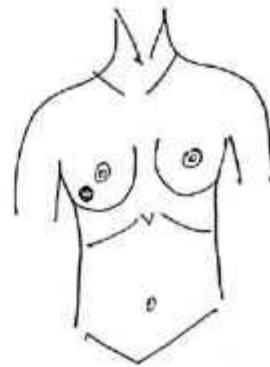
Slipping below jug LOQ.
Nipple axilla (w)

Lt breast - mild nodular
No lump felt
Nipple axilla (w)

Plt 50k / div Sph nor path

Adv -

- 1 USG guided Core biopsy.
- 2 PT / INR / CBC.



Prof Santanu Chaudhuri
MD (TMH), DNB, PGDHA,
MPHIL CPC CIO, CGPA
Chairman - Pushpanjali Cancer Care
Institute, Agra
Reg No. 71814

8630748266 HEALTH FOR ALL
People caring for people

FOR MORE INFORMATION CALL: 0954893956

Near Raja ki Mandi Station, Hariparwat, Dehli Gate, Agra

0562-7124000, 8954893956, 8954893972



24x7 Ambulance Facility



Pushpanjali

Hospital & Research Centre
NABH ACCREDITED - ENTRY LEVEL

प्रति हस्ताक्षरित

मुख्य चिकित्सा अधिकारी
अगरा

Scanned with OKEN Scanner

Scanned with OKEN Scanner

Scanned with OKEN Scanner

Pankaj Stanning

Dr. Shiv Mohindru

9105999976

Dr. Karan

8971471693

20/6/23

USA guided — S/O Fibroadenoma
biopsy

13/6/23


Actv

(Surgical on W?)
To review with Dr. Surendra Singh
for Surgery



Prof. Santanu Chaudhuri
MD (TMH), DNB, PGDHA,
MPHIL, CPC, CIO, CGPA
Chairman, Pushpanjali Cancer Care
Institute, Agra
Reg. No. 71814

प्रति हस्ताक्षरित


मुख्य चिकित्सा अधिकारी
अगरा

Scanned with OKEN Scanner

Scanned with OKEN Scanner

Scanned with OKEN Scanner



12/9/23

Nurse. Deepa NATE 4/4/23

Atypia to Hyperplasia

Ⓟ Breast
lesion

mammogram $\frac{1}{2}$ Breast
(moderate)

USG - Mammogram
(Boda)

FNA

$\frac{1}{2}$ BI RASTI



No significant
family history

Repeat Bx

① wide excision



Ravagi

ndi HEALTH FOR ALL
PEOPLE CARING FOR PEOPLE

FOR MORE INFORMATION CALL: 9258104989

Near Raja ki Mandi Station, Hariparwat, Delhi Gate, Agra
☎ 0562-4024000, 7505400400

प्रति हस्तान्तरित
24x7 Emergency Facility

24x7 Ambulance Facility



Pushpanjali
Hospital & Research Centre
NABH ACCREDITED - ENTRY LEVEL

- Scanned with OKEN Scanner
- Scanned with OKEN Scanner
- Scanned with OKEN Scanner

मुख्य चिकित्सा अधिकारी
अगरा

Wp do extension + QWAD

⊙ +

Ry

⊙ ECG

⊙ PAC review

⊙ CBC / WBC / WFT
* Thyroid profile
Loopulation profile
HNP / Hw / HbA1c

⊙

Admit at 8:00 AM

⊙ NPO after
midnight

⊙ T. Altra 0.5 mg #18

⊙ T. Pantop 40mg PR

प्रति हस्ताक्षरित

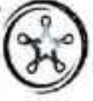4

मुख्य चिकित्सा अधिकारी
अमरा

⊙ Scanned with OKEN Scanner

⊙ Scanned with OKEN Scanner

⊙ Scanned with OKEN Scanner



DISCHARGE SUMMARY

| | |
|---------------------------------|-------------------------------|
| PATIENT NAME : DEEPTI VATSA | DATE OF ADMISSION : 21/6/2023 |
| AGE/SEX : 42/FEMALE | DATE OF DISCHARGE : 21/6/2023 |
| DOCTOR NAME : DR.SURENDRA SINGH | ROOM/BEDNO. : SUITE/III/301 |
| CATEGORY : HOSPITAL | IP ADDRESS : IP2304413 |

DIAGNOSES:

Right breast lesion (? Atypia with hyperplasia)

OPERATIVE PROCEDURE:

SURGERY: WIDE EXCISION OF LUMP RIGHT BREAST ↓+ LEVEL I OPBS
↓ GA

BRIEF SUMMARY:

Mrs. Deepti, 42 year old r/o Agra presented with complaints of lesion in right breast since last 6 months, for which patient evaluated with USG, mammography and Cytology, following which she presented for surgical management.

HOSPITAL COURSE:

Patient presented with above complaints in our hospital. She underwent surgery on 21 June. 2023. Post-operatively she was shifted to ward, started on liquid diet and gradually increased to soft diet. She was kept on antibiotics, pain medication and PPI. Now she is being discharged in stable condition.

OPERATIVE NOTES:

INCISION: 4-5 CM inframammary crease incision

- Superior skin flap raised in mastectomy plane beyond the growth.
- Wide excision of lump done taking adequate margins all around.
- Specimen marked with suture.
- Clips applied in lumpectomy cavity.
- Hemostatis achieved
- level I OPBS done.
- Incision closed in layers

प्रति हस्ताक्षरित


Dr.

मुख्य चिकित्सा अधिकारी
अगरा

HEALTH FOR ALL
PEOPLE CARING FOR PEOPLE

FOR MORE INFORMATION CALL: 9258104989

Near Raja ki Mandi Station, Hariparwat, Delhi Gate, Agra
☎ 0562-4024000, 7505400400



Pushpanjali
Hospital & Research Centre
NABH ACCREDITED - ENTRY LEVEL

Scanned with OKEN Scanner

Scanned with OKEN Scanner

Scanned with OKEN Scanner

INVESTIGATION:

USG (20.05.2023):

Welldefined hypoechoic lesion at 6'o clock in right breast, lesion shows mild internal vascularity with few internal echogenic foci? Calcification- (BIRADS 4).

CYTOLOGY (06.06.2023):

Features are suggestive of proliferative breast disease with extensive Apocrine change & epithelial hyperplasia with mild Atypia-Right Breast.

MAMMOGRAPHY (05.06.2023):

Probably benign right breast lesion. BIRAD'S- III

HISTOPATHOLOGY (13.06.2023):

Overall Features are suggestive of a Fibroadenoma.

CONDITION AT DISCHARGE

Patient taking soft diet orally and wound healthy, actively mobile, pain adequately controlled on oral medication and is being discharged in a stable condition.

ADVICE ON DISCHARGE:

| MEDICINE | DOSAGE | DAYS |
|--------------------|------------------|------|
| TAB. CEFTUM 500 MG | TWICE DAILY | 5 |
| TAB PANTOP 40 MG . | ONCE DAILY | 5 |
| SYP. A TO Z | TSF TWICE DAILY | 7 |
| SYP.LOOZ | 20ML AT BED TIME | |

प्रति हस्ताक्षरित


मुख्य चिकित्सा अधिकारी
अगरा

Scanned with OKEN Scanner

Scanned with OKEN Scanner

Scanned with OKEN Scanner



PUSHPANJALI
Cancer Care Institute

Dr. Surendra Singh

Surgical Oncologist
Pushpanjali Cancer Care Institute
MBBS, MS (General Surgery)
DrNB (Surgical Oncology)
Laposcopic / Robotic Oncosurgeons
Formerly at: Saldarjung Hospital, Delhi
Max Hospital, Saket, Delhi
Rajiv Gandhi Cancer Institute, Rohini, Delhi

GIVEN MEDICINE IN CASE OF PAIN

| MEDICINE | DOSAGE | DAYS |
|---------------------|-------------------------------|--------------|
| TAB. DOLO 650 MG | THREE TIMES DAILY | 3 (THEN SOS) |
| TAB. TRAMADOL 50 MG | SOS, IN CASE PAIN PERSISTS | |
| TAB. ULTRACET | SOS | |


FOLLOW UP ADVICE:

❖ BREAST SUPPORT AS ADVISED

To Review After 3 Days on Saturday (24/6/2023)
In case of emergency contact at 0562- 4024000, 7505400400

प्रति हस्ताक्षरित


मुख्य चिकित्सा अधिकारी
अग्ररा


Dr. Surendra Singh
(Surgical oncology)
Mob no. 8763134990

HEALTH FOR ALL
PEOPLE CARING FOR PEOPLE

FOR MORE INFORMATION CALL: 9258104989

Near Raja ki Mandi Station, Haripurwal, Delhi Gata, Agra
☎ 0562-4024000, 7505400400



Pushpanjali
Hospital & Research Centre
NABH ACCREDITED - ENTRY LEVEL

- Scanned with OKEN Scanner
- Scanned with OKEN Scanner
- Scanned with OKEN Scanner



PUSHPANJALI
Cancer Care Institute

Dr. Surendra Singh

Surgical Oncologist
Pushpanjali Cancer Care Institute
MBBS, MS (General Surgery)
DNB (Surgical Oncology)
Laposcopic / Robotic Onco Surgeon
Formerly at: Safdarjung Hospital, Delhi
Max Hospital Saket, Delhi
Rajiv Gandhi Cancer Institute, Rohini, Delhi

24.6.23

Mr. Deepthi Vats ; 42yof

Post of Case of Right Breast
lump.

Sex on 21/6/23.

O/E = wound healthy.

Op - weakness,
Pain & control.

Adv:

(1)

Continue
Breast support.

प्रति हस्ताक्षरित

[Signature]

मुख्य चिकित्सा अधिकारी
अगरा

HEALTH FOR ALL
PEOPLE CARING FOR PEOPLE

FOR MORE INFORMATION CALL: 9258104989

Near Raja ki Mandi Station, Haripurwat, Delhi Gate, Agra
☎ 0562-4024000, 7505400400



24x7 Ambulance Facility



Pushpanjali
Hospital & Research Centre
NABH ACCREDITED - ENTRY LEVEL

Scanned with OKEN Scanner

Scanned with OKEN Scanner

Scanned with OKEN Scanner

T. Fe daily
-0-0-
X 1 month

→ T. Ferric phosphate
-0-
X 1 month

① Cep A to 2.

② Pro-full protein powder

③ Review with biopsy report.

④ Avoid Travelling
Red. Rest X 1 week

प्रति हस्ताक्षरित



मुख्य चिकित्सा अधिकारी
अगरा



PUSHPANJALI
Cancer Care Institute

Dr. Surendra Singh

Surgical Oncologist
Pushpanjali Cancer Care Institute
MBBS, MS (General Surgery)
DrNB (Surgical Oncology)
Laparoscopic / Robotic OncoSurgeon
Formerly at: Saldarjung Hospital, Delhi
Max Hospital, Saket, Delhi
Rajiv Gandhi Cancer Institute, Rohini, Delhi

7.7.23

Mrs. Deepa Vats ; 42y of ♀

Pl/c of lump @ breast

no → pain & discomfort
@ Breast (U/L;

→ weakness & lethargy [R > L]

Biopsy :- Awaited.

O/E = mild swelling in lateral part of @ Breast c. 4 cm

प्रति हस्ताक्षरित

मुख्य चिकित्सा अधिकारी
अगरा

HEALTH FOR ALL
PEOPLE CARING FOR PEOPLE

FOR MORE INFORMATION CALL: 9258104989

Near Raja ki Mandi Station, Hariparwat, Dehli Gate, Agra
☎ 0562-4024000, 7505400400



24x7 Ambulance Facility



Pushpanjali
Hospital & Research Centre
NABH ACCREDITED - ENTRY LEVEL

Scanned with OKEN Scanner

Scanned with OKEN Scanner

Adv:

① T. Ultrasound of
+ 5 day

① T. Bil-N
of 5 day

① T. Chest X-ray
of 5 day

① Rest for 2 weeks
Review after
7 days with
biopsy report.

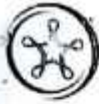① Collects sample

Send for
Review to
Dr. Singh

प्रति हस्ताक्षरित

4

मुख्य चिकित्सा अधिकारी
अगरा



24.7.23

Mrs. Deepa Vats ; 42y/9

H/P/E/O → Complex Fibroadenoma
Ⓡ Parast.

40 → weakness (muscle)
localised pain &
mild swelling
at operative site.

O/E =

No RD nodes / lymphome.
mild tenderness.
no obvious collection -
wound healthy.

प्रति हस्ताक्षरित

मुख्य चिकित्सा अधिकारी
एग्रा

R Ⓡ Cont. Breast
support of 1 inch

HEALTH FOR ALL
PEOPLE CARING FOR PEOPLE

FOR MORE INFORMATION CALL: 9258104989

Near Raja ki Mandi Station, Hariparwat, Delhi Gate, Agra
☎ 0562-4024000, 7505400400



24x7 Ambulance Facility



Pushpanjali
Hospital & Research Centre
NASH ACCREDITED - ENTRY LEVEL

① CBC after
7 week:

① T. Fe daily
of 2 x 100

② Cholecalciferol
1000 IU
once/week x 6 weeks

③ T. shellal soup
of 2 x 100

④ Rest for 3-4 weeks
till physically
active full
Avoid travelling



~~24/7/23~~

प्रति हस्ताक्षरित

मुख्य चिकित्सा अधिकारी
अंगरा



PUSHPANJALI
Cancer Care Institute

Dr. Surendra Singh

Surgical Oncologist
Pushpanjali Cancer Care Institute
MBBS, MS (General Surgery)
DrNB (Surgical Oncology)
Laparoscopic / Robotic Oncosurgeon
Formerly at: Safdarjung Hospital, Delhi
Max Hospital, Saket, Delhi
Rajiv Gandhi Cancer Institute, Rohini, Delhi

30/01/23.

Mrs. Deepika Nats, Physio

F/U/O → complex fibroadenoma Breast

O → Tingling & numbness at op. site.
O/E = wound healthy

Ry
○

Review after 1 month

○

Cica-care silicone gel sheet.
(LA) continuous application.

प्रति हस्ताक्षरित

[Signature]

मुख्य चिकित्सा अधिकारी
अगरा

HEALTH FOR ALL
PEOPLE CARING FOR PEOPLE

OR MORE INFORMATION CALL: 9258104989

near Raja ki Mandi Station, Harijanpura, Delhi Gate, Agra
0562-4024000, 7505400400



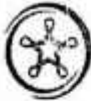24x7 Ambulance Facility



Pushpanjali
Hospital & Research Centre

Scanned with OKEN Scanner

Scanned with OKEN Scanner



PUSHPANJALI
Cancer Care Institute

Dr. Surendra Singh

Surgical Oncologist
Pushpanjali Cancer Care Institute
MBBS, MS (General Surgery)
DrNB (Surgical Oncology)
Laparoscopic / Robotic Onco Surgeon
Formerly at: Saldarjung Hospital, Delhi
Max Hospital, Saket, Delhi
Rajiv Gandhi Cancer Institute, Rohini, Delhi

14/10/23

Mrs - Sasha Vats ; 45y/o

operate base of complex fibroadenoma breast.

yo → small swelling / lump /
apparent to operate site

O/E = a small 1x1cm
lump in (R) breast
in LSR, skin &
chest wall, pa.
mobile.

प्रति हस्ताक्षरित

[Signature]

मुख्य चिकित्सा अधिकारी
अगारा

Review Hepat. -

Rp

○

Sonomanup Singh
B/L Breast

HEALTH FOR ALL
PEOPLE CARING FOR PEOPLE

FOR MORE INFORMATION CALL: 9258104989

Near Raja ki Mandi Station, Hariparvat, Delhi Gate, Agra

☎ 0562-4024000, 7505400400



Pushpanjali
Hospital & Research Centre

Scanned with OKEN Scanner

Scanned with OKEN Scanner



14.11.23.

Mrs. Deepthi Vats

F/U/d/o (R) Complex
Fibroadenoma

Now, do → small swelling
away from operative
site; painful

o/E = 1x1 cm
lump? cystic
at 5 o'clock
position of
breast; painful
exam.

प्रति हस्ताक्षरित

मुख्य चिकित्सा अधिकारी
अगरा

HEALTH FOR ALL
PEOPLE CARING FOR PEOPLE

FOR MORE INFORMATION CALL: 9258104989

Near Raja ki Mandi Station, Hariparwat, Delhi Gate, Agra
☎ 0562-4024000, 7505400400



24x7 Ambulance Facility



Pushpanjali

Hospital & Research Centre
NABH ACCREDITED - ENTRY LEVEL




27/1/24

Mrx. Deepika Vats; age 79

CO → generalized pain
R/L breast,
continuous in
nature.

O/E = obvious.
No lump / @
? small subcut. lump at breast
? Acyclical breast



R/L sonomammography

T. BOLD 600 mg 600 mg

Cap. EPO. x 2 unit
Breast support.

Counter Signature

Chief Medical Officer

Agre
26/04/24

HEALTH FOR ALL
PEOPLE CARING FOR PEOPLE

FOR MORE INFORMATION CALL: 9258104989

Near Raja ki Mandi Station, Hariparwat, Dehli Gate, Agra
☎ 0562-4024000, 7505400400



Pushpanjali
Hospital & Research Centre
NABH ACCREDITED - ENTRY LEVEL

① Reassurance.

② F/U after 1 month

f.

Dr. Surendra Singh
MBBS, MS, General Surgery
DrNB Surgical Oncology
Consultant Surgical Oncologist
Reg. No. 84809
Pushpanjali Cancer Care
Institute, Gurgaon



24/ Feb/24

Mrs. Deepa Vats ;
45y / f

C/O - persistent tender mass
R/L breast.

O/E = No significant abn

Rx

⊙

Continue previous
HT. X 1 with

⊙

Review after 1 month

Counter Signature

Chief Medical Officer

Agr
26/04/24

HEALTH FOR ALL
PEOPLE CARING FOR PEOPLE

Dr. Surendra Singh
MBBS, MS, General Surgery
DrNB Surgical Oncology
Consultant Surgical Oncologist
Reg. No. 84889
Pushpanjali Cancer Care
Institute

FOR MORE INFORMATION CALL: 9258104989

Near Raja ki Mandi Station, Haripurwat, Dehli Gate, Agra
☎ 0562-4024000, 7505400400



Pushpanjali
Hospital & Research Centre
NABH ACCREDITED - ENTRY LEVEL



13/4/24

MWA seen vats; 4m of
R/L of 40 - Post fibroadenoma &
40 - (L) Breast lump
∴ 1 mth.

O/E = (L) No obvious lump
palpable.
Normal breast changes

NAC was
No nodes palpable.
R/L Breast was

Counter Signature
Chief Medical Officer
Agra
26/04/24

R (L) Breast
sonography.
Cap Evion HP X 1st

Review
after 1 mth

HEALTH FOR ALL
PEOPLE CARING FOR PEOPLE

FOR MORE INFORMATION CALL: 9258104989

Near Raja ki Mandi Station, Hariparwat, Dehli Gate, Agra
0562-4024000, 7505400400



24X7 Ambulance Facility

Dr. Surendra Singh

MBBS, MS, General Surgery
DrNB Surgical Oncology
Consultant Surgical Oncologist
Pushpanjali
Hospital & Research Centre
NABH ACCREDITED - ENTRY LEVEL

2

संख्या-19/1-1976-कार्मिक-1

प्रेषक,

श्री पृथ्वी नाथ चतुर्वेदी,
आयुक्त एवं सचिव,
उत्तर प्रदेश शासन।

सेवा में,

- 1-समस्त विभागाध्यक्ष, उत्तर प्रदेश।
- 2-समस्त कार्यालयाध्यक्ष, उत्तर प्रदेश।

कार्मिक अनुभाग-1

लखनऊ, दिनांक 5 जनवरी, 1976

महोदय,

मुझे यह कहने का निदेश हुआ है कि राज्यपाल महोदय यह आदेश देते हैं कि यदि पति एवं पत्नी दोनों सरकारी सेवा में, कर्मचारी/अधिकारी हों तो उनकी नियुक्ति करते समय दोनों को एक ही स्थान पर रखने का यथासम्भव प्रयत्न किया जाय।

भवदीय,

पृथ्वी नाथ चतुर्वेदी,
आयुक्त एवं सचिव।

