

Dr. Sujay Shad

MBBS (AIIMS), MS (AIIMS)
FRCS Surg. FRCS CT Surg. (UK)
DMC : 31617

Senior Consultant Cardiac Surgeon
Director Cardiac Transplant
Professor & Co-Chairman Cardiac Surgery
Appointments +91 9911177891
Emergency +91 9811177891
sujayshad@gmail.com
www.drsojayshad.com



Dharma Vira Heart Centre
Sir Ganga Ram Hospital
New Delhi-110060

Post Operative / Pre Op. *of CAB x1*
other needs very small.

Date *20/12/2023*
Name *Smt Shanti Arya*
66/F

Pain Appetite

Constipation Sleep

Others *Doing well, allergies on & off.*

Pulse *72/min* B.P. *160/70*

Chest *Clear* Heart Sound *W*

Edema *0* JVP

Sternum Wound

Others

Hb Urea / Creat

TLC Na⁺/K⁺

PLTS FBS *130* HbA1C *10.0*

MCV Lipids *↑ TG*

Thyroid INR

Next Follow Up

Dr. Weeks

Dr. Shad *12* Months

Ad
- Tab Ecosprin AV 75/20 *OD*
- Tab Ezetimibe 10mg *OD*
- Tab Metolol XR 25mg *OD*
~~Tab Metolol XR 25mg *OD*~~
- Tab Isotalazine 2.5mg *BD*
- Tab Amlodipine 5mg *OD*
Needs better control of sugars
*Vogli 0.3mg *BD**

CBC, INR, RFT, LFT, FBS, HbA1C, Lipid Profile,
Thyroid Profile, B12, Folate, Homocysteine,
25-OHD, CXR, ECG, Echo

For Online Consult, Doctor ID 42
myFollowup
Available on the App Store | ANDROID APP ON Google play



Sir Ganga Ram Hospital

Rajinder Nagar, New Delhi-110 066

SHANTIARYA
69 Y/Female CAT-2
3055867 IP01224462
Admit On : 02/09/2022 12:42PM
CARDIAC SURGERY
1654/1654 - A - CAT2 SP
6E WARD

OPERATION NOTES - PICTORIAL

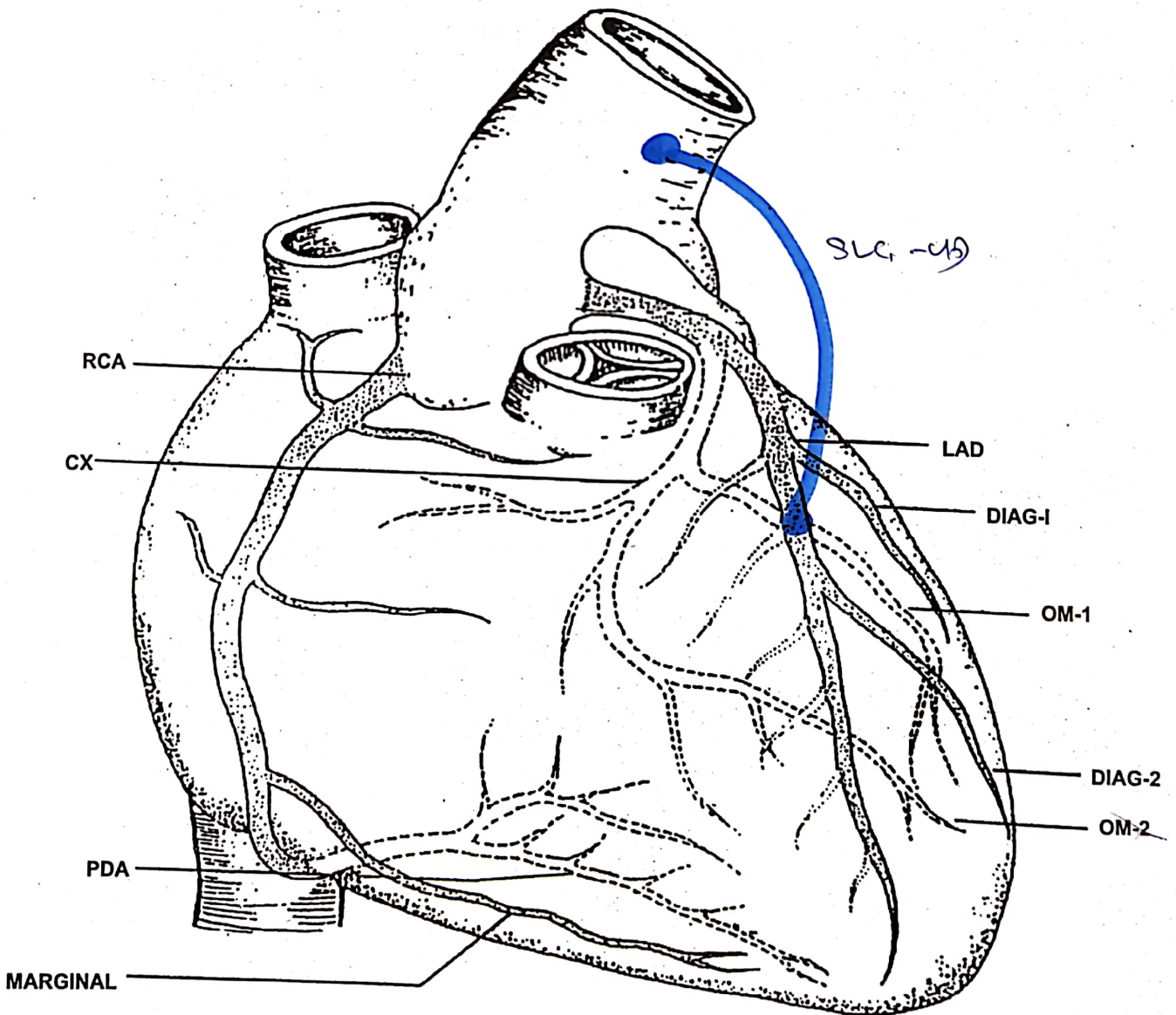
Name : Sudhi Ag

Age/Sex : 69 Y/F

C.R. No. : 3055867

Date : 3/9/22

Operation : OPUCX (SVC-CA)





**NARINDER MOHAN
HOSPITAL & HEART CENTRE**
(A UNIT OF NARINDER MOHAN FOUNDATION)
NABH & NABL ACCREDITED HOSPITAL

NMH/LH/21-22/1



ECHOCARDIOGRAPHY REPORT

Name: SHANTI ARYA
Age: 66 Years Sex: Female
Echo No. – 2859
Referring Diagnosis:
(Study done at bedside)

Date: 06.06.2022
Lab. No. 238139
UHID No.100614402
Ref. Physician: Dr. Anurag Singhal

M-MODE MEASUREMENT

		Normal values
Aorta diameter	: 31 mm	(21 – 35 mm)
Left Atrium end systolic (LA es) diameter	: 33 mm	(21 – 37 mm)
Left Ventricle end diastolic (LV ed) diameter	: 41 mm	(36 – 52 mm)
Left Ventricle end systolic (LV es) diameter	: 23 mm	(23 – 39 mm)
Interventricular septum end diastolic (IVS ed) thickness	: 09 mm	(06 – 10 mm)
Posterior wall end diastolic (PW ed) thickness	: 09 mm	(06 – 11 mm)
Right Ventricle end diastolic (RV ed) diameter	: -- mm	(15 – 30 mm)
Right Ventricle anterior wall thickness	: -- mm	(up to 05 mm)

MITRAL VALVE (MV)

Morphology	Anteromedial leaflet (AML)	Normal
	Posteromedial leaflet (PML)	Normal
Doppler	Mitral stenosis (MS)	Absent
	Mitral regurgitation (MR)	Absent

E wave : 0.7 m./sec.
A wave : 01.0 m./sec.

E/A Ratio : E < A

Mitral annulus Tissue Doppler (septal) :

Sa wave : 08 cm/sec.
Aa wave : 11 cm/sec.

Ea wave : 07 cm/sec
E/Ea Ratio : 10

TRICUSPID VALVE (TV)

Morphology	Normal	
Doppler	Tricuspid Stenosis (TS)	Absent
	Tricuspid Regurgitation (TR)	Absent

PULMONARY VALVE (PV)

Morphology	Normal	
Doppler	Pulmonary Stenosis (PS)	Absent
	Pulmonary Regurgitation (PR)	Absent
	Peak systolic gradient (PSG):	03 mmHg

AORTIC VALVE (AV)

Morphology	Tricuspid, mildly thickened	
Doppler	Aortic Stenosis (AS)	Absent
	Aortic Regurgitation (AR)	Present
	Peak systolic gradient (PSG):	05 mmHg
		Trivial

Page 01 of 02.



Mohan Nagar, Ghaziabad-201007 (U.P.)
Phones : +91-120-2657501 to 505, 2819000, +91-120-4130151 to 154
E-mail : info@nmh.net.in, nmhgz@gmail.com Website : www.nmh.net.in





NARINDER MOHAN HOSPITAL & HEART CENTRE

(A UNIT OF NARINDER MOHAN FOUNDATION)
NABH & NABL ACCREDITED HOSPITAL



Name: SHANTI ARYA
Age: 66 Years Sex: Female
Echo No. - 2859

Date: 06.06.2022
Lab. No. 238139
UHID No.100614402

LEFT VENTRICLE (LV) :

Normal size
Regional wall motion abnormality (LV RWMA) : Nil
Inter-ventricular septum (IVS) motion : Normal
Left Ventricle ejection fraction (LVEF) : $55 \pm 5 \%$
No LV mass / thrombus

LEFT ATRIUM (LA) :

Normal size, No LA mass / thrombus

RIGHT VENTRICLE (RV) :

Normal size, No RV mass / thrombus

RIGHT ATRIUM (RA) :

Normal size, No RA mass / thrombus

INTRACARDIAC SHUNT :

Absent

INFERIOR VENA CAVA (IVC) :

Normal size, shows normal inspiratory collapse

PULMONARY ARTERY :

Normal size

AORTA :

Normal size

PERICARDIUM :

Normal, no pericardial effusion / pathology

DIAGNOSIS / FINAL IMPRESSION :

ALL CARDIAC CHAMBERS ARE OF NORMAL SIZE.
NO LV RWMA, NORMAL LV SYSTOLIC FUNCTION, GLOBAL LVEF = 55 %.
GRADE - 1 LV DIASTOLIC DYSFUNCTION (RELAXATION ABNORMALITY).
NORMAL RV SYSTOLIC FUNCTION.
TRIVIAL AORTIC REGURGITATION (AR), NO AORTIC STENOSIS (AS)
NO MITRAL OR TRICUSPID REGURGITATION.
NO INTRACARDIAC MASS / THROMBUS / VEGETATION.
NO PERICARDIAL EFFUSION / PATHOLOGY

NO LV RWMA, NORMAL LV & RV SYSTOLIC FUNCTION, TRIVIAL AR.

DR. AMIT KUMAR, MD
Consultant, Non-invasive Cardiology

DR. ANURAG SINGHAL, DM
Sr. Consultant, Interventional Cardiology

NOTE: Echocardiography report given is that of the procedure done on that day and needs to be assessed in conjunction with the clinical findings. This is not for medicolegal purposes.





H-2008-0017
June 16, 2020 - June 15, 2023
Since June 16, 2008



Sir Ganga Ram Hospital

Patient Name (Last,First)	: ARYA SHANTI	Age/Sex	: 69 Yrs/F
Reg. No.	: 3055867	Ward No.	: 6E WARD
Episode No.	: IP01224462	Room No.	: 1654A/1654 - A - CAT2
Imaging No.	: 13637477-188	Executed On	: 02-Sep-22 05:42:50PM
Location	: CARDIAC SURGERY	Location Type	: IPD
Referred By	: DR. SUJAY SHAD	External Doctor	:

CAROTID DOPPLER

The innominate artery arises normally from the aortic arch and bifurcates into the right common carotid artery and subclavian artery. There was no evidence of any atherosclerotic plaque or an area of stenosis in the right common carotid artery. The bifurcation portion of the right common carotid artery was well visualised and found to be free of obstructive plaque or stenosis. The right internal carotid artery did not show evidence of any obstructive plaque or stenosis. However, intimal thickening was seen in the right carotid system. Colour Guided Doppler revealed normal laminar non turbulent flow across these arteries. The right vertebral artery showed normal flow pattern.

The left common carotid and the left internal carotid arteries were found to be free of obstructive plaque or stenosis. However, intimal thickening was seen in the left carotid system. Colour Guided Doppler revealed normal laminar non turbulent flow across these vessels. The left vertebral artery showed normal flow pattern.

IMPRESSION

BILATERAL INTIMAL THICKENING PRESENT. NO EVIDENCE OF ANY SIGNIFICANT PLAQUE.

Dr. Ashish Jain MD, DNB
Clinical Assistant (Cardiology)

Dr. Aman Makhija MD, DM
Sr. Consultant Cardiologist

[ApprovedBy]
[ValidateBy]

This is an Electronically Generated Report and Needs No Signature.
Any Alternations will make the Report Void.



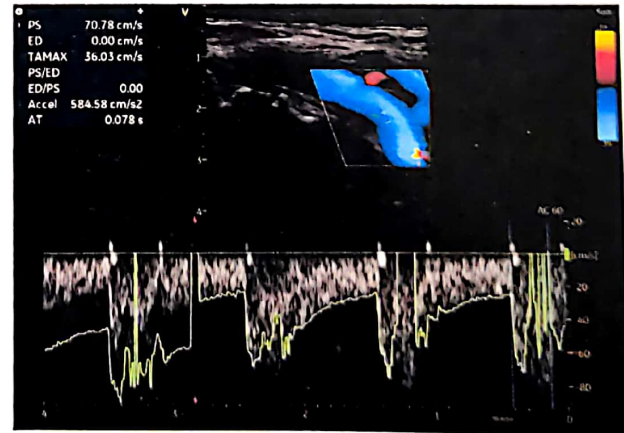
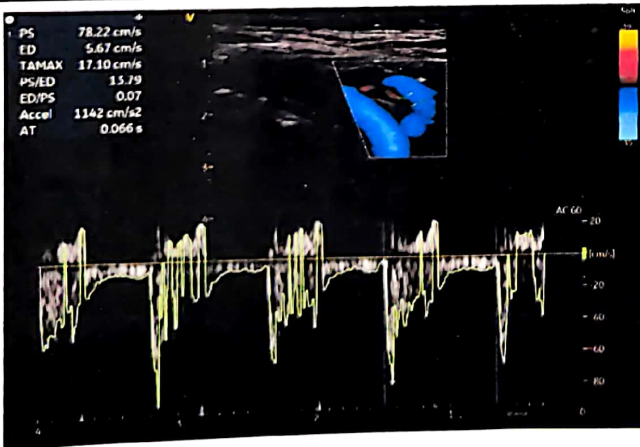
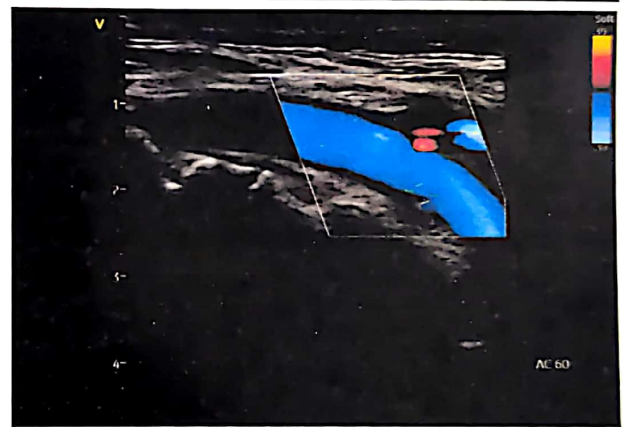
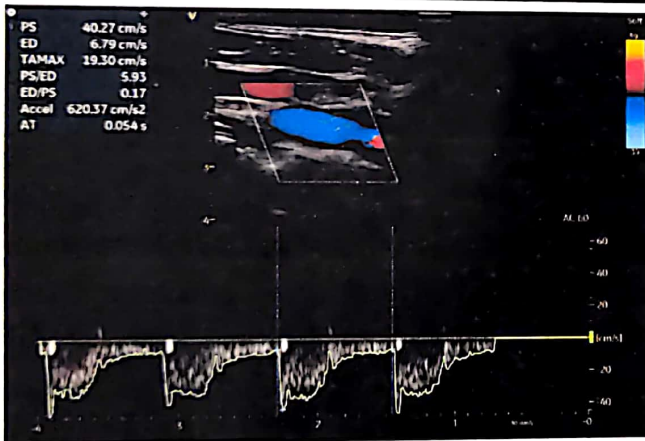

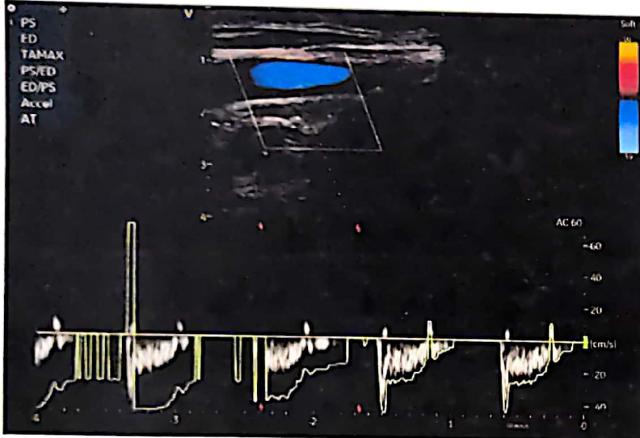
SIR GANGARAM HOSPITAL

RAJENDRA NAGAR

NEW DELHI - 60

Patient ID: SHANT73_96160
 Name: SHANTI ARYA

Date: 02-Sep-2022



Dr. Sujay Shad

MBBS (AIIMS), MS (AIIMS)
FRCS Surg. FRCS CT Surg. (UK)
DMC : 31617

Senior Consultant Cardiac Surgeon
Director Cardiac Transplant
Professor & Co-Chairman Cardiac Surgery
Appointments +91 9911177891
Emergency +91 9811177891
sujayshad@gmail.com
www.drsojayshad.com



Dharma Vira Heart Centre
Sir Ganga Ram Hospital
New Delhi-110060

Post Operative / Pre Op. OP CAB x1

Date 16/9/2022

Name Shri. Geeta Arya
69/P.

Weakness \uparrow
Pain \downarrow Appetite \downarrow
Constipation \circ Sleep \checkmark
Others High temperature last night
followed by eps. episodes of loose motions
associated with presyncope.
Pulse 72/min B.P. 94/54
Chest Clean Heart Sound S2 \checkmark
Edema Minimal JVP 0
Sternum \checkmark Wound \checkmark
Others

ECG - Global T Inversion
SR. 94/min QTc 540
PR. 122.
CXR - Clear

Urine R/M/S/C/S

Hb 12.47 Urea / Creat 32 / 0.84
TLC 12480 Na⁺/K⁺ 131 / 4.63
PLTS 286 FBS 179
MCV 85.4 Lipids

- Ady
- 1) Norflox T2 BD x 5 days.
 - 2) Tab Rosera Gold 10mg \times OD
 - 3) Tab Lasix 40mg $\frac{1}{2}$ OD
 - 4) ~~Tab Nitrosum 2.5mg BD~~
 - 5) Tab Paracetamol 500mg TDS
Reduce & stop as per pain.
 - 6) Tab Pan 40 OD
 - 7) Tab Metformin 500mg BD
 - 8) Tab Glimepide 2mg BD
 - 9) Tab Salza M 50mg/500mg OD
- Next

Thyroid INR
Next Follow Up
Dr. Weeks
Dr. Shad 6 Months

CBC, ~~ESR~~, RFT, LFT, FBS, HbA1C, Lipid Profile,
Thyroid Profile, B12, Folate, Homocysteine,
25-OHD₃, CXR, ECG, Echo

For Online Consult, Doctor ID 42

myFollowup

Available on the App Store

ANDROID APP ON Google play

Dr. Sujay Shad

MBBS (AIIMS), MS (AIIMS)
FRCS Surg. FRCS CT Surg. (UK)
DMC : 31617

Senior Consultant Cardiac Surgeon
Director Cardiac Transplant
Professor & Co-Chairman Cardiac Surgery
Appointments +91 9911177891
Emergency +91 9811177891
sujayshad@gmail.com
www.drsojayshad.com



Dharma Vira Heart Centre
Sir Ganga Ram Hospital
New Delhi-110060

Post Operative / Pre Op. *ECG x1.*

Date *7/10/2022.*

Other needs were very small.

Name *Smt. Sneha Arya.*

Pain *Resolving* ↓↓ Appetite ↓↓

Constipation Sleep

Others *Bad taste, No further temp*

*Came to SGRH 2 days ago.
ECG/ ANP profile negative
ECG. Extremities T ↓
Precordium under the painful
area has a minor pleural rub.*

Pulse *80/min* B.P. *120/70.*

Chest *Clear* Heart Sound *(A)*
Bounding under Aortic MCL.

Edema *mod* JVP *0*

Sternum Wound *leg wounds need debridement.*

Others

- 1) Tab Rosuva Cold 10mg OD
- 2) Tab Lactox 40 1/2 OD.
- 3) Tab Pan 40mg ~~2~~ OD.
- 4) Tab Nitrogran 2.5mg ~~BD~~
- 5) Tab Metolax XL 2.5mg OD

Hb Urea / Creat

TLC Na⁺/K⁺

PLTS FBS

MCV Lipids

Thyroid INR

Next Follow Up

Dr. Weeks

Dr. Shad *6.* Months

*+ anti drabctice
+ leg wound. debridement -
↓
Megahcal gel BD.*

Chakr

CBC, ~~Hb~~, RFT, LFT, FBS, HbA1C, Lipid Profile,
Thyroid Profile, B12, Folate, Homocysteine,
25-OHD, ~~CXR~~, ECG, Echoc

For Online Consult, Doctor ID 42

myFollowup

Available on the App Store

ANDROID APP ON Google play

Dr. Sujay Shad

MBBS (AIIMS), MS (AIIMS)
FRCS Surg. FRCS CT Surg. (UK)
DMC : 31617

Senior Consultant Cardiac Surgeon
Director Cardiac Transplant
Professor & Co-Chairman Cardiac Surgery
Appointments +91 9911177891
Emergency +91 9811177891
sujayshad@gmail.com
www.drsojayshad.com



Dharma Vira Heart Centre
Sir Ganga Ram Hospital
New Delhi-110060

Post Operative / Pre Op. *of CABG 1*
Other vessels were very small.

Date *24/12/2022*

Name *Smt. Shanti Arya*

Pain Appetite

Constipation Sleep

Others *No major issues*

Pulse *76/min* B.P. *120/80*

Chest *Clear* Heart Sound *@*

Edema JVP

Sternum Wound

Others

2.
- Tab Ecosprin Gold 20mg OD x 1
- Tab Nitrogran 2.5mg BD x 1
- Tab Metolol XL 25mg OD x 1
- Tab Ban 40mg SOS

[Signature]

Hb Urea / Creat

TLC Na⁺/K⁺

PLTS FBS

MCV Lipids

Thyroid INR

Next Follow Up

Dr. Weeks

Dr. Shad Months

Dr. Himanshu Koch
9911037668

CBC, INR, RFT, LFT, FBS, HbA1C, Lipid Profile,
Thyroid Profile, B12, Folate, Homocysteine,
25-OHD₃, CXR, ECG, Echo

For Online Consult, Doctor ID 42

myFollowup

Available on the App Store

ANDROID APP ON Google play

Dr. Sujay Shad

MBBS (AIIMS), MS (AIIMS)
FRCS Surg. FRCS CT Surg. (UK)
DMC : 31617

Senior Consultant Cardiac Surgeon
Director Cardiac Transplant
Professor & Co-Chairman Cardiac Surgery
Appointments +91 9911177891
Emergency +91 9811177891
sujayshad@gmail.com
www.drsojayshad.com



Dharma Vira Heart Centre
Sir Ganga Ram Hospital
New Delhi-110060

Post Operative / Pre Op. *of CAB x1*

other needs very small.

Date *20/12/2023*

Name *Smt Shanti Arya*

GG/R.

Pain Appetite

Constipation Sleep

Others *Doing well, allergies on & off.*

Pulse *72/min* B.P. *160/70*

Chest *Clear* Heart Sound *W.*

Edema JVP

Sternum Wound

Others

Hb Urea / Creat

TLC Na⁺/K⁺

PLTS FBS *130. HbA1c 10.0*

MCV Lipids *✓ ↑ TG*

Thyroid INR

Next Follow Up

Dr. Weeks

Dr. Shad *12.* Months

Medications:

- Tab Ecosprin AV 75/20 *OD*
- Tab Ezetimibe 10mg *OD*
- Tab Metolol XR 25mg *OD*
- ~~Tab Metolol XR 25mg~~
- Tab Isotalazine 2.5mg *BD*
- Tab Amlodipine 5mg *OD*

*Needs better control of sugars
Vogli 0.3mg *BD**

CBC, INR, RFT, LFT, FBS, HbA1C, Lipid Profile,
Thyroid Profile, B12, Folate, Homocysteine,
25-OHD, CXR, ECG, Echo

For Online Consult, Doctor ID 42

myFollowup

Available on the App Store

ANDROID APP ON Google play

Dr. Narendra Singh

M.D. (Medicine)
KGMU, Lucknow
Ex. SENIOR PHYSICIAN
AIIMS, NEW DELHI



(P)

डॉ० नरेंद्र सिंह

एम.डी. (मेडिसिन) के.जी.एम.यू. (लखनऊ)
भूतपूर्व सीनियर रेजिडेंट फिजिशियन
अखिल भारतीय आयुर्विज्ञान संस्थान
(एम्स) नई दिल्ली

हृदय, दमा, टी.बी., डायबिटीज, सिर दर्द, कमर दर्द एवं पेट रोग
Regd. No. : UPMCI -60760

Work At :

- Ex. Senior Physician at AIIMS, New Delhi
- Ex. Senior Physician at AAAH, New Delhi
- Ex. Senior Physician at TSM, MC, Lucknow
- Ex. Resident Doctor at KGMU, LKO
- Act as Senior Physician at Shri Amarnath Ji Yatra 2018

Consultation by Prior Appointment at Residence :

SD-377, डी-ब्लॉक, निकट कार्टे चौक, शास्त्री नगर, गाजियाबाद
M. : 9871560211
Morning : 7 to 9 am
Evening : 3 to 5 pm

Consultation by Prior Appointment

F-125, निकट त्यागी हॉस्टल, आकाश नगर, गाजियाबाद
M. : 9871560211
Morning : 9 am to 10 am

10.30 am to 2.00 pm & 06:00 pm to 08:00 pm at J-71, पटेल नगर-I, पुराना बस स्टैंड, (GDA के सामने, डॉक्टरों वाली लाईन में) गाजियाबाद (रविवार सायं अवकाश)

INVESTIGATION

CBC / KFT / LFT / RBS / HbA_{1c}
S.TSH / FT₃ / FT₄ / FLP / FIP / GBP / S.uric Acid / ESR / CRP
S.VitD₃ / S.Vit b₁₂ / S.folate
RA factor / PT / INR
IgM typhoid / Widal / MP Antigen
IgM Dengue / NS, For Dengue
Urine-R/M / C/S / Stool - R/M
Stool for Occult blood / HIV / HCV / HBV / HAV / HEV
ANA profile / Anti-dsDNA / AMA / ASMA / ALKM, Ab.
Chest X-ray PA / USG Whole Abd.

For **7303556342**
9871560211
appointment : **9891680947**

This Prescription is not a valid Medico-Legal Document (As patient Identity is not Verified)
Prescription Valid For 3 Days Only (Valid For Medical Treatment only)

- नोट : 1. किसी भी दवा से रिएक्सन/बिपरित असर होने पर दवा बन्द कर डॉ० से मिलें।
2. आपातकालीन स्थिति में निकटवर्ती अस्पताल / सर्वोदया अस्पताल केने-7, कविनगर, गाजियाबाद में सम्पर्क करें।
3. कृपया मोबाइल / व्हाट्स ऐप पर इलाज नहीं लें।
4. बिना नियमित परामर्श के दवा लेते नहना या बन्द कर देना नुकसानदायक हो सकता है।
5. दवा खरीदने के बाद अपने डॉक्टर से चेक करा लें।
6. गर्भवती महिलायें अपनी गर्भ की स्थिति को डॉक्टर को बतायें और दी गयी दवाईयों अपने प्रसूतिरोग विशेषज्ञ की अनुमति के बाद खायें।
7. अपेक्षित चिकित्सा लाभ नहीं होने पर दूसरे चिकित्सक से परामर्श लें।



Shri Krishna Eye Institute



Eye care... We care

(ISO 9001 : 2015 Certified Eye Hospital)

Dr Sulabh Goel

M.B.B.S., M.S., FAEH

Chief Surgeon & Head

Reg. No.DMC - 948, UKMC- 3985

Reg. No. A-11996
Date- 8/7/22

Dr Sumi Gupta (Goel)

M.B.B.S., M.S., DNB, FAEH, FVRS

Retina & Uvea Consultant

DMC- 01851, UKMC- 3986

Formerly at: Safdarjang Hospital, New Delhi, Aravind Eye Care System, Madurai
Vasan Eye Hospital, Madurai, Gomabai Netralaya, Nimach, Bhumanand Hospital Haridwar, Metro Hospital Haridwar

Facilities Available :

Name.. Mrs. Shanti Arya Age/Sex..... 66 / F

Complete Eye Check up

सम्पूर्ण नेत्र जाँच सुविधा

Dist/cont

ca 7.5 x 10 @ 12mths

Phacoemulsification cataract surgery with foldable lenses-Toric, Multifocal lenses

मोतियाबिन्द का फेको तकनीक से ऑपरेशन एवं मुझे वाला अत्याधुनिक लेंस

Quicky Injection

Va 7 8/200
Pach
(Ym)

Ⓟ Inta fold
colob

Retina and Vitreous Services

(OCT, DORC Vitrectomy, Green Laser, B-Scan)

आँख के पर्दे की बीमारियों की जाँच, लेजर एवं ऑपरेशन

1. 10
2. 12

Ⓟ Laser

Ⓟ I MSc

Glaucoma Services

काला मोतियों की जाँच एवं ऑपरेशन

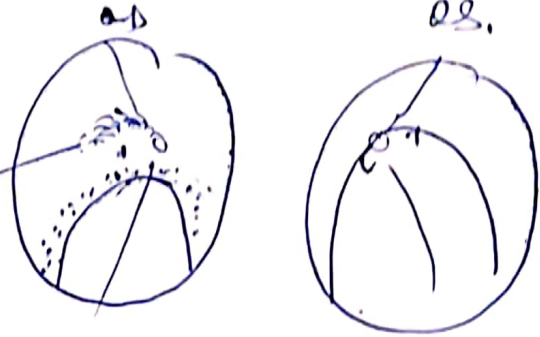
Squint and Pediatric Ophthalmology

भेगापन एवं बाल नेत्र रोगों की विशेष जाँच सुविधा एवं ऑपरेशन

Oculoplasty Services & DCR

आँख की पलक की बीमारियों एवं नासुर जाँच सुविधा एवं ऑपरेशन

Minor
BYO



ROP (Retinopathy of Prematurity) &

Diabetic Retinopathy- screening and Treatment

Contact Lens Fitting and Glasses

कॉन्टैक्ट लेंस फिटिंग एवं चश्मे की जाँच सुविधा

Mon-Sat (9.00 am to 1 pm)

(5.00 pm to 8 pm)

Sun (9.00 am to 1.00 pm)

OCT (R)

IPVB - nocare

Ⓟ 1) Ud Hevaro 1.5

Ⓟ 2) epd SOHA BD 0-0

सोम-शनि (प्रातः 9.00 बजे से 1.00 बजे तक)

सोम-शनि (सायं 5.00 बजे से रात्री 8.00 बजे तक)

रविवार (प्रात 9.00 बजे से दोपहर 1.00 बजे तक)

a/A 1mth/508 Amies chart.

Main Centre :- N-71, Shivalik, Nagar, Haridwar 01334-232361, 8006498211 | www.skei.co.in | Email: info@skei.co.in

Roshanabad Centre:- Near Gali No.2, Navoday Chowk, Roshnabad, Haridwar (9193426257)

Laksar Centre:- at Agarwal Medical Centre (Pappu Nursing Home), Haridwar Road, Laksar Ph. : 8191900800

NOT VALID FOR MEDICO LEGAL PURPOSE

CONSULTATION FEES VALID TWICE IN 5 DAYS (AFTER SURGERY FOR 1 MONTH)

परामर्श शुल्क 5 दिन में 2 बार मान्य (ऑपरेशन के बाद 1 माह तक मान्य)



SU:netra

THE SUPER SPECIALITY EYE CARE CENTRE



सु:नेत्र

सुपर स्पेशलिटी नेत्र केंद्र

ON PANEL OF CGHS/ ECHS/ DGEHS/ TPA

NABH & ISO : 9001-2008 Certified Centre

OUR TEAM OF DOCTORS

Dr. Nitin Dua

MBBS, MS, DNB, FRCS (U.K.)
Ex. Fellow: L.V. Prasad Eye Institute (Hyd.)
(Gold Medalist)
Super Specialist: FEMTO LASIK,
Phaco (Cataract), Cornea & Eye Transplantation.
Eye Consultant: Center For Sight, New Delhi
Shroff Eye Hospital, New Delhi
Regn. No.: MCI-4105
Tue, Wed, Thu, Fri, Sat, Sun **By Appointment Only**

Dr. Supreet Juneja

MBBS, MS,
Fellowship in Vitreo Retina
(Arvind Eye Care System, Madurai)
FVRS (Fellowship in Vitreo Retina)
Regn. No.: DMC-38609
Mon, Tue, Wed, Thu, Fri, Sat **By Appointment Only**

Dr. Chirag Mittal

MBBS, DNB
Specialist in Cataract & Cornea
Regn. No.: DMC-38609
Tue, Wed, Thu, Fri, Sat **By Appointment Only**

Dr. Harsimran Kaur Bhatia

MBBS, DNB (Ophthalmology)
Senior Consultant
Fellow Sankara Nethralaya (Chennai)
Regn. No.: DMC-42189
Mon, Tue, Thu, Fri, Sat, Sun **By Appointment Only**

Dr. Pradeep

MBBS, MS, FICO Glaucoma (U.K.)
Fellowship in Glaucoma (Arvind Eye Hospital,
Madurai)
Regn. No.: DMC-R-8042
Sun **By Appointment Only**

Dr. Sweety Tiple

MBBS, DO, FLPEI (Hyd.)
FICO (Switzerland)
Consultant Ophthalmologist
& Oculoplasty, Specialist
Regn. No.: DMC-51197
Mon, Tue, Wed, Fri, Sat **By Appointment Only**

Dr. Abhishek Agarwal

MBBS, MS, FAEH, FICO (London)
Fellowship, Cataract (Arvind Eye Hospital,
Madurai)
Regn. No.: DMC-55948
Mon, Tue, Wed, Thu, Sat, Sun **By Appointment Only**

Dr. Udbhav Dorwal

MBBS, DNB
Specialist in Cataract & Lasik
Regn. No.: DMC-42486
Wed, Fri, Sat **By Appointment Only**

Dr. Manish Sharma

MBBS, MS
Specialist in Pediatric Ophthalmology & Squint
Regn. No.: DMC-4582
By Appointment Only

Dr. Pratibha Gupta

MBBS, DNB, FRM (Bangalore)
Consultant, Ophthalmologist
Regn. No.: MCI-13744
Mon, Tue, Wed, Sat, Sun, **By Appointment Only**

Regn. No: RMEE 1905120

All Consultations by Appointment Only

UHID	146920	VISIT DATE	04-JUN-2022
PATIENT NAME	MRS. SHANTI ARYA	AGE / SEX	65 YRS / F
PATIENT ADDRESS	G 36 PATEL NAGAR IIIRD	CONTACT NO.	9891660225
CATEGORY	RETINA FREE		

PRESENT COMPLAINTS

PT COME FOR OCT, FPH. Retina Check Up.

PAST EYE HISTORY

Covid History- Nil, Drug Allergy -nil, No Current Rx, Using Glasses

SYSTEMIC DISEASE HISTORY

H/o Diabetes Since May, 2002. Comment :ON RX.
H/o CAD Since March, 2022. Comment :ON RX.
H/o Hypertension Since March, 2022. Comment :NO RX.

Adv. Glasses	Right Eye						Left Eye					
	Sph	Cyl	Axis	Prism	V/A	N/V	Sph	Cyl	Axis	Prism	V/A	N/V
Distance	+03.00				6/18P		No Acc				2/60	
Add	+03.00				N12		+03.00					

USE OF GLASSES : OP99 ,NEED DILATED FUNDUS EXAM

DIAGNOSIS

Pseudophakia in Right Eye
Cataract in Left Eye
Iris Coloboma in Both Eyes
Pathological Myopia With Amblyopia LE>RE
Npdr in Both Eyes
Diagnosis Comments/Clinical Impression :
?RE MACULAR EDEMA WITH BRVO

PLAN OF CARE:

STRICT GLYCEMIC CONTROL

Rx

1. MICRONAC PF EYE DROP [NEPAFENAC]
One Drop three times in a day for 30 Days in BOTH EYES
2. LUBREX DS EYE DROP [CMC 1%]
One Drop four times in a day for 90 Days in BOTH EYES

DOCTOR'S ADVICE:

BE OCT MACULA
BE FUNDUS PHOTO.
RE INTRAVIT RAZUMAB / ACCENTRIX UNDER GVP
NEEDS MULTIPLE INJ AT REGULAR INTERVALS
INJ RX IS FOR STABILIZATION OF VSIION.

NEXT REVIEW : BY APPOINTMENT ONLY



A Unit of SUNETRA EYE CENTRE PVT. LTD.

CIN No.: 48510DL 2012 PTC 241040

KC-120, KAVI NAGAR, GHAZIABAD PH. : 0120 - 4533333, 9891082009, 9892348770

Web.: www.sunetra.co.in, E-mail: sunetraeyecare@gmail.com





ON PANEL OF CGHS/ ECHS/ DGEHS/ TPA

NABH & ISO : 9001-2008 Certified Centre

OUR TEAM OF DOCTORS

Regn. No: RMEE 1905120

All Consultations by Appointment Only

Dr. Nitin Dua

MBBS, MS, DNB, FRCS (U.K.)
Ex. Fellow: L.V. Prasad Eye Institute (Hyd.) (Gold Medalist)
Super Specialist: FEMTO LASIK, Phaco (Cataract), Cornea & Eye Transplantation.
Eye Consultant: Center For Sight, New Delhi Shroff Eye Hospital, New Delhi
Regn. No.: MCI-4105
Tue,Wed,Thu,Fri,Sat,Sun **By Appointment Only**

Dr. Supreet Juneja

MBBS, MS,
Fellowship in Vitreo Retina (Arvind Eye Care System, Madurai)
FVRS (Fellowship in Vitreo Retina)
Regn. No.: DMC-38609
Mon,Tue,Wed,Thu,Fri,Sat **By Appointment Only**

Dr. Chirag Mittal

MBBS, DNB
Specialist in Cataract & Cornea
Regn. No.: DMC-38609
Tue,Wed,Thu,Fri,Sat **By Appointment Only**

Dr. Harsimran Kaur Bhatia

MBBS, DNB (Ophthalmology)
Senior Consultant
Fellow Sankara Nethralaya (Chennai)
Regn. No.: DMC-42189
Mon,Tue,Thu,Fri,Sat,Sun **By Appointment Only**

Dr. Pradeep

MBBS, MS, FICO Glaucoma (U.K.)
Fellowship in Glaucoma (Arvind Eye Hospital, Madurai)
Regn. No.: DMC-R-8042
Sun **By Appointment Only**

Dr. Sweety Tiple

MBBS, DO, FLPEI (Hyd.)
FICO (Switzerland)
Consultant Ophthalmologist & Oculoplasty, Specialist
Regn. No.: DMC-51197
Mon,Tue,Wed,Fri,Sat **By Appointment Only**

Dr. Abhishek Agarwal

MBBS, MS, FAEH, FICO (London)
Fellowship, Cataract (Arvind Eye Hospital, Madurai)
Regn. No.: DMC-55948
Mon,Tue,Wed,Thu,Sat,Sun **By Appointment Only**

Dr. Udbhav Dorwal

MBBS, DNB
Specialist in Cataract & Lasik
Regn. No.: DMC-42486
Wed,Fri,Sat **By Appointment Only**

Dr. Manish Sharma

MBBS, MS
Specialist in Pediatric Ophthalmology & Squint
Regn. No.: DMC-4582
By Appointment Only

Dr. Pratibha Gupta

MBBS, DNB, FRM (Bangalore)
Consultant, Ophthalmologist
Regn. No.: MCI-13744
Mon,Tue,Wed,Sat,Sun, **By Appointment Only**

2900
1500
4400

UHID	146920	VISIT DATE	31-MAY-2022
PATIENT NAME	MRS. SHANTI ARYA	AGE / SEX	65 YRS / F
PATIENT ADDRESS	G 36 PATEL NAGAR IIIRD	CONTACT NO.	9891660225
CATEGORY	NEW		

PRESENT COMPLAINTS

Dimness Of Vision Since 2 Months in right eye. Dimness Of Vision.

PAST EYE HISTORY

Covid History- Nil,Drug Allergy -nil,No Current Rx,Using Glasses

SYSTEMIC DISEASE HISTORY

H/o Diabetes Since May, 2002. Comment :ON RX.

H/o CAD Since March, 2022. Comment :ON RX.

H/o Hypertension Since March, 2022. Comment :NO RX.

Method Name	IOP Time	Right Eye	Left Eye
NCT	12:56	18	18

Adv.Glasses	Right Eye						Left Eye					
	Sph	Cyl	Axis	Prism	V/A	N/V	Sph	Cyl	Axis	Prism	V/A	N/V
Distance	+03.00				6/18P		No Acc					2/60
Adia	+03.00				N12		+03.00					

USE OF GLASSES : ,OP99 ,NEED DILATED FUNDUS EXAM

DIAGNOSIS

Pseudophakia in Right Eye
Cataract in Left Eye
Iris Coloboma in Both Eyes
Pathological Myopia With Amblyopia LE>RE
Npdr in Both Eyes
Diagnosis Comments/Clinical Impression :
?RE MACULAR EDEMA.

PLAN OF CARE:

STRICT GLYCEMIC CONTROL

Rx

1. MICRONAC PF EYE DROP [NEPAFENAC]
One Drop three times in a day for 30 Days in BOTH EYES
2. LUBREX DS EYE DROP [CMC 1%]
One Drop four times in a day for 90 Days in BOTH EYES

DOCTOR'S ADVICE:

BE OCT MACULA
BE FUNDUS PHOTO.
RETINA OPINION WITH DR SJ.

NEXT REVIEW : BY APPOINTMENT ONLY



A Unit of SUNETRA EYE CENTRE PVT. LTD.

CIN No.: 48510DL 2012 PTC 241040

KC-120, KAVI NAGAR, GHAZIABAD PH. : 0120 - 4533333, 9891087007, 0582348770
Web.: www.sunetra.co.in, E-mail: sunetraeyecare@gmail.com



VRINDA Diagnostics

www.vrinda.info.com

Patient Name : Mrs. SHANTI
Age/Sex : 65 Y/Female
Patient ID : 44594
Refer by : Dr. ACHAL SWAMI
Source : Vrinda Diagnostics Nehru Nagar

Registered : 02/Mar/2022 11:25AM
Received : 02/Mar/2022 11:25AM
Reporting : 02/Mar/2022 02:22PM
Sample Id : 4220302018



X- RAY DORSOLUMBAR SPINE AP & LAT VIEW


Anterolisthesis of L5 over S1 vertebrae is seen with pars interarticularis defect at this level.
Anterior wedge compression of L1 vertebra is noted with sclerotic changes along the inferior end plate-likely osteoporotic.
The vertebral bodies reveal evidence of marginal osteophytic changes.
Inter-vertebral disc space is reduced at L5-S1 level.
Bone density appears diffusely reduced.
Rest of the inter-vertebral disc spaces are maintained.

PLEASE CORRELATE CLINICALLY.

*** End Of Report ***

Test Requested: X-RAY DORSO LUMBAR SPINE AP & LAT VIEW

DR. DHRUV SHARMA
MBBS DMRD(RADIOLOGIST)
CONSULTANT RADIOLOGIST


DR. SAKSHI TOMAR PARIHAR
MBBS, MD (RADIOLOGIST)
CONSULTANT RADIOLOGIST

DR. ADIL ALI KHAN
MBBS, MD(RADIOLOGIST)
CONSULTANT RADIOLOGIST

DR. PRABHAT KUMAR DAS
MBBS, DMRD(RADIOLOGIST)
CONSULTANT RADIOLOGIST

Authenticated On : 02/Mar/2022 02:22PM
Print DateTime : 02-Mar-22 2:22 PM

Pathological and Radiological findings are only professional opinions and not the diagnosis. They are always considered in conjunction with clinical and other investigatory findings where applicable. Findings on the blood samples collected from outside the lab are not liable to challenge.

III - B/10, Nehru Nagar, Gurgaon



Scanned with OKEN Scanner

Patient Name Mr Shanki Age/Sex 65yr M Date 25/2/22

Backache

Ado
D. L. spine
Lab

Tab. Astiff MR x 1 day + 10%
Wampnoid

25/2/22

4/3/22

Spinal ext exercises & quadriceps
Tab. Chlcal 25
Tab. ~~Paracetamol~~ Etos-P
today

रोगियों के लिए आवश्यक निर्देश : प्लास्टर वाले अंग को ऊंचा रखें। प्लास्टर वाले हाथ/पैर की उंगलियों को खूब पूरी रेंज में चलाते रहें और सूजन आने, ठंडी या नीली पड़ने, अत्यधिक दर्द होने या तेज बुखार होने पर तुरन्त दिखायें। प्लास्टर टूटने, ढीला पड़ने, प्लास्टर से दबाव या बदबू महसूस करने पर तुरन्त दिखायें। प्लास्टर के अन्दर हड्डी अपनी जगह से सरक सकती है, जो दुबारा एक्स-रे से ही पता चलेगी। इस ईलाज से सम्भावित दुष्परिणाम और इस मर्ज के वैकल्पिक इलाज के विषय में समझ लें। ईलाज के परिणाम के विषय में कोई गारन्टी नहीं है। तसल्ली न होने पर दूसरे हड्डी रोग विशेषज्ञ से सलाह लें। पैर के फ्रैक्चर वाले रोगी पैर पर वजन डॉक्टर की सलाह के बाद से दें। ● आगे न हकें ● वजन न उठावें ● बहुत देर न खड़े रहें ● बहुत दूर पैदल न चलें ● उकड़ू न बैठें ● सीढ़ियां न चढ़ें ● ब्लड प्रेशर, शुगर या अन्य बीमारी के मरीज दवा नियमित रूप से लें।

ON PANAL:

● NAGAR HOSPITAL ● HEERALAL HOSPITAL

Identity of Patient Not Verified, Hence Not Valid for Medico Legal Purpose